

Hip labral reconstruction: consensus study on indications, graft type and technique among high-volume surgeons

David R. Maldonado, Ajay C. Lall, Rafael Walker-Santiago, Philip Rosinsky, Jacob Shapira, Jeffrey W. Chen and Benjamin G. Domb*

American Hip Institute, 999 E Touhy Ave, Des Plaines, IL 60018, USA.

*Correspondence to: B. G. Domb. E-mail: DrDomb@americanhipinstitute.org

Submitted 21 September 2018; Revised 7 December 2018; revised version accepted 3 February 2019

ABSTRACT

To survey high-volume hip arthroscopists regarding their current indications for labral reconstruction, graft preference and technique. In May 2018, a cross-sectional based survey was conducted on high-volume hip arthroscopists. A high-volume surgeon was defined as an orthopaedist who had case experience ranging from 50 to 5000 hip arthroscopies performed annually. The survey included their current indications for labral reconstruction, graft preference and technique. Twelve high-volume surgeons successfully completed the questionnaire. The mean arthroscopic procedures performed by the surgeons annually was 188.7 (range 60–350). Four surgeons (33.3%) performed <5 labral reconstruction cases per year, three (25.0%) 5–10 cases per year, two (16.7%) 11–15 cases per year and three (25.0%) over 20 cases per year. Of the 12 surgeons, 11 (91.6%) would reconstruct in certain primary settings and 100% would reconstruct in revision settings. In the primary setting, the main indications for reconstruction were poor quality labral tissue, calcified labrum and hypoplastic labrum. None of the surgeons recommended labral reconstruction for reparable labral tears in primary cases. In primary cases of irreparable labra, 58.3% of the surgeons favoured reconstruction over debridement. In revisions, 100% of the surgeon favoured reconstruction over debridement; 91.7% chose an allograft option versus an autograft alternative. Amongst high-volume arthroscopists, labral reconstruction was considered a valuable technique to restore labral function. Labral reconstruction was more often advocated in revision than in primary settings. Allograft was the preferred choice for reconstruction. Excision of the labral tissue prior to reconstruction was favoured over augmentation. Fewer surgeons performed circumferential reconstruction than segmental reconstruction.

INTRODUCTION

The labrum is a vital structure for normal biomechanics of the hip joint [1–6]. Preservation and restoration of labral function have been advocated as key factors for success in hip preservation surgery. Several publications demonstrated that hip arthroscopy is a valid tool to accomplish these goals [7–12]. Labral repair versus debridement may lead to better results in the short- and mid-long-term outcomes especially in a high-risk population like ‘borderline’ dysplastic patients [8, 13–19]. The modernization and explosion of innovative hip arthroscopy tools and techniques have shifted the field towards labral preservation procedures over simple debridement [14, 20]. Nevertheless, in

circumstances when labral tears cannot be repaired (Fig. 1), and labral reconstruction is an alternative technique to re-establish labral functionality [21–23]. Different authors have published early outcomes that affirm reconstruction’s utility [23–26]. However, the ideal technique, the optimal graft and even proper indications for procedure remain subjects of debate [22, 27–31]. Both, autograft and allograft have been used for labral reconstruction [22], going from iliotibial band [32, 33], indirect head of the rectus femoris [21] and hamstring autografts [26], to iliotibial band [25, 30, 34] and hamstring allografts [31, 35]. Technically demanding, labral reconstructions currently can only be accomplished reproducibly by a handful of

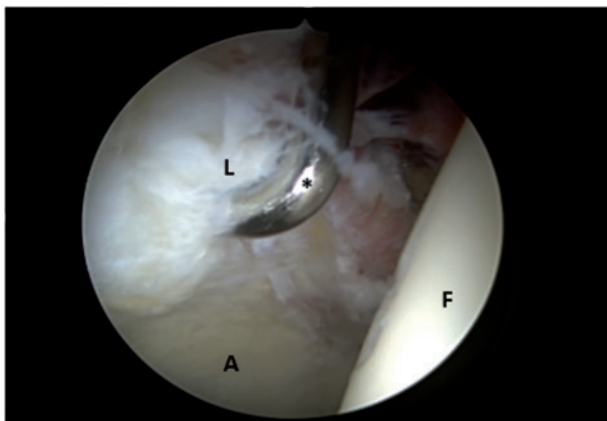


Fig. 1. Irreparable labral tear. Right hip, viewing from anterolateral portal with 70° arthroscope, probe coming from the mid-anterior portal. L, labral tear; F, femoral head; *, probe.

orthopaedic hip surgeons around the world [22, 30, 36–39]. The purpose of this study was to survey these high-volume hip arthroscopists to document their current indications for labral reconstruction, technique and graft preference (allograft versus autograft) [31, 32, 35, 38]. It was hypothesized that labral reconstruction in the setting of irreparable tears would be an important resource of treatment among high-volume hip specialist orthopaedic surgeons.

MATERIALS AND METHODS

In May 2018, a cross-sectional based survey questionnaire was conducted on hip specialist orthopaedic surgeons classified as ‘high-volume surgeons’ who served as faculty members during a Hip Arthroscopy Current Concepts meeting [40–43]. Based on previous high-volume hip arthroscopy surgeon consensus, high volume was defined as an orthopaedic surgeon who had case experience ranging from 50 to 5000 hip arthroscopies performed annually [43, 44]. The questionnaire itself was not a validated questionnaire. Rather it represented a list of commonly debated questions within the hip arthroscopy community concerning arthroscopic labral reconstruction. The survey included four fill in the blank questions, six single-choice questions and two multiple-choice questions (Appendix). The participants completed their surveys in person, and responses were kept anonymous. Questions were designed to include each respondent’s current indications, graft type preference and technique for labral reconstruction.

The study was exempt from institutional review board because of the confidential and anonymous nature of the survey. Consent from each individual surgeon was obtained before participation. The lead and senior authors

(D.R.M. and B.G.D.) developed the current study in consultation with the Institution Statistics Department. Because the current study only represented the prevalence of reconstruction among high-volume practices, statisticians agreed that statistical analysis would not be appropriate for the study’s purposes.

RESULTS

Arthroscopic labral reconstruction as an option

In total, 21 high-volume hip specialist orthopaedic surgeons were present at the meeting and invited to participate in the consensus, and 13 surgeons responded to the questionnaire. Of the 13, 12 (92.3%) had labral reconstructions in their surgical repertoire. High-volume surgeons that did not include labral reconstruction in their current practice were excluded from the study. The mean total number of hip arthroscopies performed by the surgeons annually was 188.7 (range 60–350).

Arthroscopic labral reconstructions performed annually

Each surgeon was asked to report the average number of labral reconstructions they performed per year. Responses indicated 33.3% of the surgeons performed <5 reconstructions per year, 25% between 5 and 10, 16.7% between 11 and 15 and 25% performed 20 or more.

Labral reconstruction in primary hip arthroscopy

Percentages of labral reconstructions in the primary setting were collected. All but one of the surgeons (91.7%) performed reconstruction in <5% of primary cases (Table I).

Labral reconstruction in revision hip arthroscopy

Surgeons reported the occurrence of labral reconstruction in the revision setting. In total, 33.3% of the surgeons reported encountering 5–10 cases of reconstruction in such setting, 25% reported 11–20 cases, 33.3% reported 21–40 cases and 8.3% reported 41 or more cases per year, (Table I).

Indications for labral reconstruction

The following were selected as indications for labral reconstruction in a primary case: poor quality labral tissue (21.1%), calcified labrum (26.3%) and hypoplastic labrum (7.9%). No surgeon selected ‘torn labrum’ as an indication for labral reconstruction (Table II).

Revision arthroscopy for failed prior labral repair or prior reconstruction was another selection for indications for labral reconstruction (26.3% and 18.4%, respectively) (Table II).

Table I. Labral reconstruction frequency

	Surgeons (%)
Reconstructions performed annually	
≤5 cases per year	4 (33.3)
5–10 cases per year	3 (25.0)
11–15 cases per year	2 (16.7)
≥20 cases per year	3 (25.0)
Percentage of primary arthroscopies with reconstruction (%)	
0	1 (8.3)
1	5 (41.7)
2–4	2 (16.7)
<5	3 (25.0)
10	1 (8.3)
Revision arthroscopies with reconstruction	
5–10 cases per year	4 (33.3)
11–20 cases per year	3 (25.0)
21–40 cases per year	4 (33.3)
≥41 cases per year	1 (8.3)

Labral reconstruction versus labral debridement in primary and revision surgery

In primary cases, 58.3% of the surgeons selected labral reconstruction over debridement for hips with irreparable labral tear findings. In revision cases, all surgeons agreed to proceed with reconstruction. In cases of failure of prior labral reconstruction, 63.6% of the surgeons would perform a new reconstruction, while 36.4% would abstain (Table II).

Graft preference and technique for labral reconstruction

For graft choice, 91.7% of the surgeons selected some form of allograft for labral reconstruction (Table III). For treatment of the pre-existing labral tissue prior to reconstruction, 54.5% selected complete excision, while 45.5% selected incorporation of native labral tissue into the reconstruction (augmentation). Segmental reconstruction was the preferred technique over circumferential (50% and 16.7%, respectively; Table III).

Table II. Surgical indications and irreparable labra procedures

	Percentage
Indications for reconstruction	
Poor quality labral tissue in primary surgery	66.6%
Calcified labrum in primary surgery	83.3%
Hypoplastic labrum in primary surgery	4 (33.3%)
ALL primary surgeries for torn labrum	0
Revision arthroscopy for failed previous failed repair	75%
Revision arthroscopy for failed previous failed reconstruction	66.6%
Primary cases with irreparable labral tears: reconstruction over debridement?	
Yes	7 (58.3%)
No	5 (41.7%)
Revision cases with irreparable labral tears: Reconstruction over Debridement?	
Yes	12 (100%)
No	0
Revision cases with failed labral reconstruction: Reconstruct again after failed reconstruction? ^a	
Yes	7 (63.6%)
No	4 (36.4%)

^aOne participant did not answer question.

DISCUSSION

The present study reports current trends in hip labral reconstruction among high-volume hip specialist orthopaedic surgeons.

Labral reconstruction was found to be a common procedure for labral function restoration for high-volume hip specialist orthopaedic surgeons; 92.3% of the surveyed surgeons reported having this technique in their arsenal. Arthroscopic reconstruction is a technically demanding procedure that requires long and high-volume training before adequate adroitness. As such, it is unlikely that the presented outcomes reflect reconstruction rates in lower-volume surgeons who may not be able to reproducibly achieve the same results [22, 27, 36, 45, 46].

Table III. Labral reconstruction technique

	Surgeons (%)
Graft choice	
Hamstring autograft	0
Hamstring allograft	3 (25.0)
Fascia lata autograft	1 (8.3)
Fascia lata allograft	2 (16.7)
Anterior tibialis allograft	5 (41.7)
Tissue bank acetabular labrum	1 (8.3)
Technique	
Segmental reconstruction	6 (50.0)
Circumferential reconstruction	2 (16.7)
Some of each	4 (33.3)
Native labral tissue ^a	
Complete excision	6 (54.5)
Preserve and include it into the reconstruction (augmentation)	5 (45.5)

^aOne participant did not answer question.

Recently, Mehta *et al.* [45] published findings regarding the learning curve in hip arthroscopy. According to the authors, a surgeon could be classified as low-volume, medium-volume, high-volume or very high-volume arthroscopist. Surprisingly, just to be considered a low-risk surgeon (very high volume), one had to perform at least 519 hip arthroscopies within 5 years. The authors concluded that ‘the learning curve for hip arthroscopy was unexpectedly demanding’. In the current study, even within the cohort of high-volume surgeons, there was a wide variation in annual reconstructions performed. White *et al.* [27, 47] highlighted the possibility of being an ‘experienced hip arthroscopist’, yet a ‘novice labral reconstructionist’. Taking the study results from Mehta *et al.* as a template, a classification with reference to labral reconstruction expertise may be applied to the high-volume surgeons to subcategorize by volume of reconstructions in the revision scenario: 5–10 cases per year (33.3%) classifies as low-volume labral reconstructionist; 11–20 cases per year (25%), medium-volume reconstructionist; 21–40 cases per year (33.3%), high-volume reconstructionist; over 41 cases per year (8.3%), very high-volume reconstructionist. Future research is needed to determine how reconstruction

volume affects patient-reported outcomes and to establish parameters for one to be considered a ‘low-risk labral reconstructionist’.

Labral reconstruction is mostly performed in the setting of revision hip arthroscopy [14, 22, 25, 46]. A study by Domb *et al.* comparing outcomes of labral reconstruction versus resection in patients symptomatic for femoroacetabular impingement concluded that at minimum 2-year follow-up, labral reconstruction produced higher values for Non-Arthritic Hip Score and Hip Outcome Score-Activities of Daily Living. The present study showed that all 12 surgeons selected reconstruction rather than debridement in cases of revision hip arthroscopy with findings of irreparable labra (Fig. 2). Interestingly, in primary cases with similar findings of irreparable labral tear, 41.7% of these surgeons favoured debridement over reconstruction. The reasons for this difference in treatment when faced with the same labral findings cannot be clarified without deeper investigation. Most of the research on arthroscopic labral reconstruction available comprise of technical notes, case-series reports and short-term follow-up predominately from revision surgeries [14, 21, 23, 24, 26, 29–32, 35, 38, 46, 48, 49]. The lack of evidence for primary reconstructions may explain why high-volume surgeons exercise caution in proceeding with reconstruction in the primary setting.

Recently, promising short-term follow-up data involving labral reconstruction in primary hip arthroscopy may shift the trend for primary reconstruction to become a more feasible alternative than complete debridement or excision [30]. The comparison of efficacy between labral reconstructions with labral repair has been a topic of increasing study [28, 29]. White *et al.* [28] concluded that patients with previous failed labral repair were 2.6 times more likely to fail with re-repair than with revision reconstruction, although these findings represented the results of a single high-volume surgeon, which limits generalizability. In a more controversial study, comparing labral repair versus reconstruction in primary hip arthroscopy, the same authors reported a 31% increased likelihood of failure in patients who underwent primary labral repair compared to their reconstruction counterparts [29]. However, when labral tissue is not compromised, management with primary repair has shown excellent results and outcomes at short-, mid- and long-term follow-up [11, 50, 51].

Two of the most recent systematic reviews regarding labral reconstruction identified non-salvageable labrum as the most common indication for reconstruction [22, 46]. In this study, poor quality labral tissue, calcified labrum and failed primary repair were the predominant reasons to proceed

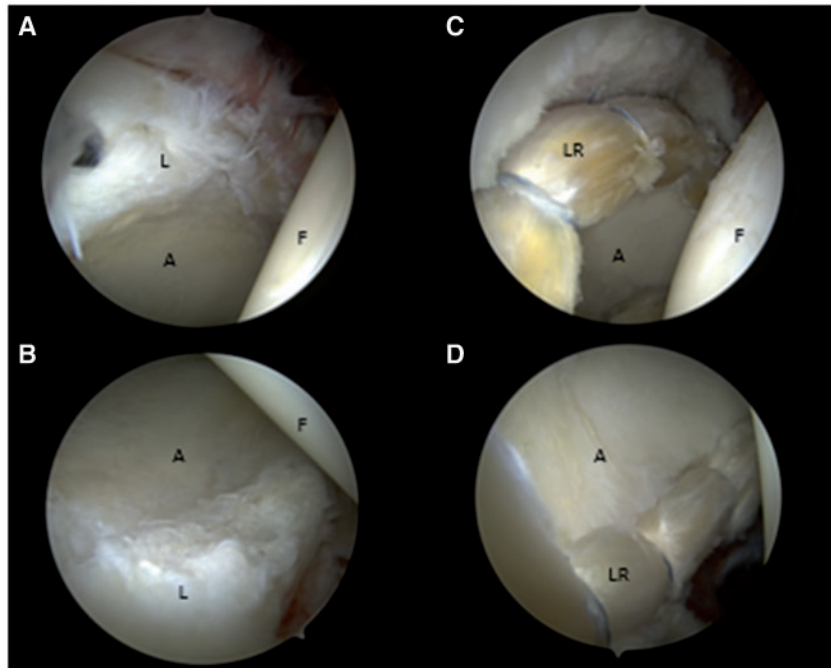


Fig. 2. Circumferential labral reconstruction in the setting of irreparable labral tear. Before circumferential labral reconstruction: (A) perspective showing irreparable labral tear from 12 to 3 o'clock position; (B) perspective showing irreparable labral tear from 11 to 7 o'clock position. After circumferential labral reconstruction: (C) perspective from 12 to 3 o'clock position; (D) perspective from 11 to 7 o'clock position. Right hip, viewing from anterolateral portal with 70° arthroscope. L, irreparable labral tear; F, femoral head, A, acetabulum; LR, labrum reconstructed.

with reconstruction. It seems that the current consensus is to 'save' the labrum with repair when possible [52].

Multiple graft options for reconstruction have been proposed [30–32, 34, 35]. Early techniques used autografts, while recent procedures have shifted towards allografts [43, 48]. Advantages and disadvantages of autografts and allografts have been described, but presently there is a dearth of available information regarding the type of graft for reconstruction and the influence this choice may have in patient outcomes or hip survivorship [14, 22, 46, 53]. In total, 91.7% of the surgeons surveyed chose an allograft option over an autograft alternative. The risk of donor site morbidity and possible reduction of surgical time may explain these decisions.

Different labral reconstruction techniques have been described [30, 31, 34, 54]. Currently, segmental and lately circumferential reconstructions are in vogue (Fig. 2). In general, the segmental technique reconstructs only the non-reparable 'segment' of the labrum (Fig. 3) [26, 33, 35]. On the other hand, circumferential reconstruction does not require precise measurement of the labral defect, and proceeds in a 'front-to-back' fashion [27, 30, 31]. Both techniques have shown good results in short-term follow-ups and neither has proven to be superior [26, 30]. The

50% of high-volume surgeons chose segmental reconstruction, 16.7% selected circumferential reconstruction and 33.3% a combination thereof.

Incorporation of the remaining labral tissue prior to reconstruction, known as augmentation, has been proposed [54]. Almost half of the surveyed surgeons selected this approach.

Limitations

Limitations of this study must be acknowledged. First, the questionnaire used for survey purposes was not a validated one. Second, the questionnaire itself included questions that are controversial among hip specialist orthopaedic surgeons and did not record quantitative outcome measures. Third, this study presents opinions and the expertise of high-volume specialized orthopaedic hip surgeon, which are not necessarily generalizable. Fourth, specific trends related to graft selection based on the surgeons' geographic area was not taken into account. Fifth, though based on previous publications, the number of performed cases selected to defined a high-volume hip arthroscopy surgeon and high-volume labral reconstructionist, were arbitrary and needs validation [36].

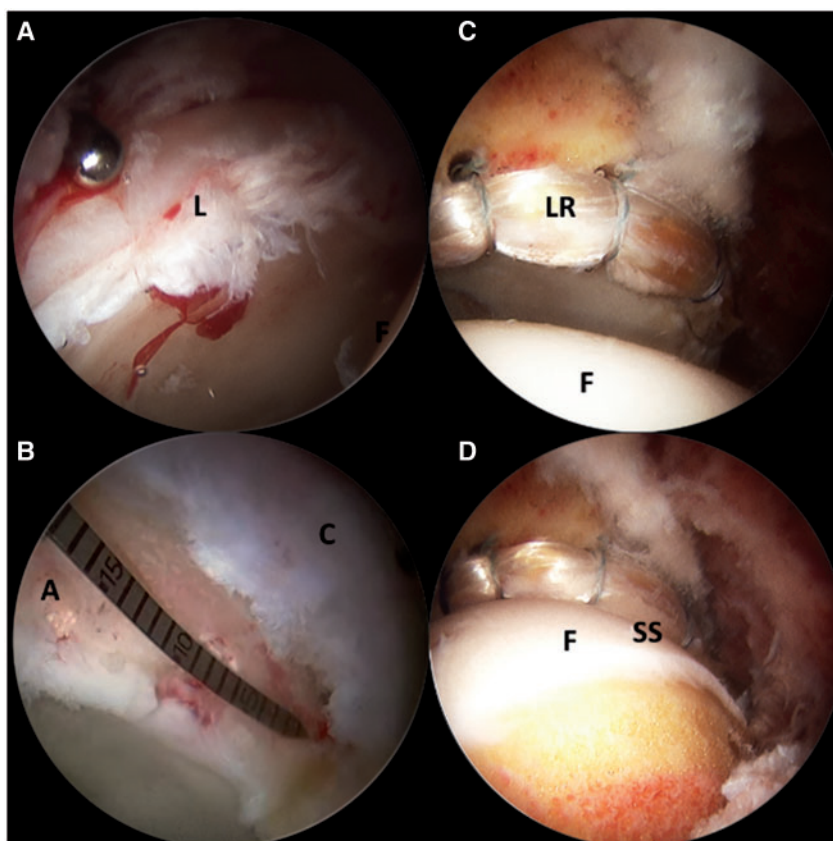


Fig. 3. Segmental labral reconstruction in the setting of irreparable labral tear. Before reconstruction: (A) perspective showing labral tear from 12 to 2 o'clock position; (B) measure of the defect. After segmental reconstruction: (C) perspective from 12 to 3 o'clock position; (D) restoration of the suction seal. Right hip, viewing from anterolateral portal with 70° arthroscope. L, irreparable labral tear; F, femoral head, A, acetabulum (segmental defect); C, capsule; LR, labrum reconstructed; SS, suction seal.

CONCLUSIONS

Amongst high-volume arthroscopists, labral reconstruction was considered a valuable technique to restore labral function. Labral reconstruction was more often advocated in revision than in primary settings. Allograft was the preferred choice for reconstruction. Excision of the labral tissue prior to reconstruction was favoured over augmentation, and segmental reconstruction was also favoured over the circumferential technique.

FUNDING

This study was performed at and received funding from the American Hip Institute. No specific grant was given for this study. This study was approved by the Institutional Review Board (IRB ID: 5276).

CONFLICT OF INTEREST STATEMENT

A.C.L. has received educational funding from Medwest Associates and Smith & Nephew; Food and Beverage from Arthrex, Iroko Pharmaceuticals, Stryker, Vericel and Zimmer Biomet; Research support from Arthrex; Travel and Lodging

from Arthrex and Stryker. B.G.D. is a board member for American Orthopedic Foundation, American Hip Foundation, AANA Learning Center Committee, Hinsdale Hospital Foundation and Arthroscopy Journal; Consulting Fees from Adventist Hinsdale Hospital, Amplitude, Arthrex, MAKO, Medacta, Pacira Pharmaceuticals and Stryker; Educational funding from Arthrex, Breg and Medwest; Food and Beverage from Arthrex, Ceterix Orthopaedics, DePuy Syntheses Sales, DJO Global, FUJIFILM SonoSite, Linvatec, MAKO Surgical Corporation, Medacta, Pacira Pharmaceuticals, Stryker and Zimmer Biomet Holdings; Ownership Interests in Hinsdale Orthopedic Associates, American Hip Institute, SCD#3, North Shore Surgical Suites, Munster Specialty Surgery Center; Research support from Arthrex, ATI, Kaufman Foundation, Medacta, Pacira Pharmaceuticals and Stryker; Royalties from Arthrex, DJO Global, MAKO Surgical Corporation, Stryker and Orthomerica; Speaking fees from Arthrex and Pacira Pharmaceuticals; Travel and lodging from Arthrex, Medacta and Stryker.

REFERENCES

1. Bsat S, Frei H, Beaulé PE. The acetabular labrum: a review of its function. *Bone Joint J* 2016; **98B**: 730–5.
2. Ferguson SJ, Bryant JT, Ganz R *et al*. The acetabular labrum seal: a poroelastic finite element model. *Clin Biomech (Bristol, Avon)* 2000; **15**: 463–8.
3. Dwyer MK, Jones HL, Hogan MG *et al*. The acetabular labrum regulates fluid circulation of the hip joint during functional activities. *Am J Sports Med* 2014; **42**: 812–9.
4. Grant AD, Sala DA, Davidovitch RI. The labrum: structure, function, and injury with femoro-acetabular impingement. *J Child Orthop* 2012; **6**: 357–72.
5. Philippon MJ, Nepple JJ, Campbell KJ *et al*. The hip fluid seal—part I: the effect of an acetabular labral tear, repair, resection, and reconstruction on hip fluid pressurization. *Knee Surg Sports Traumatol Arthrosc* 2014; **22**: 722–9.
6. Seldes RM, Tan V, Hunt J *et al*. Anatomy, histologic features, and vascularity of the adult acetabular labrum. *Clin Orthop* 2001; **382**: 232–40.
7. Audenaert EA, Dhollander AAM, Forsyth RG *et al*. Histologic assessment of acetabular labrum healing. *Arthroscopy* 2012; **28**: 1784–9.
8. Kalore NV, Jiranek WA. Save the torn labrum in hips with borderline acetabular coverage. *Clin Orthop* 2012; **470**: 3406–13.
9. Philippon MJ, Bolia I, Locks R *et al*. Treatment of femoroacetabular impingement: labrum, cartilage, osseous deformity, and capsule. *Am J Orthop* 2017; **46**: 23–7.
10. Domb BG, Stake CE, Lindner D *et al*. Arthroscopic capsular plication and labral preservation in borderline hip dysplasia: two-year clinical outcomes of a surgical approach to a challenging problem. *Am J Sports Med* 2013; **41**: 2591–8.
11. Domb BG, Yuen LC, Ortiz-Declet V *et al*. Arthroscopic labral base repair in the hip: 5-year minimum clinical outcomes. *Am J Sports Med* 2017; **45**: 2882–90.
12. Domb BG, Chaharbakhshi EO, Perets I *et al*. Hip arthroscopic surgery with labral preservation and capsular plication in patients with borderline hip dysplasia: minimum 5-year patient-reported outcomes. *Am J Sports Med* 2018; **46**: 305–13.
13. Chen AW, Yuen LC, Ortiz-Declet V *et al*. Selective debridement with labral preservation using narrow indications in the hip: minimum 5-year outcomes with a matched-pair labral repair control group. *Am J Sports Med* 2018; **46**: 297–304.
14. Domb BG, Hartigan DE, Perets I. Decision making for labral treatment in the hip: repair versus débridement versus reconstruction. *J Am Acad Orthop Surg* 2017; **25**: e53–62.
15. Harris JD. Hip labral repair: options and outcomes. *Curr Rev Musculoskelet Med* 2016; **9**: 361–7.
16. Hevesi M, Krych AJ, Johnson NR *et al*. Multicenter analysis of midterm clinical outcomes of arthroscopic labral repair in the hip: minimum 5-year follow-up. *Am J Sports Med* 2018; **46**: 280–7.
17. Larson CM, Ross JR, Stone RM *et al*. Arthroscopic management of dysplastic hip deformities: predictors of success and failures with comparison to an arthroscopic FAI cohort. *Am J Sports Med* 2016; **44**: 447–53.
18. Khan M, Habib A, de Sa D *et al*. Arthroscopy up to date: hip femoroacetabular impingement. *Arthroscopy* 2016; **32**: 177–89.
19. Larson CM, Giveans MR. Arthroscopic debridement versus refixation of the acetabular labrum associated with femoroacetabular impingement. *Arthroscopy* 2009; **25**: 369–76.
20. Bonazza NA, Homcha B, Liu G *et al*. Surgical trends in arthroscopic hip surgery using a large national database. *Arthroscopy* 2018; **34**: 1825–30.
21. Amar E, Sampson TG, Sharfman ZT *et al*. Acetabular labral reconstruction using the indirect head of the rectus femoris tendon significantly improves patient reported outcomes. *Knee Surg Sports Traumatol Arthrosc* 2017; **26**: 2512–18.
22. Ayeni OR, Alradwan H, de Sa D *et al*. The hip labrum reconstruction: indications and outcomes—a systematic review. *Knee Surg Sports Traumatol Arthrosc* 2014; **22**: 737–43.
23. Domb BG, El Bitar YF, Stake CE *et al*. Arthroscopic labral reconstruction is superior to segmental resection for irreparable labral tears in the hip: a matched-pair controlled study with minimum 2-year follow-up. *Am J Sports Med* 2014; **42**: 122–30.
24. Boykin RE, Patterson D, Briggs KK *et al*. Results of arthroscopic labral reconstruction of the hip in elite athletes. *Am J Sports Med* 2013; **41**: 2296–301.
25. Locks R, Bolia IK, Utsunomiya H *et al*. Revision hip arthroscopy after labral reconstruction using iliotibial band autograft: surgical findings and comparison of outcomes with labral reconstructions not requiring revision. *Arthroscopy* 2018; **34**: 1244–50.
26. Chandrasekaran S, Darwish N, Close MR *et al*. Arthroscopic reconstruction of segmental defects of the hip labrum: results in 22 patients with mean 2-year follow-up. *Arthroscopy* 2017; **33**: 1685–93.
27. White BJ, Herzog MM. Labral reconstruction: when to perform and how. *Front Surg* 2015; **2**: 27.
28. White BJ, Patterson J, Herzog MM. Revision arthroscopic acetabular labral treatment: repair or reconstruct? *Arthroscopy* 2016; **32**: 2513–20.
29. White BJ, Patterson J, Herzog MM. Bilateral hip arthroscopy: direct comparison of primary acetabular labral repair and primary acetabular labral reconstruction. *Arthroscopy* 2018; **34**: 433–40.
30. Scanaliato JP, Christensen DL, Salfiti C *et al*. Primary circumferential acetabular labral reconstruction: achieving outcomes similar to primary labral repair despite more challenging patient characteristics. *Am J Sports Med* 2018; **46**: 2079–88.
31. Perets I, Hartigan DE, Chaharbakhshi EO *et al*. Circumferential labral reconstruction using the knotless pull-through technique—surgical technique. *Arthrosc Tech* 2017; **6**: e695–8.
32. Chahla J, Soares E, Bhatia S *et al*. Arthroscopic technique for acetabular labral reconstruction using iliotibial band autograft. *Arthrosc Tech* 2016; **5**: e671–7.
33. Geyer MR, Philippon MJ, Fagrelus TS *et al*. Acetabular labral reconstruction with an iliotibial band autograft: outcome and survivorship analysis at minimum 3-year follow-up. *Am J Sports Med* 2013; **41**: 1750–6.
34. White BJ, Herzog MM. Arthroscopic labral reconstruction of the hip using iliotibial band allograft and front-to-back fixation technique. *Arthrosc Tech* 2016; **5**: e89–97.
35. Redmond JM, Cregar WM, Martin TJ *et al*. Arthroscopic labral reconstruction of the hip using semitendinosus allograft. *Arthrosc Tech* 2015; **4**: e323–9.

36. Hoppe DJ, de Sa D, Simunovic N *et al.* The learning curve for hip arthroscopy: a systematic review. *Arthroscopy* 2014; **30**: 389–97.
37. Locks R, Bolia I, Utsunomiya H *et al.* Current concepts in revision hip arthroscopy. *Hip Int* 2018; **28**: 343–51.
38. Locks R, Bolia IK, Utsunomiya H *et al.* Revision hip arthroscopy after labral reconstruction using iliotibial band autograft: surgical findings and comparison of outcomes with labral reconstructions not requiring revision. *Arthroscopy* 2018; **34**: 1244–50.
39. Duchman KR, Westermann RW, Glass NA *et al.* Who is performing hip arthroscopy?: An analysis of the American Board of Orthopaedic Surgery Part-II Database. *J Bone Joint Surg Am* 2017; **99**: 2103–9.
40. Humphrey-Murto S, Varpio L, Wood TJ *et al.* The use of the Delphi and other consensus group methods in medical education research: a review. *Acad Med* 2017; **92**: 1491–8.
41. Rath E, Sharfman ZT, Paret M *et al.* Hip arthroscopy protocol: expert opinions on post-operative weight bearing and return to sports guidelines. *J Hip Preserv Surg* 2017; **4**: 60–6.
42. Westby MD, Brittain A, Backman CL. Expert consensus on best practices for post-acute rehabilitation after total hip and knee arthroplasty: a Canada and United States Delphi study. *Arthritis Care Res (Hoboken)* 2014; **66**: 411–23.
43. Gupta A, Suarez-Ahedo C, Redmond JM *et al.* Best practices during hip arthroscopy: aggregate recommendations of high-volume surgeons. *Arthroscopy* 2015; **31**: 1722–7.
44. Domb BG, Stake CE, Finch NA *et al.* Return to sport after hip arthroscopy: aggregate recommendations from high-volume hip arthroscopy centers. *Orthopedics* 2014; **37**: e902–5.
45. Mehta N, Chamberlin P, Marx RG *et al.* Defining the learning curve for hip arthroscopy: a threshold analysis of the volume-outcomes relationship. *Am J Sports Med* 2018; **46**: 1284–93.
46. Forster-Horvath C, von Rotz N, Giordano BD *et al.* Acetabular labral debridement/segmental resection versus reconstruction in the comprehensive treatment of symptomatic femoroacetabular impingement: a systematic review. *Arthroscopy* 2016; **32**: 2401–15.
47. Philippon MJ, Utsunomiya H, Briggs KK *et al.* My first 100 compared to my last 100 labral reconstructions—the role of patient selection in increasing survivorship. *Orthop J Sports Med* 2018; **6**(7 Suppl4).
48. Lee S, Wuerz TH, Shewman E *et al.* Labral reconstruction with iliotibial band autografts and semitendinosus allografts improves hip joint contact area and contact pressure: an *in vitro* analysis. *Am J Sports Med* 2015; **43**: 98–104.
49. Amenabar T, O'Donnell J. Arthroscopic ligamentum teres reconstruction using semitendinosus tendon: surgical technique and an unusual outcome. *Arthrosc Tech* 2012; **1**: e169–74.
50. Menge TJ, Briggs KK, Dornan GJ *et al.* Survivorship and outcomes 10 years following hip arthroscopy for femoroacetabular impingement: labral debridement compared with labral repair. *J Bone Joint Surg Am* 2017; **99**: 997–1004.
51. Byrd JWT, Jones KS. Hip arthroscopy for labral pathology: prospective analysis with 10-year follow-up. *Arthroscopy Surg* 2009; **25**: 365–8.
52. Youm T. Editorial Commentary: wanted dead or alive: primary allograft labral reconstruction of the hip is as successful, if not more successful, than primary labral repair. *Arthroscopy* 2018; **34**: 441–3.
53. Kartus J, Movin T, Karlsson J. Donor-site morbidity and anterior knee problems after anterior cruciate ligament reconstruction using autografts. *Arthroscopy* 2001; **17**: 971–80.
54. Locks R, Chahla J, Frank JM *et al.* Arthroscopic hip labral augmentation technique with iliotibial band graft. *Arthrosc Tech* 2017; **6**: e351–6.

APPENDIX

SURVEY STUDY: CONSENSUS STATEMENT ON INDICATIONS FOR LABRAL RECONSTRUCTION IN 2018

1. Approximately how many hip arthroscopies do you perform annually?

2. Currently, is labral reconstruction an option in your labral treatment repertoire? If “no”, stop here.
 - Yes
 - No
3. Approximately how many labral reconstructions do you perform annually?

4. What % of your primary hip arthroscopies involve labral reconstruction?

5. What % of your revision hip arthroscopies involve labral reconstruction?

6. ‘Circle all of the following’ that you would consider an indication for labral reconstruction:
 - Poor quality labral tissue in primary surgery
 - Calcified labrum in primary surgery
 - Hypoplastic labrum in primary surgery
 - ALL primary surgeries for torn labrum
 - Revision arthroscopy for failed previous failed ‘repair’
 - Revision arthroscopy for failed previous failed ‘reconstruction’
7. In a ‘primary’ surgery with an irreparable labral tear, is labral reconstruction your treatment choice over labral debridement?
 - Yes
 - No
8. In a ‘revision’ surgery with an irreparable labral tear, is labral reconstruction your choice over labral debridement?
 - Yes
 - No
9. In labral reconstruction, what is your graft choice option? (Please select just one)
 - Hamstring autograft

- Fascia lata autograft
 - Hamstring allograft
 - Fascia lata allograft
 - Anterior tibialis allograft
 - Other _____
10. If you perform labral reconstruction, which describes your current technique?
- Segmental reconstruction
 - Circumferential reconstruction
 - Some of each
11. If you perform labral reconstruction, what is your approach with native labral tissue?
- Complete excision
 - Preserve and include it into the reconstruction (augmentation)
12. In the case of failed reconstruction in a patient with minimal to no arthritis (Tönnis 0–1), would you consider reconstructing again?
- Yes
 - No