



Contents lists available at ScienceDirect

International Journal of Surgery Case Reports

journal homepage: www.casereports.com

Large ileocecal submucosal lipoma presenting as hematochezia, a case report and review of literature



Hiba Hassan El Hage Chehade^a, Riad Hassan Zbibo^a, Walid Nasreddine^b,
Houssam Khodor Abtar^{a,*}

^a Makassed General Hospital, Department of Surgery, Beirut, Lebanon

^b Makassed General Hospital, Department of Gastroenterology, Beirut, Lebanon

ARTICLE INFO

Article history:

Received 18 February 2015

Received in revised form 3 March 2015

Accepted 4 March 2015

Available online 7 March 2015

Keywords:

Colonic lipoma

Hematochezia

Right hemicolectomy

ABSTRACT

INTRODUCTION: Colonic lipomas are rare subepithelial benign tumors affecting mainly middle-aged women. They are usually asymptomatic and, hence, are discovered incidentally on autopsy, surgery, or colonoscopy. There is a wide range of presentations like abdominal pain, bleeding per rectum, intussusception, etc. The latter picture constitutes the usual presentation of an ileocecal lipoma. Only few cases of ileocecal lipomas presenting as lower GI bleeding have been reported in the literature.

PRESENTATION OF CASE: We present a case of an adult female patient who was admitted to our institution complaining of hematochezia and right lower quadrant pain. She was found to have chronic anemia. She was investigated by CT scan of the abdomen & pelvis and by colonoscopy which showed a fungating, submucosal mass with ulcerated base near the ileocecal valve. She underwent a colonic resection. The pathology came out as a submucosal benign pedunculated ileocecal lipoma.

DISCUSSION: Colonic lipomas represent 4% of benign lesions of the gastrointestinal tract. They are usually asymptomatic hence are often discovered incidentally on colonoscopy, surgery or autopsy. The definitive diagnosis is made by pathological evaluation. Colonic lipomas are usually treated if they are symptomatic or there is any suspicion of malignancy. The treatment modalities include endoscopic and surgical resection.

CONCLUSION: We, hereby, describe a case of benign ileocecal lipoma that presented with hematochezia which is an unusual presentation. Also, there is a great controversy regarding the treatment of colonic lipomas. In this article, we tried to answer several questions concerning the management of ileocecal lipomas.

© 2015 The Authors. Published by Elsevier Ltd. on behalf of Surgical Associates Ltd. This is an open access article under the CC BY-NC-ND license (<http://creativecommons.org/licenses/by-nc-nd/4.0/>).

1. Introduction

Colonic lipomas are rare nonepithelial benign tumors of the gastrointestinal tract. They are mesenchymal in origin and are composed of well-differentiated adipose tissue supported by fibrous tissue [1]. They were first described by Bauer et al. in 1757 [2]. They represent 4% of benign lesions of the gastrointestinal tract and are the second most common benign colonic tumors after adenomatous polyps [3]. Relative to all polypoid lesions of the large intestine, the incidence is reported to range from 0.035% to 4.4% [4]. Colonic lipomas are typically found in the middle-aged population with a female predominance of 66.7% [1].

The etiology is still unknown. Some refer to colonic lipomas as true neoplasms. Others say they could be due to a chronic inflammatory process, especially in the cecum, resulting in altered intestinal motility causing the mucosa to pull away from the submucosa. This will lead to the creation of a space with a subsequent adipose tissue deposition. These are better termed as pseudo-lipomas [5].

2. Presentation of case

A 42 year-old female patient, previously healthy, presented to our hospital with a two-month history of right lower quadrant abdominal pain and hematochezia. She denied any change in bowel habits, weight loss, anorexia, fever, chills, or urinary symptoms. She was on no medications, denied any previous surgeries, and her family history was positive for diabetes. On physical exam, she had mild pallor, and her abdomen was soft, nontender with no palpable lymphadenopathies or hernias. Anal exam showed no masses or fresh blood per rectum. Her laboratory investigations

* Corresponding author at: Makassed General Hospital, P.O. Box: 11-6301 Riad El-Solh, 11072210 Beirut, Lebanon. Tel.: +961 70 858658/1858658.

E-mail addresses: haj_shehadeh_hiba@hotmail.com (H.H.E.H. Chehade), rzbibo1@hotmail.com (R.H. Zbibo), walidan@hotmail.com (W. Nasreddine), dr.houssamabtar@gmail.com (H.K. Abtar).

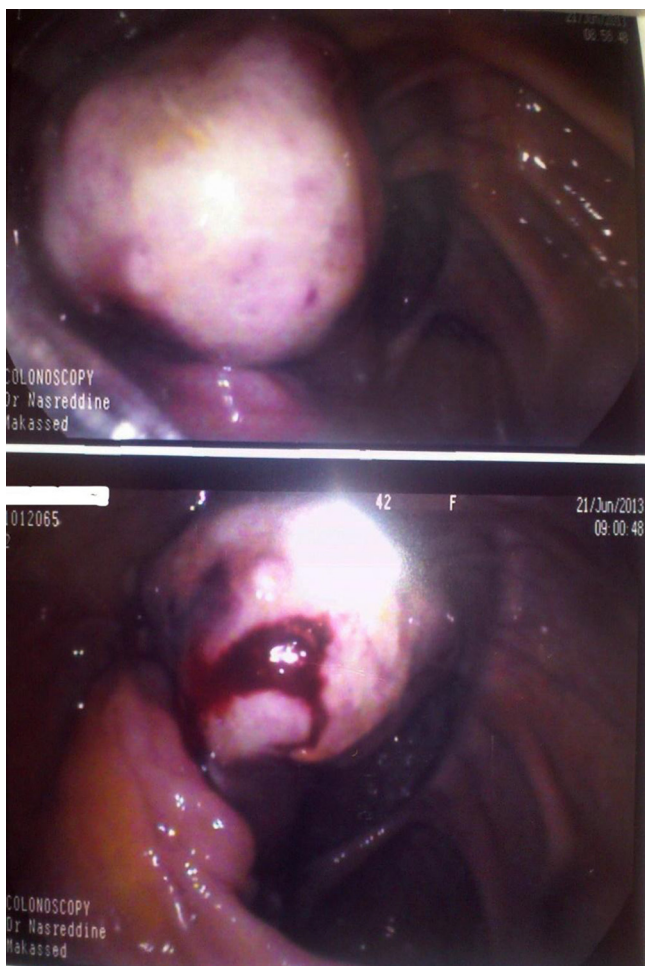


Fig. 1. Colonoscopy showed large fungating ileo-caecal mass with ulcerated base.

showed mild anemia with a hemoglobin of 10.2 and a hematocrit of 30.4. She had a CT scan of her abdomen and pelvis with IV and oral contrast which showed thickening of the ascending colon up to the proximal transverse colon with a hypodense mass. Malignancy could not be ruled out. Hence, a colonoscopy was done. The latter showed a large ileocecal fungating polyp with an ulcerated bleeding base (Fig. 1). Punch biopsy was taken and showed inflammatory changes and stigmata of ulceration. Since the possibility of malignancy could still not be ruled out, and since the patient had hematochezia with anemia, the decision was to go for a laparotomy. Abdominal exploration showed a soft palpable mass in the proximal cecum without any peritoneal seeding or liver involvement. Thus, a right hemicolectomy was done. Grossly, it was a large polypoid tumor with a diameter of 4.5 cm in its greatest dimension and a 1.7 cm stalk (Fig. 2). Pathologically, it showed a submucosal benign pedunculated lipoma (Fig. 3) with a normal surrounding mucosa and reactive mesenteric lymph nodes.

3. Discussion

Colonic lipomas are mainly found in the ascending colon and cecum with a decreasing frequency from cecum to sigmoid. They originate from deposits of adipose connective tissue in the bowel with 90% of these lesions arising from the submucosa, while the remaining 10% arising from the subserosa or the intramuscular layer [3]. Moreover, transmural colonic lipomas have also been reported [6]. Colonic lipomas contain mature adipose tissue with a thick capsule usually surrounding the tumor. Secondary

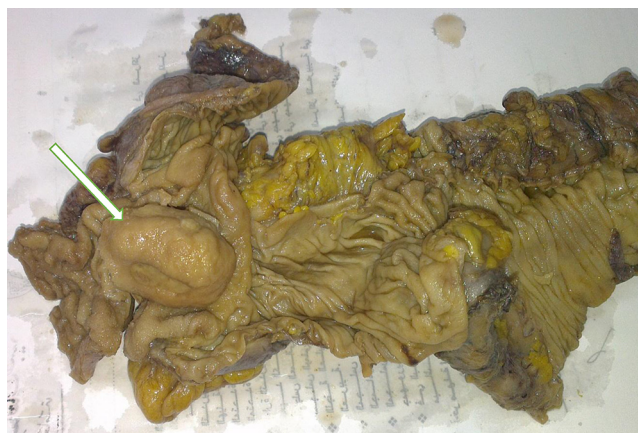

Fig. 2. opened cecum revealed large ileo-caecal polypoid tumor about 4.5 × 3 cm (arrow).

cellular changes can include nuclear hypertrophy, hyperchromasia, pleomorphism, and fat necrosis. These changes, if extensive, can mimic a liposarcoma. However, frank liposarcomas of the colon are extremely rare and require the presence of lipoblasts [7]. Sarcomatous changes have not been reported, but intermittent torsion and relative ischemia can give rise to a pseudomalignant appearance [8].

Symptoms largely depend on the size of the lipoma with symptomatic lipomas usually being >2 cm in diameter. They are usually asymptomatic hence are often discovered incidentally on colonoscopy, surgery or autopsy. Symptoms include abdominal pain, change in bowel habits, and weight loss. Rarely, ulceration of the overlying mucosa may cause clinically apparent bleeding or chronic anemia. They may have serious consequences like life-threatening hemorrhage, bowel obstruction (caused by intussusception or direct luminal protrusion of the enlarging mass) [9], and even spontaneous expulsion and prolapse have been reported [3,9]. Only few cases of ileocecal lipomas presenting as lower GI bleeding have been reported in the literature [10]. A report by Jiang et al. has shown that the most common presentations of colonic lipomas were abdominal pain (42.4%), bleeding per rectum (54.5%) and alteration in bowel habits (24.2%) [1].

There are several proposed methods to diagnose colonic lipomas. Lipomas would appear on ultrasonography as hyperechoic, well-circumscribed solid lesions with absent or minimal blood flow on color doppler sonography. However, definitive diagnosis is not possible [11]. A barium enema shows an ovoid filling defect with

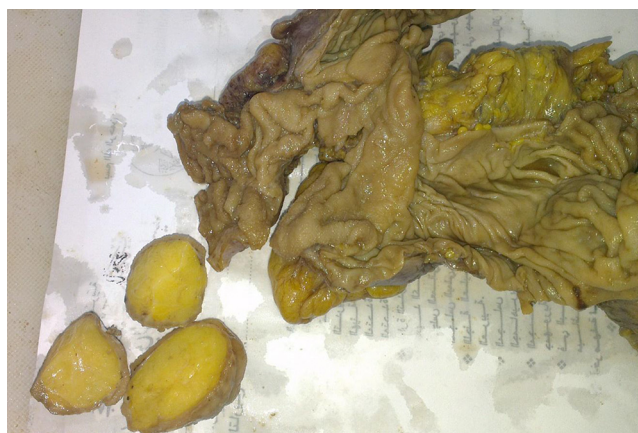

Fig. 3. Pathological photograph of tumor incised showed well circumscribed submucosal lesion.

well-defined borders. The “squeeze sign”, which is a change in the size and shape of a radiolucent lesion in response to peristalsis or the application of external pressure to the abdomen, is pathognomonic for lipomas [12]. Nonetheless, barium enemas are not totally reliable especially if the lesion is ulcerated because it would be hard to differentiate from colonic malignancy [9]. CT scan is the most useful tool for the detection of these lesions [9,11]. A colonic lipoma appears as a mass with well-defined margins and absorption density between –40 and –120HU, which is characteristic of fatty tissue [13]. CT scan has some limitations in diagnosing colonic lipomas because CT appearance may be atypical if fat necrosis or infarction is present, and smaller tumors are not detectable due to artifacts [9,12]. MRI may be particularly useful because signal intensity is characteristic of adipose tissue on T1-weighted and fat-suppressing images [12].

Colonoscopy is both diagnostic and therapeutic. A lipoma appears as a smooth, submucosal, rounded yellowish mass/polyp with a thick stalk or broad-based attachment [11,12]. Characteristic Features include the “cushion sign” or “pillow sign” (depression or pillowing of the mass due to pressing by forceps), the “naked fat sign” (extrusion of yellowish fat at the biopsy site), and the “tenting sign” (easy retraction of the overlying mucosa away from the underlying mass with a biopsy forceps) [8,12]. However, sometimes, necrotic mucosa, ulceration, and relatively hard texture of the lesion make it difficult to differentiate a lipoma from a malignant lesion [9]. Despite recent diagnostic innovations in radiology, histopathological evaluation is the gold standard in precise diagnosis [3]. Also, mucosal biopsies may be unhelpful if they yield an intact mucosa, granulation/inflammatory changes, or fat necrosis. When the tumor is sampled away from the ulcerated areas, mature adipocytes will be found [7]. Thus, even if a biopsy yields benign tissue, one cannot completely exclude the possibility of malignancy. The exact diagnosis still mainly relies on an intra- or postoperative pathology examination [11]. Endoscopic ultrasonography (EUS) plays a role in determining the size, border, and layer of origin of these colonic submucosal lesions and may improve diagnostic accuracy [13]. Also, EUS can determine any extension into the muscularis propria before injection-assisted polypectomy of symptomatic lipomas [12]. Despite recent diagnostic innovations, it has been reported that the preoperative diagnostic accuracy is only about 62% [14].

Colonic lipomas are usually treated when they are symptomatic or there is any suspicion of malignancy [3]. As for endoscopic resection, it is always preferred over surgical removal if it can be done safely [8]. They are indicated in elective cases, pedunculated, small lipomas (i.e. <2 cm in diameter) because larger lesions increase the risk of complications (uncontrolled hemorrhage and perforation) [3]. For large pedunculated lipomas, the size of the stalk seems to be a more important factor than the diameter of the lipoma when colonoscopic removal is considered [12]. Endoscopic resection carries a risk of perforation for several reasons. First, most lipomas are submucosal with high water content requiring tremendous amount of heat to cut through [8]. Second, sessile lipomas also increase the risk of perforation [15]. Third, extension of the lipoma to the muscularis propria poses a risk factor for perforation. In three of seven perforations reported by Pfler et al., specimens contained large portions of smooth muscle from the muscularis propria [16]. Thus, various techniques have been advocated to reduce the risk of perforation. Kim and coworkers reported that large colonic lipomas that do not extend to the muscularis propria, injecting saline or epinephrine at the base prior to electrosurgical resection appears to be safe [17]. Raju and Gomez used a detachable nylon endoloop to mechanically transect a 4-cm pedunculated colonic lipoma without the use of electrosurgical snare [18]. Also, unroofing technique has been proposed as a safe, easy, and suitable technique for the

treatment of large lipomas, and it is especially useful for high-risk cases with poor general condition [19].

As for surgical resection of colonic lipomas, it is indicated in large, sessile-appearing, or limited pedunculated cases, suspicion of malignancy, surgical emergencies; (obstruction, intussusception, perforation, or very rarely massive hemorrhage), involvement of the muscular layer or serosa, or in lesions that cannot be resected radically under colonoscopy [3,11,13]. The extent of resection ranges from colostomy and enucleation or segmental resection in preoperatively confirmed lipomas to hemicolectomy or even subtotal colectomy if malignancy cannot be excluded or in complicated cases [3,9]. Preferring a radical resection, even in benign cases, is not irrational because it is technically easier, ensures proper collection of LNs for appropriate staging of presumed colonic malignancy, and eliminates a second operation when an unexpected malignancy is diagnosed in the final pathological examination [9].

3. Conclusion

Colonic lipomas usually present with intussusception or volvulus, while hematochezia is a rare presentation. Also, there is a great controversy regarding the treatment: 1- when to treat, 2- endoscopic vs. surgical approach and 3- the extent of resection. We, hereby, presented to you a case of ileocecal lipoma that was admitted due to lower GI bleeding, and we discussed the various treatment options.

Conflict of interest

The author declares no conflict of interest.

Funding

The authors had no sponsor or funding.

Ethical approval

This is not a research study

Consent

Written informed consent was obtained.

Author contribution

Hiba El Hage Chehade: writing the paper.
Houssam Abtar: writing the paper and submission.
Riad Zbibo: article review.
Walid nasreddine: article review.

Guarantor

All authors contributed in the clinical care of the patient and subsequent follow up.

References

- [1] L. Jiang, L.S. Jiang, F.Y. Li, H. Ye, N. Li, N.S. Cheng, et al., Giant submucosal lipoma located in the descending colon: a case report and review of the literature, *World J. Gastroenterol.* 13 (November (42)) (2007) 5664–5667.
- [2] M. Bardaji, F. Roset, R. Camps, F. Sant, M.J. Fernandez-Layos, Symptomatic colonic lipoma: differential diagnosis of large bowel tumors, *Int. J. Colorectal Dis.* 13 (1) (1998) 1–2.
- [3] O. Tascilar, G.K. Cakmak, B.D. Gun, et al., Clinical evaluation of submucosal colonic lipomas: decision making, *World J. Gastroenterol.* 12 (August (31)) (2006) 5075–5077.
- [4] R.A. De Beer, H. Shinya, Colonic lipomas: an endoscopic analysis, *Gastrointest. Endosc.* 22 (1975) 90–91.

- [5] W.F. Worthen 2nd, N. Worthen, D. State, F.M. Hirose, Lipoma of the cecum clinically simulating carcinoma, *Dis. Colon Rectum* 22 (May–June (4)) (1979) 270–273.
- [6] A. Tsiaousidou, E. Chatzitheoklitos, I. Hatzis, M. Alatsakis, A. Katsourakis, Giant transmural lipoma of the sigmoid colon, *Hippokratia* 16 (July (3)) (2012) 278–279.
- [7] P. Coyne, T. Teemul, B. Dent, D. Henderson, R. Crabbe, T. Garud, *Submucosal lipoma* of the large intestine masquerading as a colonic malignancy, *J. Surg. Case Rep.* 4 (February (2)) (2011) 4.
- [8] G. Lazaraki, D. Tragiannidis, P. Xirou, A. Nakos, I. Pilpilidis, I. Katsos, Endoscopic resection of giant lipoma mimicking colonic neoplasm initially presenting with massive haemorrhage: a case report, *Cases J.* 2 (March (10)) (2009) 6462.
- [9] D.E. Böler, B. Baca, C. Uras, Laparoscopic resection of colonic lipomas: when and why? *Am. J. Case Rep.* 14 (July (24)) (2013) 270–275.
- [10] L.A. Dultz, B.W. Ullery, H.H. Sun, T.L. Huston, et al., Ileocecal valve lipoma with refractory hemorrhage, *JSLs* 13 (January–March (1)) (2009) 80.
- [11] R. Mason, J.B. Bristol, V. Petersen, I.D. Lyburn, Education and imaging: gastrointestinal: lipoma induced intussusception of the transverse colon, *J. Gastroenterol. Hepatol.* 25 (June (6)) (2010) 1177.
- [12] P. Katsinelos, G. Chatzimavroudis, C. Zavos, I. Pilpilidis, G. Lazaraki, B. Papaziogas, et al., Cecal lipoma with pseudomalignant features: a case report and review of the literature, *World J. Gastroenterol.* 13 (May 7 (17)) (2007) 2510–2513.
- [13] S. Boyce, Y.P. Khor, A colonic submucosal lipoma presenting with recurrent intestinal obstruction attacks, *BMJ Case Rep.* 2009 (2009), pii: bcr11.2008.1199.
- [14] P. Martin, B. Sklow, D.G. Adler, Large colonic lipoma mimicking colon cancer and causing colonic intussusception, *Dig. Dis. Sci.* 53 (October (10)) (2008) 2826–2827.
- [15] G. Liessi, M. Pavanello, S. Cesari, et al., Large lipomas of the colon: CT and MR findings in three symptomatic cases, *Abdom. Imaging* 21 (March–April (2)) (1996) 150–152.
- [16] S. El-Dika, A. Vahabzadeh, L. Karageorge, A. Kinsey, A large pedunculated lipoma endoscopically resected with the assistance of a detachable nylon endoloop, *Gastroenterol. Hepatol. (N. Y.)* 3 (November (11)) (2007) 880–881.
- [17] C.Y. Kim, D. Bandres, T.L. Tio, S.B. Benjamin, F.H. Al-Kawas, Endoscopic removal of large colonic lipomas, *Gastrointest. Endosc.* 55 (June (7)) (2002) 929–931.
- [18] G.S. Raju, G. Gomez, Endoloop ligation of a large colonic lipoma: a novel technique, *Gastrointest. Endosc.* 62 (December (6)) (2005) 988–990.
- [19] K. Sugimoto, K. Sato, H. Maekawa, M. Sakurada, H. Orita, T. Ito, et al., Unroofing technique for endoscopic resection of a large colonic lipoma, *Case Rep. Gastroenterol.* 6 (May (2)) (2012) 557–562.

Open Access

This article is published Open Access at sciedirect.com. It is distributed under the [IJSCR Supplemental terms and conditions](#), which permits unrestricted non commercial use, distribution, and reproduction in any medium, provided the original authors and source are credited.