

Superficial Medial Collateral Ligament Reattachment During High Tibial Osteotomy: Regulate Tension, Preserve Stability!



Konrad Malinowski, M.D., Ph.D., Aleksandra Sibilska, Adrian Góralczyk, M.D., Robert F. LaPrade, M.D., Ph.D., and Krzysztof Hermanowicz, M.D., Ph.D.

Abstract: High tibial osteotomy (HTO) is a commonly performed surgical procedure. Although it is well-known that the superficial medial collateral ligament (sMCL) should be released during HTO, there is still no agreement on performing its reattachment. Considering the function of the sMCL, after its release during HTO, increased medial joint instability may be expected. We present a technique for sMCL reattachment that prevents medial gapping development and maintains nearly native pressure on the medial compartment of the knee joint by matching the tension on the sMCL to the size of the osteotomy gap. This technique is suitable for any correction angle.

High tibial osteotomy (HTO) is usually applied in patients who have varus deformity and osteoarthritis in the medial compartment of the knee joint.^{1,2} It provides realignment of the mechanical axis of the lower limb and unloading of the affected compartment, thus transferring weight-bearing forces more to the lateral knee compartment.^{3,4} In particular, this procedure is preferred in relatively young and active patients as an alternative to knee arthroplasty.⁵ Although this procedure is not considered a long-term solution, it may deliver better functional levels expected by highly active patients in comparison to other procedures.⁶

There is currently much discussion about the superficial medial collateral ligament (sMCL) and its function after HTO. Per LaPrade et al.,^{7,8} the proximal origin of

the sMCL is located 3.2 mm proximal and 4.8 mm posterior to the medial femoral epicondyle whereas the broad distal attachment of the sMCL is located 61.2 mm distal to the medial joint line and anterior to the posteromedial crest of the tibia. It is well-known that the sMCL is a primary restraint on valgus stress. Some authors have suggested that release of the sMCL without its further reattachment is possible and that this does not affect patient-reported outcomes.^{9,10} Either way, its release, which is inevitable during HTO, may lead to medial instability when it is not addressed after osteotomy. In addition, lack of reattachment of the sMCL after HTO, except that it is a nonanatomic action, may create an open space for the hematoma or displaced gap filling material. The purpose of this article is to present, in detail, a technique for sMCL reattachment that provides proper stability and avoids potential complaints caused by iatrogenic instability or over-tensioning on the medial side in patients after HTO.

Surgical Technique

After induction of spinal anesthesia, the patient is positioned supine with a pneumatic tourniquet on the proximal thigh. The leg is prepared and draped in a sterile fashion.

Diagnostic Arthroscopy

A diagnostic arthroscopy is performed to assess and treat intra-articular lesions. Severe lateral knee compartment and patellofemoral joint pathologies have to be ruled out before performing the HTO.

From Artromedical Orthopaedic Clinic (K.M.), Belchatów, Poland; Clinic of Orthopedics and Pediatric Orthopedics, Medical University of Lodz (A.S.), Lodz, Poland; ORTIM Orthopaedic Clinic (A.G., K.H.), Białystok, Poland; and Twin Cities Orthopedics (R.F.L.), Edina, Minnesota, U.S.A.

The authors report that they have no conflicts of interest in the authorship and publication of this article. Full ICMJE author disclosure forms are available for this article online, as [supplementary material](#).

Received June 8, 2019; accepted July 9, 2019.

Address correspondence to Konrad Malinowski, M.D., Ph.D., Artromedical Orthopaedic Clinic, Chrobrego 24, 97-400 Belchatów, Poland E-mail: malwin8@wp.pl

© 2019 by the Arthroscopy Association of North America. Published by Elsevier. This is an open access article under the CC BY-NC-ND license (<http://creativecommons.org/licenses/by-nc-nd/4.0/>).

2212-6287/19741

<https://doi.org/10.1016/j.eats.2019.07.002>

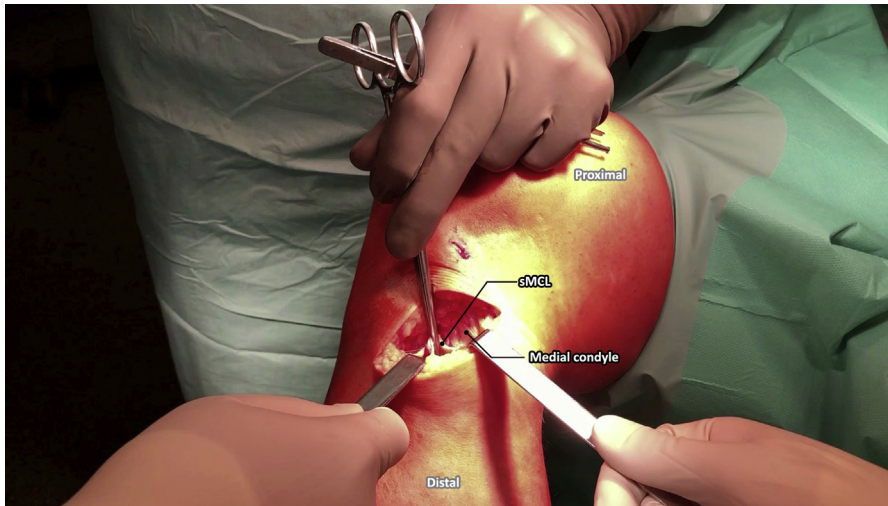


Fig 1. Medial side of the right proximal tibia during high tibial osteotomy. An atraumatic surgical tool is used to elevate the released part of the superficial medial collateral ligament (sMCL) from its distal insertion.

Approach to HTO and sMCL Release Technique

The knee is positioned in 90° of flexion. An oblique skin incision running from the posterosuperior to anteroinferior aspect of the medial side of the knee is performed (Video 1). The incision begins about 2 cm below the medial joint line at the level of the posteromedial corner of the tibial plateau and ends about 3 cm below and 1 cm medial to the tibial tuberosity, running over the pes anserinus. In this way, after subcutaneous soft-tissue dissection is performed, an anteromedial aspect of the tibia and pes anserinus covering the vertical fibers of the sMCL is exposed (Video 1). The course of the sartorius, gracilis, and semitendinosus is determined by palpation. Then, the sartorius fascia is cut, paying attention not to harm the sMCL lying underneath it and gracilis tendon running transversely. After that, blunt dissection of the periosteum anterior to the anterolateral fibers of the sMCL is performed using closed surgical scissors (Aesculap, Tuttlingen, Germany). Then, a straight surgical rasp (Aesculap) and the surgical scissors are used to carefully detach the anterolateral fibers of the sMCL from their distal insertion, leaving the posteromedial fibers attached in their anatomic position (Video 1). The released part of the sMCL is elevated with an atraumatic surgical tool, and all the soft-tissue adhesions of the medial part of the sMCL are removed until the deep part of the medial collateral ligament is exposed (Fig 1). Then, the HTO is performed.

Technique for sMCL Reattachment

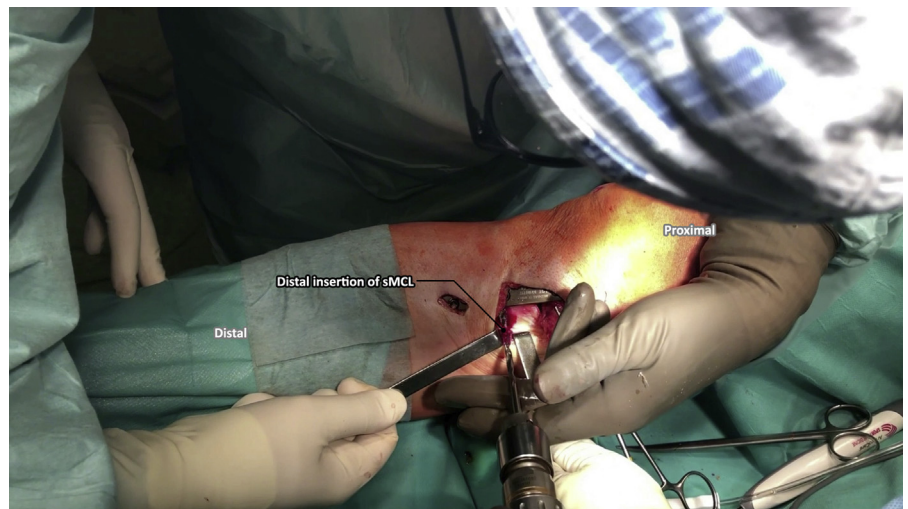When the HTO is completed, the knee is positioned in full extension. Pean forceps are used to elevate the pes anserinus, whereas the surgical blade is used to perform an oblong stab incision underneath it as close as possible to the anatomic position of the distal attachment of the sMCL (Video 1). A 4.5-mm socket in the

cortical bone is created with a drill (Fig 2). The exact point of the socket is chosen based on the size of the osteotomy gap to avoid over-tensioning on the sMCL. What is important is that it lies on the line that is parallel and close to the posterior tibial cortex so that it allows for an appropriate and linear tension on the released sMCL. Then, a double-loaded suture anchor (Super Revo; ConMed, Warsaw, Poland) is placed into the prepared bony bed (Video 1). One end of each strand is passed underneath the pes anserinus with Pean forceps (Fig 3). A free needle is used to place, with passed strands, the Krackow stitches on the anterior and posterior parts of the previously released distal attachment of the sMCL (Video 1). After suturing, the free ends of the strands are moved back underneath the pes anserinus toward the suture anchor with Pean forceps. The proper tension on the sMCL is regulated, and the surgical knots are tied (Fig 4). The sMCL should be tensioned with the knee in extension. This results in full coverage of the posterior part of the osteotomy gap and stabilizes the medial aspect of the knee (Fig 5). If bone grafts are being used, we first suture the distal part of the sMCL and then send the sutures under the pes anserinus, but we wait to make a knots until the osteotomy gap is filled.

Rehabilitation

Because the reattachment is isometric, passive range of motion of 0° to 90° is safe and starts on the first postoperative day. Walking on crutches with touch weight bearing and then gradually increasing partial weight bearing is recommended for 6 to 9 weeks. For the first 4 postoperative weeks, the patient uses a simple straight knee immobilizer only for walking; then, the Quantum brace (Breg, Carlsbad, CA) dedicated to lateral osteoarthritis of the knee is recommended for walking. After the fourth week, the brace is set to 0° to

Fig 2. Medial side of the right proximal tibia during high tibial osteotomy. A 4.5-mm socket in the cortical bone is made to place a double-loaded suture anchor. The exact point of the socket is chosen based on the size of the osteotomy gap to avoid over-tensioning on the superficial medial collateral ligament (sMCL).



90°, and after the sixth week, full active range of motion is allowed. We discontinue bracing gradually after the third month. For the first 6 weeks, quadriceps strengthening exercises, co-contraction exercises, and patella and scar mobilization are performed.

Discussion

Although the effectiveness of the HTO seems to be clear, there are still some debates on the technical details of this procedure to obtain better outcomes.⁹⁻¹¹ It is clear that during HTO, release of the sMCL should be performed because omitting it might not allow for proper osteotomy gap opening and may result in overstress on the medial compartment. Using our method allows better insight into the operative area and, above all, precise sMCL anatomic reattachment afterward.

Currently, much of the discussion focuses on reattachment of the sMCL. This discussion was started in 1985 by Coventry.¹² Since then, there have been many articles supporting and doubting this thesis. Among the authors describing the HTO procedures, some emphasize sMCL repair whereas some do not mention it at all. In addition, some descriptions note only cutting or peeling the sMCL insertion.^{13,14} It is worth noting that to authors cutting or peeling the insertion of the sMCL (primary restraint of valgus stress) alone, this does not provide control of ligament healing or it may cause healing in a nonanatomic position, leading to chronic medial instability.

Studies seem to confirm these presumptions. Van Egmond et al.¹⁰ reported in their cadaveric study that after releasing the sMCL, the mean contact pressure, peak contact pressure, and contact area decreased in the medial compartment. These findings may suggest

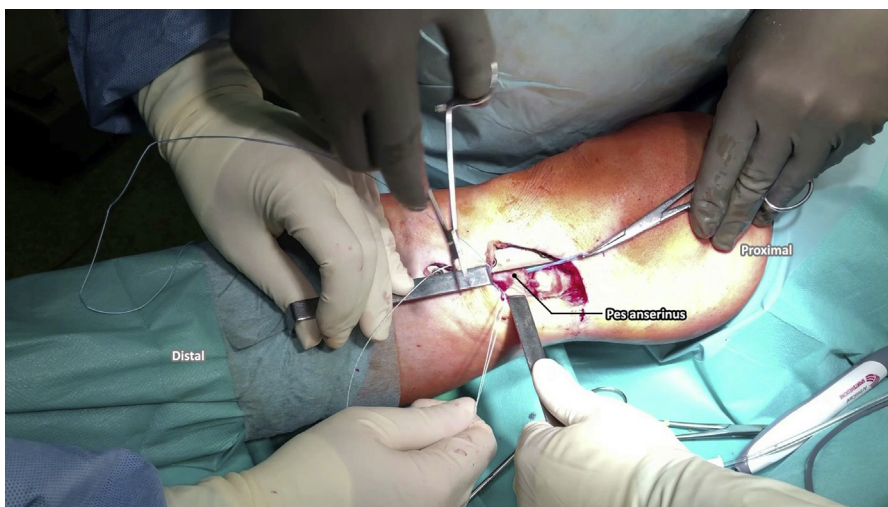


Fig 3. Medial side of the right proximal tibia during high tibial osteotomy. After placement of the double-loaded suture anchor into the prepared bony bed, one end of each strand is passed underneath the pes anserinus.

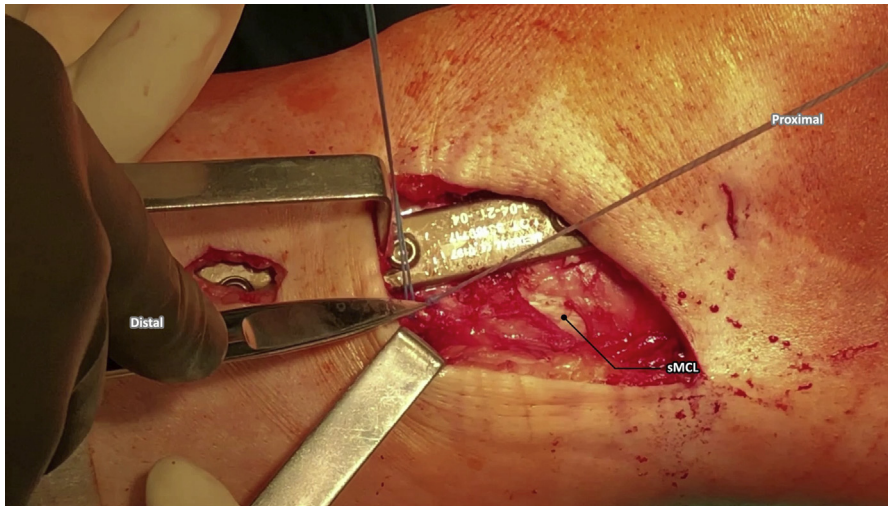


Fig 4. Medial side of the right proximal tibia during high tibial osteotomy. Before tying the surgical knots, we regulated the proper tension on the superficial medial collateral ligament (sMCL).

that it may help to achieve the goal of reducing medial cartilage loading. However, their study also reported a mean increase of 7.9° in valgus laxity, which may have an influence on knee stability after HTO. In our opinion, by anatomic repair of the sMCL, we aim to prevent the occurrence of instability.

On the other hand, Seo et al.⁹ reported that, indeed, release of the sMCL during HTO increased medial joint opening; however, because of the opening of the osteotomy site, medial joint opening decreased again to the pre-release level. In our opinion, these data may vary depending on the degree of correction and the size of the osteotomy gap, and by the sMCL reattachment, we can prevent chronic medial instability in a more predictable way.

To conclude, reattachment allows restoration of the function of the sMCL and thus control of the medial knee opening. One should remember that the distal

attachment of the sMCL is not just a single spot but rather a group of points forming a line along the posterior tibial cortex. Our presented technique is suitable for any correction angle. When the osteotomy is completed, one may adjust the point of the distal sMCL fixation to the size of the osteotomy gap, matching the tension to the existing condition. In the aforementioned studies, the pressure on the medial compartment was often investigated—the key point for us seems to be the close to anatomic and isometric reconstruction of the sMCL. This way, nearly native pressure on the medial compartment can be achieved. Thanks to this, we may prevent both excessive pressure on the medial compartment and medial instability.

We are convinced that by preserving the sMCL at the healing area, we enhance the stability of the whole structure and support the plate itself. Moreover, reattaching the distal part of the sMCL allows coverage of

Fig 5. Medial side of the right proximal tibia during high tibial osteotomy. Fully covered posterior part of osteotomy gap and stable medial aspect of knee. (sMCL, superficial medial collateral ligament.)

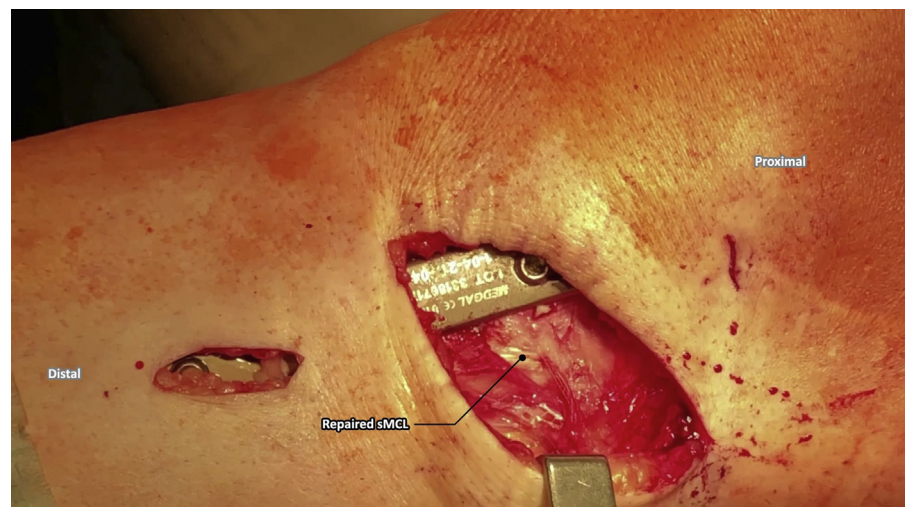


Table 1. Advantages and Disadvantages of sMCL Reattachment During HTO

Advantages
Prevention of excessive pressure on medial compartment
Prevention of medial instability
Control of ligament healing
Coverage of osteotomy gap
Prevention of formation of excessive hematoma
Healing stimulation (additional blood supply)
Disadvantages
Increasing difficulty of HTO procedure
Increasing total duration
Not fully anatomic restoration of distal attachment of sMCL
Only approximated manual tension is used for repaired sMCL distal insertion

HTO, high tibial osteotomy; sMCL, superficial medial collateral ligament.

the bone graft and helps prevent the formation of excessive hematoma out of the osteotomy gap. Besides, it may be an additional source of blood supply and thus healing stimulation.

Our procedure also has some disadvantages. It is surely an additional step in the HTO procedure and thus increases its difficulty and extends the total duration. Another drawback that we discern is the fact that using 1 anchor, we are not able to fully reconstruct the anatomic attachment of the sMCL, because it is more a line than a single point. Therefore, proper tension adjustment is extremely important and can help to reproduce nearly native pressure on the medial compartment of the knee. A brief overview of our technique is presented in Table 1. According to the senior surgeon's (K.M.) experience and on the basis of the aforementioned studies, it seems to us that anatomic reconstruction of the sMCL is reasonable.

References

1. Lee DC, Byun SJ. High tibial osteotomy. *Knee Surg Relat Res* 2012;24:61-69.
2. Prodromos CC, Amendola A, Jakob RP. High tibial osteotomy: Indications, techniques, and postoperative managements. *Instr Course Lect* 2015;64:555-565.
3. Herman BV, Giffin JR. High tibial osteotomy in the ACL-deficient knee with medial compartment osteoarthritis. *J Orthop Traumatol* 2016;17:277-285.
4. Niemeyer P, Stöhr A, Köhne M, Hochrein A. Medial opening wedge high tibial osteotomy. *Oper Orthop Traumatol* 2017;29:294-305.
5. Salzmann GM, Ahrens P, Naal FD, et al. Sporting activity after high tibial osteotomy for the treatment of medial compartment knee osteoarthritis. *Am J Sports Med* 2009;37:312-318.
6. Jones GG, Clarke S, Jaere M, Cobb JP. Failed high tibial osteotomy: A joint preserving alternative to total knee arthroplasty. *Orthop Traumatol Surg Res* 2019;105:85-88.
7. LaPrade RF, Engebretsen AH, Ly TV, Johansen S, Wentorf FA, Engebretsen L. The anatomy of the medial part of the knee. *J Bone Joint Surg Am* 2007;89:2000-2010.
8. LaPrade RF, Wijdicks CA. Development of an anatomic medial knee reconstruction. *Clin Orthop Relat Res* 2012;470:806-814.
9. Seo SS, Kim CW, Seo JH, Kim DH, Lee CR. Does superficial medial collateral ligament release in open-wedge high tibial osteotomy for varus osteoarthritis knees increase valgus laxity? *Am J Sports Med* 2016;44:908-915.
10. Van Egmond N, Hannink G, Janssen D, Vrancken AC, Verdonschot N, van Kampen A. Relaxation of the MCL after an open-wedge high tibial osteotomy results in decreasing contact pressures of the knee over time. *Knee Surg Sports Traumatol Arthrosc* 2017;25:800-807.
11. van Lieshout WAM, Martijn CD, van Ginneken BTJ, van Heerwaarden RJ. Medial collateral ligament laxity in valgus knee deformity before and after medial closing wedge high tibial osteotomy measured with instrumented laxity measurements and patient reported outcome. *J Exp Orthop* 2018;5:49.
12. Coventry B. Upper tibial osteotomy for arthritis. *J Bone Joint Surg Am* 1985;67:1136-1140.
13. Na YG, Lee BK, Hwang DH, Choi ES, Sim JA. Can osteoarthritic patients with mild varus deformity be indicated for high tibial osteotomy? *Knee* 2018;25:856-865.
14. Morris J, Grant A, Kulkarni R, Doma K, Harris A, Hazratwala K. Early results of medial opening wedge high tibial osteotomy using an intraosseous implant with accelerated rehabilitation. *Eur J Orthop Surg Traumatol* 2019;29:147-156.