

An algorithm for managing QT prolongation in coronavirus disease 2019 (COVID-19) patients treated with either chloroquine or hydroxychloroquine in conjunction with azithromycin: Possible benefits of intravenous lidocaine



Raman L. Mitra, MD, PhD, FACC, FHRS, Steven A. Greenstein, MD, Laurence M. Epstein, MD, FACC

From the Northshore University Hospital, Northwell Health, Manhasset, New York.

Introduction

The rapid spread of the coronavirus disease 2019 (COVID-19) pandemic owing to a newly identified coronavirus, SARS-CoV-2, originating in Wuhan, China, has resulted in significant morbidity and mortality around the world. Early reports have shown improved clinical outcome and viral clearance with the use of chloroquine and hydroxychloroquine.^{1,2}

The results of a recent open-label nonrandomized clinical trial by Gautret and colleagues³ suggest that the addition of azithromycin to hydroxychloroquine significantly reduced polymerase chain reaction detection of SARS-CoV-2 in nasopharyngeal samples by 6 days in 6 patients compared to 14 patients treated with hydroxychloroquine alone.³ Patients with baseline prolonged QT intervals were excluded from this study, since both drugs are known to prolong the QT interval, which may increase the risk of torsades de pointes (TdP).

Despite the drugs' QTc-prolonging effects, several reports suggest the risk of TdP is very low when either of these agents is used alone or in combination.^{4,5} Nonetheless, these risks may be higher in critically ill, hospitalized COVID-19 patients with metabolic derangements, with organ failure, and on other medications, increasing the risk of drug-drug interactions. If this combination, however, proves to be life-saving for COVID-19 patients, "managing" the QT interval to allow patients to receive combination therapy will be critical.

KEYWORDS Acquired LQTS; Azithromycin; Chloroquine; COVID-19; Drug toxicity; Flow chart; Hydroxychloroquine; Long QT; Pandemic; Proarrhythmia; Torsades de pointes; Ventricular fibrillation (Heart Rhythm Case Reports 2020;6:244–248)

This research did not receive any specific grant from funding agencies in the public, commercial, or not-for-profit sectors. None of the authors has any conflicts of interest related to the content of this manuscript. **Address reprint requests and correspondence:** Dr Raman L. Mitra, Northshore University Hospital, Northwell Health, 300 Community Drive, Manhasset, NY 11030. E-mail address: rmitra1@northwell.edu.

KEY TEACHING POINTS

- The combination of azithromycin and chloroquine/hydroxychloroquine has been shown in a small number of COVID-19 patients to have effective virucidal potency.
- Concerns of QT prolongation and increased risks of torsades de pointes (TdP) with this combination have been raised, since each agent can individually prolong the QT interval, and patients with QT prolongation were excluded from receiving this therapy.
- Combination therapy with azithromycin and chloroquine has previously been found to be safe in the treatment of resistant malaria, without reports of syncope or TdP.
- The addition of lidocaine or mexiletine may allow this type of combination therapy even in patients who have a prolonged QT interval.
- We developed and provided a flow chart to manage the risk of QT prolongation and TdP while treating these patients in the hospital with combination therapy.

We describe an algorithm that may help manage this combination therapy to mitigate the risk of TdP and describe the possible use of intravenous lidocaine to permit combination therapy that might not otherwise be possible.

Case report

A 66-year-old woman with a past medical history of rheumatoid arthritis, pulmonary fibrosis, and asthma, on chronic methotrexate and oral and inhaled steroids, presented on

March 16, 2020 with fever and cough after a 2-week course of sinus and upper respiratory tract symptoms initially treated with doxycycline, followed by levofloxacin as an outpatient. Owing to lack of improvement, she presented to the emergency room and was found to be hypoxic. Computed tomography showed widespread ground-glass opacities as well as honeycombing of the right lung (Figure 1). COVID-19 was suspected and testing was eventually positive. Within 48 hours she developed profound respiratory failure and required intubation. She also required adrenergic support with norepinephrine. She was started on intravenous azithromycin on March 18. The decision was made to start hydroxychloroquine on March 21; however, it was stopped after 1 dose owing to a QTc of 620 ms with a notched broad T wave (Figure 2A). No ventricular ectopy was present. Serum potassium and magnesium were 4.4 mM and 2.9 mg/dL, respectively. Electrophysiology consultation recommended 100 mg intravenous lidocaine followed by a repeat 12-lead electrocardiogram. This revealed a shortening of the QTc to 550 ms (Figure 2B). It was recommended to restart hydroxychloroquine and begin a lidocaine infusion. The patient was able to complete the course of hydroxychloroquine without an arrhythmic event. Despite receiving a full course of hydroxychloroquine, she remained ventilator dependent and died owing to progressive metabolic acidosis and multiorgan system failure on March 25. By the time hydroxychloroquine was first initiated, she had already been intubated for 72 hours and was in severe respiratory failure. Owing to several similar consults in COVID-19 patients with borderline or increased QTc intervals, we developed a flow chart that addresses QT interval management in order to help clinicians taking care of COVID-19 patients who require chloroquine or hydroxychloroquine with or without azithromycin (Figure 3).

Discussion

Owing to the current COVID-19 pandemic, there is great interest in using chloroquine or hydroxychloroquine in combination with azithromycin to improve the virucidal efficacy against SARS-CoV-2. This is tempered with concerns of increased risks of QT prolongation and development of TdP, which may be life threatening.

Though it is generally recommended to avoid any pharmacological agent that prolongs the QTc >500 ms in the outpatient setting, the benefit-risk ratio in a monitored intensive care unit setting may allow for short-term administration of lifesaving medications that exceed this limit.

Although at first glance the combination of chloroquine with azithromycin may seem risky, pharmacokinetic studies have also demonstrated no significant interaction between the 2 agents,⁶ and this combination has been used in previous outpatient studies to treat resistant malaria, with no reports of syncope or sudden death.^{4,5} Similar data are not available for the use of hydroxychloroquine and azithromycin in combination.

An observational nonrandomized clinical study in 2012 that compared the risks of cardiovascular death in patients

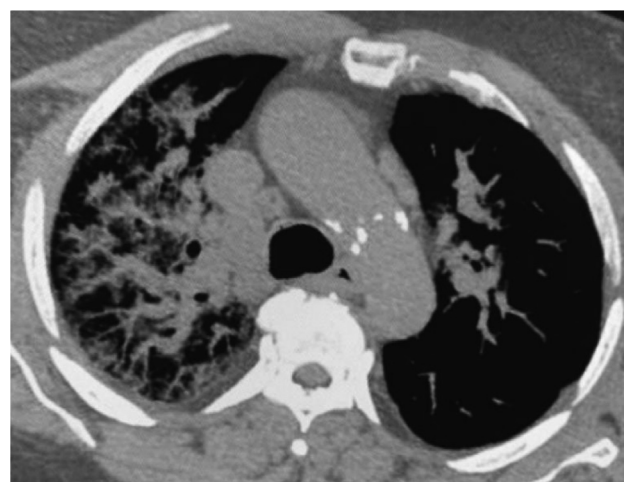


Figure 1 Chest computed tomography of patient on March 16, 2020, showing extensive right lung infiltrates.

treated with the antibacterial drugs azithromycin, amoxicillin, ciprofloxacin, and levofloxacin vs no antibacterial drug reported an increase in cardiovascular deaths, and the risk of death from any cause, in persons treated with a 5-day course of azithromycin compared to persons treated with amoxicillin, ciprofloxacin, or no drug.⁷

This study led the U.S. Food and Drug Administration to issue a public warning in 2013 that azithromycin can cause abnormal changes in the electrical activity of the heart that may lead to a potentially fatal irregular heart rhythm.⁸ Those at higher risk included individuals with known risk factors such as existing QT-interval prolongation, low blood levels of potassium or magnesium, a slower-than-normal heart rate, heart failure or ischemia, and the use of antiarrhythmic drugs. The deaths reported in this study, however, occurred during the 5 days of therapy, after which the cardiovascular death rate was no different from the other groups.⁹ This risk would clearly be less for an inpatient cohort on telemetry and not as relevant for COVID-19 patients being treated in the hospital.

The low risks of azithromycin are also supported by real-world data, which reveal a very low incidence of sudden death or syncope.^{10,11} The risks were associated with patients above the age of 60 years, concomitant use of other QT-prolonging drugs, cardiovascular disease, and female sex.¹²

Most drugs that lead to acquired long QT syndrome (LQTS) and TdP do so by blocking the hERG potassium channel.¹³ Drugs such as lidocaine and mexiletine, which can block the I_{Na-L} channel, and thereby the late sodium current, have been shown to slightly shorten the QT interval and suppress TdP in acquired LQTS.¹⁴ Mexiletine has been successfully used to control TdP in patients with acquired LQTS who continued to have TdP despite withdrawal of QT-prolonging medications, electrolyte correction, and magnesium infusions.¹⁵ Treatment with mexiletine slightly shortened the QT interval, by approximately 15%

We felt that this property would make lidocaine an ideal adjunctive agent in the intensive care unit to allow

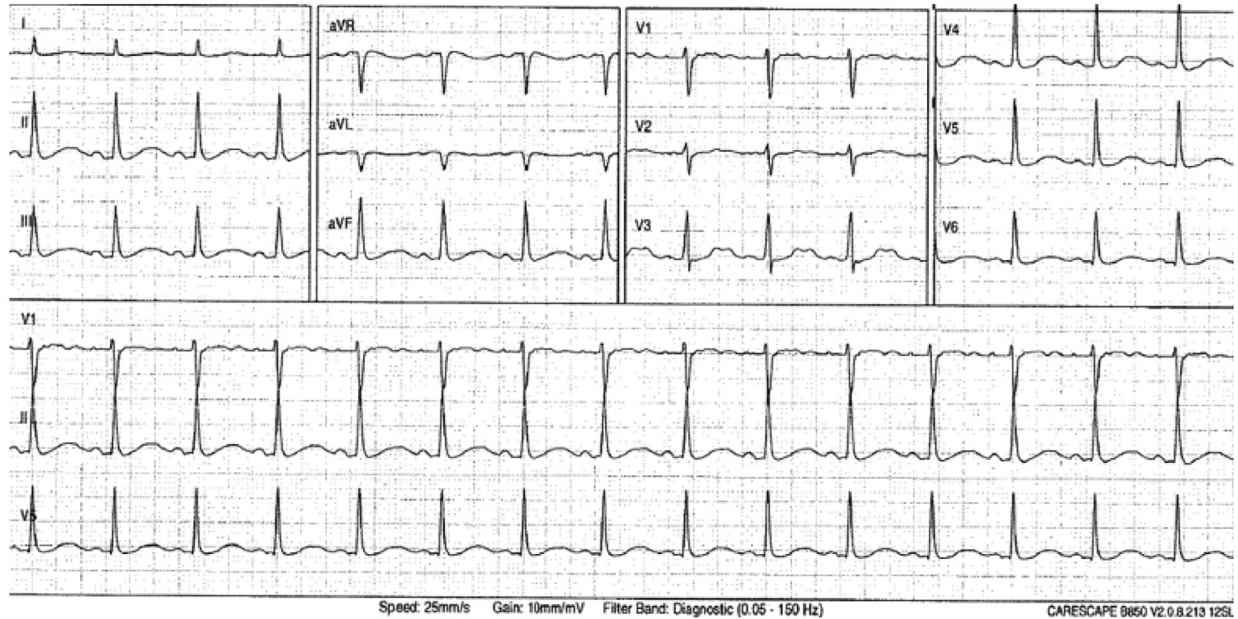
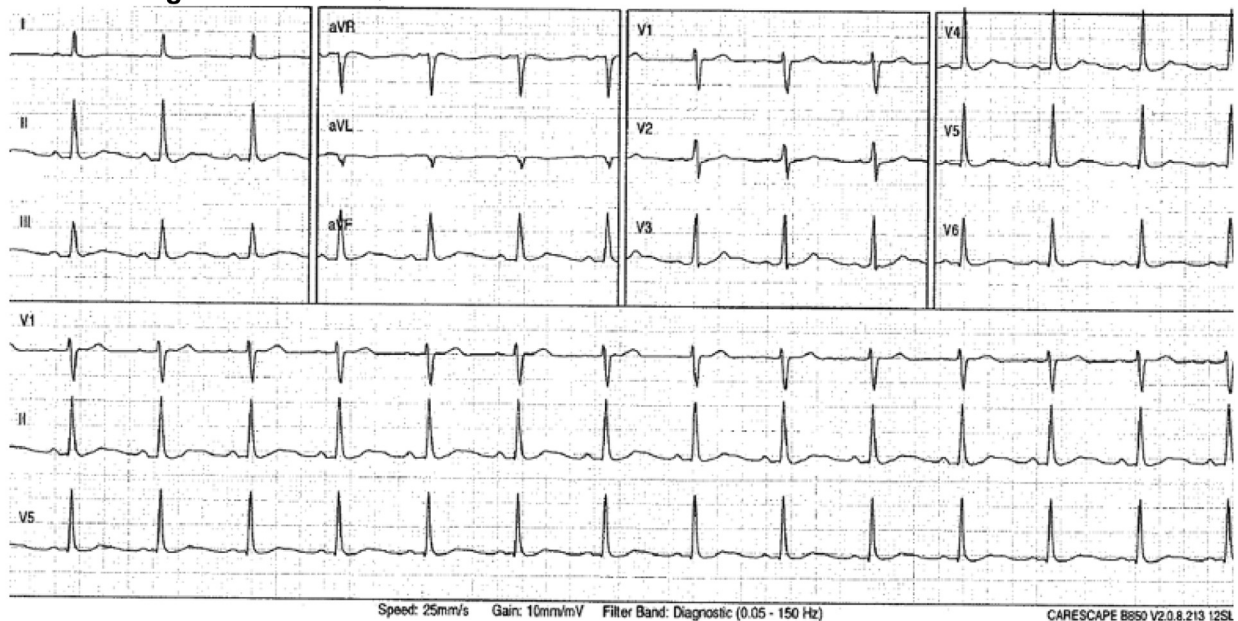
A Pre lidocaine: QTc 620 ms**B Post 100 mg IV lidocaine: QTc 550 ms**

Figure 2 A: Electrocardiogram (ECG) showing prolonged QTc of 620 ms using Bazett's formula after 1 dose of hydroxychloroquine in a patient on azithromycin. B: ECG 30 minutes after administration of 100 mg intravenous (IV) lidocaine with reduction of QTc to 550 ms.

COVID-19 patients to receive short-term dual therapy with azithromycin and chloroquine/hydroxychloroquine for acquired LQTS. Known therapies to mitigate TdP, such as maintaining potassium and magnesium levels and heart rates >70 beats per minute, are incorporated into our flow chart. Another option may be to use mexiletine in patients able to take oral medications. Unfortunately, this patient died despite receiving therapy. Hydroxychloroquine was started late into her course (4 days after presentation and 3 days after intubation); therefore, it is uncertain whether she would have survived had hydroxychloroquine been started earlier. Her

previous history of rheumatoid arthritis, pulmonary fibrosis, and asthma placed her at a higher risk for mortality as well.

Conclusion

In conclusion, although the theoretical risk of acquired LQTS and TdP is present with chloroquine, hydroxychloroquine, or azithromycin used alone or in combination, previous reports of combined treatment in malaria patients suggest that the risk is very low. In COVID-19 patients who are hospitalized, however, there may be an increased risk of QT prolongation

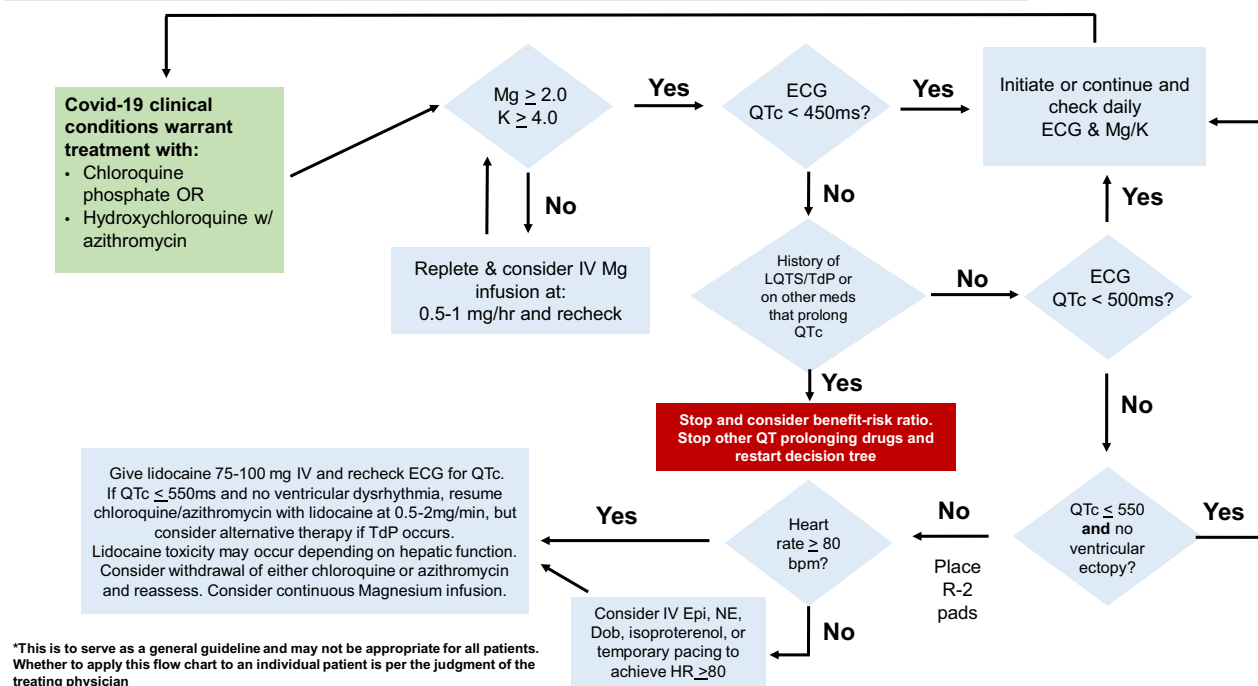
QTc Flow chart to minimize TdP in COVID-19 inpatients on Chloroquine/Azithromycin*

Figure 3 Flow chart to manage effects on QTc with chloroquine, hydroxychloroquine with azithromycin. bpm = beats per minute; Dob = dobutamine; ECG = electrocardiogram; Epi = epinephrine; IV = intravenous; K = serum potassium; LQTS = long QT syndrome; Mg = serum magnesium; NE = norepinephrine; TdP = torsades de pointes.

and TdP owing to previous or concurrent medications, age, sex, or metabolic derangements (pH, hypoxia, electrolyte abnormalities, and multiorgan system failure), as well as previous cardiovascular disease. Recent reports suggest that direct viral- or autoimmune-induced myocardial injury may also occur in COVID-19 patients.¹⁶⁻¹⁸

Certainly, the use of combination therapy with azithromycin and chloroquine or hydroxychloroquine in patients with congenital or acquired LQTS must be carefully weighed against the risks. The use of late sodium channel-blocking drugs like lidocaine or mexiletine and careful attention to serum electrolytes, heart rate, and monitoring of QTc intervals may allow administration of a full course of these drugs, even in patients with a prolonged QT interval. Further data will be required to determine if this approach can be safely applied to the majority of COVID-19 patients in need of such therapy.

References

- Colson P, Rolain JM, Lagier JC, Brouqui P, Raoult D. Chloroquine and hydroxychloroquine as available weapons to fight COVID-19 [published online ahead of print March 4, 2020]. *Int J Antimicrob Agents*. <https://doi.org/10.1016/j.ijantimicag.2020.105932>.
- Gao J, Tian Z, Breakthrough Yang X. Chloroquine phosphate has shown apparent efficacy in treatment of COVID-19 associated pneumonia in clinical studies. *Bio-sci Trends* 2020;14:72-73.
- Gautret P, Lagier JC, Parola P, et al. Hydroxychloroquine and azithromycin as a treatment of COVID-19: results of an open-label non-randomized clinical trial [published online ahead of print March 20, 2020]. *Int J Antimicrob Agents*. <https://doi.org/10.1016/j.ijantimicag.2020.105949>.
- Dunne MW, Singh N, Shukla M, et al. A multicenter study of azithromycin, alone and in combination with chloroquine, for the treatment of acute uncomplicated *Plasmodium falciparum* malaria in India. *J Infect Dis* 2005; 191:1582-1588.
- Chico RW, Chandramohan D. Azithromycin plus chloroquine: combination therapy for protection against malaria and sexually transmitted infections in pregnancy. *Expert Opin Drug Metab Toxicol* 2011;7:1153-1167.
- Cook JA, Randitis EJ, Bramson CR, Wesche DL. Lack of a pharmacokinetic interaction between azithromycin and chloroquine. *Am J Trop Med Hyg* 2006; 74:407-412.
- Ray WA, Murray KT, Hall K, Arbogast P, Stein CM. Azithromycin and the risk of cardiovascular death. *N Engl J Med* 2012;366:1881-1890.
- FDA drug safety communication: azithromycin (Zithromax or Zmax) and the risk of potentially fatal heart rhythms. U.S. Food and Drug Administration, <https://www.fda.gov/drugs/drug-safety-and-availability/fda-drug-safety-communication-azithromycin-zithromax-or-zmax-and-risk-potentially-fatal-heart>. Accessed March 12, 2013.
- Mosholder AD, Mathew J, Alexander JJ, Smith H, Nambiar S. Cardiovascular risks with azithromycin and other antibacterial drugs. *N Engl J Med* 2013; 368:1665-1668.
- Khosropour CM, Capizzi JD, Schafer SD, Kent JB, Dombrowski JC, Golden MR. Lack of association between azithromycin and death from cardiovascular cause. *N Engl J Med* 2014;370:1961-1962.
- Almalki ZS, Guo JJ. Cardiovascular events and safety outcomes associated with azithromycin therapy: a meta-analysis of randomized controlled trials. *Am Health Drug Benefits* 2014;7:318-326.
- Hancox JC, Hasnain M, Vieweg WV, Breden Crouse EL, Baranchuk A. Azithromycin, cardiovascular risks, QTc interval prolongation, torsade de pointes, and regulatory issues: a narrative review based on the study of case reports. *Ther Adv Infect Dis* 2013;1:155-165.
- Trudeau MC, Warmke JW, Ganetzky B, Robertson GA. HERG, a human inward rectifier in the voltage-gated potassium channel family. *Science* 1995;269:92-95.
- Johannessen L, Vicente J, Mason JW, Erato C, et al. Late sodium current block for drug-induced long QT syndrome: results from a prospective clinical trial. *Clin Pharmacol Ther* 2016;99:214-223.
- Badri M, Patel A, Patel C, et al. Mexiletine prevents recurrent torsades de pointes in acquired long QT syndrome refractory to conventional measures. *J Am Coll Cardiol* 2015;1:315-322.
- Hu H, Ma F, Wei X, Fang Y. Coronavirus fulminant myocarditis saved with glucocorticoid and human immunoglobulin [published online ahead of print March 16, 2020]. *Eur Heart J*. <https://doi.org/10.1093/eurheartj/ehaa190>.

17. Zeng JH, Liu YX, Yuan J, et al. First case of COVID-19 infection with fulminant myocarditis complication: case report and insights. Preprints 2020; 2020030180, <https://doi.org/10.20944/preprints202003.0180.v1>.
18. Clerkin KJ, Fried JA, Raikhelkar J, et al. Coronavirus Disease 2019 (COVID-19) and cardiovascular disease [published online ahead of print March 21, 2020]. *Circulation*, <https://www.ahajournals.org/doi/pdf/10.1161/CIRCULATIONAHA.120.046941>.