



Case report

Splenic abscess secondary to COVID-19 infection – A case report

Nicholas Cairl^{a,*}, Victoria Sharp^b^a Department of Surgery, Trinity Health Ann Arbor, 5301 McAuley Dr, Ypsilanti, MI 48197, United States of America^b Trinity Health IHA Medical Group, Trauma & Surgical Critical Care, Trinity Health Ann Arbor, 5301 McAuley Dr, Ypsilanti, MI 48197, United States of America

ARTICLE INFO

Keywords:

COVID-19

Abscess

Surgery

Case report

Interventional radiology

ABSTRACT

Introduction and importance: The sequelae of COVID-19 infection are largely unknown. There are reports of abscess formation in patients with recent COVID-19 infection, likely due to the formation of microthrombi secondary to endothelial damage. This case report describes an unvaccinated patient who presented with a large splenic abscess after recent symptomatic COVID-19 infection.

Case presentation: A man in his forties with recent symptomatic COVID-19 infection presented to the emergency room with worsening left-sided abdominal and flank pain associated with subjective fever and chills. On physical exam he was significantly tender to palpation in the left hemi-abdomen with a palpable left upper quadrant mass. CT scan demonstrated a large intra-splenic fluid collection. He underwent drainage by interventional radiology with return of 400 cm³ of purulent material, which grew *Staphylococcus aureus*. Blood cultures were negative and transesophageal echocardiogram revealed no endocarditis. Further workup by infectious disease revealed no identifiable source of the splenic abscess. The patient was treated with intravenous antibiotics and clinically improved without surgical intervention.

Clinical discussion: Several studies have shown that SARS-CoV-2, the virus that causes COVID-19, injures the endothelium resulting in endothelial dysfunction. This dysfunction creates a prothrombotic state leading to the formation of thrombi in both large and small vessels. It has been suggested that microthrombi may contribute to the formation of abscesses.

Conclusion: In the absence of other etiologies despite a thorough workup, it is believed that this patient's recent COVID-19 infection led to the formation of microthrombi within his splenic vasculature allowing for abscess formation.

1. Introduction

The sequelae of COVID-19 infection are largely unknown. There are reports of abscess formation in patients with recent COVID-19 infection, likely due to the formation of microthrombi secondary to endothelial damage. This case report describes an unvaccinated patient who presented with a large splenic abscess after recovering from a symptomatic COVID-19 infection. Microthrombi within his splenic arterioles are believed to have caused his splenic abscess. Given COVID-19's continued prevalence within communities, it is important to recognize this new etiology of splenic abscess formation. This case has been reported in line with the SCARE 2020 criteria for case reports [1].

2. Case presentation

A man in his forties with a history of obstructive sleep apnea (OSA),

asthma, nephrolithiasis and recent COVID-19 infection presented to the emergency department with worsening left-sided abdominal and flank pain associated with subjective fever and chills. He denied prior surgeries and took no medications. Family history was significant for hypertension in his mother. He denied tobacco and recreational drug use. He reported he consumed two standard alcoholic drinks weekly. Upon presentation he had a temperature of 37.5 °C and was tachycardic to the 130 s. On physical exam he was tender to palpation in the left hemi-abdomen and there was a palpable, tender mass in the left upper quadrant. Labs were significant for a leukocytosis of 21.4 and platelet count of 1198. He denied recent travel, trauma, and intravenous drug use. He tested positive for COVID-19 several weeks prior to presentation and was symptomatic with myalgias, cough, and shortness of breath. He was unvaccinated against COVID-19.

Blood cultures were obtained in the emergency department. CT chest, abdomen and pelvis demonstrated mixed ground-glass interstitial

* Corresponding author.

E-mail address: nicholas.cairl001@trinity-health.org (N. Cairl).<https://doi.org/10.1016/j.ijscr.2022.107807>

Received 27 September 2022; Received in revised form 25 November 2022; Accepted 27 November 2022

2210-2612/© 2022 The Authors. Published by Elsevier Ltd on behalf of IJS Publishing Group Ltd. This is an open access article under the CC BY-NC-ND license (<http://creativecommons.org/licenses/by-nc-nd/4.0/>).

opacities in both lungs consistent with resolving sequela of recent viral pneumonia and a $19 \times 15 \times 20$ cm cystic structure in the left upper quadrant with mild surrounding inflammation and edema (Figs. 1 and 2). Of note, a CT scan from several months prior showed a normal spleen. This mass was concerning for an evolving subcapsular hematoma, splenic cyst, or splenic abscess. Interventional radiology was consulted and a CT-guided 10.2 Fr drain was placed with return of 400 cm³ of tan purulent material (Fig. 3). This material was sent for gram stain and culture. Transesophageal echocardiogram was completed and showed no evidence of endocarditis. Blood cultures eventually grew no organisms. COVID-19 antibodies were detected, confirming prior infection given the patient's unvaccinated status.

The patient was initially started on broad-spectrum antibiotics including ceftriaxone, metronidazole, and vancomycin. He was admitted to the medicine service with infectious disease consultation. General surgery was consulted; however, given the patient's clinical improvement, splenectomy was not recommended. Cultures subsequently grew *Staphylococcus aureus* and he was transitioned to cefazolin monotherapy. His leukocytosis resolved and a PICC line was inserted in anticipation of a prolonged antibiotic course. He was discharged with his drain in place and a 4-week course of cefazolin.

Due to continued drain output, his antibiotic course was extended by 2 weeks. Approximately 6 weeks after drain placement his output had decreased to less than 10 cm³ for several days. He underwent a drain study with radiology that demonstrated collapse of his abscess cavity and his drain was removed (Fig. 4). At a recent follow-up appointment roughly 2.5 months after initial presentation, the patient was afebrile with no signs of infection.

3. Clinical discussion

Several studies have shown that SARS-CoV-2, the virus that causes COVID-19, injures the endothelium, resulting in endothelial dysfunction. This creates a pro-thrombotic state leading to the formation of thrombi in both large and small vessels. It has been suggested that microthrombi may contribute to the development of acute respiratory distress syndrome (ARDS) as well as dysfunction in other organs, such as the heart and brain [2,3].

There have been reports of abscess formation in patients with recent COVID-19 infection. Al Zarooni et al. published a case series in which three patients with COVID-19 developed splenic abscesses without other

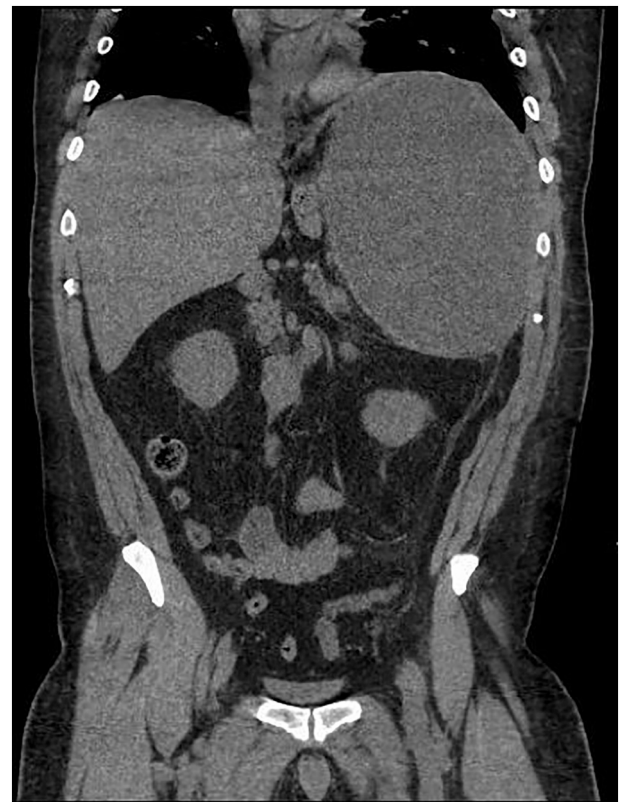

Fig. 2. Coronal view of large uniloculated cystic structure within the spleen.

obvious etiologies [4]. Liemarto et al. describe a patient presenting with multiple necrotic liver abscesses believed to be secondary to his recent COVID-19 pneumonia [5]. The proposed mechanism by which these abscesses form involves microthrombi within the vasculature that allow for bacteria to grow and form an abscess.

Splenic abscesses are typically seen in the context of bacteremia and occur in up to 5 % of patients with infective endocarditis; however, they can also be seen post-procedurally following splenic artery embolization or after blunt trauma to the abdomen. A variety of parasitic infections are also associated with splenic abscesses. Splenic abscesses are uncommon and have an estimated incidence between 0.07 and 0.2 %. Two thirds of patients are found to have a single abscess with the remaining one third having multiple abscesses [6].

A triad of fever, left upper quadrant abdominal pain, and leukocytosis is associated with splenic abscesses; however, it is reportedly only present in one third of cases [6]. In a single-institution review of thirty patients with pyogenic splenic abscesses, Ng et al. report the presence of this triad in the majority of their patients. Furthermore, this triad, in combination with certain imaging findings including splenic fluid collection, splenic cystic lesions, gas within the spleen, or progressive enlargement of a splenic lesion, had a rate of diagnosis for splenic abscess of 86.7 % [7]. Among imaging modalities, computed tomography (CT) is considered the gold standard for diagnosis of splenic abscesses [6].

Once a splenic abscess has been diagnosed, treatment should be initiated with broad-spectrum intravenous antibiotics. Blood cultures may be used to guide antibiotic selection; however, aspirate from the abscess should be sent for bacterial culture and ultimately guide antibiotic therapy [8]. Traditionally, splenectomy has been the standard of care for splenic abscesses, though, given the spleen's important immunologic function, its removal is associated with risk of overwhelming post-splenectomy infection (OPSI). Recently, percutaneous drainage has become the favored initial intervention for splenic abscesses. One meta-analysis of splenectomy versus percutaneous drainage for splenic

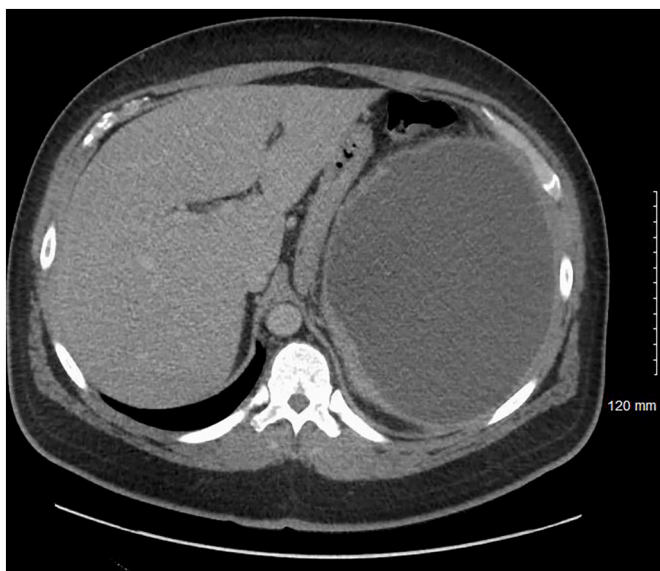

Fig. 1. Axial imaging demonstrating large uniloculated cystic structure within the spleen.

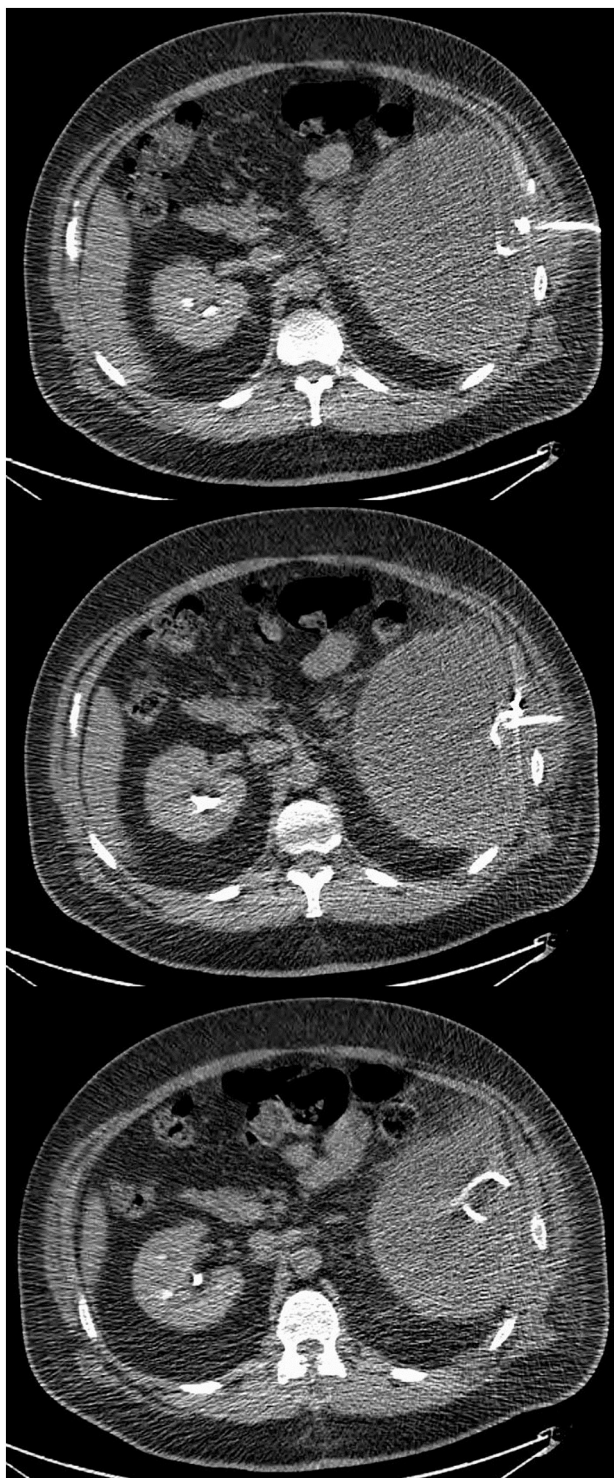

Fig. 3. Pigtail catheter placement by interventional radiology.

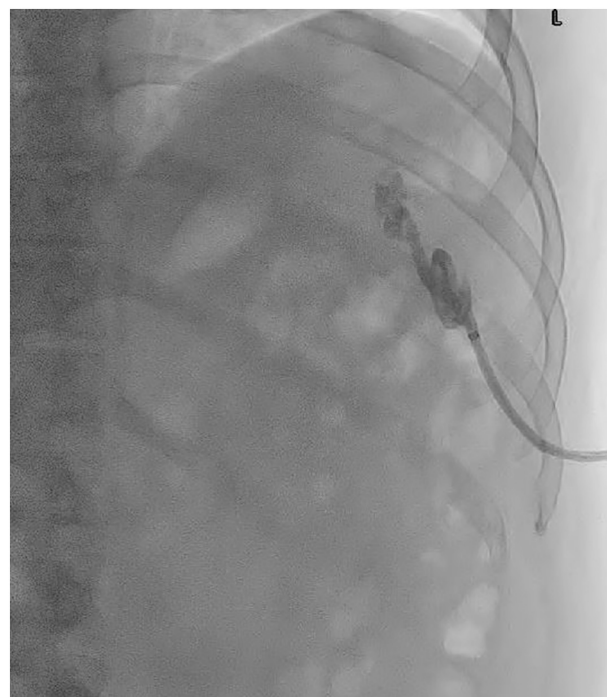


Fig. 4. Drain study demonstrating collapse of abscess cavity.

abscesses shows a complication rate of 26 % and 10 %, respectively [9]. Although not significant, this trend towards fewer complications with percutaneous drainage nonetheless gives credence to splenic preservation. With percutaneous drainage, the patient both avoids a major operation and maintains the immunologic function of their spleen.

The concept of splenic preservation has become more popular, especially in the trauma literature. The use of splenic artery embolization has increased and become the first-line treatment for splenic injuries in hemodynamically stable trauma patients [10]. Splenic artery embolization preserves the spleen's immunologic function while

preventing further hemorrhage [11]. Splenic preservation is even more important in children, as the risk of OPSI is greater [12]. In the pediatric population, in cases of trauma, splenic abscess, or congenital abnormalities such as wandering spleen, splenic preservation should be attempted prior to splenectomy [13–15]. In both adult and pediatric patients who ultimately require splenectomy, patients should receive vaccinations against encapsulated organisms including *H. influenza* type b, pneumococci, meningococci, and influenza. Furthermore, asplenic patients who develop fever should be treated with empiric antibiotics given the risk of rapid sepsis and possible death [16].

4. Conclusion

In the absence of other etiologies despite a thorough workup, it is believed that this patient's recent COVID-19 infection led to the formation of microthrombi within his splenic vasculature allowing for abscess formation. He was successfully treated with intravenous antibiotics and spleen-preserving percutaneous drainage. Physicians should be aware of this etiology of abscess given the continued presence of COVID-19 in our communities.

Sources of funding

None.

Ethical approval

Not applicable.

Consent

Written informed consent was obtained from the patient for publication of this case report and accompanying images. A copy of the written consent is available for review by the Editor-in-Chief of this journal on request.

Author contribution

The authors contributed equally to this case report.

Research registration

Not applicable.

Guarantor

Nicholas Cairl.

Provenance and peer review

Not commissioned, externally peer-reviewed.

Declaration of competing interest

None.

References

- [1] R.A. Agha, T. Franchi, C. Sohrabi, G. Mathew, for the SCARE Group, The SCARE 2020 guideline: updating consensus Surgical CAse REport (SCARE) guidelines, *Int. J. Surg.* 84 (2020) 226–230.
- [2] M.P. Nägele, B. Haubner, F.C. Tanner, F. Ruschitzka, A.J. Flammer, Endothelial dysfunction in COVID-19: current findings and therapeutic implications, *Atherosclerosis* 314 (2020 Dec) 58–62.
- [3] A. Bonaventura, A. Vecchié, L. Dagna, K. Martinod, D.L. Dixon, B.W. Van Tassel, et al., Endothelial dysfunction and immunothrombosis as key pathogenic mechanisms in COVID-19, *Nat. Rev. Immunol.* 21 (5) (2021 May) 319–329.
- [4] N. AlZarooni, A. AlBaroudi, L. AlOzaibi, O. AlZoabi, Splenic abscess as a possible sequela of COVID-19: a case series, *Ann. Saudi Med.* 41 (5) (2021 Sep) 307–311.
- [5] A.K. Liemarto, B.P. Budiono, M.A. Chionardes, I. Oliviera, A. Rahmasiwi, Liver abscess with necrosis in post COVID-19: a case report, *Ann. Med. Surg. (Lond.)* 72 (2021 Dec), 103107.
- [6] S. Lotfollahzadeh, G. Mathew, M.R. Zemaitis, Splenic abscess. [Updated 2022 Jun 3], Jan-. Available from: in: StatPearls [Internet], StatPearls Publishing, Treasure Island (FL), 2022 <https://www.ncbi.nlm.nih.gov/books/NBK519546/>.
- [7] K.K. Ng, T.Y. Lee, Y.L. Wan, C.F. Tan, K.W. Lui, Y.C. Cheung, Y.F. Cheng, Splenic abscess: diagnosis and management, *Hepato-Gastroenterology* 49 (44) (2002) 567–571. PMID: 11995499.
- [8] I. Brook, E.H. Frazier, Microbiology of liver and spleen abscesses, *J. Med. Microbiol.* 47 (1998) 1075–1080, <https://doi.org/10.1099/00222615-47-12-1075>.
- [9] B. Gutama, J.K. Wothe, M. Xiao, D. Hackman, H. Chu, J. Rickard, Splenectomy versus imaging-guided percutaneous drainage for splenic abscess: a systematic review and meta-analysis, *Surg. Infect.* 23 (5) (2022 Jun) 417–429, <https://doi.org/10.1089/sur.2022.072>. Epub 2022 May 24. PMID: 35612434; PMCID: PMC9208856.
- [10] J.M. Haan, G.V. Bochicchio, N. Kramer, T.M. Scalea, Nonoperative management of blunt splenic injury: a 5-year experience, *J. Trauma* 58 (3) (2005 Mar) 492–498, <https://doi.org/10.1097/01.ta.0000154575.49388.74>. PMID: 15761342.
- [11] J. Skattum, P.A. Naess, C. Gaarder, Non-operative management and immune function after splenic injury, *Br. J. Surg.* 99 (Suppl 1) (2012 Jan) 59–65, <https://doi.org/10.1002/bjgs.7764>. PMID: 22441857.
- [12] K. Hansen, D.B. Singer, Asplenic-hyposplenic overwhelming sepsis: postsplenectomy sepsis revisited, *Pediatr. Dev. Pathol.* 4 (2) (2001) 105–121, <https://doi.org/10.1007/s100240010145>. PMID: 11178626.
- [13] S. Bairdain, H.J. Litman, M. Troy, M. McMahon, H. Almodovar, D. Zurakowski, D. P. Mooney, Twenty-years of splenic preservation at a level 1 pediatric trauma center, *J. Pediatr. Surg.* 50 (5) (2015 May) 864–868, <https://doi.org/10.1016/j.jpedsurg.2014.08.022>. Epub 2014 Oct 1 PMID: 25783335.
- [14] A.V. Faruque, S.H. Qazi, M. Arshad, N. Anwar, Isolated splenic abscess in children, role of splenic preservation, *Pediatr. Surg. Int.* 29 (8) (2013 Aug) 787–790, <https://doi.org/10.1007/s00383-013-3336-2>. Epub 2013 Jun 28 PMID: 23811935.
- [15] H. Taher, M. Abdellatif, M. Tarek, G. El Tagy, Torsion of wandering spleen in an infant associated with hamartomatous vascular malformation, *J Pediatr Surg Case Rep* 40 (2019) 13–16, <https://doi.org/10.1016/j.epsc.2018.10.001>.
- [16] L.G. Rubin, W. Schaffner, Clinical practice. Care of the asplenic patient, *N. Engl. J. Med.* 371 (4) (2014 Jul 24) 349–356, <https://doi.org/10.1056/NEJMcp1314291>. PMID: 25054718.