

Conjunctival Rhinosporidiosis in an Ethiopian Child: A Case Report

Tewodros Wubshet Desta ¹, Abdo Kedir ²

¹Department of Pathology, Dire Dawa University, Dire Dawa, Ethiopia; ²Department of Pathology, Jimma University Medical Center, Jimma, Ethiopia

Correspondence: Tewodros Wubshet Desta, Department of Pathology, Dire Dawa University, Po Box 1362, Dire Dawa, Ethiopia, Tel +251-931262484, Fax +251-251127971, Email theddo04@gmail.com

Background: Rhinosporidiosis is a chronic infectious disease caused by an infection with the sporulating bacterium *Rhinosporidium seeberi*. It primarily affects the nose and nasopharynx mucous membranes, but it can also involve the conjunctiva. The most common presentation of ocular rhinosporidiosis is a polypoid mass in the palpebral conjunctiva. It affects people of all ages and genders and is found in few Asian countries. Conjunctival lesions are uncommon, and no previous case from Ethiopia has been documented to the authors' knowledge.

Case Presentation: A 12-year-old boy with a fleshy pedunculated conjunctival mass was brought to Jimma University Medical Center with a 1-month history of foreign body sensation. The patient was diagnosed with Pedunculated Squamous Cell Papilloma and had an excisional biopsy of the lesion. The mass was found to be a hyperplastic polypoid lesion with numerous globular cysts within the conjunctival submucosa, surrounded by a heavy inflammatory infiltrate of lymphocytes, plasma cells, and neutrophils, as well as large thick-walled sporangia with numerous endospores on microscopic sections. Conjunctival Rhinosporidiosis was diagnosed histopathologically.

Conclusion: In terms of clinical appearance, conjunctival Rhinosporidiosis resembles squamous papilloma. As a result, a thorough histopathologic study is essential for a correct diagnosis of this uncommon condition.

Keywords: ocular, rhinosporidiosis, histopathology, Ethiopia

Introduction

Rhinosporidiosis is a granulomatous infection that affects the mucosal membranes of the nose, mouth, eyes, genitalia, and the rectal mucosa caused by *Rhinosporidium seeberi*, an aquatic protistan parasite.¹ The illness is thought to spread across the traumatized epithelium ("transepithelial infection") as a result of contact with infected water sources, most commonly in the nasal cavity. In India, Sri Lanka, South America, and portions of Africa, the disease is endemic.²⁻⁶

Ocular Rhinosporidiosis affects the conjunctiva, lacrimal sac, sclera, and eyelids as a primary lesion or as a secondary dissemination from other mucosal locations. Trauma has been recognized as a risk factor for the development of ocular rhinosporidiosis. Conjunctival lesions are soft, fleshy, red, and strawberry-like in appearance.⁷⁻⁹ The lesions typically exhibit extensive vascularity and friability. On the surface, little white dots are also frequently spotted.⁷ Histopathology on biopsied or resected tissues allows for a definitive diagnosis of rhinosporidiosis as well as the identification of the pathogen in various stages. Fine needle aspiration from rhinosporidial lesions or smears of secretions from the surfaces of accessible polyps have also been used for cytodiagnosis.⁵ In the submucosa of the afflicted region, the organism develops spherical, thick-walled sporangia ranging in size from 10 to 200 μm, which are visible in most histological sections at all stages of development. Fungal stains such as Gomori methenamine silver (GMS) and Periodic acid-Schiff (PAS) can be used to visualize the organism in addition to standard hematoxylin and eosin (H&E) staining.^{6,10-12} The treatment of choice is complete surgical excision with or without cautery at the base and recurrence is described as rare.¹³

Case Presentation

Clinical History

A 12-year-old boy presented to our hospital with a one-month history of foreign body sensation and a fleshy pedunculated conjunctival mass that grew larger over time. There was no history of trauma or similar lesions to other side of the body. A 15mm pinkish pedunculated fleshy mass of the right palpebral conjunctiva is discovered during an ophthalmologic examination. The visual acuity was within normal limits. The child was diagnosed as Pedunculated Squamous Cell Papilloma and underwent excisional biopsy of the lesion.

Macroscopic and Microscopic Findings

We received one formalin-fixed tiny firm ovoid grey white tissue fragment measuring 1.5x1cm for pathology. A hyperplastic polypoid lesion with multiple globular cysts in the conjunctival submucosa was found in microscopic sections, coupled with a significant inflammatory infiltration constituting of lymphocytes, plasma cells, and neutrophils, as well as enormous thick-walled sporangia with numerous endospores (Figure 1). Endospores were released after some of the matured sporangia were ruptured (Figure 2). Conjunctival Rhinosporidiosis was diagnosed histopathologically. There was no recurrence or sign of Rhinosporidiosis in the eye or any other area of the body at the patient's last examination, which was 7 months following surgical excision.

Discussion

With the widespread practice of bathing in river and pond water, ocular rhinosporidiosis is common in India and Sri Lanka. In the age group of 11–20 years, roughly 7% of patients have a conjunctival source of the disease.^{14,15} It primarily affects young male patients, though a Nepalese study found that the prevalence is higher among children in their first decade of life.¹⁶ The route of transmission is unknown, however it is thought to be acquired by contact with injured epithelium by the causative organism, which usually occurs in an aquatic environment.¹⁷ Those who dive or swim in stagnant water are more likely to get it.^{4,7} This could be the source of infection in our patient, who had previously bathed in river water.

Rhinosporidiosis causes fleshy, vascular, polypoidal, and friable lesions.⁴ These polyps are either sessile or pedunculated, as in our case, and have a strawberry-like look. The sporangia, which appear as grey or yellow dots in the vascular polypoid masses, are responsible for this appearance. *Rhinosporidium seeberi* sporangia can be seen under the normal

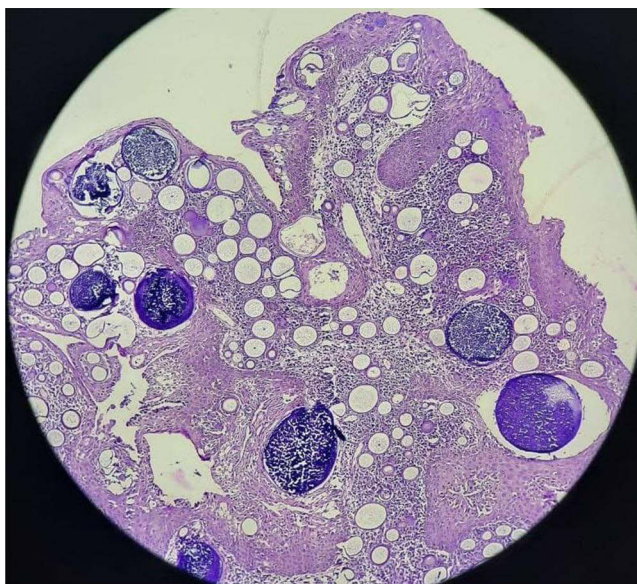


Figure 1 Low power (4x) view showing polypoid lesion with numerous sporangia within conjunctival submucosa with surrounding heavy lymphoplasmacytic inflammatory infiltrates.

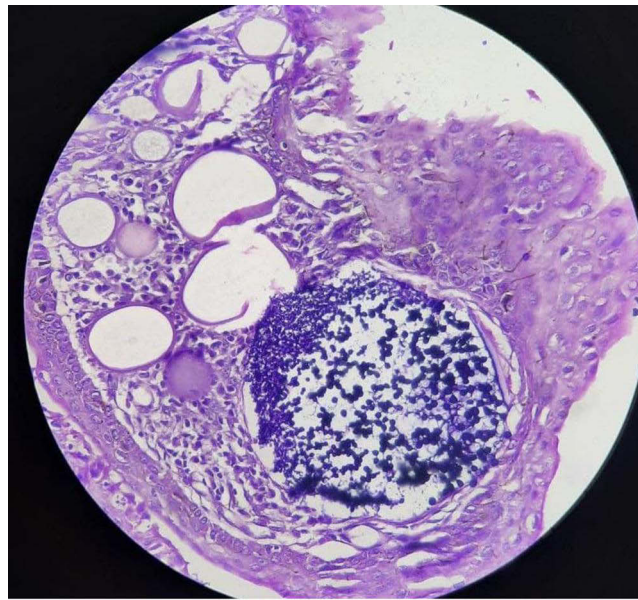


Figure 2 Numerous sporangia within conjunctival submucosa with bursting of sporangia and trans-epithelial migration of spores.

epithelium on histopathologic examination, which can invariably exhibit papillomatous hyperplasia and hypervascularity. Associated with this, mixed inflammatory infiltrates composed of lymphocytes, plasma cells, neutrophils and multinucleated giant cells and scattered granuloma are common.

A swelling in the lacrimal region, a polypoidal conjunctival mass, eyelid mass, and, occasionally, a scleral mass that can induce scleral melting can all be the presentations of ocular lesions.⁷ Wart-like lesions of the scalp, abdomen, and other regions have been seen as a result of systemic involvement.⁸ Recurrent chalazion or persistent follicular conjunctivitis are rare clinical presentations.¹⁸ The major form of presentation in our scenario cannot be determined because no previous reports of conjunctival Rhinosporidiosis in Ethiopia are available. Early removal of the lesion as well as the surrounding conjunctiva is the preferred treatment for conjunctival rhinosporidiosis. Recurrences are uncommon.¹³

Due to the papillomatous appearance of the mass and the fact that ocular Rhinosporidiosis is uncommon in our setup, the case was initially diagnosed as conjunctival papilloma. Thus, even in nonendemic areas, oculosporidiosis should be considered in the differential diagnosis of conjunctival polypoidal lesions. In such cases, the ocular infection could be primary, or the person could be a migrant from an endemic location.

Conclusion

This is an uncommon case of ocular Rhinosporidiosis in an Ethiopian child, with just a few examples previously recorded in the literature, and no such report of its occurrence in our setup to our knowledge. When evaluating and managing patients with ocular lesions, clinicians and pathologists should keep this in mind. It might also mimic conjunctival squamous papilloma clinically, highlighting the importance of a histopathological study to guarantee accurate diagnosis and therapy.

Ethics Statement

We sought for and obtained the written consent from the parents of the child to publish this article anonymously. This required no further review by institutional review board (IRB) of Jimma University.

Acknowledgment

We thank the patient for cooperating and consenting to the publication of this case report.

Disclosure

The authors declare that no competing interests exist.

References

- Hernández P, Bastidas C. Rhinosporidiosis en el estado de Barinas 1980–1990. *Dermatologia Venez.* 1992;30(3):143–151.
- Arseculeratne S. Recent advances in rhinosporidiosis and rhinosporidium seeberi. *Indian J Med Microbiol.* 2002;20(3):119–131. doi:10.1016/S0255-0857(21)03243-6
- Pal M, Shimelis S, Rao PVR, Samajpati N, Manna AK. Rhinosporidiosis: an enigmatic pseudofungal disease of humans and animals. *J Mycopathol Res.* 2016;54(1):49–54.
- Pfaller MA, Diekema DJ. Unusual fungal and pseudofungal infections of humans. *J Clin Microbiol.* 2005;43(4):1495–1504. doi:10.1128/JCM.43.4.1495-1504.2005
- Satyanarayana C. Rhinosporidiosis: with a record of 255 cases. *Acta Otolaryngol.* 1960;51(3–4):348–366. doi:10.3109/00016486009124506
- Das S, Kashyap B, Barua M, et al. Nasal rhinosporidiosis in humans: new interpretations and a review of the literature of this enigmatic disease. *Med Mycol.* 2011;49(3):311–315. doi:10.3109/13693786.2010.526640
- Gichuhi S, Onyuma T, Macharia E, et al. Ocular rhinosporidiosis mimicking conjunctival squamous papilloma in Kenya - a case report. *BMC Ophthalmol.* 2014;14(1):2–5. doi:10.1186/1471-2415-14-45
- Prasad K, Veena S, Permi HS, Teerthanath S, Shetty KP, Shetty JP. Disseminated cutaneous rhinosporidiosis. *J Lab Physicians.* 2010;2(1):44–46. doi:10.4103/0974-2727.66706
- Bhagat A, Singla K, Singh K, Heer P. Ocular rhinosporidiosis. *QJM.* 2020;113(7):497–498. doi:10.1093/qjmed/hcz260
- Singh CA, Sakthivel P. Rhinosporidiosis. *N Engl J Med.* 2019;380(14):1359. doi:10.1056/NEJMicm1811820
- Rajeshwari A, Gangadhara S, Deviprasad S, Manohar S. Rhinosporidiosis - a report of two cases. *Indian J Otolaryngol Head Neck Surg.* 2010;62(3):322–325. doi:10.1007/s12070-010-0082-9
- Coetzee T. Rhinosporidiosis of the conjunctiva. *Br J Ophthalmol.* 1959;43(5):309–311. doi:10.1136/bjo.43.5.309
- Sefu U, Fauzia A. Human nasal rhinosporidiosis: a case report from Malawi. *Pan Afr Med J.* 2011;9(1):1–5. doi:10.4314/pamj.v9i1.71203
- Udoye E, Azonobi R, Opubiri I. Ocular rhinosporidiosis in a Nigerian child: a case report and literature review from Niger Delta of Nigeria. *J Sci Res Reports.* 2015;4(7):599–604.
- Kaimbo KWD, Parys-Van Ginderdeuren R. Conjunctival rhinosporidiosis: a case report from a Congolese patient. *Bull Soc Belge Ophthalmol.* 2008;309:19–22.
- Morelli L, Polce M, Pescioli F, et al. Human nasal rhinosporidiosis: an Italian case report. *Diagn Pathol.* 2006;1(1):4–7. doi:10.1186/1746-1596-1-25
- Mithal C, Agarwal P, Mithal N. Ocular and adnexal rhinosporidiosis: the clinical profile and treatment outcomes in a tertiary eye care centre. *Nepal J Ophthalmol.* 2012;4(1):45–48. doi:10.3126/nepjoph.v4i1.5849
- Karthikeyan P, Vijayasundaram S, Pulimoottil DT. A retrospective epidemiological study of rhinosporidiosis in a rural tertiary care centre in Pondicherry. *J Clin Diagnostic Res.* 2016;10(5):MC04–MC08. doi:10.7860/JCDR/2016/17465.7788
- Shrestha SP, Hennig A, Parija SC. Prevalence of rhinosporidiosis of the eye and its adnexa in Nepal. *Am J Trop Med Hyg.* 1998;59(2):231–234. doi:10.4269/AJTMH.1998.59.231
- Mukhopadhyay S, Shome S, Bar PK, et al. Ocular rhinosporidiosis presenting as recurrent chalazion. *Int Ophthalmol.* 2015;35(5):705–707. doi:10.1007/s10792-012-9625-2

International Medical Case Reports Journal

Dovepress

Publish your work in this journal

The International Medical Case Reports Journal is an international, peer-reviewed open-access journal publishing original case reports from all medical specialties. Previously unpublished medical posters are also accepted relating to any area of clinical or preclinical science. Submissions should not normally exceed 2,000 words or 4 published pages including figures, diagrams and references. The manuscript management system is completely online and includes a very quick and fair peer-review system, which is all easy to use. Visit <http://www.dovepress.com/testimonials.php> to read real quotes from published authors.

Submit your manuscript here: <https://www.dovepress.com/international-medical-case-reports-journal-journal>