


Formalin Fixation for Optimal Concordance of Programmed Death-Ligand 1 Immunostaining Between Cytologic and Histologic Specimens From Patients With Non-small Cell Lung Cancer

Bregje M. Koomen, MD ¹; Jose van der Starre-Gaal, MD, PhD²; Judith M. Vonk, PhD³; Jan H. von der Thüsen, MD, PhD⁴; Jacqueline J. C. van der Meij, MD⁵; Kim Monkhorst, MD, PhD⁶; Stefan M. Willems, MD, PhD^{1,7}; Wim Timens, MD, PhD⁷; and Nils A. 't Hart, MD, PhD^{2,7}

BACKGROUND: Immunohistochemical staining of programmed death-ligand 1 (PD-L1) is used to determine which patients with non-small cell lung cancer (NSCLC) may benefit most from immunotherapy. Therapeutic management of many patients with NSCLC is based on cytology instead of histology. In this study, concordance of PD-L1 immunostaining between cytology cell blocks and their histologic counterparts was analyzed. Furthermore, the effect of various fixatives and fixation times on PD-L1 immunoreactivity was studied. **METHODS:** Paired histologic and cytologic samples from 67 patients with NSCLC were collected by performing fine-needle aspiration on pneumonectomy/lobectomy specimens. Formalin-fixed, agar-based or CytoLyt/PreservCyt-fixed Cellient cell blocks were prepared. Sections from cell blocks and tissue blocks were stained with SP263 (standardized assay) and 22C3 (laboratory-developed test) antibodies. PD-L1 scores were compared between histology and cytology. In addition, immunostaining was compared between PD-L1-expressing human cell lines fixed in various fixatives at increasing increments in fixation duration. **RESULTS:** Agar cell blocks and tissue blocks showed substantial agreement ($\kappa = 0.70$ and $\kappa = 0.67$, respectively), whereas fair-to-moderate agreement was found between Cellient cell blocks and histology ($\kappa = 0.28$ and $\kappa = 0.49$, respectively). Cell lines fixed in various alcohol-based fixatives showed less PD-L1 immunoreactivity compared with those fixed in formalin. In contrast to SP263, additional formalin fixation after alcohol fixation resulted in preserved staining intensity using the 22C3 laboratory-developed test and the 22C3 pharmDx assay. **CONCLUSIONS:** Performing PD-L1 staining on cytologic specimens fixed in alcohol-based fixatives could result in false-negative immunostaining results, whereas fixation in formalin leads to higher and more histology-concordant PD-L1 immunostaining. The deleterious effect of alcohol fixation could be reversed to some degree by postfixation in formalin. *Cancer Cytopathol* 2021;129:304-317. © 2020 The Authors. *Cancer Cytopathology* published by Wiley Periodicals LLC on behalf of American Cancer Society. This is an open access article under the terms of the Creative Commons Attribution-NonCommercial License, which permits use, distribution and reproduction in any medium, provided the original work is properly cited and is not used for commercial purposes.

KEY WORDS: 22C3 antibody; immunocytochemistry; immunohistochemistry; non-small cell lung carcinoma; programmed cell death-ligand 1; SP263 antibody; tissue fixation.

Corresponding Author: Bregje M. Koomen, MD, Department of Pathology, University Medical Center Utrecht, PO Box 85500, 3508 GA Utrecht, the Netherlands (b.m.koomen@umcutrecht.nl).

¹Department of Pathology, University Medical Center Utrecht, Utrecht University, Utrecht, the Netherlands; ²Department of Pathology, Isala Hospitals, Zwolle, the Netherlands; ³Department of Epidemiology, University Medical Center Groningen, University of Groningen, Groningen, the Netherlands; ⁴Department of Pathology, Erasmus Medical Center, Rotterdam, the Netherlands; ⁵Pathologie Friesland, Leeuwarden, the Netherlands; ⁶Department of Pathology, Netherlands Cancer Institute-Antoni van Leeuwenhoek Hospital, Amsterdam, the Netherlands; ⁷Department of Pathology and Medical Biology, University Medical Center Groningen, University of Groningen, Groningen, the Netherlands

We thank the participating centers for supplying paired histologic and cytologic specimens. Furthermore, we thank HistoCyte Laboratories Ltd for developing PD-L1-expressing cell lines with different fixation schemes. We also thank the Pathology Department of the Martini Hospital for performing PD-L1 staining with the 22C3 pharmDx assay on the cell microarray blocks containing cell line cores. Finally, we thank Martin Kristensson from Visiopharm for calculating H-scores in the PD-L1-expressing cell line cores.

Additional supporting information may be found in the online version of this article.

Received: August 20, 2020; **Revised:** September 28, 2020; **Accepted:** September 30, 2020

Published online October 27, 2020 in Wiley Online Library (wileyonlinelibrary.com)

DOI: 10.1002/cncy.22383, wileyonlinelibrary.com

INTRODUCTION

In non–small cell lung cancer (NSCLC), immunohistochemical expression of programmed death-ligand 1 (PD-L1) on tumor cells is shown to predict the likelihood of response to anti-PD1/anti-PD-L1 immunotherapy.¹ The detection of PD-L1 in tumor tissue by immunohistochemistry (IHC) is required as a companion diagnostic for the immune checkpoint inhibitor pembrolizumab, which may only be prescribed as first-line monotherapy to patients with advanced NSCLC when tumor cells have $\geq 50\%$ PD-L1 expression.^{2,3} For patients with locally advanced (stage III) NSCLC whose disease has not progressed after treatment with radiation and platinum-based chemotherapy, the anti-PD-L1 checkpoint inhibitor durvalumab may be prescribed. This drug, however, only received approval by the European Medicines Agency for patients whose tumors have PD-L1 expression in $\geq 1\%$ tumor cells.⁴ For the immune checkpoint inhibitors nivolumab and atezolizumab, PD-L1 IHC is used as a complementary diagnostic, rendering it less important to gather adequate tissue for PD-L1 immunostaining. Nevertheless, it may identify patients who could respond better to treatment than others and aid in the assessment of risks and benefits for individual patients,^{5,6} especially when the presence of tumor-infiltrating lymphocytes is also taken into account.⁷

Because clinical trials addressing immune checkpoint inhibitors included patients with tissue-based diagnoses, the use of IHC assays for evaluating PD-L1 expression in tumor cells is validated only in histologic specimens.^{8,9} In clinical practice, however, the management of many patients with advanced NSCLC is based on cytology.¹⁰ Diagnostic cytology by fine-needle aspiration (FNA) is less invasive than tissue-based diagnostics through histologic biopsies and thus is preferable.^{8,11} The sensitivity, specificity, and positive predictive values of PD-L1 immunocytochemistry (ICC), however, are unclear, with only a limited number of studies focusing on histologic and cytologic correlation of PD-L1 immunostaining.^{8,9,12-16}

In addition, routinely used fixatives in cytology are often based on methanol or ethanol compared with formalin-based fixatives in histology.¹⁷ This might negatively affect the staining intensity of IHC assays,¹⁸⁻²¹ resulting in false-negative analyses. The effect of different preanalytical variables on PD-L1 immunoreactivity in cytologic specimens is largely unknown, leaving it unclear whether

fixatives other than formalin can reliably be used for determining PD-L1 expression through immunostaining.

The objective of the current multicenter study was to compare PD-L1 immunostaining in matched histologic specimens and cytologic cell blocks by using FNA material and histologic samples from the same resected lung tumor. Second, the effects of various fixation solutions as well as different fixation times on PD-L1 immunostaining were studied using PD-L1–expressing human cell lines. Preliminary and limited results from the study were previously reported in an item of correspondence.²² Complete, extended results are presented here.

MATERIALS AND METHODS

Collection of Histologic and Cytologic Specimens

Five Dutch pathology laboratories collaborated to collect material for the comparison of PD-L1 immunostaining in histologic and cytologic specimens from patients with NSCLC (University Medical Center Groningen, Isala Zwolle, Erasmus Medical Center Rotterdam, Netherlands Cancer Institute Amsterdam, and Pathology Friesland). In each center, paired histologic and cytologic samples were collected. To do so, FNAs were performed on pneumonectomy or lobectomy specimens with a palpable or visible tumor to obtain cytologic samples that were as close as possible to routine FNA-derived specimens. The collection of cytologic material was performed before further preparation and fixation of the resection specimen. It has been demonstrated previously that collecting FNA material this way can be done without compromising routine histologic evaluation of the tumor, thus it is a safe method that can be used within the outlines of the code of conduct for responsible use of residual human tissue for research established by the Federation of Dutch Medical Scientific Societies.²³ Histology samples were taken after 18 to 72 hours following routine protocols used in clinical practice. The mean estimated fixation time was between 18 hours (overnight fixation) and 72 hours (resection specimens that remained in formalin over the weekend). All patient material was used anonymously and was collected and used in accordance with the Federation of Dutch Medical Scientific Societies code of conduct and with the General Data Protection Regulation.

After obtaining the FNA specimen, each center was allowed to use their routine method for fixation and

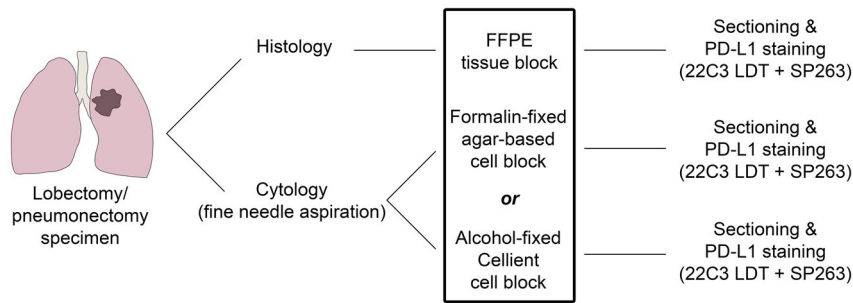


Figure 1. This is a schematic representation of the study design. FFPE indicates formalin-fixed, paraffin-embedded; LDT, laboratory-developed test (using the 22C3 antibody); PD-L1, programmed death-ligand 1; SP263, antibody used in the standardized assay.

generation of a cell block (see Supporting Table 1). In this way, concordance of PD-L1 immunostaining could be analyzed between histologic tissue and cell blocks that were processed in different ways, reflecting normal, everyday practice. Depending on the locally developed protocols, either a formalin-fixed, agar-based cell block or a CytoLyt/PreservCyt-fixed Cellient cell block was prepared. The Cellient Automated Cell Block System (Hologic Inc) was used for the latter. From each cell block, a slide was cut and stained with hematoxylin and eosin to check for the presence of tumor cells. If enough viable tumor cells were present (≥ 100 tumor cells), sequential, 3- μm -thick slices were cut for staining with 2 separate PD-L1 antibodies, ie, the Ventana SP263 standardized assay (Ventana Medical Systems Inc) and a Dako 22C3 laboratory-developed test (LDT). Formalin-fixed, paraffin-embedded (FFPE) tissue sections were cut from a routinely made histologic tissue block from the same tumor. These sections were also stained for PD-L1 with both antibodies (SP263 and 22C3) and were used for histologic comparison (for a schematic representation of the study design, see Fig. 1).

Preparation of PD-L1-Expressing Cell Lines

To further evaluate the effects of different fixatives on PD-L1 immunostaining in cytologic samples, commercially available cell lines with high PD-L1 expression were used (T-cell non-Hodgkin lymphoma cell lines from HistoCyte Laboratories Ltd²⁴). The cell lines were fixed in either 5 mL 10% neutral-buffered formalin (NBF) or 25 mL CytoLyt, PreservCyt, CytoRich Red, or Carbowax. CytoLyt and PreservCyt (Hologic Inc) are methanol-based fixatives, while Carbowax (Dow Chemical Company) contains ethanol and polyethylene glycol. CytoRich Red (Thermo Scientific) is alcohol-based as well (methanol,

isopropyl alcohol, and ethylene glycol) but also contains a small amount of formaldehyde. Each is used as a (pre-) fixation solution in clinical practice. In addition, cell lines were fixed in CytoLyt, PreservCyt, CytoRich Red, or Carbowax followed by 30-minute fixation in 10% NBF. Various fixation times were used, which allowed us to evaluate the effect of different fixation periods on PD-L1 immunostaining. The fixation periods used were 2 hours and 24 hours for all fixatives and 48 hours for the cell lines fixed in NBF and CytoLyt only. This design allowed for 20 different fixation schemes (see Supporting Table 2). Subsequently, agarose pellets were created for each cell line and were then processed into paraffin blocks. Cores from each block were assembled in paraffin-embedded cell microarray (CMA) blocks. These were sent to the University Medical Center in Groningen, where slides were cut (3- μm thickness) for PD-L1 immunostaining.

PD-L1 IHC Staining and Scoring

Sections cut from each cell block and tissue block were stained with the Ventana SP263 antibody and the Dako 22C3 antibody. All staining of patient material was performed within 1 center (University Medical Center Groningen). Staining of slides with the SP263 standardized assay was carried out on a Ventana Benchmark Ultra platform according to the manufacturer's instructions. The Dako 22C3 was used as the LDT, also using the Ventana Benchmark Ultra platform. Previously, this LDT was compared with the Dako 22C3 pharmDx assay on Dako Link 48, for optimization and validation of its use in routine clinical practice. The addition of an amplification step led to the best protocol, which was comparable to a previously published protocol by Adam et al.²⁵ The same SP263 standardized assay and the 22C3 LDT were used to stain sections from the CMA blocks containing

the cell line cores. In addition, sections from the CMA blocks were stained with the Dako 22C3 pharmDx assay, used on a Dako Autostainer Link 48 platform according to the manufacturer's instructions (performed in Martini Hospital, Groningen, the Netherlands).

Staining patterns were analyzed in cores from each cell line and compared visually between the 20 different fixation schemes. Differences in PD-L1 expression between cell lines were quantified by determining PD-L1 H-scores for each cell core, using an application in Visiopharm software (Visiopharm A/S).²⁶ The H-score was calculated by determining staining intensity in each cell (divided into levels 0, 1+, 2+, and 3+), followed by application of the following formula: $1 * (\% \text{ of cells with staining intensity level } 1+) + 2 * (\% \text{ of cells with staining intensity level } 2+) + 3 * (\% \text{ of cells with staining intensity level } 3+)$.^{27,28} All stained slides from the paired cell and tissue blocks of included patients were reviewed independently by 2 trained pathologists. Cases of disagreement were resolved through discussion. PD-L1 expression was scored in tumor cells according to the guidelines provided by Roche/Ventana or Dako as part of the PD-L1 IHC pharmDx test. For each slide, the pathologists determined the tumor proportion score (TPS), which is constructed by determining the percentage of viable tumor cells that show membranous PD-L1 immunostaining relative to the total amount of tumor cells. This score was used to categorize the samples into 3 groups: TPS <1% (negative), TPS 1% to 49% (weakly positive), and TPS \geq 50% (strongly positive).

Statistical Analysis

To assess agreement of the PD-L1 TPS between histologic and cytologic samples, weighted κ values (linear weights) were calculated. Furthermore, the Cohen κ was calculated using data dichotomized according to the 1% and 50% cutoffs. Overall percent agreement (OPA), positive percent agreement, and negative percent agreement were determined for both cutoffs using histology as the reference standard. In addition, the McNemar-Bowker test of symmetry was applied to assess whether the categorization of PD-L1 expression differed significantly between histologic and cytologic samples. *P* values <.05 were considered statistically significant. Both interobserver and interassay agreement were assessed using weighted κ and Cohen κ values for the 1% and 50% cutoffs. Statistical analysis was performed using RStudio version 1.1.456

(R Foundation for Statistical Computing) and IBM SPSS Statistics version 25 (IBM Corporation).

RESULTS

Sample Selection

Paired histologic and cytologic samples from 85 patients were collected. Fifteen were excluded, because these patients had a diagnosis other than NSCLC. Three patients were excluded because 1 or both of their samples contained an insufficient number of viable tumor cells (<100). The remaining 67 patients all had a diagnosis of NSCLC, with various histologic subtypes (adenocarcinoma, *n* = 38; squamous cell carcinoma, *n* = 25; pleomorphic carcinoma, *n* = 2; adenosquamous carcinoma, *n* = 1; and NSCLC not otherwise specified, *n* = 1). Cytologic material from 33 patients was processed into agar-based cell blocks. The cytologic material from the other 34 patients was processed into Cellient cell blocks.

Overall Concordance Between Histology and Cytology

When the 22C3 LDT was used for determining PD-L1 expression in histologic samples, 25 samples (37%) had a TPS <1%, 20 samples (30%) had a TPS from 1% to 49%, and 22 samples (33%) had a TPS \geq 50%. When we used the 22C3 antibody on cytologic samples, 34 samples (51%) had a TPS <1%, 22 samples (33%) had a TPS from 1% to 49%, and 11 samples (16%) had a TPS \geq 50%. Of all 67 samples, 39 (58%) showed concordant results between histology and cytology. A weighted κ value of 0.49 was identified, which can be described as moderate agreement.²⁹ Dichotomizing data according to the 1% and 50% cutoffs also resulted in moderate agreement levels (κ = 0.49 and κ = 0.50, respectively) (see Supporting Table 3).

When the SP263 antibody was used on histologic samples, 25 samples (37%) had a TPS <1%, 24 samples (36%) had a TPS from 1% to 49%, and 18 samples (27%) had a TPS \geq 50%. Performing SP263 immunostaining on cytologic samples resulted in a TPS <1% in 37 samples (55%), a TPS from 1% to 49% in 18 samples (27%), and a TPS \geq 50% in 12 samples (18%). Also when using the SP263 antibody, 45 of 67 samples (67%) showed concordance between histology and cytology. The agreement observed can be described as moderate (κ = 0.59). Dichotomization according to the 1% and

TABLE 1. Concordance of Programmed Death-Ligand 1 (PD-L1) Expression (Tumor Proportion Score) Between Histologic and Cytologic Specimens When the 22C3 Laboratory-Developed Test Was Used to Stain for PD-L1^a

Cytologic Specimen	Agreement of TPS in 3 Categories: <1%, 1%-49%, and ≥50%			Agreement When Dichotomizing TPS at 1% Cutoff			Agreement When Dichotomizing TPS at 50% Cutoff			Cohen κ (95% CI)	
	Weighted κ (95% CI)			Cohen κ (95% CI)			Cohen κ (95% CI)				
	OPA, %	NPA, %	PPA, %	OPA, %	NPA, %	PPA, %	OPA, %	NPA, %	PPA, %		
Agar, formalin-fixed	73	88	90	83	85	85	85	85	67	95	0.65 (0.37-0.94)
Cellient, alcohol-fixed	44	62	48	85	85	48	85	76	20	100	0.26 (-0.05, 0.57)

Abbreviations: LDT, laboratory-developed test; NPA, negative percent agreement; OPA, overall percent agreement; PPA, positive percent agreement; TPS, tumor proportion score.
^aAnalyses were performed separately for formalin-fixed, agar-based cell blocks and for alcohol-fixed Cellient cell blocks.

50% cutoffs resulted in moderate-to-substantial agreement levels, suggesting a somewhat higher level of agreement between cytologic and histologic material at the 50% cutoff ($\kappa = 0.66$) compared with the 1% cutoff ($\kappa = 0.53$) with use of the SP263 antibody (see Supporting Table 3).

Concordance Between Histology and Agar or Cellient Cell Blocks

Separate analyses of agar-based and Cellient-processed cell blocks revealed a higher degree of agreement between the formalin-fixed agar cell blocks and histology than between the alcohol-fixed Cellient cell blocks and histology. When using the 22C3 LDT, substantial agreement levels were found when analyzing concordance between agar cell blocks and histology (OPA, 73%; $\kappa = 0.70$) (Table 1). Agreement between Cellient cell blocks and histology can be described as fair (OPA, 44%; $\kappa = 0.28$). In addition, a comparison of the categorization of PD-L1 expression between histologic samples and alcohol-fixed Cellient samples revealed a statistically significant difference ($P < .01$), whereas no statistically significant difference was observed between histologic samples and formalin-fixed, agar-based samples ($P = .407$) (see Supporting Table 4). An overview of concordance and discordance between matched samples using the 22C3 LDT is displayed by Figure 2.

Similar results were observed for the SP263 antibody (Fig. 2), with substantial agreement (OPA, 73%; $\kappa = 0.67$) observed for formalin-fixed agar cell blocks, whereas moderate agreement (OPA, 62%; $\kappa = 0.49$) was observed when analyzing agreement between alcohol-fixed Cellient cell blocks and their histologic counterparts (Table 2). A comparison of the categorization of PD-L1 expression between histology and both groups of cytologic samples showed a statistically significant difference for the Cellient-processed samples ($P < .05$). As with the 22C3 LDT, no statistically significant difference was found between histologic samples and agar cell blocks ($P = .247$) (see Supporting Table 5).

Analyzing the data after dichotomization at the 1% and 50% cutoffs again resulted in lower concordance values for alcohol-fixed Cellient samples compared with formalin-fixed, agar-based samples (Tables 1 and 2). This applied to both antibodies, although concordance levels for the Cellient samples were lower for the 22C3 LDT ($\kappa = 0.28$ and $\kappa = 0.26$ for the 1% and 50% cutoffs, respectively) than for the SP263 antibody ($\kappa = 0.38$ and

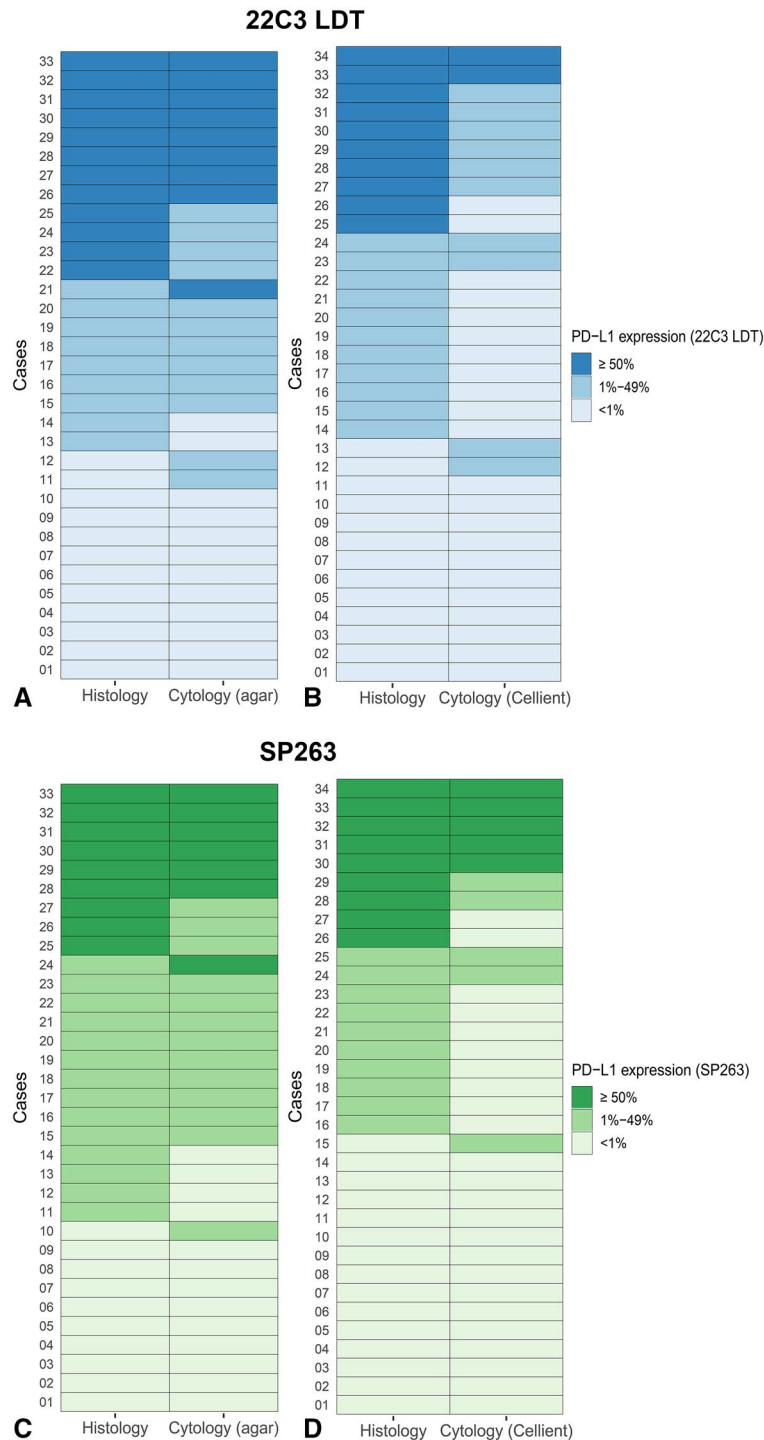


Figure 2. The concordance of programmed death-ligand 1 (PD-L1) expression (tumor proportion score) is illustrated between matched histologic and cytologic samples from individual patients. (A) Histology and formalin-fixed, agar-based cell blocks stained with 22C3 (the laboratory-developed test [LDT]) are compared. Nine of 33 cases (27%) show discordance. (B) Histology and alcohol-fixed Cellient cell blocks stained using the 22C3 LDT are compared. Nineteen of 34 cases (56%) show discordance. (C) Histology and formalin-fixed, agar-based cell blocks stained with SP263 (the standardized assay) are compared. Nine of 33 cases (27%) show discordance. (D) Histology and alcohol-fixed Cellient cell blocks stained with SP263 are compared. Thirteen of 34 cases (38%) show discordance.

TABLE 2. Concordance of Programmed Death-Ligand 1 (PD-L1) Expression (Tumor Proportion Score) Between Histologic and Cytologic Specimens When the SP263 Standardized Assay Was Used to Stain for PD-L1^a

Cytologic Specimen	Agreement of TPS in 3 Categories: <1%, 1%-49%, and ≥50%				Agreement When Dichotomizing TPS at 1% Cutoff				Agreement When Dichotomizing TPS at 50% Cutoff			
	OPA, %	OPA, %	Weighted κ (95% CI)	Cohen κ (95% CI)	OPA, %	PPA, %	NPA, %	Cohen κ (95% CI)	OPA, %	PPA, %	NPA, %	Cohen κ (95% CI)
Agar, formalin-fixed	73	85	0.67 (0.47-0.87)	0.67 (0.40-0.94)	83	90	96	0.67 (0.37-0.98)	88	67	96	0.67 (0.37-0.98)
Cellient, alcohol-fixed	62	68	0.49 (0.24-0.73)	0.38 (0.11-0.65)	47	93	100	0.65 (0.33-0.97)	88	56	100	0.65 (0.33-0.97)

Abbreviations: LDT, laboratory-developed test; NPA, negative percent agreement; OPA, overall percent agreement; PPA, positive percent agreement; TPS, tumor proportion score.
^aAnalyses were performed separately for formalin-fixed, agar-based cell blocks and for alcohol-fixed Cellient cell blocks.

$\kappa = 0.65$, respectively). The lowest agreement levels were observed for Cellient cell blocks at the 50% cutoff and using the 22C3 antibody. Figure 3 displays an exemplary case in which the surgical resection specimen had a TPS $\geq 50\%$ with both antibodies, whereas the Cellient samples had a TPS between 1% and 49%.

Interpathologist and Interassay Agreement

Agreement of PD-L1 scoring between the 2 pathologists was high for histologic samples with the use of both 22C3 LDT and SP263. An analysis of concordance of PD-L1 staining between both antibodies also showed high agreement, especially in histologic material (for more detailed results of interpathologist agreement analysis, see Supporting Results A and Supporting Table 6; for more detailed results of interassay agreement analysis, see Supporting Results B and Supporting Table 7).

PD-L1-Expressing NSCLC Cell Lines

Twenty PD-L1-expressing cell line specimens were created using different fixatives and various fixation times. Formalin-fixed cell lines, which were used as controls, showed clear membranous staining on all cells with all staining protocols (SP263, 22C3 LDT, and 22C3 pharmDx). Fixation in CytoLyt, PreservCyt, or Carbowax resulted in lower staining intensity compared with fixation in formalin with all antibodies. Longer fixation times (24 and 48 hours, the latter for CytoLyt only) resulted in even less immunoreactivity compared with 2-hour fixation, which was most clearly visible for SP263; whereas, for the 22C3 LDT, this phenomenon was observed in cells fixed in Carbowax only. When the 22C3 pharmDx assay was used, no apparent difference between the different fixation times was discernible. Fixation in CytoRich Red did not result in lower staining intensity compared with formalin, regardless of the antibody or the fixation time used (Fig. 4).

When fixation in CytoLyt, PreservCyt, or Carbowax was followed by fixation in formalin, staining intensity was preserved using the 22C3 LDT (Fig. 5). This effect was apparent irrespective of fixation time. Similarly, using the 22C3 pharmDx assay, most of the cell lines that were fixed in formalin after alcohol fixation showed a stronger staining intensity than was observed in the cell lines without formalin fixation (see Supporting Fig. 1). This effect was most prominent in cell lines that were fixed for a total duration of 2 hours, although an improvement in staining

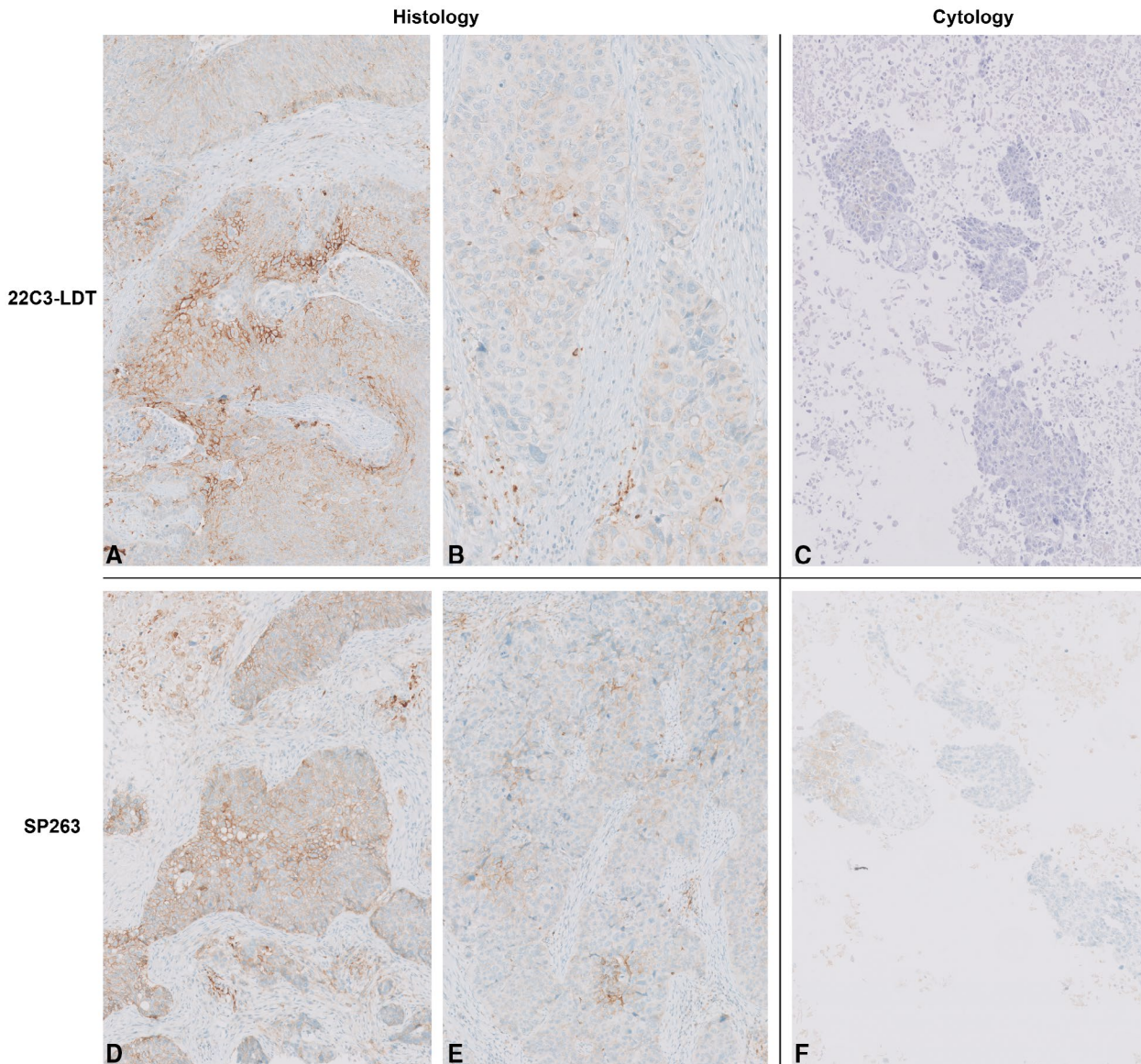


Figure 3. This is an example of a case in which the programmed death-ligand 1 (PD-L1) tumor proportion score (TPS) was $\geq 50\%$ in the resection specimen and ranged from 1% to 49% in the cytologic material (alcohol-fixed Cellient cell block). (A,B) The PD-L1 TPS was $\geq 50\%$ in a resection specimen stained with 22C3 (the laboratory-developed test [LDT]), with (A) part of the tumor showing strong staining intensity and (B) another part showing somewhat weaker staining intensity. (C) The PD-L1 TPS was between 1% and 49% in a Cellient cell block stained with 22C3. (D,E) The PD-L1 TPS was $\geq 50\%$ in a resection specimen stained with SP263 (the standardized assay), with (D) part of the tumor showing strong staining intensity and (E) another part showing somewhat weaker staining intensity. (F) The PD-L1 TPS was between 1% and 49% in a Cellient cell block stained with SP263 (original magnification $\times 10$ in A-F).

intensity was also discernible in cell lines fixed in CytoLyt or PreservCyt for 23.5 hours followed by formalin fixation. IHC staining with SP263 showed a similar effect in the cell line fixed in Carbowax for 1.5 hours followed by 0.5 hours of formalin fixation only. SP263 showed no or only negligible preserved staining intensity after formalin fixation in the other cell lines (Fig. 6). Quantification of the difference in PD-L1 staining intensity between the

cell lines with and without additional formalin fixation confirmed the beneficial effect of formalin postfixation on the 22C3 LDT (see Supporting Fig. 2).

DISCUSSION

In this multicenter study, concordance of PD-L1 immunostaining between matched cell blocks and histologic FFPE tissue was investigated using 2 different PD-L1

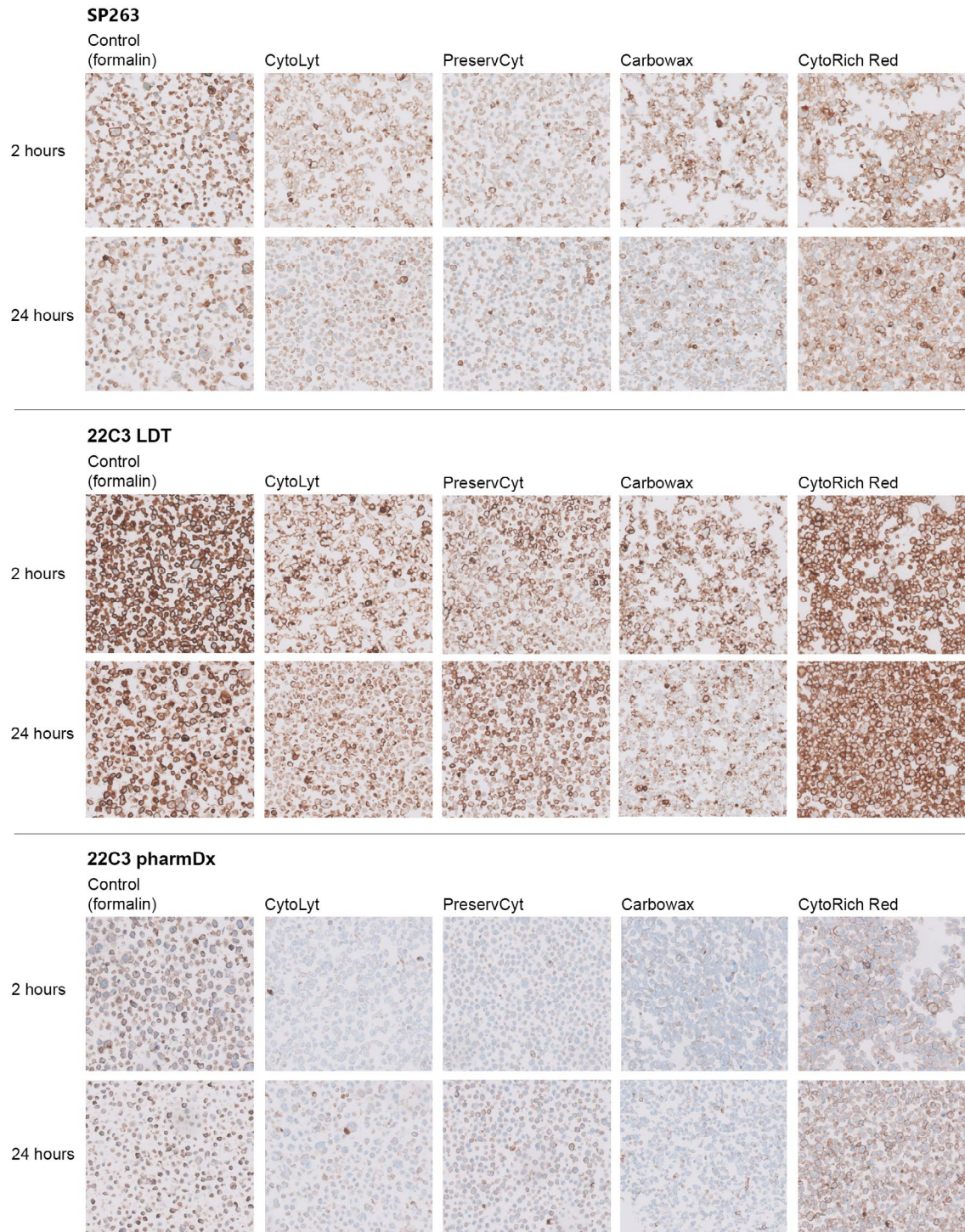
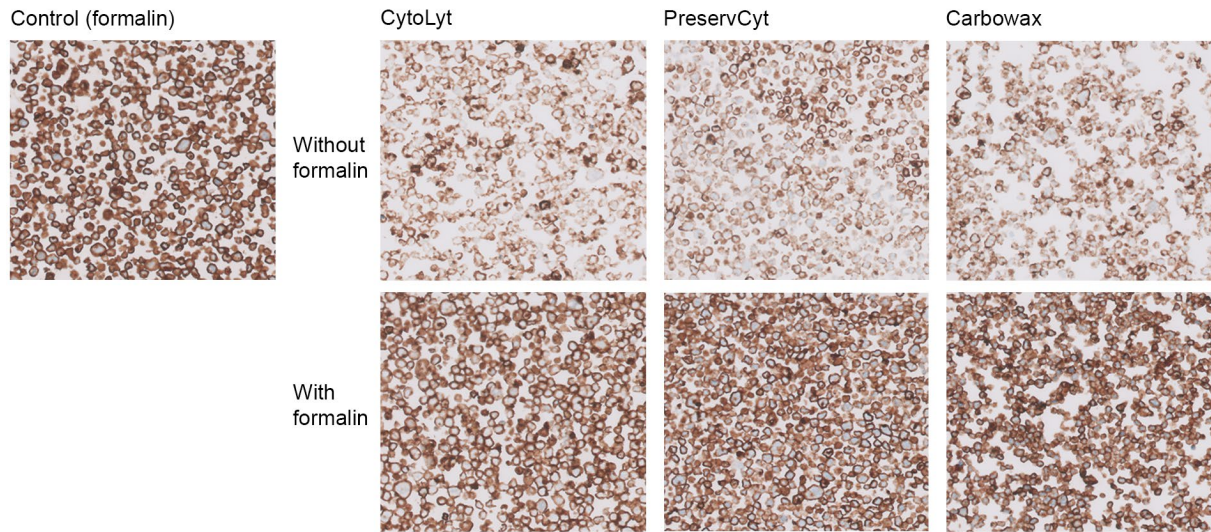


Figure 4. Immunostaining patterns are illustrated of programmed death-ligand 1 (PD-L1)-expressing cell lines fixed with different fixation schemes. Results are shown for cell lines fixed in formalin (control) and in CytoLyt, PreservCyt, Carbowax, and CytoRich Red for 2 and 24 hours. PD-L1 immunostaining was performed with (*Top*) the standardized assay SP263, (*Middle*) the 22C3 laboratory-developed test (LDT), and (*Bottom*) the 22C3 pharmDx assay.

IHC antibodies (SP263 and 22C3 LDT). First, differences were observed between alcohol-fixed Cellient cell blocks and formalin-fixed, agar-based cell blocks, with

the Cellient material showing a clear decrease in membranous PD-L1 staining. Second, the effect of different fixatives on PD-L1 immunostaining was studied by

2 hour fixation



24 hour fixation

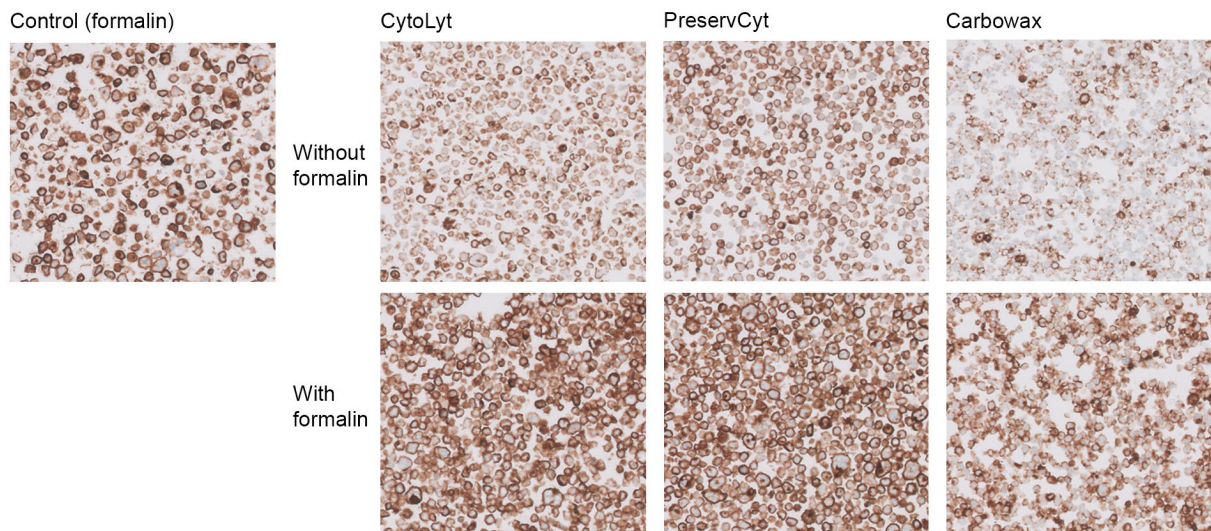


Figure 5. Immunostaining patterns of programmed death-ligand 1 (PD-L1)-expressing cell lines fixed in CytoLyt, PreservCyt, or Carbowax, either with or without additional formalin fixation for 0.5 hours, are illustrated using the 22C3 antibody (the laboratory-developed test [LDT]). Results are shown for a total fixation duration of (*Top*) 2 hours and (*Bottom*) 24 hours.

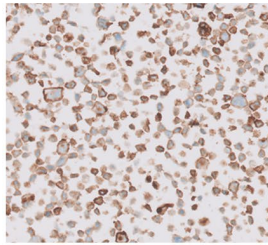
analyzing PD-L1-expressing cell lines fixed in formalin, CytoLyt, PreservCyt, CytoRich Red, and Carbowax.

The overall concordance was moderate to substantial between histologic and cytologic specimens from the same tumor. When agar and Cellient cell blocks were analyzed separately, however, concordance levels were much higher for agar cell blocks than for Cellient-processed material. Therefore, it seems likely that the use of different modes of processing cytology results in variations

in PD-L1 immunostaining and thus different levels of concordance with validated histologic PD-L1 protocols. We hypothesized that the observed differences between the 2 types of cell blocks could be explained by the use of alternative fixatives, resulting in various levels of PD-L1 immunoreactivity. Notably, the agar-based cytologic samples were fixed in formalin, whereas the Cellient samples were fixed in CytoLyt and PreservCyt, both of which are methanol-based fixatives. Other studies have

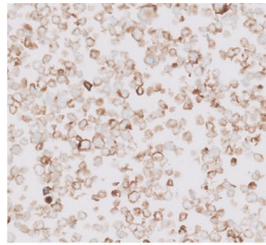
2 hour fixation

Control (formalin)

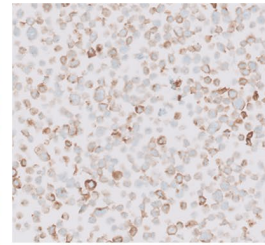


Without formalin

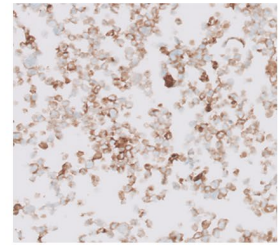
CytoLyt



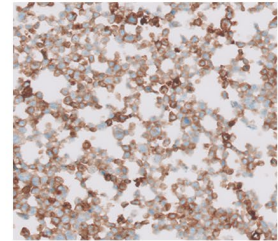
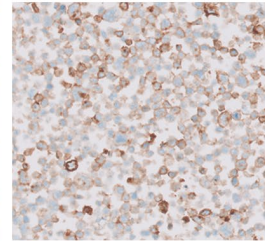
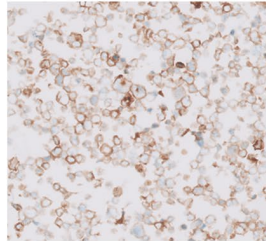
PreservCyt



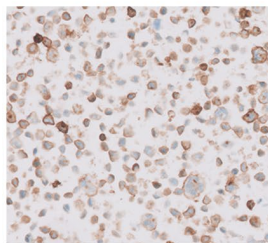
Carbowax



With formalin

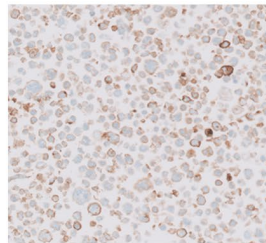
**24 hour fixation**

Control (formalin)

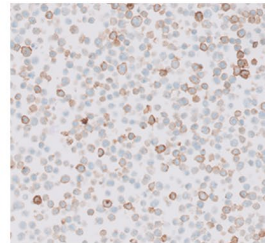


Without formalin

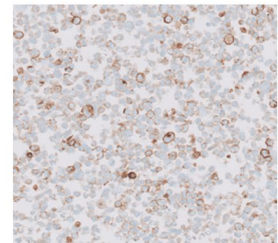
CytoLyt



PreservCyt



Carbowax



With formalin

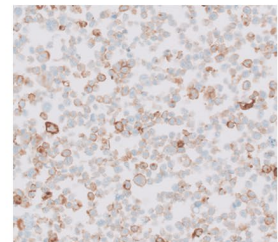
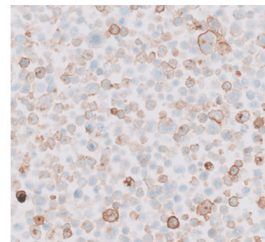
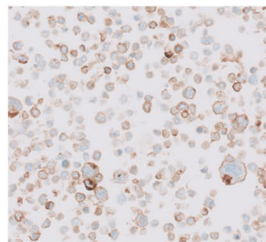


Figure 6. Immunostaining patterns of programmed death-ligand 1 (PD-L1)-expressing cell lines fixed in CytoLyt, PreservCyt, or Carbowax, either with or without additional formalin fixation for 0.5 hours, are illustrated using the SP263 antibody (the standardized assay). Results are shown for a total fixation duration of (*Top*) 2 hours and (*Bottom*) 24 hours.

shown a detrimental effect of CytoLyt fixation on IHC detection of some antigens, such as thyroid transcription factor-1 (TTF-1)¹⁸ and Ki-67.²¹ A study by Lloyd et al³⁰ demonstrated a similar effect on PD-L1 staining, with CytoLyt fixation showing poor PD-L1 immunostaining results. Gosney et al³¹ observed no effect of alcohol-based fixatives, including CytoLyt, on PD-L1 immunostaining with the 22C3 pharmDx assay in cytology specimens. However, the number of cases that were fixed in CytoLyt

was low. Most cases were fixed in CytoRich Red, the use of which, as discussed below, did not result in diminished PD-L1 immunostaining in our PD-L1-expressing cell lines either. Furthermore, all specimens had a postfixation step with 10% NBF for a minimum of 45 minutes, likely resulting in the preservation of PD-L1 immunoreactivity. As indicated by our results, this preserving effect is especially prominent for the extracellular 22C3 antibody.

Diminished PD-L1 immunoreactivity caused by alcohol fixation holds significant implications for clinical practice. Although it is desirable to optimize all individual antibody staining protocols for alcohol-fixed material, perfect concordance with staining intensity in histology cannot always be achieved. Because pathologists frequently use panels of markers to make a diagnosis, a slightly lower immunocytochemical staining intensity of a single marker or a few diagnostic markers can be accepted. In predictive ICC, however, pathologists mostly rely on a single marker to allow clinicians to make a treatment decision. A low membranous staining intensity in histology might result in a false-negative result in cytology. Therefore, using PD-L1 ICC could lead to wrongful denial of treatment with durvalumab to patients with unresectable, stage III NSCLC in Europe (prescribed only to patients with a TPS $\geq 1\%$)⁴ and of treatment with pembrolizumab as first-line monotherapy to patients with metastasized NSCLC (prescribed only to patients with a TPS $\geq 50\%$).² Because many PD-L1 tests for patients with advanced-stage NSCLC are performed on cytologic samples, it is of the utmost importance that the methods used to process cytologic material do not negatively affect PD-L1 staining.

Our analysis of PD-L1-expressing cell lines fixed in different fixatives supports the hypothesis that the use of fixatives other than formalin could result in less PD-L1 immunoreactivity. Cell lines fixed in methanol-based CytoLyt or PreservCyt and cell lines fixed in ethanol-based Carbowax exhibited lower staining intensity with the SP263 and 22C3 standardized assays and the 22C3 LDT. It is known that formalin fixation and alcohol fixation have different effects on proteins, leading to different alterations of the 3-dimensional protein structure.^{32,33} This might explain differences in staining results. Many IHC antibodies have primarily been developed for use on FFPE samples, thus targeting epitopes after formalin fixation. These epitopes, however, may not remain good targets after alcohol fixation. Notably, fixation in CytoRich Red did not result in lower immunostaining, although this fixative contains alcohol elements as well. In contrast to CytoLyt, PreservCyt, and Carbowax, CytoRich Red contains a small amount of formaldehyde (<1%), possibly explaining the preserved PD-L1 immunostaining.³⁴ A side effect of CytoRich Red, however, is DNA degradation,³⁴ rendering the solution less appropriate for routine FNA practice in the selected population,

in which treatment decisions rely on adequate predictive molecular analysis as well.

Interestingly, the addition of formalin to cell lines fixed in CytoLyt, PreservCyt, or Carbowax revealed a positive effect on PD-L1 immunostaining using both the 22C3 LDT and the 22C3 pharmDx assay. Similar to these results, a study by Torous et al³⁵ showed no significant difference in PD-L1 categorization (TPS <1%, TPS 1%-49%, and TPS $\geq 50\%$) between cell blocks fixed in CytoLyt followed by formalin fixation and FFPE surgical resection specimens using the 22C3 pharmDx assay to stain for PD-L1. Although that study did not use paired cytology and resection specimens, the results suggest that additional formalin fixation could be helpful in preserving PD-L1 staining intensity in cytology specimens that were fixed in an alcohol-based fixative. In our study, however, we did not observe improved PD-L1 staining results in most of the cell lines postfixed in formalin when stained with the SP263 antibody. It is known that fixation effects may differ between different antibodies that target the same protein, which also was demonstrated in a study by Buonocore et al.²¹ These differences might be explained by the finding that different antibodies targeting the same protein normally target different epitopes.³³ In the case of PD-L1 IHC, the SP263 antibody binds to an epitope in the cytoplasmic domain of PD-L1, whereas the 22C3 antibody binds to the extracellular domain of PD-L1.³⁶ It has been suggested before that this may lead to different tumor cell staining results,³⁷ rendering it plausible that variation in epitopes might also result in different effects of formalin postfixation between antibodies. Perhaps other differences between epitopes, such as the degree of glycosylation, which has been shown to affect the accuracy of IHC staining,³⁸ also could lead to variation in fixation effects between antibodies. It is noteworthy, however, that we only applied 30 minutes of additional formalin fixation in our cell lines, so we cannot exclude the possibility that longer formalin fixation times also might result in a positive effect on PD-L1 immunostaining using the SP263 antibody. In any case, the positive effects of formalin postfixation observed with the 22C3 antibody seem promising. It would be worthwhile to investigate whether additional fixation in formalin after alcohol fixation also results in preserved PD-L1 staining intensity in patient samples using various PD-L1 IHC antibodies and varying fixation times.

Various studies have proposed intratumoral heterogeneity of PD-L1 expression as the cause of disagreement

in PD-L1 immunostaining between histology and cytology.^{9,13,16} In our study, it is possible that PD-L1 intratumoral heterogeneity also played a part in creating discordance between surgical resection specimens and cytology cell blocks, especially in the comparison of histology and agar-based cell blocks. It seems very unlikely, however, that discordance between histology and Cellient cell blocks can be attributed completely to PD-L1 intratumoral heterogeneity because the discordance in these cell blocks was much more pronounced compared with that in the agar cell blocks, and most of the discordant cases (89% and 92% for 22C3LDT and SP263, respectively) showed lower PD-L1 immunostaining on cytology compared with histology. Combined with results from the analysis of our PD-L1-expressing cell lines fixed in different fixatives, a decrease in PD-L1 immunostaining caused by alcohol fixation seems the most likely explanation for the observed discordance.

It should be mentioned that the negative effects of alcohol-based fixatives on PD-L1 immunoreactivity were observed using PD-L1 IHC protocols that were validated for use on FFPE tissue. Altering the immunostaining protocol to optimize its use on cytology specimens fixed in alcohol might result in better staining results. This has been demonstrated before with other IHC antibodies,²⁰ although changing IHC protocols for use on cytologic specimens does not always result in improved immunostaining.^{20,21} Notably, it has also been described that pathologists often use techniques designed for histology on cytologic specimens without considering the differences in specimen preparation and how these differences could affect the interpretation of immunostaining.³⁹ The use of PD-L1 IHC protocols, validated for FFPE tissue, on cytology specimens fixed in alcohol-based fixatives could result in less PD-L1 immunoreactivity and might result in false-negative results.

In conclusion, our study demonstrates the negative effects of methanol-based and ethanol-based fixatives on PD-L1 immunostaining using the SP263 standardized assay, the 22C3 pharmDx assay, and a 22C3 LDT, each validated for use on FFPE tissue specimens. Therefore, if cytologic specimens need to be used for ICC testing of PD-L1 expression, the fixative of choice is formalin. Methanol-based or ethanol-based fixatives should be avoided unless they are used with a meticulously validated ICC protocol that has been designed specifically for use on specimens fixed in these fixatives. Postfixation

in formalin potentially may reverse the negative effect of alcohol fixation to some degree. This preserving effect should be studied in patient samples using various PD-L1 antibodies to assess the applicability of additional formalin fixation after alcohol fixation in clinical practice.

FUNDING SUPPORT

This study was supported by an unrestricted research grant from Roche Diagnostics Nederland BV received by Nils A. 't Hart. The funding source was not involved in the study design; in the collection, analysis, and interpretation of data; in the writing of the report; or in the decision to submit the article for publication.

CONFLICT OF INTEREST DISCLOSURES

Bregje M. Koomen reports grants from AstraZeneca, Merck Sharp & Dohme, and Roche Diagnostics, outside the submitted work. Jan H. von der Thüsen reports personal fees from Merck Sharp & Dohme, during the conduct of the study. Kim Monkhorst reports grants and personal fees from AstraZeneca; personal fees from Merck Sharp & Dohme, Benecke, Bristol-Myers Squibb, AbbVie, Diaceutics, Lilly, Bayer, and Boehringer Ingelheim; personal fees and nonfinancial support from Roche Diagnostics; and nonfinancial support from PGDX, Delfi, and Takeda, all outside the submitted work. Stefan M. Willems reports grants from Bristol-Myers Squibb, NextCure, Pfizer Inc, Roche Diagnostics, Merck Sharp & Dohme, Amgen, AstraZeneca, and Bayer, outside the submitted work. Wim Timens reports personal fees from Roche Diagnostics/Ventana, Merck Sharp & Dohme, Bristol-Myers Squibb, and AbbVie, outside the submitted work. The remaining authors made no disclosures.

AUTHOR CONTRIBUTIONS

Bregje M Koomen: Data curation, formal analysis, methodology, visualization, and writing—original draft. **Jose van der Starre-Gaal:** Formal analysis, and writing—review and editing. **Judith M. Vonk:** Methodology and writing—review and editing. **Jan H. von der Thüsen:** Resources and writing—review and editing. **Jacqueline J. C. van der Meij:** Resources and writing—review and editing. **Kim Monkhorst:** Resources and writing—review and editing. **Stefan M. Willems:** Methodology and writing—review and editing. **Wim Timens:** Conceptualization, methodology, and writing—review and editing. **Nils A. 't Hart:** Conceptualization, data curation, formal analysis, funding acquisition, methodology, resources, and writing—review and editing.

REFERENCES

1. Reck M, Rodriguez-Abreu D, Robinson AG, et al. Pembrolizumab versus chemotherapy for PD-L1-positive non-small-cell lung cancer. *N Engl J Med.* 2016;375:1823-1833.
2. Planchard D, Popat S, Kerr K, et al. Metastatic non-small cell lung cancer: ESMO Clinical Practice Guidelines for diagnosis, treatment and follow-up. *Ann Oncol.* 2018;29(suppl 4):iv192-iv237.
3. European Society for Medical Oncology (ESMO). Metastatic Non-Small-Cell Lung Cancer: ESMO Clinical Practice Guidelines for Diagnosis, Treatment and Follow-Up. ESMO; 2019. Accessed January 10, 2020. <https://www.esmo.org/content/download/227453/3874538/1/ESMO-CPG-mNSCLC-18SEPT2019.pdf>

4. European Medicines Agency (EMA). Imfinzi (durvalumab). EMA; 2018. Accessed April 5, 2019. <https://www.ema.europa.eu/en/medicines/human/EPAR/imfinzi>
5. Jorgensen JT. Companion and complementary diagnostics: clinical and regulatory perspectives. *Trends Cancer*. 2016;2:706-712.
6. Scheerens H, Malong A, Bassett K, et al. Current status of companion and complementary diagnostics: strategic considerations for development and launch. *Clin Transl Sci*. 2017;10:84-92.
7. Teng MWL, Ngiow SF, Ribas A, Smyth MJ. Classifying cancers based on T cell infiltration and PD-L1. *Cancer Res*. 2015;75:2139-2145.
8. Russell-Goldman E, Kravets S, Dahlberg SE, Sholl LM, Vivero M. Cytologic-histologic correlation of programmed death-ligand 1 immunohistochemistry in lung carcinomas. *Cancer Cytopathol*. 2018;126:253-263.
9. Skov BG, Skov T. Paired comparison of PD-L1 expression on cytologic and histologic specimens from malignancies in the lung assessed with PD-L1 IHC 28-8pharmDx and PD-L1 IHC 22C3pharmDx. *Appl Immunohistochem Mol Morphol*. 2017;25:453-459.
10. Skov BG, Hogdall E, Clementsen P, et al. The prevalence of EGFR mutations in non-small cell lung cancer in an unselected Caucasian population. *APMIS*. 2015;123:108-115.
11. Roh MH. The utilization of cytologic fine-needle aspirates of lung cancer for molecular diagnostic testing. *J Pathol Transl Med*. 2015;49:300-309.
12. Ilie M, Juco J, Huang L, Hofman V, Khambata-Ford S, Hofman P. Use of the 22C3 anti-programmed death-ligand 1 antibody to determine programmed death-ligand 1 expression in cytology samples obtained from non-small cell lung cancer patients. *Cancer Cytopathol*. 2018;126:264-274.
13. Noll B, Wang WL, Gong Y, et al. Programmed death ligand 1 testing in non-small cell lung carcinoma cytology cell block and aspirate smear preparations. *Cancer Cytopathol*. 2018;126:342-352.
14. Sakakibara R, Inamura K, Tambo Y, et al. EBUS-TBNA as a promising method for the evaluation of tumor PD-L1 expression in lung cancer. *Clin Lung Cancer*. 2017;18:527-534.e1.
15. Wang H, Agulnik J, Kasymjanova G, et al. Cytology cell blocks are suitable for immunohistochemical testing for PD-L1 in lung cancer. *Ann Oncol*. 2018;29:1417-1422.
16. Hernandez A, Brandler TC, Zhou F, Moreira AL, Schatz-Siemers N, Simsir A. Assessment of programmed death-ligand 1 (PD-L1) immunohistochemical expression on cytology specimens in non-small cell lung carcinoma. *Am J Clin Pathol*. 2019;151:403-415.
17. Nambirajan A, Jain D. Cell blocks in cytopathology: an update. *Cytopathology*. 2018;29:505-524.
18. Gruchy JR, Barnes PJ, Dakin Hache KA. CytoLyt® fixation and decalcification pretreatments alter antigenicity in normal tissues compared with standard formalin fixation. *Appl Immunohistochem Mol Morphol*. 2015;23:297-302.
19. Nietner T, Jarutat T, Mertens A. Systematic comparison of tissue fixation with alternative fixatives to conventional tissue fixation with buffered formalin in a xenograft-based model. *Virchows Arch*. 2012;461:259-269.
20. Sauter JL, Grogg KL, Vrana JA, Law ME, Halvorson JL, Henry MR. Young Investigator Challenge: validation and optimization of immunohistochemistry protocols for use on Cellient cell block specimens. *Cancer Cytopathol*. 2016;124:89-100.
21. Buonocore DJ, Konno F, Jungbluth AA, et al. CytoLyt fixation significantly inhibits MIB1 immunoreactivity whereas alternative Ki-67 clone 30-9 is not susceptible to the inhibition: critical diagnostic implications. *Cancer Cytopathol*. 2019;127:643-649.
22. T Hart NA, van der Starre-Gaal J, Vonk JM, Timens W. Essential preanalytics in PD-L1 immunocytochemistry. *Histopathology*. 2019;74:362-364.
23. Federation of Dutch Medical Scientific Societies (FEDERA). Human Tissue and Medical Research: Code of Conduct for Responsible Use. FEDERA; 2011. Accessed January 15, 2019. https://www.federa.org/sites/default/files/digital_version_first_part_code_of_conduct_in_uk_2011_12092012.pdf
24. HistoCyte Laboratories. PD-L1 Analyte Control Datasheet. Accessed September 16, 2019. http://www.histocyte.com/images/pdf/HCL0019_HCL0020_HCL0021_PI_V003.pdf
25. Adam J, Le Stang N, Rouquette I, et al. Multicenter harmonization study for PD-L1 IHC testing in non-small-cell lung cancer. *Ann Oncol*. 2018;29:953-958.
26. Visiopharm. PD-L1, Cell Lines, Cancer. Accessed September 25, 2020. <https://visiopharm.com/app-center/app/pd-l1-cell-lines-cancer/>
27. John T, Liu G, Tsao MS. Overview of molecular testing in non-small-cell lung cancer: mutational analysis, gene copy number, protein expression and other biomarkers of EGFR for the prediction of response to tyrosine kinase inhibitors. *Oncogene*. 2009;28(suppl 1):S14-S23.
28. Smith J, Robida MD, Acosta K, et al. Quantitative and qualitative characterization of two PD-L1 clones: SP263 and E1L3N. *Diagn Pathol*. 2016;11:44.
29. Landis JR, Koch GG. The measurement of observer agreement for categorical data. *Biometrics*. 1977;33:159-174.
30. Lloyd IE, Zhou W, Witt BL, Chadwick BE. Characterization of PD-L1 immunohistochemical expression in cell blocks with different specimen fixation and processing methods. *Appl Immunohistochem Mol Morphol*. 2019;27:107-113.
31. Gosney JR, Haragan A, Chadwick C, et al. Programmed death ligand 1 expression in EBUS aspirates of non-small cell lung cancer: is interpretation affected by type of fixation? *Cancer Cytopathol*. 2020;128:100-106.
32. Miller RT, Swanson PE, Wick MR. Fixation and epitope retrieval in diagnostic immunohistochemistry: a concise review with practical considerations. *Appl Immunohistochem Mol Morphol*. 2000;8:228-235.
33. Ramos-Vara JA. Technical aspects of immunohistochemistry. *Vet Pathol*. 2005;42:405-426.
34. Dejmek A, Zendeckrohn N, Tomaszewska M, Edsjo A. Preparation of DNA from cytological material: effects of fixation, staining, and mounting medium on DNA yield and quality. *Cancer Cytopathol*. 2013;121:344-353.
35. Torous VF, Rangachari D, Gallant BP, Shea M, Costa DB, VanderLaan PA. PD-L1 testing using the clone 22C3 pharmDx kit for selection of patients with non-small cell lung cancer to receive immune checkpoint inhibitor therapy: are cytology cell blocks a viable option? *J Am Soc Cytopathol*. 2018;7:133-141.
36. Lawson NL, Dix CI, Scorer PW, et al. Mapping the binding sites of antibodies utilized in programmed cell death ligand-1 predictive immunohistochemical assays for use with immuno-oncology therapies. *Mod Pathol*. 2020;33:518-530.
37. Jotatsu T, Oda K, Yatera K. PD-L1 immunohistochemistry in patients with non-small cell lung cancer. *J Thorac Dis*. 2018;10(Suppl 18):S2127-S2129.
38. Lee HH, Wang YN, Xia W, et al. Removal of N-linked glycosylation enhances PD-L1 detection and predicts anti-PD-1/PD-L1 therapeutic efficacy. *Cancer Cell*. 2019;36:168-178.e4.
39. Fowler LJ, Lachar WA. Application of immunohistochemistry to cytology. *Arch Pathol Lab Med*. 2008;132:373-383.