



Case report

Disseminated tuberculosis infection and paradoxical reaction during antimycobacterial treatment related to TNF-alpha blocker agent Infliximab



Mehmet Unlu*, Pinar Cimen, Aysu Ayranci, Tulay Akarca, Onur Karaman, Mustafa Sevkett Dereli

Izmir Training and Research Hospital for Thoracic Medicine and Surgery, Pulmonary Division, 35210 Yenisehir, Izmir, Turkey

A B S T R A C T

Keywords:

TNF-alpha inhibitors
Infliximab
Tuberculosis
Paradoxical response

Tumor necrosis factor (TNF)-alpha inhibitors play an important role in the treatment of immun-mediated diseases such as Crohn's disease. But they also have been related to increased risk for disseminated *Mycobacterium tuberculosis* infections and paradoxical response to antimycobacterial treatment. Here we report a disseminated tuberculosis case and a paradoxical response to treatment after receiving TNF-inhibitor agent Infliximab for Crohn's disease. The patient had a severe clinical condition before the antimycobacterial treatment and although proper treatment was initiated his radiological findings were worsened one month after initiation of the treatment. All control microbiologic tests for secondary infections were negative and this situation was accepted as a paradoxical response to antimycobacterial treatment and treatment was continued with the same regimen. At the end of the second month of the treatment, most of the symptoms disappeared and chest radiograph findings were better than the previous one. In conclusion, TNF-alpha inhibitor therapy increases risk of mycobacterial infections and patients should be examined carefully about tuberculosis before starting this therapy. Also, it is important for physicians to recognize and know how to manage paradoxical response related to TNF-alpha inhibitors during anti-tuberculosis treatment.

© 2014 The Authors. Published by Elsevier Ltd. This is an open access article under the CC BY-NC-SA license (<http://creativecommons.org/licenses/by-nc-sa/3.0/>).

Introduction

Crohn's disease is an idiopathic inflammatory bowel disease, treatment of which consists of administration of high dose mesalazine in mild cases, corticosteroids in moderate to severe cases and immunosuppressives [Tumor necrosis factor (TNF)-alpha blockers, azathioprine, methotrexate] for corticosteroid dependent patients or corticosteroid refractory disease [1,2]. One of the most important side effects of TNF-alpha blockers is an increased risk for reactivation of latent tuberculosis and an increased risk for disseminated tuberculosis infection [3,4]. Besides, there is a phenomenon called as "paradoxical reaction" during the treatment of tuberculosis in which pre-existing lesions worsen or new lesions appear despite of improving symptoms of the patient [5,6]. There are some

published reports in which paradoxical reaction to antimycobacterial treatment was related to discontinuation of TNF-alpha blockers after the diagnosis of an active tuberculosis infection [7].

We report a case of a Crohn's disease patient with disseminated tuberculosis caused by administration of TNF-alpha inhibitor agent Infliximab and paradoxical response to antimycobacterial treatment after this agent was stopped.

Case presentation

A 45-year-old man was referred to our clinic from gastroenterology department of another hospital. He was diagnosed as Crohn's disease in 2007 and treated with mesalazine for 2 years. In 2009, this treatment regime was stopped because of refractory symptoms and azathioprine was administered in combination with oral glucocorticoids. Again because of inadequate control, therapy with Infliximab was initiated in January 2013. After 3 doses of Infliximab therapy, the patient exhibited dyspnea, night sweating and intermittent high fever. Examination of blood

* Corresponding author. Izmir Dr. Suat Seren Göğüs Hastalıkları ve Cerrahisi Eğitim ve Araştırma Hastanesi, 1. Göğüs Hastalıkları Servisi, Gaziler Caddesi, 35210 Yenisehir, Izmir, Turkey. Tel.: +90 232 4333333x2560, +90 507 6507616 (mobile); fax: +90 232 4587262.

E-mail address: lidokain21@hotmail.com (M. Unlu).

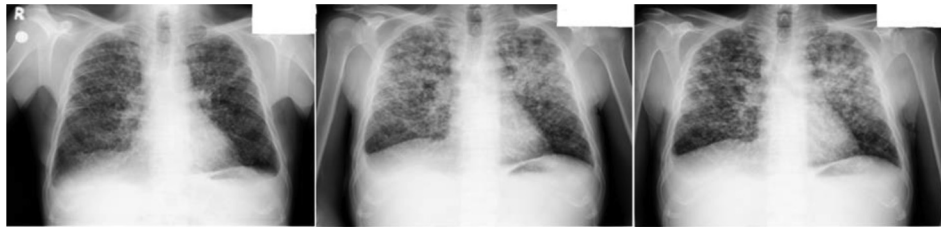


Fig. 1. Chest radiographs of the patient from left to right; on admission, one month after initiation of the treatment, two months after initiation of the treatment.

samples revealed leukopenia ($1800/\text{mm}^3$), neutropenia ($1120/\text{mm}^3$), lymphopenia ($460/\text{mm}^3$) and anemia (haemoglobin: 10.6 g/dl). Number of thrombocytes and results of blood chemistry were within normal limits. Erythrocyte sedimentation rate was 114 mm/h and serum level of C-reactive protein was 12.5 mg/dl . Tuberculin skin test (TST) was measured as 13 mm at the end of 72 h and anti-HIV antibody tests were negative. Chest radiograph findings were including small nodules throughout both lungs which were compatible with miliary tuberculosis (Fig. 1). Computerized Tomography (CT) report was defining granular shadows and multiple nodules with different sizes especially located in the upper and middle zones of the both lungs (Fig. 2). Also there were paratracheal, precarinal, bilateral hilar, aorticopulmonary and subcarinal enlarged lymph nodes whose greatest diameter was measured as 15 mm . According to these images, possible diagnoses were listed as atypical infectious disease, sarcoidosis, miliary tuberculosis, pneumoconiosis and metastatic nodules. After the Haematology consultation, hemogram results of the patient were related to Azathioprine and this drug was discontinued. Also Infliximab was stopped because of high possibility of active tuberculosis infection, with the consultation of gastroenterology. Positron Emission Tomography-Computerized Tomography (PET-CT) was performed and different focuses showed pathological $^{18}\text{-Fluorodeoxyglucose}$ ($^{18}\text{-FDG}$) uptake (several mediastinal lymph nodes $\text{SUV}_{\text{max}} = 7.4$, nodules of the lung parenchyme

$\text{SUV}_{\text{max}} = 6.1$, lymph nodes of the abdomen $\text{SUV}_{\text{max}} = 5.8$, spleen $\text{SUV}_{\text{max}} = 8.9$, supradiaphragmatic lymph nodes and liver $\text{SUV}_{\text{max}} = 5.4$) (Fig. 3). Involvement of the spleen and lymph nodes were also suggesting lymphoma. Endobronchial Ultrasound Bronchoscopy (EBUS) was performed for both isolation of infectious agent and examination of enlarged mediastinal lymph nodes. Subcarinal and lower paratracheal lymph nodes were sampled by EBUS-guided fine needle aspiration biopsy. Pathologic view of the subcarinal lymph node biopsy was consistent with caseating granuloma and *M. tuberculosis* was isolated from both bronchial aspiration fluid and lymph node biopsy sample. So patient was diagnosed as disseminated tuberculosis disease and antimycobacterial treatment was initiated (Isoniazid 300 mg/day , Rifampicin 600 mg/day , Pyrazinamide 1500 mg/day , Ethambutol 1200 mg/day). One month after the initiation of antimycobacterial therapy, symptoms of the patient were decreased but chest radiograph (Fig. 1) and CT scan findings were worsened (Fig. 4). Fiberoptic Bronchoscopy (FOB) was done and bronchoscopic aspiration and bronchoalveolar lavage (BAL) fluids were taken for microbiological tests. All tests were negative for fungal agents, *Pneumocystis jiroveci*, viruses, bacteria and no asido-resistant bacillus was isolated. This situation was accepted as a paradoxical response to antimycobacterial treatment and treatment regimen was not changed. At the end of the second month of the treatment, most of the symptoms disappeared and chest radiograph

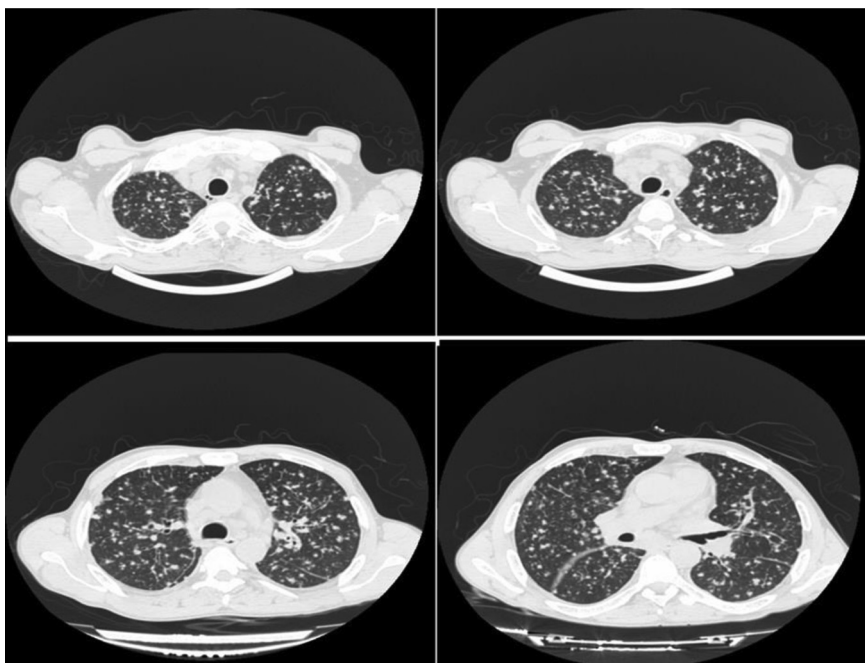


Fig. 2. Thorax-CT images of the patient on admission.

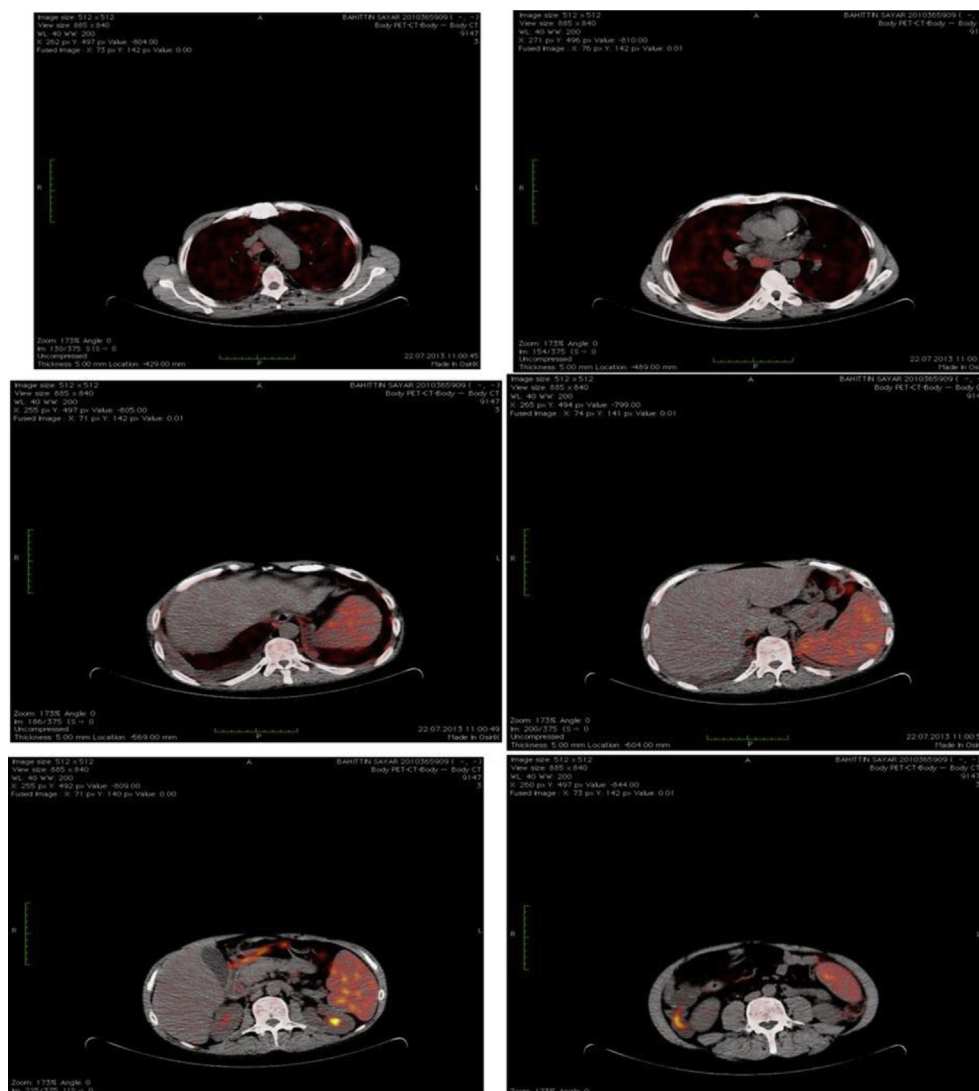


Fig. 3. PET-CT images of the patient.

findings were better than the previous one (Fig. 1). Patient is still under treatment and has a better health condition.

Discussion

We described a disseminated tuberculosis case with paradoxical response to antimycobacterial treatment associated with TNF-alpha neutralizing agent Infliximab.

Despite effectiveness of TNF-alpha inhibitors in treatment of immun-mediated diseases such as Crohn's disease, they also have been related to disseminated tuberculosis infection as a side effect [8]. Because TNF-alpha has a crucial role in protective immunity against *M. tuberculosis* infection and its blockage results with severe mycobacterium infections [9]. That's why, appropriate screening of patients is needed by using TST, a careful medical history of risk factors for tuberculosis and chest radiographs before starting the therapy [10]. Although diameter of 10 mm is accepted for the positiveness of TST in immunocompetent patients, diameter equal to 5 mm or greater should be accepted as a positive result in immunosuppressed patients, as in this case [11]. Immunosuppressed patients should receive chemoprophylaxis with Isoniazid (300 mg/day) for 9 months. An alternative for Isoniazid is

Rifampicin (600 mg/day) for 4 months [12]. Unfortunately, this patient had no chest radiograph and TST before receiving Infliximab therapy.

Keane et al. reported 70 patients who had tuberculosis during and after Infliximab therapy. Seventeen of them had disseminated tuberculosis, median interval from the beginning of the Infliximab therapy until the development of tuberculosis was 12 weeks (range 1–52 weeks) and in 48 patients tuberculosis developed after 3 or fewer infusions [13]. Consistent with their data, patient in this case had received this drug for 3 times in 3 months.

Mechanism of paradoxical response to antimycobacterial treatment is still uncertain. Immunorestitution phenomenon was suggested to explain this response. According this phenomenon, changes in cellular and cytokine patterns after the initiation of antimycobacterial treatment and prompt recovery of the immune system are the reasons of paradoxical reaction. As a result, an overwhelming immunorestitution may produce immunopathological damage at the tissue level [14].

Although discontinuation of TNF-alpha blockers is suggested after the diagnosis of active tuberculosis infection, there are some evidences that this also causes paradoxical response and resumption of TNF-alpha blockers with antimycobacterial

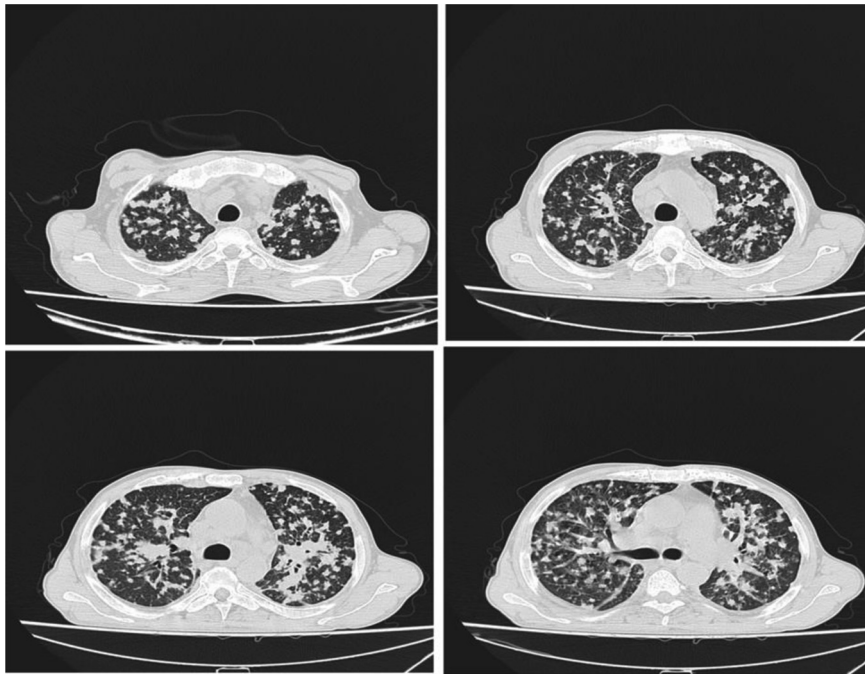


Fig. 4. Thorax-CT images of the patient one month after initiation of the treatment.

treatment has been reported to be effective in a tuberculosis case with paradoxical response [7,15]. Infliximab therapy was stopped in this case.

Paradoxical response occurs in 10–15% of active tuberculosis patients and the median time to the development of paradoxical response is 2 months in HIV-negative patients (from 14 days to 270 days) [16]. In both HIV-negative and positive patients it occurs more frequently with extrapulmonary tuberculosis and associated with lymphopenia at the baseline [17,18]. Age, sex and comorbidities have no relation with this response. Patient in this case had disseminated tuberculosis, low number of lymphocytes on admission and paradoxical response occurred one month after initiation of the treatment.

There are no international guidelines for the treatment of paradoxical response. However, continuation of the same antimycobacterial drugs and administration of corticosteroids are recommended [19]. Besides, secondary infections, inadequate anti-tuberculosis treatment and adverse reactions due to antimycobacterial therapy should be excluded. Generally this response is transient and most of the patients recover with conservative or medical treatment. Corticosteroids were not administered in this case and treatment regimen of the patient was not changed. This patient is still under treatment without a sign of relapse.

In conclusion, TNF-alpha inhibitor therapy increases risk of mycobacterial infections and patients should be examined carefully about tuberculosis before starting this therapy. Also it is important for physicians to recognize and know how to manage paradoxical response related to TNF-alpha inhibitors, during anti-tuberculosis treatment.

Written consent

Written informed consent was obtained from the patient for publication of this case report and accompanying images. A copy of the written consent is available for review by the Editor-in-Chief of this journal.

Author contribution

MU: The conception and design of the study, revision of the article, final approval of the version to be submitted.

PC: Analysis and interpretation of data, drafting the article, final approval of the version to be submitted.

AA: Analysis and interpretation of data, drafting the article, final approval of the version to be submitted.

TA: Analysis and interpretation of data, drafting the article, final approval of the version to be submitted.

OK: Analysis and interpretation of data, drafting the article, final approval of the version to be submitted.

MSD: Analysis and interpretation of data, drafting the article, final approval of the version to be submitted.

References

- [1] Hanauer SB. Inflammatory bowel disease. *N Engl J Med* 1996;334:841–8.
- [2] Hanauer SB, Meyers S. Management of Crohn's disease in adults. *Am J Gastroenterol* 1997;92:559–66.
- [3] Scheinfeld N. A comprehensive review and evaluation of the side effects of the tumor necrosis factor alpha blockers etanercept, infliximab and adalimumab. *J Dermatol Treat* 2004;15:280–94.
- [4] Dimakou K, Papaioannides D, Latsi P, Katsimboula S, Korantzopoulos P, Orphanidou D. Disseminated tuberculosis complicating anti-TNF-alpha treatment. *Int J Clin Pract* 2004;58:1052–5.
- [5] Chloremis CD, Padiatellis C, Zou Mbou Lakis D, Yannakos D. Transitory exacerbation of fever and roentgenographic findings during treatment of tuberculosis in children. *Am Rev Tuberc* 1955;72:527–36.
- [6] Silver CP, Steel SJ. Mediastinal lymphatic gland tuberculosis in Asian and coloured immigrants. *Lancet* 1961;1:1254–6.
- [7] Garcia Vidal C, Rodríguez Fernández S, Martínez Lacasa J, Salavert M, Vidal R, Rodríguez Carballeira M, et al. Paradoxical response to antituberculous therapy in infliximab-treated patients with disseminated tuberculosis. *Clin Infect Dis* 2005;40:756–9.
- [8] Sandborn WJ, Hanauer SB, Katz S, Safdi M, Wolf DG, Baerg RD, et al. Etanercept for active Crohn's disease: a randomised, double blind, placebo-controlled trial. *Gastroenterology* 2001;121:1088–94.
- [9] Ehlers S, Benini J, Kutsch S, Endres R, Rietschel ET, Pfeffer K. Fatal granuloma necrosis without exacerbated mycobacterial growth in tumour necrosis factor receptor p 55 gene-deficient mice intravenously infected with *Mycobacterium avium*. *Infect Immun* 1999;67:3571–9.

- [10] Chang J, Girgis L. Clinical use of anti TNF- α biological agents. A guide for GPs. *Aust Fam Phys* 2007;36:1035–8.
- [11] Murdaca G, Colombo BM, Puppo F. Anti-TNF-alpha inhibitors: a new therapeutic approach for inflammatory immune-mediated diseases: an update upon efficacy and adverse events. *Int J Immunopathol Pharmacol* 2009;22: 557–65.
- [12] T. C. Sağlık Bakanlığı Tüberküloz Tanı ve Tedavi Rehberi. 2011. Available at: <http://tuberkuloz.thsk.saglik.gov.tr/bilgi-dokumanlar/kitaplar/805-tuberkuloz-tani-ve-tedavi-rehberi.html>. [access date: 2012].
- [13] Keane J, Gershon S, Wise RP, Mirabile-Levens E, Kasznica J, Schwieterman WD, et al. Tuberculosis associated with infliximab, a tumour necrosis factor alpha-neutralizing agent. *N Engl J Med* 2001;345:1098–104.
- [14] Cheng VC, Yueng KY, Chan VM, Wong SS, Ma ES, Chan RM. Immunorestitution disease involving the innate and adaptive response. *Clin Infect Dis* 2000;30: 882–92.
- [15] Matsumoto T, Tanaka T, Kawase I. Infliximab for rheumatoid arthritis in a patient with tuberculosis. *N Engl J Med* 2006;355:740–1.
- [16] Cheng VC, Ho PL, Lee RA, Chan KS, Chan KK, Woo PC, et al. Clinical spectrum of paradoxical deterioration during antituberculosis therapy in non- HIV-infected patients. *Eur J Clin Microbiol Infect Dis* 2002;21:803–9.
- [17] Cheng VC, Yam WC, Woo PC, Lau SK, Hung IP, Wong SF, et al. Risk factors for development of paradoxical response during antituberculosis therapy in-HIV-negative patients. *Eur J Clin Microbiol Infect Dis* 2003;22:597–602.
- [18] Wendel KA, Alwood KS, Gachuhi R, Chaisson RE, Bishai WR, Sterling TR. Paradoxical worsening of tuberculosis in HIV- infected persons. *Chest* 2001;120:193–7.
- [19] Jung JW, Shin JW, Kim JY, Park IW, Choi BW, Seo JS, et al. Risk factors for development of paradoxical response during anti-tuberculosis treatment in HIV-negative patients with pleural tuberculosis. *Tohoku J Exp Med* 2011;223: 199–204.