

Asymptomatic dural ectasia in neurofibromatosis-1: A case report

Received: 10 June 2021
Accepted: 07 Aug. 2021

Ali Razmkon^{1,2}, Saeed Abdollahifard^{1,2}, Omid Yousefi¹, Hiran Rezaei^{1,3}

¹ Research Center for Neuromodulation and Pain, Shiraz, Iran

² Unite de Recherche Clinique du Centre Hospitalier Henri Laborit, Poitiers, France

³ Student Research Committee, Shiraz University of Medical Sciences, Shiraz, Iran

Keywords

Neurofibromatosis; Dura Matter; Ectasia; Low Back Pain

Neurofibromatosis-1 (NF1) is a multisystem genetic disorder that affects approximately 1 in 3000 individuals, can be inherited in an autosomal dominant pattern, and can be developed with spontaneous mutations. As it can affect many organs, NF1 has various signs and symptoms from skin manifestation (such as cafe-au-lait spots or axillary/inguinal freckling) to neurobehavioral disorders (such as attention deficit hyperactivity disorder, or autism spectrum disorder). NF1 can also affect the musculoskeletal system, and develop conditions such as kyphoscoliosis, vertebral body scalloping, and dural ectasia.^{1,2}

Dural ectasia, defined as the ballooning of the dural sac around the spinal cord, is mostly associated with Marfan syndrome, ankylosing spondylitis, Ehlers-Danlos syndrome, and NF1. Currently, there is no definite explanation about the pathophysiology of dural ectasia in these aforementioned conditions.³

A 21-year-old woman was referred to our

center with moderate low back pain and an abnormal imaging study. She had no other complaints such as radicular pain or any motor or sensory deficits.

Although physical exam did not reveal any relevant neurological findings in the lower back and extremities, magnetic resonance imaging (MRI) demonstrated strange anomalies in the lumbar area involving L1-L4 vertebral bodies, including vertebral body scalloping and wedging. On further examination, we found axillary freckling and multiple different-size café-au-lait spots in her back. Moreover, a positive family history of neurofibromatosis was noted in her brother. Eventually, due to lack of significant symptoms or neurological deficits and an acceptable spinal curvature, no operative treatment was considered, and the patient responded satisfactorily to the conservative treatment (Figure 1, A and B).

How to cite this article: Razmkon A, Abdollahifard S, Yousefi O, Rezaei H. Asymptomatic dural ectasia in neurofibromatosis-1: A case report. *Curr J Neurol* 2021; 20(4): 246-7.

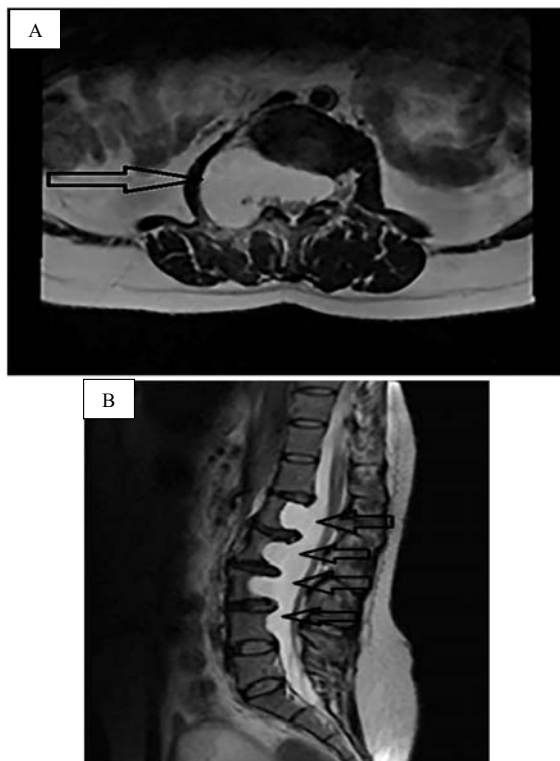


Figure 1. Magnetic resonance imaging (MRI) study of the patient; A: T2-weighted axial section of L2 vertebra shows severe dural ectasia, lateral meningocele formation; and posterior body scalloping; B: T2-weighted mid-sagittal section of the lumbosacral spine showing dural ectasia and posterior body scalloping despite acceptable sagittal balance at L1-L4

Dural ectasia is -the expansion of the dural sac- mostly seen in Marfan syndrome and NF1.³ Lateral meningocele is reported to form after dural ectasia in NF-1 cases, and these malformations are usually seen in the thoracic area.⁴ In our patient, lateral meningocele was formed at the L1-L2 levels at the right side (Figure 1). In our patient, vertebral bodies and laminae were both affected. Laminal involvement may cause foraminal expansion; this may be why patients do not manifest neurological deficits at the onset of spinal involvement. Scalloping of the vertebral bodies makes them prone to compression fractures or curvature changes. Being symptomatic is the only indication for surgical treatment.⁵ In a case series of 37 patients diagnosed with NF 1, most of the patients were treated without surgery, and had no symptoms before the diagnosis of dural ectasia.³ Similarly, we managed the case without surgical intervention. Annual radiographic follow-up is also required to evaluate any exacerbation of spinal deformity and further need for surgical interventions.

Conflict of Interests

The authors declare no conflict of interest in this study.

Acknowledgments

None.

References

1. Gutmann DH, Ferner RE, Listerick RH, Korf BR, Wolters PL, Johnson KJ. Neurofibromatosis type 1. *Nat Rev Dis Primers* 2017; 3: 17004.
2. Adil A, Koritala T, Singh AK. Neurofibromatosis type 1. In: StatPearls [Internet]. Treasure Island, FL: StatPearls Publishing; 2021.
3. Polster SP, Dougherty MC, Zeineddine HA, Lyne SB, Smith HL, MacKenzie C, et al. Dural Ectasia in neurofibromatosis 1: Case series, management, and review. *Neurosurgery* 2020; 86(5): 646-55.
4. Tubbs RS, Oakes WJ. Dural ectasia in neurofibromatosis. *Pediatr Neurosurg* 2002; 37(6): 331-2.
5. Das P, Goyal T, Hunt MA. Intrathoracic meningocele associated with neurofibromatosis Type 1 and a novel technique for surgical repair: Case report. *J Neurosurg Spine* 2017; 27(3): 291-4.