

# Removal of self expandable metallic airway stent: A rare case report

Rakesh K. Chawla, Arun Madan<sup>1</sup>, Ishwar Singh<sup>2</sup>, Rahul Mudoiya, Aditya Chawla, Radha Gupta<sup>2</sup>, Kiran Chawla, Roopam Chhabra<sup>2</sup>

Department of Respiratory Medicine, Critical Care and Sleep Medicine, <sup>2</sup>Department of Anaesthesia, Jaipur Golden Hospital, Rohini, Delhi, <sup>1</sup>Department of Pulmonary Medicine, Sharda Medical College and Hospital, Noida, Uttar Pradesh, India

## ABSTRACT

Covered self expandable metallic airway stents (SEMS) have been used for benign tracheal stenosis, post intubation tracheal stenosis, tracheal burn or trauma, tracheo-broncho-malacia, and extrinsic compression of trachea. Their placement is considered to be permanent, with open surgery the only way to remove the stent, though there are few cases reports of their removal with the bronchoscope, but the complications after their removal are very high. In our patient, one and a half years after placement of SEMS, she developed cough with dyspnoea, video bronchoscopy showed stenosis above the level of stent with granulation tissue inside the stent, stent fracture in lower part and stent migration to right main bronchus, thus she had all conceivable complications of stent placement. The stent was removed with the help of rigid bronchoscope under general anaesthesia. She was discharged the following day. The case is being reported because it was unique in having all the possible complications of stent placement, and rare as we could take out the stent *in Toto*. Thirdly, the stent could be removed without any complication.

**KEY WORDS:** Granulation tissue inside the stent, stenosis above the stent, stent fracture, stent migration

**Address for correspondence:** Dr. Rakesh K. Chawla, Chawla Respiratory, Allergy, Sleep Disorders and Research Centre, 58 - 59/C-12/Sector-3, Rohini, Delhi - 110 085, India. E mail: chawla.rakesh@rediffmail.com

## INTRODUCTION

Indications for covered Self-Expandable Metallic Airway Stent removal include recurrent mucous plugging of the stent, excessive or recurrent granuloma formation, migration of the stent, stent infection, recurrence of stenosis, stent failure, stent fractures and accomplishment of treatment.<sup>[1,2]</sup> Usually, it is tedious to remove a stent because of their embedding in the bronchial mucosa and epithelization of the inner surface. Granuloma formation at the extremities is a relative common occurrence in covered metallic stents possibly resulting from the radial force applied against the airway wall and the friction exerted. We report a case of covered self expandable metallic stent removal with a rigid bronchoscope under general

anesthesia. The case is unique because it had almost all the common complications associated with the stent placement but it was successfully removed without much ado. To the best of our knowledge this is the first case of successful removal of a complete stent reported from India.

## CASE REPORT

A 21 year old female presented with complaints of increasing dyspnoea and cough with pain chest for last two weeks. Patient had a past history of benign tracheal stenosis which was opened up by endobronchial electro surgery followed by placement of a self expandable metallic airway covered stent. X-Ray chest done one and a half year back showed stent well in place [Figure 1].

Bronchoscopy was done under local anesthesia and a stenosis was observed well above the level of the stent [Figure 2] with granulation tissue inside the stent [Figure 3], lower end of the stent was fractured, Carina was not visualized and stent was seen entering upper part of right main bronchus [Figure 4]. Endobronchial electro-surgery was done and the stenotic segment

### Access this article online

Quick Response Code:

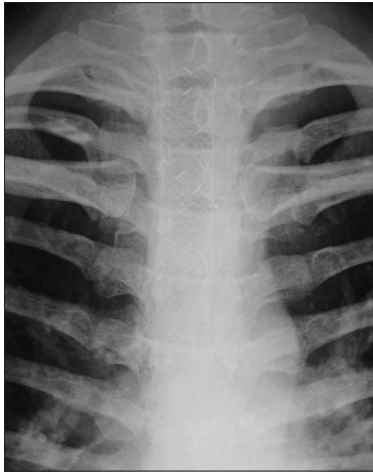


Website:

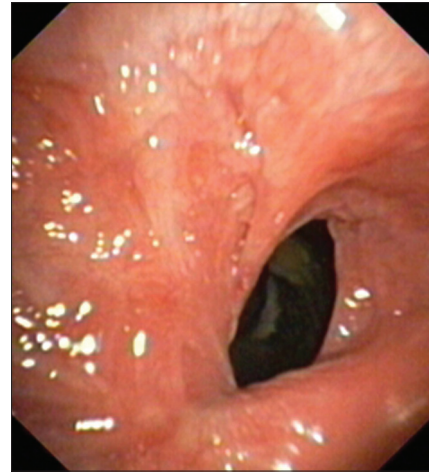
www.lungindia.com

DOI:

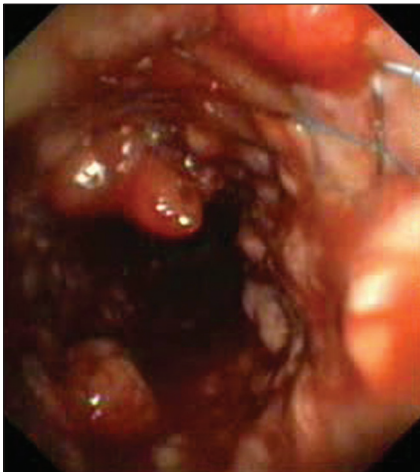
10.4103/0970-2113.106177



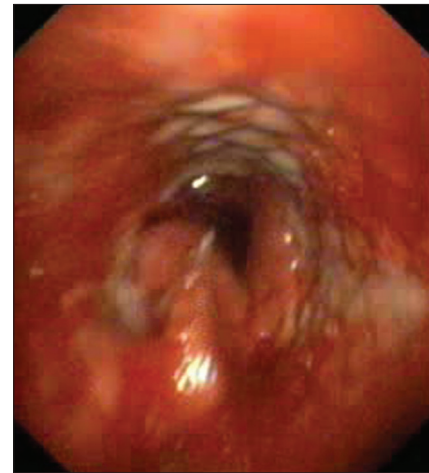
**Figure 1:** X-Ray chest done one and a half year back showing stent well in place



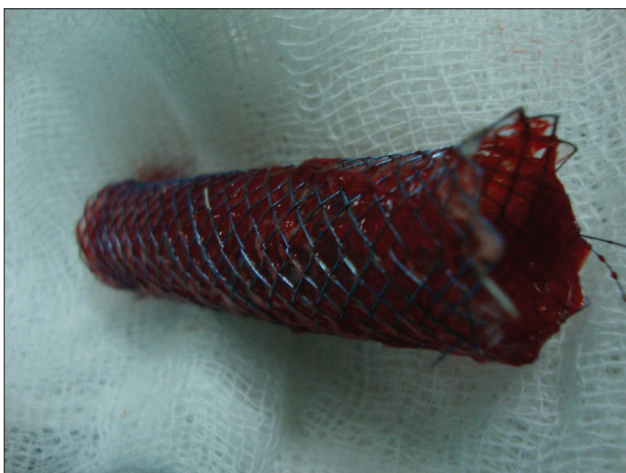**Figure 2:** Stenosis above the level of the stent



**Figure 3:** Granulation tissue inside the stent and at the margins



**Figure 4:** Fracture of stent at its lower end (Stent is seen at upper part of right main bronchus, carina is not visualized)



**Figure 5:** The stent after removal

was dilated. Patient's vigorous cough persisted, so it was decided to remove the stent. Patient was shifted to Operation theatre and rigid bronchoscopy was done under GA. The beveled edge of the rigid scope was

advanced between the stent wall and the airway mucosa thus creating a space between them. The circular extraction loop at the upper end of the metallic stent was grasped with a rigid optical alligator forceps and pulled in the lumen of rigid bronchoscope with continuous winding movements gradually separating the stent from the tracheal wall. Immediately after that, total assembly with forceps was removed and stent isolated [Figure 5]. Patient's cough got relieved significantly and she was discharged the following day. This is one of the rare cases of successful removal of Self Expandable Metallic Airway Covered Stent in benign tracheal stenosis.

## DISCUSSION

The management of patients with tracheal/bronchial strictures of benign etiology can be quite challenging. Though surgical tracheal sleeve resection and reconstruction remains the Gold Standard for most benign airway strictures, non-surgical modalities such as laser photocoagulation and resection, balloon dilatation, electrocautery and stenting of the airway have been

developed to deal with airway stenosis. Various inoperable benign airway disorders are considered for airway stenting, like post intubation tracheal stenosis, tracheal burn or trauma, tracheo-broncho-malacia and extrinsic compression of trachea. Though Silicone prostheses are considered to be first choice in benign diseases their use is less suited, especially in airway wall malacia or distal and angular stenosis where SEMS are preferred. The disadvantages of the silicone stents are high migration rate, small lumen to wall thickness ratio and difficulty in clearing the secretions. On the other hand, the major drawback for placement of SEMS in benign situations is their difficult repositioning and removal in situations like excessive granulation tissue, stent fractures and stent migration. The complications of stent removal include significant oozing, tracheal mucosal dehiscence, tracheal puncture requiring thoracotomy, retained stent pieces, need for restenting, respiratory failure, tracheotomy, and even death.<sup>[2]</sup> In our case, no such complication took place.

Various authors have come up with different methods of removal of the stent, like the technique of Nashef *et al.*,<sup>[3]</sup> which was similar to that of rolling spaghetti on a fork, but much more difficult and at least equally messy. They further observed that there may be several fractures of the stent, which have to be removed piece by piece. In our case, we were able to remove the stent in one piece. Filler *et al.*,<sup>[4]</sup> used a metal suction catheter to dissect the stent from the airway wall before extraction with the forceps. Zakaluzny *et al.*,<sup>[5]</sup> employed a rigid suspension laryngotracheoscope and used optical forceps to dissect the stent from the airway wall. Alligator forceps were then employed to grasp and extract the stent through the rigid scope while the scope was advanced further into the airway. We first separated the stent from the tracheal wall

and then removed all the works (scope, forceps and the stent) in one piece.

To conclude, this case is unique for many reasons, Firstly, it had almost all of the complications that can be associated with stent placement (stenosis of trachea at the upper end of the stent, extensive granuloma formation, migration of the stent downwards and fracture of the stent at its lower end), secondly, we were able to remove the stent in Toto [Figure 5] and lastly, there were no complications after removal of the stent.

Further studies are needed to re evaluate their removal successfully and safely and to produce better designed and technically superior stents like bio-absorbable stents which may not have to be removed at all.

## REFERENCES

1. Noppen M, Stratakos G, D'Haese J, Meysman M, Vinken W. Removal of covered self-expandable metallic airway stents in benign disorders: Indications, technique, and outcomes. *Chest* 2005;127:482-7.
2. Lunn W, Feller-Kopman D, Wahidi M, Ashiku S, Thurer R, Ernst A. Endoscopic removal of metallic airway stents. *Chest* 2005;127:2106-12.
3. Nashef SA, Dromer C, Velly JF, Labrousse L, Couraud L. Expanding wire stents in benign tracheobronchial disease: Indications and complications. *Ann Thorac Surg* 1992;54:937-40.
4. Filler RM, Forte V, Chait P. Tracheobronchial stenting for the treatment of airway obstruction. *J Pediatr Surg* 1998;33:304-11.
5. Zakaluzny SA, Lane JD, Mair EA. Complications of tracheobronchial airway stents. *Otolaryngol Head Neck Surg* 2003;128:478-88.

**How to cite this article:** Chawla RK, Madan A, Singh I, Mudoiya R, Chawla A, Gupta R, *et al.* Removal of self expandable metallic airway stent: A rare case report. *Lung India* 2013;30:64-6.

**Source of Support:** Nil, **Conflict of Interest:** None declared.