

# Respiratory manifestation of yellow nail syndrome: a case report and literature review

Journal of International Medical Research

49(12) 1–6

© The Author(s) 2021

Article reuse guidelines:

[sagepub.com/journals-permissions](https://sagepub.com/journals-permissions)

DOI: 10.1177/03000605211063313

[journals.sagepub.com/home/imr](https://journals.sagepub.com/home/imr)**Shan Xu and Xiaohong Wu** 

## Abstract

Yellow nail syndrome (YNS) is a rare disorder, and diagnosis is based on the clinical findings and the exclusion of other possible causes; the pathogenesis is poorly understood. YNS can be an isolated condition or associated with other diseases; however, YNS associated with multiple myeloma (MM) is rare. A 53-year-old male patient presented with coughing and shortness of breath, and he was diagnosed with YNS with MM. He underwent chemotherapy and achieved a good response. Although the etiology of YNS remains unknown, treating the underlying disease may help prevent or relieve the clinical signs.

## Keywords

Respiratory system, pleural effusion, yellow nail syndrome, multiple myeloma, clinical signs, etiology

Date received: 23 February 2021; accepted: 11 November 2021

## Background

Yellow nail syndrome (YNS) is a rare disorder that involves the combination of yellow nails, lymphedema, and pleural effusion.<sup>1</sup> The diagnosis is based on the clinical findings and the exclusion of other possible causes, and the pathogenesis is poorly understood. Some researchers have suggested that YNS is caused by an abnormality in the lymphatic vessels. YNS was first reported in 1927 by Heller,<sup>2</sup> and can present as either an isolated condition or in association with other diseases,<sup>3,4</sup>

such as malignancies, immunodeficiencies, and rheumatic disease. However, YNS associated with multiple myeloma (MM) is rare.

---

Department of Respiratory Medicine, Sir Run Run Shaw Hospital, Medical School of Zhejiang University, Hangzhou, China

### Corresponding author:

Xiaohong Wu, Department of Respiratory medicine, Sir Run Run Shaw Hospital, Medical School of Zhejiang University, 3 East Qingchun Road, Hangzhou, Zhejiang 310016, China.

Email: [3192018@zju.edu.cn](mailto:3192018@zju.edu.cn)



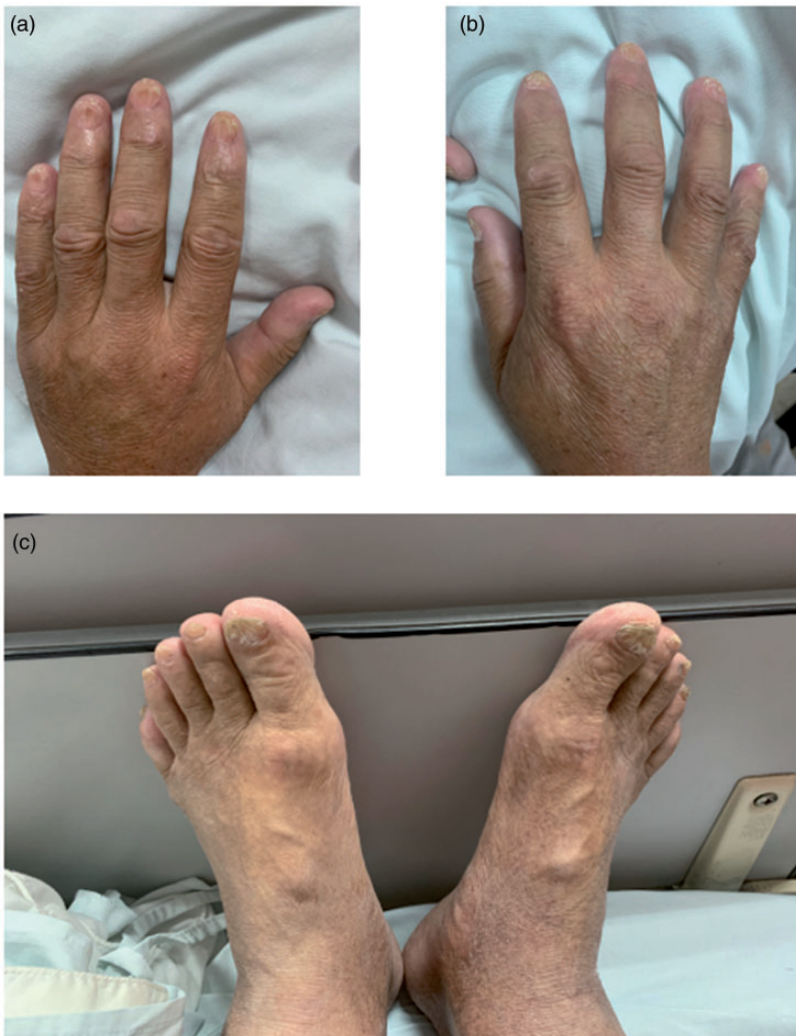Creative Commons Non Commercial CC BY-NC: This article is distributed under the terms of the Creative

Commons Attribution-NonCommercial 4.0 License (<https://creativecommons.org/licenses/by-nc/4.0/>) which permits non-commercial use, reproduction and distribution of the work without further permission provided the original work is attributed as specified on the SAGE and Open Access pages (<https://us.sagepub.com/en-us/nam/open-access-at-sage>).

### **Case summary**

A 53-year-old nonsmoking male patient presented with coughing and shortness of breath for 2 months. His medical and family history were unremarkable, and he denied infection, bronchitis, diabetes, and heart disease. Physical examination revealed multiple areas of edema, especially on the lower limbs and the chest wall, but

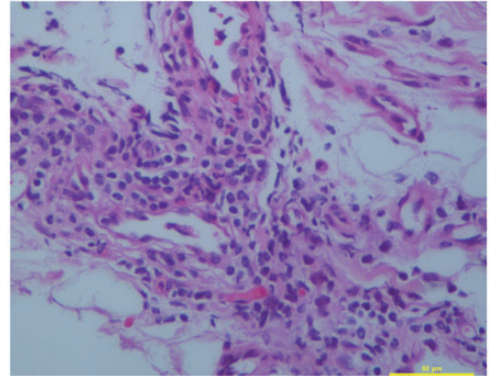
there was no evidence of cardiac failure. His lower lobe respiratory sounds were faint, and chest percussion revealed dullness. His fingernails and toenails appeared yellow and thickened with excessive curvature and onycholysis (Figure 1). B-mode ultrasonography showed bilateral pleural effusion (Figure 2a,b) and multiple areas of edema on the chest wall, neck, and in the axillae, and chest computed tomography



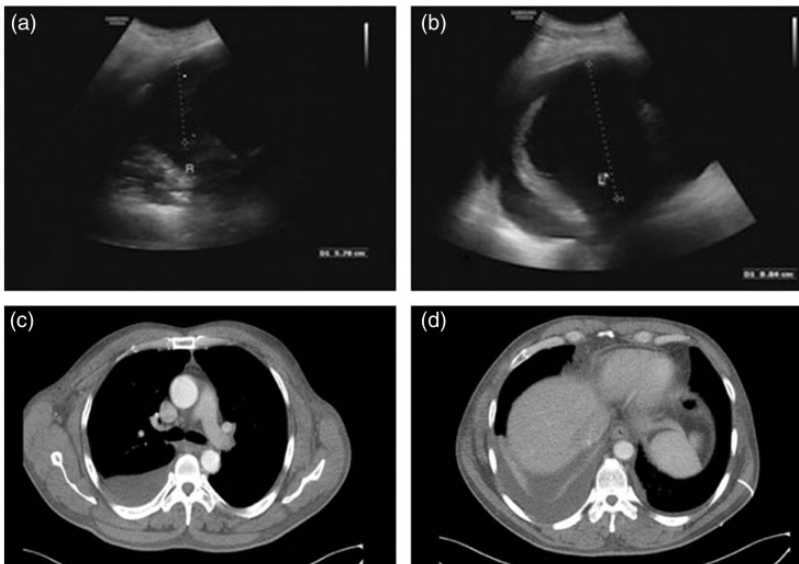
**Figure 1.** Photographs of the patient's hands and feet showing (a) left fingernails; (b) right fingernails; (c) toenails.

(CT) revealed pleural effusion (Figure 2c,d). The results of testing for human immunodeficiency virus (HIV), hepatitis B virus surface antigen (HBsAg), anti-nuclear antibody, anti-neutrophil cytoplasmic antibody, and lung cancer indicators were negative. Thoracentesis revealed an exudate with a protein concentration of 31 g/L, adenosine deaminase concentration of 208.38 nkat/L, and lactate dehydrogenase concentration of 13,200 ukat/L. Test results for pleural chylous effusion were moderately positive, and cultures of the pleural effusion for bacteria, tuberculosis, and fungi were negative. Medical thoracoscopy was performed, and histopathology of the pleural biopsy revealed chronic nonspecific inflammation (Figure 3). According to the yellow nails, lymphedema, bilateral pleural effusion, and the negative results of investigations for other causes, the patient was diagnosed with YNS. He underwent continuous external drainage, and he received diuretics, vitamin E, and octreotide

long-acting repeatable (lar) therapy. His clinical symptoms improved slightly, but the daily drainage volume still exceeded 250 mL. Twenty-four-hour urinary protein quantitation was performed because routine urinalysis showed a urine protein of 1+ (normal: negative). The protein



**Figure 3.** Hematoxylin and eosin (HE)-stained photomicrograph showing chronic nonspecific inflammation (scale bar: 50 mm).



**Figure 2.** Imaging findings confirming pleural effusion: (a) color duplex ultrasonography image showing right pleural effusion; (b) light pleural effusion; (c, d) chest computed tomography (CT) images showing pleural effusion and left chest drainage.

quantitation result was 1.8157 g/day (normal: 0–0.15 g/day). Moreover, monoclonal (M) protein was detected by serum free light chain (FLC) analysis, and bone marrow aspiration and biopsy showed 26% involvement of lambda light chain-restricted plasma cells with a labeling index of 0.4%. The final diagnosis was YNS with light-chain MM, and chemotherapy was initiated after the patient was transferred to the hematology department. Six weeks later, the patient's clinical symptoms had improved significantly, the soft tissue edema had resolved, and the pleural effusion was effectively controlled.

## Discussion

YNS is an uncommon disorder characterized by yellow nails without a cuticle or lunula,<sup>3,5</sup> lymphedema, and pulmonary manifestations, which was added to the diagnostic criteria by Emerson in 1966. Pulmonary manifestations may include chronic cough, bronchiectasis, and pleural effusion.<sup>3,5</sup> In previous studies, the most frequent pulmonary manifestation was chronic cough (56%), followed by pleural effusion (14%–46%), bronchiectasis (44%), chronic sinusitis (41%), and recurrent pneumonia (22%).<sup>6</sup> Diffuse panbronchiolitis and cystic lesions are observed rarely in YNS patients.<sup>7,8</sup> Our patient presented with coughing and shortness of breath and denied infection and bronchitis, and chest CT revealed pleural effusion without pneumonia or bronchiectasis.

Most cases of YNS are sporadic, but the condition can be inherited as an autosomal dominant or recessive trait.<sup>9</sup> We performed clinical whole-exome sequencing, and the results were negative. YNS was first reported in 1927 by Heller,<sup>2</sup> and it is associated with a variety of diseases,<sup>3,4</sup> including immunodeficiencies and autoimmune diseases, such as rheumatoid arthritis, and the condition may be induced by certain

drugs,<sup>3</sup> such as penicillamine, gold, bucillamine, methotrexate, and tiopronine.<sup>10</sup> Among these drugs, bucillamine is most common in drug-induced YNS, especially in rheumatoid arthritis, followed by penicillamine. Most of the drugs that may induce YNS belong to the thiol group of drugs, which may be associated with the pathogenesis because of their special characteristic structure.<sup>11,12</sup> In the current case, the patient's medical history was unremarkable, no drugs with the potential to cause YNS were used, and the concentrations of connective tissue disease markers, such as anti-nuclear antibody and anti-neutrophil cytoplasmic antibody, were normal. As other causes, YNS may also be associated with malignancies, such as solid tumors, including lung cancer and breast cancer. Hematologic malignancies have also been reported, but all of these reports were associations with lymphoma.<sup>3</sup> YNS associated with MM is rare. We report a case in which a patient was diagnosed with YNS and MM. The patient initially responded poorly to routine treatments for YNS, such as diuretics, vitamin E, and octreotide therapy. However, he responded well to chemotherapy, which is a treatment for MM. His clinical symptoms improved significantly with chemotherapy, and the pleural effusion was effectively controlled. According to the findings in this patient, we considered whether YNS was secondary to MM.

The etiology of YNS is still unknown. Lymphatic impairment, which could be innate or acquired, may explain the clinical symptoms. Microvasculopathy is another condition with increased capillary permeability that could also cause clinically-similar disorders.<sup>13</sup> A typical characteristic feature of MM is the production of a monoclonal immunoglobulin that could induce or aggravate lymphatic impairment or disrupt the microvascular environment through abnormal angiogenesis and

plasma cell infiltration into the organs.<sup>14</sup> This could explain the remarkable relief of clinical symptoms after chemotherapy in our patient, and we hope that clinical trials evaluating this therapy can be performed in the future.

## Conclusion

YNS is rare, and very little information regarding YNS associated with MM has been reported. The etiology of YNS remains unknown. Treating the underlying disease may help prevent or relieve the clinical signs of YNS.<sup>15,16</sup>

## Acknowledgements

We thank Xiaoling Xu from Sir Run Run Shaw Hospital, Medical School of Zhejiang University for participating in discussions and critically revising this report for important intellectual content.

## Declaration of conflicting interest

The authors declare that there is no conflict of interest.

## Ethics statement

Ethical approval was not required by our institution because we treated the patient according to an established regimen. The patient's records were obtained during routine clinical treatment, which did not affect his privacy or health. Written informed consent was obtained from the patient for the treatment and publication of this case report and any accompanying images.

## Funding

The authors disclosed receipt of the following financial support for the research, authorship, and publication of this article: This study was supported by a research grant (2020KY591) from the Medical and Health Research Project of Zhejiang Province and a grant (LQ18H010001) from the Natural Science Foundation of Zhejiang Province.

## ORCID iD

Xiaohong Wu  <https://orcid.org/0000-0002-7377-0714>

## References

1. Runyon BA, Forker EL and Sopko JA. Pleural-fluid kinetics in a patient with primary lymphedema, pleural effusions, and yellow nails. *Am Rev Respir Dis* 1979; 119: 821–825.
2. Samman PD and White WF. The yellow nail syndrome. *Br J Dermatol* 1964; 76: 153–157.
3. Maldonado F and Ryu JH. Yellow nail syndrome. *Curr Opin Pulm Med* 2009; 15: 371–375.
4. Gupta S, Samra D, Yel L, et al. T and B cell deficiency associated with yellow nail syndrome. *Scand J Immunol* 2011; 75: 329–335.
5. Wang M and Colegio OR. Nail changes, lymphedema, and respiratory symptoms. *JAAD Case Rep* 2019; 5: 773–775.
6. Maldonado F, Tazelaar HD, Wang CW, et al. Yellow nail syndrome: analysis of 41 consecutive patients. *Chest* 2008; 134: 375–381.
7. Imai R, Nakatani R, Nakaoka H, et al. Yellow nail syndrome patients with diffuse panbronchiolitis-like pulmonary manifestation. *Intern Med* 2019; 58: 553–556.
8. Sacco O, Fregonese B, Marino CE, et al. Yellow nail syndrome and bilateral cystic lung disease. *Pediatr Pulmonol* 1998; 26: 429–433.
9. Hoque SR, Mansour S and Mortimer PS. Yellow nail syndrome: not a genetic disorder? Eleven new cases and a review of the literature. *Br J Dermatol* 2007; 156: 1230–1234.
10. David-Vaudey E, Jamard B, Hermant C, et al. Yellow nail syndrome in rheumatoid arthritis: a drug-induced disease? *Clin Rheumatol* 2004; 23: 376–378.
11. Mishra AK, George AA, L. Yellow nail syndrome in rheumatoid arthritis: an aetiology beyond thiol drugs. *Oxf Med Case Reports* 2016; 3: 37–40.
12. Yamamoto T and Yokozeki H. Yellow nails under bucillamine therapy for rheumatoid arthritis: a report of two cases. *Rheumatol Int* 2007; 27: 603–604.

13. Alessandro AD, Muzi G, Monaco, A, et al. Yellow nail syndrome: does protein leakage play a role? *Eur Respir J* 2001; 17: 149–152.
14. Vacca A, Ria R, Ribatti D, et al. A paracrine loop in the vascular endothelial growth factor pathway triggers tumor angiogenesis and growth in multiple myeloma. *Haematologica* 2003; 88: 176–185.
15. Iqbal M, Rossoff LJ, Marzouk KA, et al. Yellow nail syndrome: resolution of yellow nails after successful treatment of breast cancer. *Chest* 2000; 117: 1516–1518.
16. Grégoire C, Guiot J, Vertenoil G, et al. Yellow nail syndrome after allogeneic hematopoietic stem cell transplantation in two patients with multiple myeloma. *Acta Clin Belg* 2016; 6: 1–3.