

Surgery for intra-abdominal abscess due to intestinal perforation caused by toothpick ingestion

Two case reports

Dae Ro Lim, MD, Jung Cheol Kuk, MD, Taehyung Kim, MD, Eung Jin Shin, MD*

Abstract

Rationale: Failure to pass through the gastrointestinal tract can result in inflammatory response, reactive fibrosis, and intestinal perforation. Fish bones, chicken bones, and toothpicks are the most common types of foreign substances that produce intestinal perforation during ingestion.

Patient concerns: Case 1: A 49-year-old female was hospitalized with abdominal pain and a fever. The fever lasted for 5 days before hospitalization. Case 2: A 72-year-old male was hospitalized with abdominal pain and fever. The fever lasted for 4 days before hospitalization.

Diagnoses: Case 1: An abdominal pelvic computed tomography (APCT) scan revealed a large inflammatory mass formation and linear high-density material within the inflammatory mass. The presence of foreign bodies, including acupuncture needles or intrauterine devices was ruled out. Case 2: An APCT scan revealed that there was a small abscess formation measuring about 2.5 cm abutting the abdominal wall and a parasitic infestation was ruled out.

Interventions: Case 1: An exploratory laparotomy was performed. After removal of the abscess pocket, the sigmoid colon was found to be perforated, and there was a firm, sharp foreign body in the abscess pocket that measured about 5 cm and resembled a toothpick. Case 2: Laparoscopic exploration was then performed. When the abscess was removed from the abdominal wall using a harmony scalpel, a 4 cm foreign body that resembled a toothpick appeared in the abscess pocket.

Outcomes: The patients recovered well after surgery and were discharged.

Lessons: Two of the above case reports describe the cases in which the presence of toothpicks was suspected clinically, resulting in the surgery of intra-abdominal abscess caused by intestinal perforations.

Abbreviations: APCT = abdominal pelvic computed tomography, CT = computed tomography, Hs-CRP = high-sensitivity C-reactive protein.

Keywords: intestinal perforation, surgery, toothpick

Editor: N/A.

This work was supported by the Soonchunhyang University Research Fund.

This manuscript is a case report retrospectively and also is not a clinical study. The ethical approval is not necessary.

The patients have provided written informed consent for publication of the case.

The authors have no conflicts of interest to disclose.

Division of Colon and Rectal Surgery, Department of Surgery, Soonchunhyang University College of Medicine, Soonchunhyang University Bucheon Hospital, Bucheon, South Korea.

* Correspondence: Eung Jin Shin, Division of Colon and Rectal Surgery, Department of Surgery, Soonchunhyang University Bucheon Hospital, Bucheon, South Korea (e-mail: colon@schmc.ac.kr).

Copyright © 2019 the Author(s). Published by Wolters Kluwer Health, Inc. This is an open access article distributed under the terms of the Creative Commons Attribution-Non Commercial-No Derivatives License 4.0 (CCBY-NC-ND), where it is permissible to download and share the work provided it is properly cited. The work cannot be changed in any way or used commercially without permission from the journal.

How to cite this article: Lim DR, Kuk JC, Kim T, Shin EJ. Surgery for intra-abdominal abscess due to intestinal perforation caused by toothpick ingestion. *Medicine* 2019;98:36(e17032).

Received: 7 January 2019 / Received in final form: 8 July 2019 / Accepted: 12 August 2019

<http://dx.doi.org/10.1097/MD.00000000000017032>

1. Introduction

Ingestion of foreign bodies occurs frequently in day-to-day life, often when eating, at mealtimes, or when elderly people or children put foreign objects in their mouths. In most cases, foreign bodies that are ingested will pass out through the gastrointestinal tract spontaneously without any complications. However, when foreign bodies fail to pass through the gastrointestinal tract, this may result in inflammatory reactions, reactive fibroses, and intestinal perforations.^[1] The foreign bodies that most frequently cause intestinal perforation when they are ingested are fish bones, chicken bones, and toothpicks.^[2] Most cases that involve swallowing toothpicks, whether consciously or unconsciously, occur during mealtimes. The main risk factors associated with toothpick ingestion are having a habit of chewing toothpicks, eating food that contains toothpicks, and drinking alcoholic beverages at mealtimes. In 1 study, toothpick ingestion resulted in perforation of the gastrointestinal tract in 80% of these patients, although the toothpicks reached the colon in only 37% of the patients.^[2] Establishing the correct diagnosis of an intestinal perforation that is caused by toothpick ingestion is very difficult because of the low sensitivity rate and accuracy rate of diagnostic investigations. The following 2 case reports

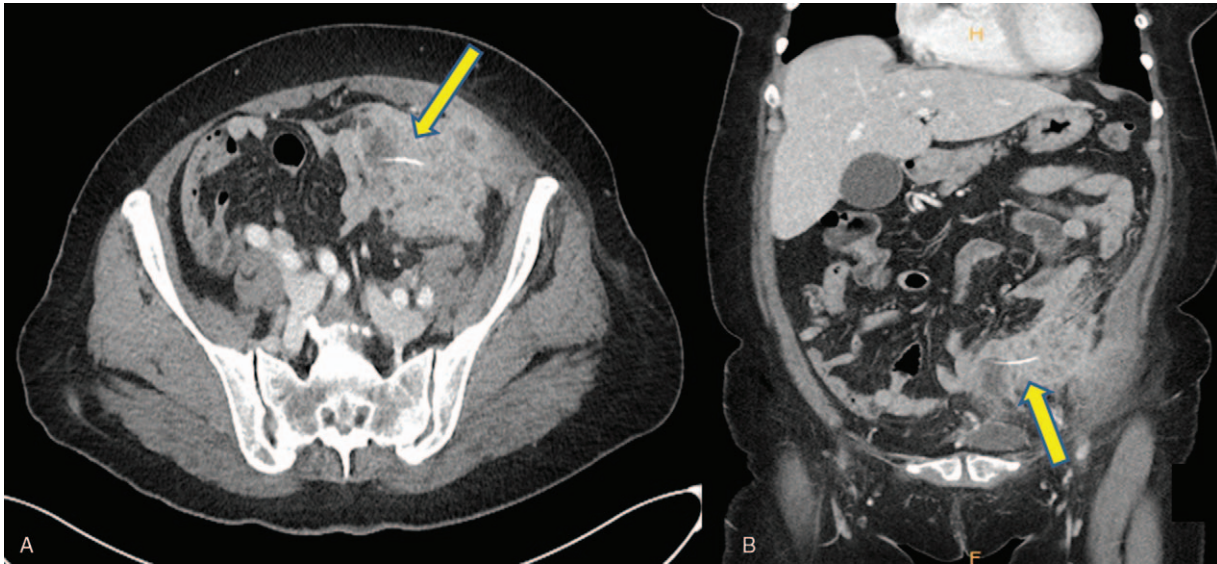


Figure 1. Abdominal pelvic computed tomography view: large inflammatory mass formation with adjacent left lower anterior abdominal wall enhancement and with linear high-density material within inflammatory mass, r/o foreign body including acupuncture needle or intrauterine device.

describe where surgery was performed for intra-abdominal abscesses that resulted from intestinal perforations caused by clinically suspected toothpick ingestion.

2. Case presentations

Case 1: A 49-year-old South Korean female was hospitalized with abdominal pain and fever. The fever lasted for 5 days before hospitalization. She had no medical or surgical history. Laboratory testing revealed a white blood cell count of $12,270 \text{ cells/mm}^3$, a hemoglobin count of 11.7 g/dL , and high-sensitivity C-reactive protein (hs-CRP) of 13.38 mg/dL . The other laboratory tests reported no specific findings. The patient's clinical symptoms were low abdominal tenderness and mild fever (37.8°C). There were no other clinical symptoms. An abdominal pelvic computed tomography (APCT) scan revealed a large

inflammatory mass formation with adjacent left lower anterior abdominal wall enhancement and linear high-density material within the inflammatory mass. The presence of foreign bodies, including acupuncture needles or intrauterine devices was ruled out (Fig. 1). An exploratory laparotomy was performed, and a 5 to 6 cm abscess pocket formation was found at the anterior wall of the sigmoid colon with adhesion to the abdominal wall as well. After removal of the abscess pocket, the sigmoid colon was found to be perforated and there was a firm, sharp foreign body in the abscess pocket that measured about 5 cm and resembled a toothpick. This foreign body was like a toothpick and was clearly not a fishbone (Fig. 2). Surgery was performed for segmental resection of the perforated sigmoid colon, followed by end-to-end anastomosis that was done by hand sewing. The final pathological analysis revealed perforation with acute peritonitis and actinomycosis with an abscess formation. The patient

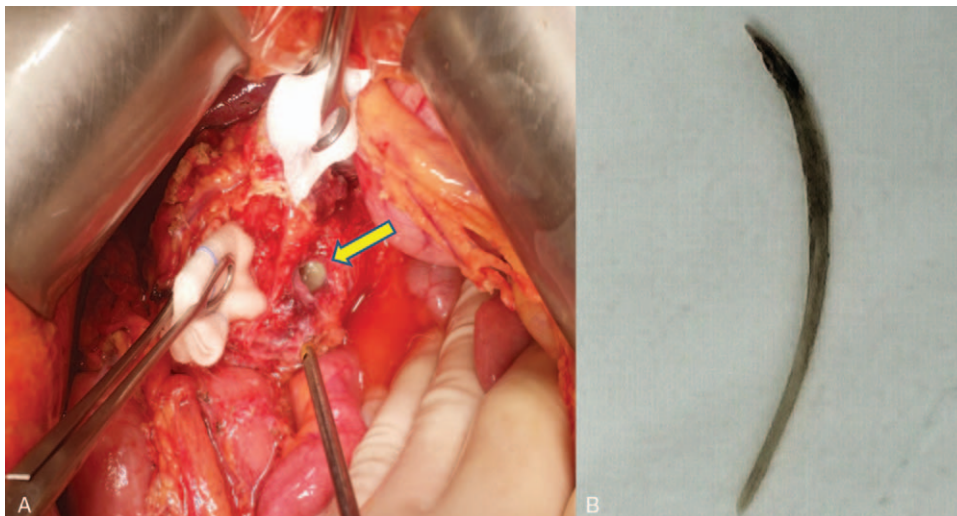


Figure 2. (A) Intraoperative view of the perforated sigmoid colon. (B) Foreign body about 5 cm size hard and shape, like toothpick at abscess pocket.

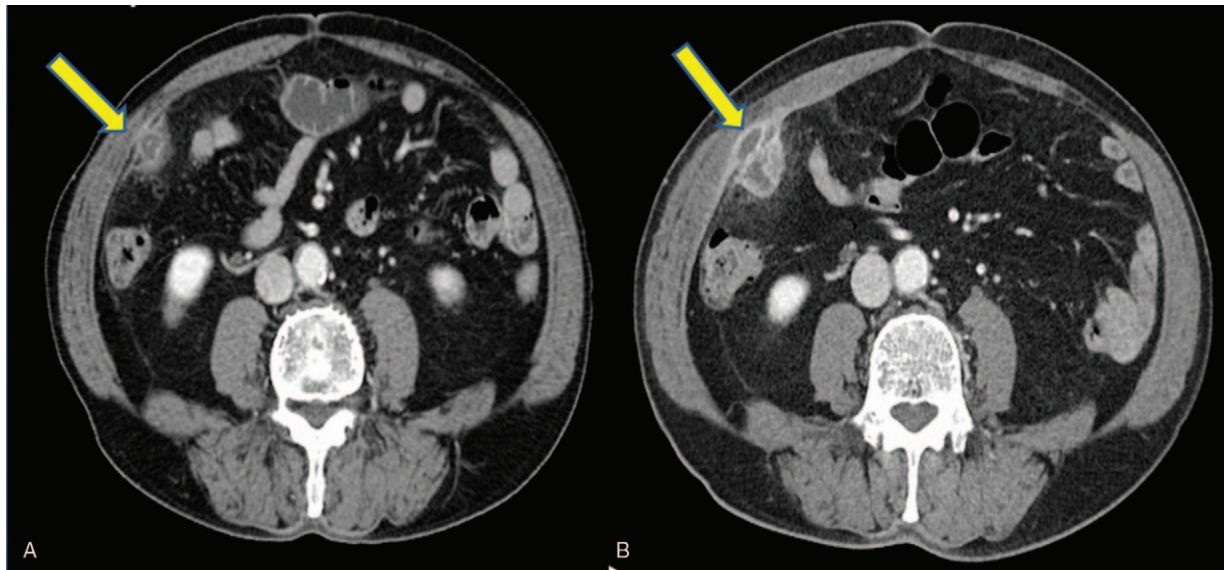


Figure 3. (A) Abdomen pelvic computed tomography view: small sized abscess formation (about 2.5 cm) abutting abdominal wall in right paracolic gutter (r/o parasite infestation). (B) Abdomen pelvic CT view after 2 weeks with antibiotics therapy: interval increased size of presumed abscess (about 4.5 cm) in right paracolic gutter with direct invasion of right anterior abdominal wall muscle.

recovered well after surgery and was discharged on postoperative day 8. Oral antibiotic therapy was then administered for 6 months to treat the actinomycosis and was successful recovery. The patient has stated that she did not eat fish or swallow a fishbone and used toothpicks. However, the patient did not remember to ingest toothpicks.

Case 2: A 72-year-old South Korean male was hospitalized with abdominal pain and fever. The fever lasted for 4 days before hospitalization. He had no medical or surgical history. Laboratory testing revealed a white blood cell count of 9950 cells/mm³, hemoglobin count of 12.2 g/dL, and hs-CRP of 9.32 mg/dL. The other laboratory tests reported no specific findings. The patient initially had massive, severe abdominal pain that persisted

for a while, followed by continued mild tenderness. There were no other clinical symptoms. An APCT scan revealed that there was a small abscess formation, measuring about 2.5 cm abutting abdominal wall in the right paracolic gutter, and a parasite infestation was ruled out (Fig. 3A). Although he received antibiotic therapy with nothing by mouth for 1 week, follow-up abdomen ultrasonography continued to show an abscess formation with a foreign body (Fig. 4A). After another week with antibiotics therapy and nothing by mouth, a follow-up APCT scan revealed that the presumed abscess had increased in size to about 4.5 cm in the right paracolic gutter with direct invasion of the right anterior abdominal wall muscle (Fig. 3B). Laparoscopic exploration was performed. The laparoscopic view

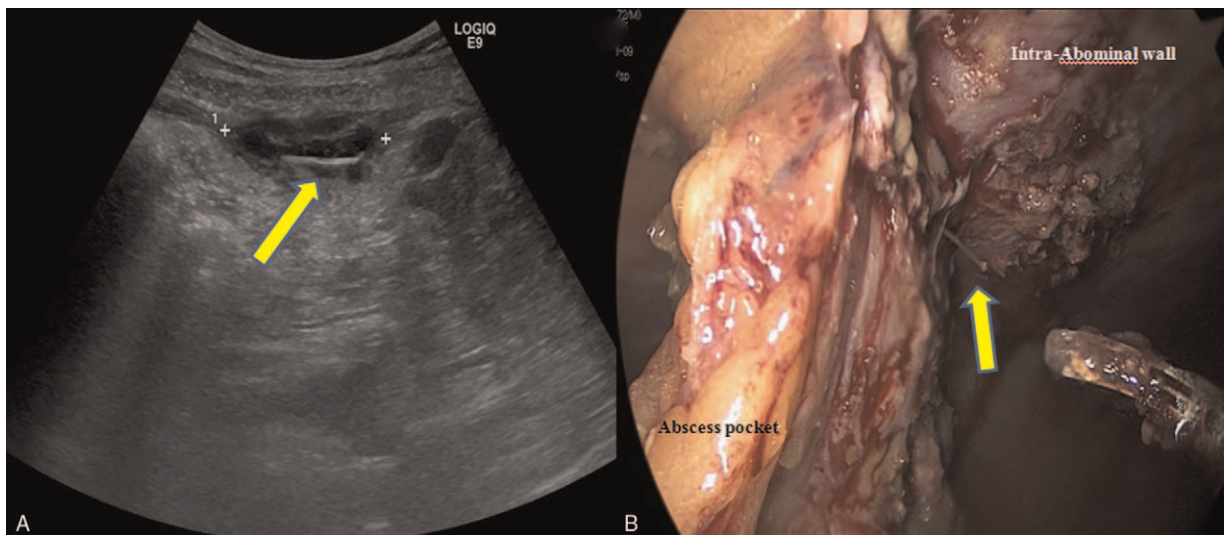


Figure 4. (A) Ultrasonography view of remained abscess formation with foreign body after 1 week with antibiotics therapy. (B) Intraoperative view of a 4 cm sized foreign body like toothpick appeared in the abscess pocket.

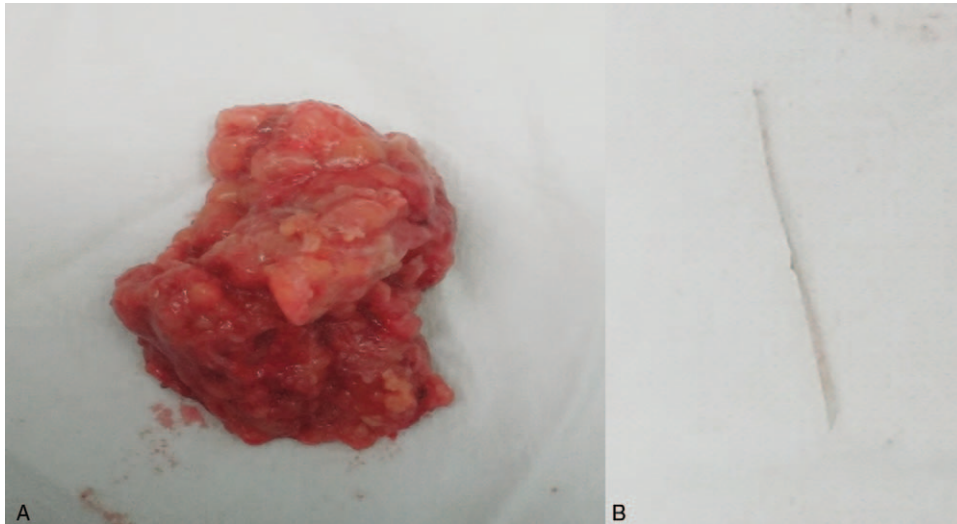


Figure 5. (A) Abscess pocket was a round shape surrounding the fatty tissue. (B) There was about 4 cm size foreign body like toothpick.

of the abdominal cavity revealed that the about 4 to 5 cm isolated abscess pocket was attached to the intra-abdominal wall and the abscess pocket was separated from the intestine and any organs or structures. When the abscess pocket was removed from the abdominal wall using a harmony scalpel, a 4 cm foreign body that resembled a toothpick appeared in the abscess pocket (Fig. 4B). Abscess pocket was a round shape surrounding the fatty tissue (Fig. 5A). There was sharp foreign body like toothpick (Fig. 5B). No perforation of the intestine was found, and no abdominal findings were seen. After removal of the abscess pocket, the final pathological analysis revealed acute and chronic inflammation with granulation tissue formation and fat necrosis. The patient recovered well after surgery and was discharged on postoperative day 4. Like the patient in Case 1, he had not eaten fish or any foreign bodies but had used toothpicks frequently, although he was not aware that he had ingested one. In this patient, it is presumed that the wound closed spontaneously after intestinal perforation, although the location of the intestinal perforation was not identified.

3. Discussion

Toothpick ingestion is a relatively rare event that can result in serious gastrointestinal injuries that lead to peritonitis, sepsis, or even death. It is interesting to note that a 4-year survey performed in the United States found 8176 reported toothpick-related gastrointestinal injuries each year, a rate of 3.6 per 100,000 person-years.^[3] Perforation of the gastrointestinal tract by ingested foreign bodies is rare, occurring in less than 1% of cases involving ingested bodies, and toothpicks are involved in less than 0.1%.^[4] Unless the foreign bodies were swallowed intentionally, many patients who ingested them fail to remember the event from which the symptoms of perforation develop, and this makes diagnosis problematic. Most patients swallow toothpicks while eating their meals and are unaware of having done so.^[5] In the 2 cases that are reported here, both patients failed to remember or were unaware of having swallowed any foreign bodies such as toothpicks. Potential complications that are commonly reported as a result of ingesting toothpicks include gastrointestinal bleeding, subphrenic abscesses, sepsis obstruc-

tions, gastrointestinal perforations, and fistula.^[6] A sharp toothpick that is ingested travels around the gastrointestinal tract, and this can injure the lumen and cause perforations. One article reports that the most frequent locations of such perforations are the rectum and sigmoid colon (54.5%) and the terminal ileum (21.2%).^[7] In present Case 1 that is reported above, the perforation site was the sigmoid colon. In present Case 2, an intra-abdominal abscess formed after intestinal perforation had occurred following toothpick ingestion. It is interesting to note that in both cases the toothpicks were outside the intestinal lumen and were present in the abscess. In Case 2, the isolated abscess pocket was located in the intra-abdominal wall, was not adjacent to the other bowel, and was not attached to the bowel.

Establishing the correct diagnosis of intestinal perforation caused by toothpick ingestion is very difficult because of the low sensitivity rate and accuracy rate of diagnostic investigations. The sensitivity of computed tomography (CT) scans when detecting an ingested toothpick is only 42.6%.^[2] A careful interpretation of CT scans can improve the detection of accidental toothpicks. CT scans are useful for acquiring clinical information, such as the location of the toothpick and the area of tissue damage.^[8] In addition, CT scans can determine the presence of a perforation and the extent of intra-abdominal inflammation either with or without abscess formation.^[8] In some cases, the toothpicks are detected by ultrasonography.^[9] In present Case2, ultrasonography was performed and showed an abscess formation with a foreign body like toothpick, although this was misdiagnosed as a parasite.

Treating intestinal perforation caused by toothpick ingestion requires surgical management. The removal of a toothpick and the primary repair of the perforation site or resection of the perforated bowel are needed for complete treatment. For patients who do not have a lot of inflammation or symptoms of peritonitis, treatment by performing only endoscopic removal of a toothpick within the lumen of bowel has proven successful.^[10] Present Case 1 involved resection of the sigmoid colon because of the perforation and resulting peritonitis and removal of the abscess pocket that contained the toothpick. In conclusion, these patients failed to remember the events in which they ingested toothpicks, and these foreign bodies can cause gastrointestinal

perforations, which generally require surgical treatment to remove the toothpicks.

Author contributions

Conceptualization: Dae Ro Lim, Eung Jin Shin.

Data curation: Dae Ro Lim, Taehyung Kim.

Investigation: Dae Ro Lim, Jung Cheol Kuk, Taehyung Kim.

Methodology: Taehyung Kim.

Resources: Dae Ro Lim, Taehyung Kim.

Software: Eung Jin Shin.

Supervision: Dae Ro Lim, Jung Cheol Kuk, Eung Jin Shin.

Validation: Jung Cheol Kuk, Eung Jin Shin.

Visualization: Dae Ro Lim, Eung Jin Shin.

Writing – original draft: Dae Ro Lim.

Writing – review & editing: Dae Ro Lim, Jung Cheol Kuk, Taehyung Kim, Eung Jin Shin.

References

- [1] Lunsford KE, Sudan R. Small bowel perforation by a clinically unsuspected fish bone: laparoscopic treatment and review of literature. *J Gastrointest Surg* 2012;16:218–22.
- [2] Steinbach C, Stockmann M, Jara M, et al. Accidentally ingested toothpicks causing severe gastrointestinal injury: a practical guideline for diagnosis and therapy based on 136 case reports. *World J Surg* 2014;38:371–7.
- [3] Budnick LD. Toothpick-related injuries in the United States, 1979 through 1982. *JAMA* 1984;252:796–7.
- [4] Henderson CT, Engel J, Schlesinger P. Foreign body ingestion: review and suggested guidelines for management. *Endoscopy* 1987; 19:68–71.
- [5] Lovece A, Asti E, Sironi A, Bonavina L. Toothpick ingestion complicated by cecal perforation: case report and literature review. *World J Emerg Surg* 2014;9:63.
- [6] Ioannidis O, Kakoutis E, Sakkas L, et al. Ingested toothpick fistula of the ileum mimicking Crohn's disease. *Acta Gastroenterol Belg* 2010; 73:527–9.
- [7] Rodríguez-Hermosa JJ, Codina-Cazador A, Sirvent JM, et al. Surgically treated perforations of the gastrointestinal tract caused by ingested foreign bodies. *Colorectal Dis* 2008;10:701–7.
- [8] Cheung YC, Ng SH, Tan CF, et al. Hepatic inflammatory mass secondary to toothpick perforation of the stomach: triphasic CT appearances. *Clin Imaging* 2009;24:93–5.
- [9] Chiang TH, Liu KL, Lee YC, et al. Sonographic diagnosis of a toothpick traversing the duodenum and penetrating into liver. *J Clin Ultrasound* 2006;34:237–40.
- [10] Sarici IS, Topuz O, Sevim Y, et al. Endoscopic management of colonic perforation due to ingestion of a wooden toothpick. *Am J Case Rep* 2017;18:72–5.