

A case of scar-related ventricular tachycardia demonstrating termination with nonglobal capture at the site of concealed entrainment with dual slow conduction pathways



Hiroshi Shimada, MD,^{*} Mitsuhiro Nishizaki, MD,[†] Noriyoshi Yamawake, MD,^{*} Makoto Suzuki, MD,^{*} Harumizu Sakurada, MD,[‡] Masayasu Hiraoka, MD, FHRSS[§]

From the ^{*}Department of Cardiology, Yokohama Minami Kyosai Hospital, Yokohama, Japan, [†]Kanto Gakuin University, Yokohama, Japan, [‡]Tokyo Metropolitan Health and Medical Treatment Corporation Ohkubo Hospital, Tokyo, Japan, and [§]Tokyo Medical and Dental University, Tokyo, Japan.

Introduction

Critical isthmus sites of the ventricular tachycardia (VT) circuit are recognized by entrainment with concealed fusion and a postpacing interval that approximates the cycle length. The stimulus-QRS (S-QRS) interval indicates the conduction time from the pacing site to the exit. We present a case of scar-related VT demonstrating termination with nonglobal capture (NGC) at the site of concealed entrainment with dual slow conduction pathways.

Case report

A 70-year-old man with prior myocardial infarction presented with palpitations and presyncope. Two years earlier, he had suffered an inferior myocardial infarction. An electrocardiogram recorded during an episode of palpitations revealed sustained monomorphic VT, in which QRS morphology showed left bundle branch block, superior axis type; the tachycardia cycle length was 360 ms. A transthoracic echocardiogram showed severe enlargement of the left ventricle (LV) (LV end-diastolic volume 110 mL; LV end-systolic volume 62 mL); the LV ejection fraction was 40% with severe hypokinesis of the inferior LV wall. He was emergently hospitalized and underwent catheter ablation for VT. The site of origin of VT was estimated to be in the inferoposterior mid-LV. This is because the QRS morphology of VT presented a negative QRS complex in the inferior leads and a positive QRS complex in leads

KEY TEACHING POINTS

- Isthmus sites of the ventricular tachycardia (VT) circuit are recognized by entrainment with concealed fusion and a postpacing interval that approximates the cycle length. The stimulus-QRS interval indicates the conduction time from the pacing site to the exit.
- Stimulus close to the entry site of the slow conduction zone during VT results in orthodromic and antidromic wavefronts. Termination of VT occurs if the orthodromic wavefront from the stimulus encounters refractory tissue at the entrance site (termination with non-orthodromic capture).
- Pace mapping that exhibits multiple exit sites may be specific for sites critical to reentry. This functional response holds promise for identifying important sites for catheter ablation of VT.

KEYWORDS Common exit; Concealed entrainment; Dual slow conduction pathway; Multipathway conduction; Scar-related ventricular tachycardia; Termination with nonglobal capture (Heart Rhythm Case Reports 2018;4:459–463)

Address reprint requests and correspondence: Dr Hiroshi Shimada, Department of Cardiology, Yokohama Minami Kyosai Hospital, 1-21-1 Mutsuurahigashi, Yokohama, Kanagawa 236-0037, Japan. E-mail address: shimada.hrs@gmail.com.

V₂–V₆.¹ Initially, coronary angiography was performed, which revealed no progression of coronary artery lesions after percutaneous coronary intervention. A bipolar voltage map of the LV endocardium was acquired using a novel multipolar high-density mapping catheter (PentaRay, Biosense Webster, Diamond Bar, CA) in sinus rhythm (SR) via retrograde aortic access together with the electrophysiological navigation system (CartoSound, Biosense Webster). A bipolar electrogram amplitude of <1.5 mV was defined as *low voltage*, and sites with low voltage of <0.5 mV were considered “scarred areas.”^{2,3} Scar sites and low-voltage areas were observed in the inferior LV wall

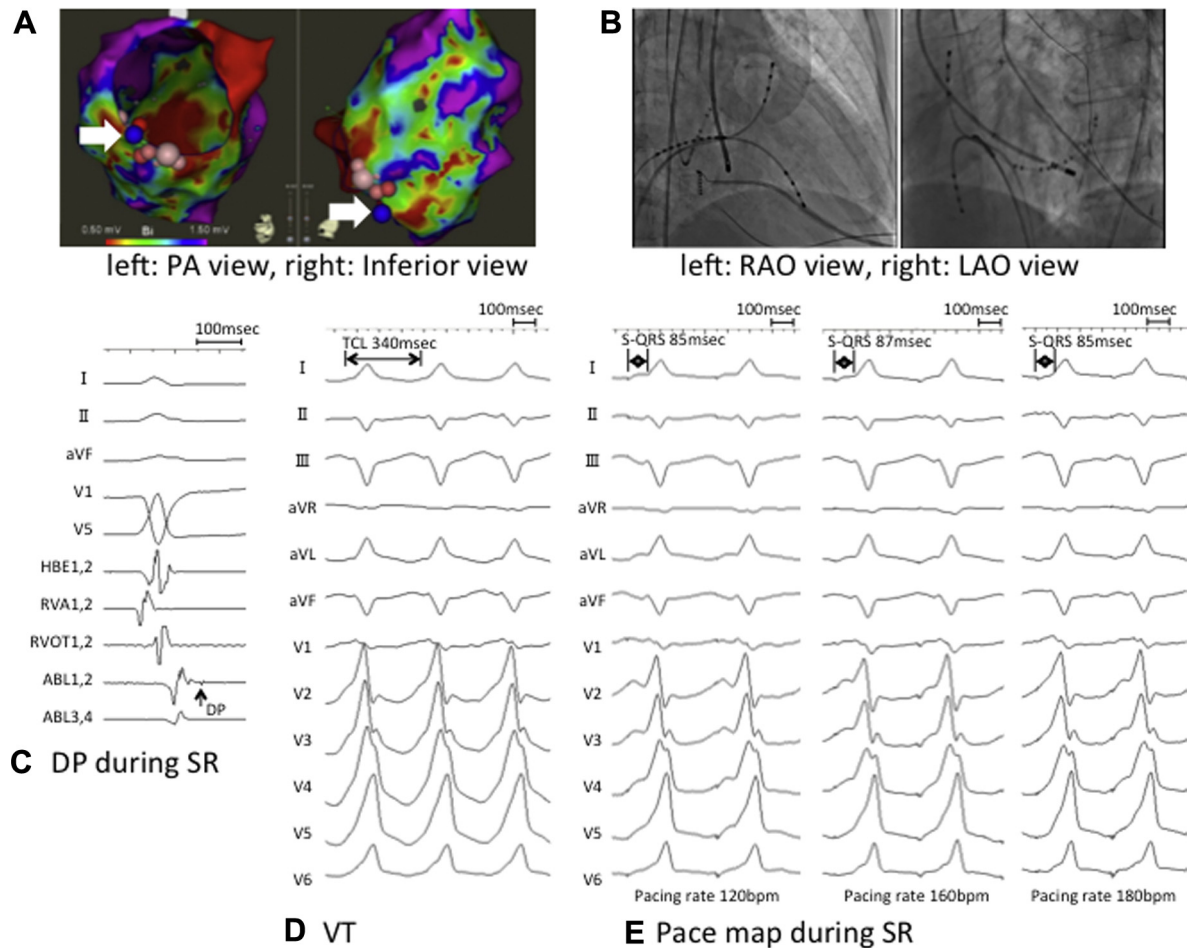


Figure 1 **A:** Voltage map of the left ventricle acquired using the CartoSound system. A bipolar electrogram amplitude of <1.5 mV was defined as *low voltage*, and sites with low voltage of <0.5 mV were designated as *scarred areas*. The low-voltage zone was observed in the inferoposterior left ventricle. Delayed potential (DP) was recorded at the site indicated by the blue circle (arrow). **B:** Ablation catheter in situ demonstrating concealed entrainment and termination with nonglobal capture in fluoroscopic images. **C:** At the same point as shown in panel A, DP was recorded during sinus rhythm (SR). **D:** In the induced ventricular tachycardia (VT), the VT cycle length was 340 ms and the QRS morphology (left bundle branch block and superior axis type) of VT was similar to that of clinical VT. **E:** Pacing was performed during SR at 120, 160, and 180 beats/min, and the stimulus-QRS (S-QRS) interval ranged from 85 to 87 ms without decremental properties. ABL = ablation catheter; HBE = His bundle electrogram; LAO = left anterior oblique; PA = posteroanterior; RAO = right anterior oblique; RVA = right ventricular apex; RVOT = right ventricular outflow tract; TCL = tachycardia cycle length.

(Figure 1A). In the border zones of these areas, a delayed potential was recorded during SR (Figure 1A–C). The tachycardia of the QRS morphology similar to that of clinically documented VT was easily induced by rapid pacing with a cycle length of 330 ms at the blue point (Figure 1A and D). The QRS morphology during VT exhibited a left bundle branch block pattern with superior axis; the tachycardia cycle length was 340 ms (Figure 1D). The presystolic potential during VT was recorded from the distal pair electrodes of the ablation catheter (ABL1,2) at this point and preceded the QRS complex by 90 ms. Pacing was performed during SR at different rates (100, 120, 140, 160, 170, and 180 beats/min), and the S-QRS interval ranged from 85 to 90 ms without decremental properties (Figure 1E). Pacing with a pacing cycle length (PCL) of 325 ms during VT entrained the tachycardia with concealed fusion (concealed entrainment) (Figure 2A). The PPI from the stimulus to presystolic potential at the ablation catheter (ABL1,2) was 355 ms,

which approximated the VT CL of 340 ms (Figure 2A). The S-QRS interval was 90 ms, which was within 30% of the VT CL and was therefore consistent with the exit site in the reentry circuit.^{4–8}

However, pacing with a PCL of 320 ms demonstrated that the S-QRS interval was extremely prolonged to 268 ms with an identical QRS complex, followed by termination with NGC, which was reproducibly observed (Figure 2B). After termination of VT, stimulus directly captured the global myocardium, probably including conduction to the entrance site, which was proved by demonstration of a QRS morphology different from that of VT (Figure 2B). Moreover, VT was terminated with NGC by premature single stimulus at this site (Figure 2C). This finding was reproducibly observed in only premature single stimulus with a coupling interval of 50 ms from ventricular electrogram to stimulus, and this coupling interval was similar to that in pacing with a PCL of 320 ms (Figure 2B and C). VT was

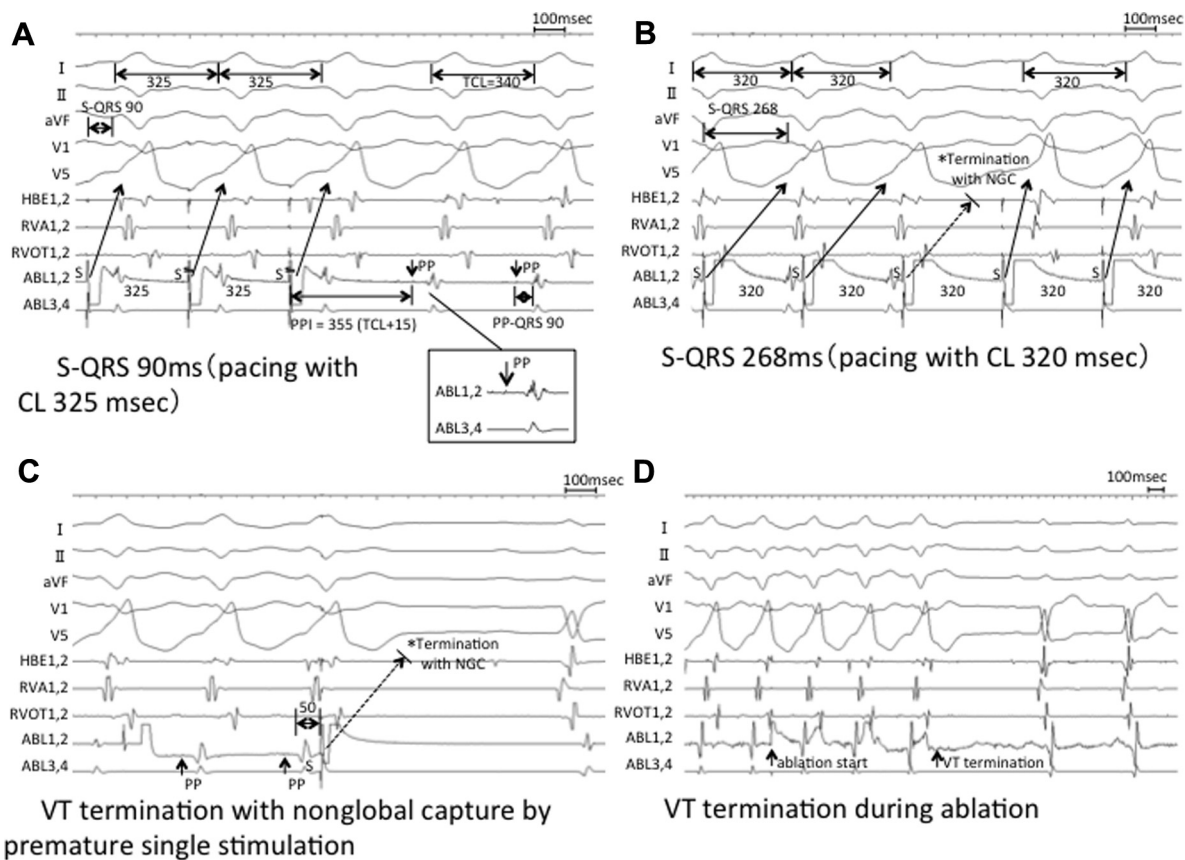


Figure 2 **A:** Pacing with a pacing cycle length (PCL) of 325 ms during the entrained ventricular tachycardia (VT) with concealed fusion (concealed entrainment). The postpacing interval (PPI) from stimulus to presystolic potential (PP) at the ablation catheter (ABL1,2) was 355 ms, which approximated the VT cycle length (CL) of 340 ms. The stimulus-QRS (S-QRS) interval was 90 ms, which was within 30% of the VT CL and was therefore consistent with the exit site in the reentry circuit. **B:** Pacing with a PCL of 320 ms demonstrated that the S-QRS interval was extremely prolonged to 268 ms with an identical QRS complex, followed by termination with nonglobal capture (NGC). After termination of VT, stimulus directly captured the global myocardium, probably including conduction to the entrance site, which was proved by demonstration of a QRS morphology different from that of VT. **C:** VT was also terminated with NGC by premature single stimulus at this site. The coupling interval from ventricular electrogram to stimulus was 50 ms, which was similar to that in overdrive pacing with a PCL of 320 ms. **D:** VT was terminated 1 second after the initiation of radiofrequency energy application at this same site (4-mm irrigated catheter, 40 W). Energy application was continued for a total of 60 seconds, and tachycardia was no longer inducible. HBE = His bundle electrogram; RVA = right ventricular apex; RVOT = right ventricular outflow tract; TCL = tachycardia cycle length.

terminated 1 second after the initiation of radiofrequency energy application at this same site (4-mm irrigated catheter, 40 W) (Figure 2D). The energy application was continued for a total of 60 seconds, and tachycardia was no longer inducible. The delayed potential recorded during SR disappeared after ablation. This patient has been free of VT episodes during a follow-up period of 1 year.

This case report was reviewed by the Institutional Review Board of the Heart Rhythm Society, and informed consent was obtained from the patient.

Discussion

In this case, the S-QRS interval was affected by PCL during VT. The S-QRS interval was prolonged from 90 ms (PCL 325 ms) to 268 ms (PCL 320 ms) with concealed entrainment, which revealed the same QRS morphology as that of VT (Figure 2A and B). This suggests that the reentry circuit of VT may have different dual slow conduction zones—

slow pathway 1 and slow pathway 2 (SP₁ and SP₂)—and pacing wavefronts propagate from the pacing site to the common exit site of SP₁ and SP₂ (Figure 3A). It is speculated that the circulating excitation wavefront propagates through SP₁ in pacing with a PCL of 325 ms during VT (Figure 3B). However, in pacing with a PCL of 320 ms during VT, the propagation of the exciting wavefront passed through the SP₂ because SP₁ tissue still cannot facilitate recovery from the depolarization state (Figure 3C). These findings suggest that the refractory period of SP₂ may be shorter than that of SP₁, although the conduction time in SP₂ is much longer than that in SP₁. In contrast, collision of the stimulated antidromic wavefront with the orthodromic wavefront from the preceding beat had occurred within a common pathway closer to the entrance by decreasing the PCL by 5 ms (from 325 to 320 ms). Moreover, termination with NGC together with conduction block of SP₂ repeatedly occurred with continuous pacing with a PCL of 320 ms (Figure 3D).

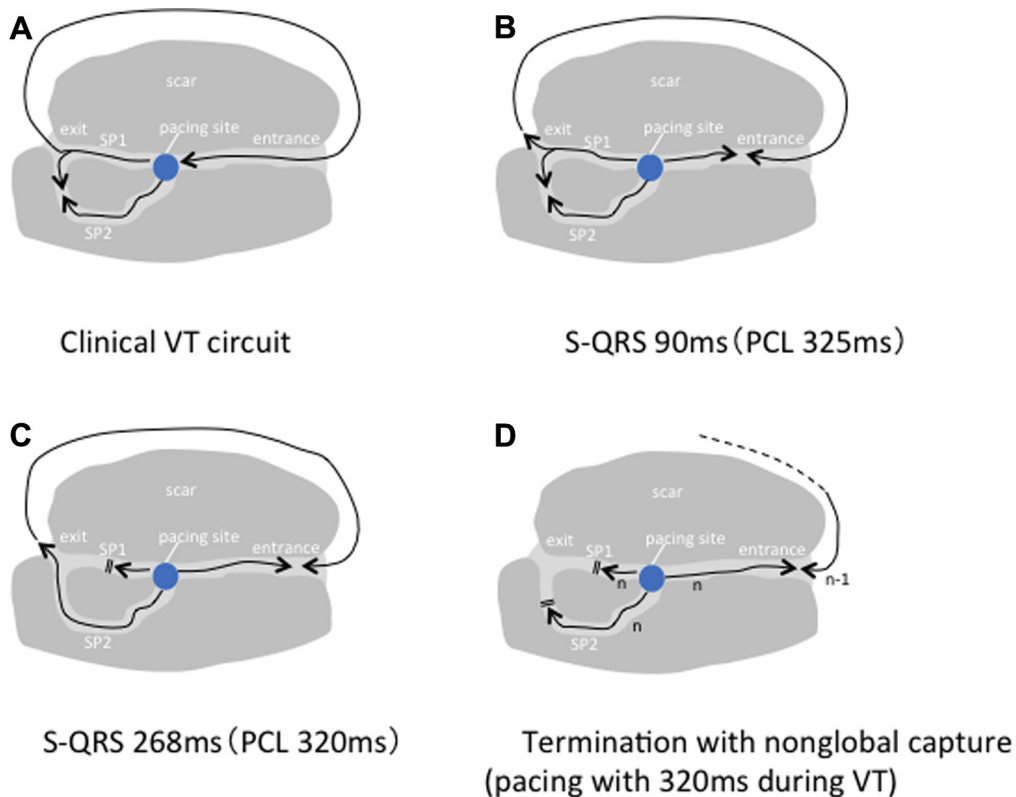


Figure 3 **A:** Scheme of the ventricular tachycardia (VT) circuit and pacing site. **B:** Concealed entrainment was obtained by pacing with a pacing cycle length (PCL) of 325 ms. Propagation conducted through slow pathway 1 (SP₁). **C:** The wavefront propagated through slow pathway 2 (SP₂) by pacing with a PCL of 320 ms during VT. The SP₁ refractory period might be shorter than that of SP₂, although the conduction time in SP₂ was longer than that in SP₁. The exit site distal to both SP₁ and SP₂ was considered the same site. **D:** Termination with nonglobal capture with conduction block of SP₂ repeatedly occurred by continuous pacing with a PCL of 320 ms. S-QRS = stimulus to the QRS complex.

Termination of VT with NGC by premature single stimulus at the site of concealed entrainment was observed (Figure 2C). In this case, we think that the timing of stimulus from ventricular electrogram was critical for VT termination with NGC.

Haberl and Allessie⁹ suggested that postrepolarization refractoriness may develop after premature stimulus, and this might contribute to VT termination after cessation of pacing. Otherwise, termination might be due to rate-dependent block in the zone of slow conduction with pacing. Stimulus close to the entry site of the slow conduction zone results in orthodromic and antidromic wavefronts. Timing is a critical factor, and concealed entrainment may be observed if the stimulus occurs later during diastole. Termination of the tachycardia occurs if the orthodromic wavefront from the stimulus encounters refractory tissue at the entrance site (termination with non-orthodromic capture). These sites were clearly separate from sites terminating with orthodromic capture, in that they were located farther away from the exit site of the reentry circuit.^{10,11}

Tung et al³ have described the phenomenon of multiple exit sites during pacing. We think that our concept of dual conduction is similar to the concept of multipathway conduction through dense myocardial scar as reported by Tung et al. However, this report differs from the concept of Tung et al in that the exit site is common. The pacing site is the mid

inferior mitral annulus, and the stimulus propagates through the dense myocardial scar dividedly from the pacing site to the common exit site, which is the basal inferoseptal LV wall. Late potentials and local abnormal ventricular activities were recorded by using the PentaRay system in the inferior scar zone. However, we could not clearly present the visualization of multiple slow conduction zones using the Carto-Sound system based on isochronal late activation mapping, which was reported by Tung and coworkers.¹²

We have presented a scar-related VT demonstrating concealed entrainment and termination with NGC by pacing at sites proximal to a dual slow conduction pathway. To our knowledge, this is the first report of scar-related VT with a dual slow conduction pathway.

References

- Benito B, Josephson ME. Ventricular tachycardia in coronary artery disease. *Rev Esp Cardiol* 2012;65:939–955.
- Marchlinski FE, Callan DJ, Gottlieb CD, Zado E. Liner ablation lesion for control of unmappable ventricular tachycardia in patients with ischemic and nonischemic cardiomyopathy. *Circulation* 2000;102:1288–1296.
- Tung R, Mathuria N, Michowitz Y, Yu R, Buch E, Bradfield J, Mandapati R, Wiener I, Boyle N, Shivkumar K. Functional pace-mapping responses for identification of targets for catheter ablation of scar-mediated ventricular tachycardia. *Circ Arrhythm Electrophysiol* 2012;5:264–272.
- Stevenson WG, Khan H, Sager P, Saxon LA, Middlekauff HR, Natterson PD, Wiener I. Identification of reentry circuit sites during catheter mapping and

- radiofrequency ablation of ventricular tachycardia late after myocardial infarction. *Circulation* 1993;88:1647–1670.
5. Stevenson WG, Friedman PL, Sager PT, Saxon LA, Kocovic D, Harada T, Wiener I, Khan H. Exploring postinfarction reentrant ventricular tachycardia with entrainment mapping. *J Am Coll Cardiol* 1997;29:1180–1189.
 6. Bogun F, Bahu M, Knight BP, Weiss R, Goyal R, Daoud E, Man KC, Strickberger SA, Morady F. Response to pacing at sites of isolated diastolic potentials during ventricular tachycardia in patients with previous myocardial infarction. *J Am Coll Cardiol* 1997;30:505–513.
 7. Zeppenfeld K, Stevenson WG. Ablation of ventricular tachycardia in patients with structural heart disease. *Pacing Clin Electrophysiol* 2008;31:358–374.
 8. El-Shalakany A, Hadjis T, Papageorgiou P, Monahan K, Epstein L, Josephson ME. Entrainment mapping criteria for the prediction of termination of ventricular tachycardia by single radiofrequency lesion in patients with coronary artery disease. *Circulation* 1999;99:2283–2289.
 9. Haberl K, Allesie M. Differential effects of a segment of slow conduction on reentrant ventricular tachycardia in the rabbit heart. *Circulation* 1999;99:949–962.
 10. Stevenson WG, Nademanee K, Weiss JN, Wiener I, Baron K, Yeatman LA, Sherman CT. Programmed electrical stimulation at potential ventricular reentry circuit sites. *Circulation* 1989;80:793–806.
 11. Bogun F, Stefan H, Bender B, Li YG, Groenefeld G, Pelosi F, Oral H, Knight B, Strickberger SA, Morady F. Mechanism of ventricular tachycardia termination by pacing at left ventricular sites in patients with coronary artery disease. *J Interv Card Electrophysiol* 2002;6:35–41.
 12. Irie T, Yu R, Bradfield JS, Vaseghi M, Buch EF, Ajjola O, Macias C, Fujimura O, Mandapati R, Boyle NG, Shivkumar K, Tung R. Relationship between sinus rhythm late activation zones and critical sites for scar-related ventricular tachycardia: a systematic analysis of isochronal late activation mapping. *Circ Arrhythm Electrophysiol* 2015;8:390–399.