

A Case of Disseminated Infection due to *Actinomyces meyeri* Involving Lung and Brain

Hyun Jung Park¹, Ki-Ho Park³, Sung-Han Kim¹, Heungsup Sung², Sang-Ho Choi¹, Yang Soo Kim¹, Jun Hee Woo¹, and Sang-Oh Lee¹

Departments of ¹Internal Medicine and ²Laboratory Medicine, Asan Medical Center, University of Ulsan College of Medicine, Seoul; ³Department of Internal Medicine, Kyung Hee University School of Medicine, Seoul, Korea

Actinomyces meyeri is rarely isolated in cases of actinomycosis. The identification of *A. meyeri* had historically been difficult and unreliable. With the recent development of 16S ribosomal RNA (16S rRNA) sequencing, *Actinomyces* species such as *A. meyeri* can be isolated much more reliably. *A. meyeri* often causes disseminated disease, which can be secondary to frequent pulmonary infections. A penicillin-based regimen is the mainstay of *A. meyeri* treatment, with a prolonged course usually required. Here, we report a case of pulmonary actinomycosis with brain abscess caused by *A. meyeri* that was initially thought to represent lung cancer with brain metastasis.

Key Words: Actinomycosis; Sequence analysis, RNA; Brain abscess

Introduction

Actinomycosis is a chronic infection caused by organisms in the genus *Actinomyces*, with *Actinomyces israelii* being the most common etiologic agent [1]. The *Actinomyces* spp. are commensal organisms that make up the normal flora of the oropharynx, skin, gastrointestinal tract, and the female genital tract of humans [2]. Consequently, infection with actinomycetes commonly involves cervicofacial, thoracic, and abdominopelvic sites [2].

The identification of other *Actinomyces* spp. has historically been difficult and unreliable; thus, the potential for other spe-

cies to cause similar clinical disease is largely unknown [2]. Recent developments in microbiological identification techniques, especially 16S ribosomal RNA (16S rRNA) sequencing, have identified other *Actinomyces* species such as *A. meyeri*, which are also being reported as human pathogens [1]. *A. meyeri* often causes pulmonary infection and shows a tendency for hematogenous dissemination [3]. Compared to the cases of disseminated actinomycosis due to *A. meyeri* that have been reported abroad [2-5], only few cases of cerebral actinomycosis presenting as brain abscess have been reported in Korea [6-8]. Here, we report a case of pulmonary actinomycosis with brain abscess caused by *A. meyeri* resembling

Received: October 24, 2013 **Revised:** December 25, 2013 **Accepted:** December 26, 2013

Corresponding Author : Sang-Oh Lee, MD

Department of Infectious Diseases, Asan Medical Center, University of Ulsan

College of Medicine, 88 Olympic-ro 43-gil, Songpa-gu, Seoul 138-736, Korea

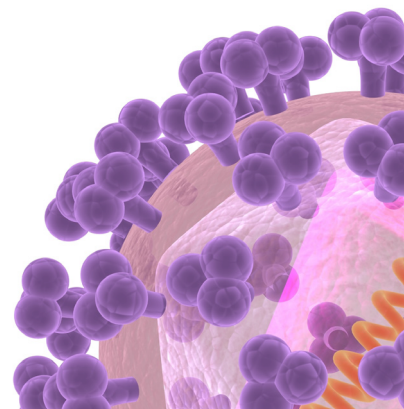
Tel: +82-2-3010-3301, Fax: +82-2-3010-6970

E-mail: soleemd@amc.seoul.kr

This is an Open Access article distributed under the terms of the Creative Commons Attribution Non-Commercial License (<http://creativecommons.org/licenses/by-nc/3.0>) which permits unrestricted non-commercial use, distribution, and reproduction in any medium, provided the original work is properly cited.

Copyrights © 2014 by The Korean Society of Infectious Diseases | Korean Society for Chemotherapy

www.icjournal.org



lung cancer with brain metastasis.

Case Report

A 46-year-old man with no significant past medical history was admitted to the hospital with a 3-day history of headache and aphasia. He had smoked daily a pack of cigarettes for 20 years and consumed approximately five bottles of beer weekly. His temperature was 36.5°C, blood pressure was 138/90 mmHg, pulse rate was 79 beats/min, and respiration rate was 20 breaths/min. Although he had aphasia, he was alert. Examination of the mouth showed no evidence of poor dental hygiene or dental abscesses.

His leukocyte count was 11,800/mm³, with 72% neutrophils, 21% lymphocytes, and 6% monocytes. Blood tests revealed the following data: hemoglobin, 15.7 g/dL; platelets, 324,000/mm³; C-reactive protein, 0.18 mg/dL; and creatinine, 0.8 mg/dL. Serologic tests for Human Immunodeficiency Virus (HIV) and toxoplasmosis were negative. A chest radiograph showed a mass-like opacity in the left lower lobe (Fig. 1A), and computed tomography (CT) confirmed a 2 cm mass in the left lobe with a speculated border and peripheral subsegmental atelectasis (Fig. 1B). A magnetic resonance brain scan showed a 3.5 cm necrotic mass with peripheral rim enhancement in

the left frontoparietal lobe, and a 0.6 cm, enhancing nodular lesion in the subcortical white matter of the left parietal lobe (Fig. 2). A presumptive diagnosis of lung malignancy with brain metastasis was made, and the patient was transferred to the department of pulmonology for a general work-up and staging of the lung cancer.

At the time of transfer, the patient's vital signs were stable, and his aphasia was improved by use of dexamethasone for the treatment of cerebral edema. A CT-guided percutaneous core-needle biopsy of the lung was performed; however, histological examination showed organizing pneumonia but no evidence of malignancy. Gram stainings and microbiological cultures of the biopsies for fungi, pathogenic bacteria, and mycobacteria remained negative. A second CT-guided percutaneous core-needle biopsy of the lung was performed after several days, and organizing pneumonia was pathologically confirmed again. A diagnosis of brain abscesses was considered, and a stereotatic biopsy was performed. The brain lesion appeared to be an abscess, and approximately 8 mL of yellowish and lightly greenish thick pus was obtained. The pus contained filamentous and non-filamentous Gram-positive rods on microscopic examination. The patient was treated with penicillin G (4 million units q 4 h) and metronidazole (500 mg q 8 h) intravenously for *Actinomyces* species and anaerobes. One week after starting treatment, the brain abscess cultures grew *Actinomyces* species,

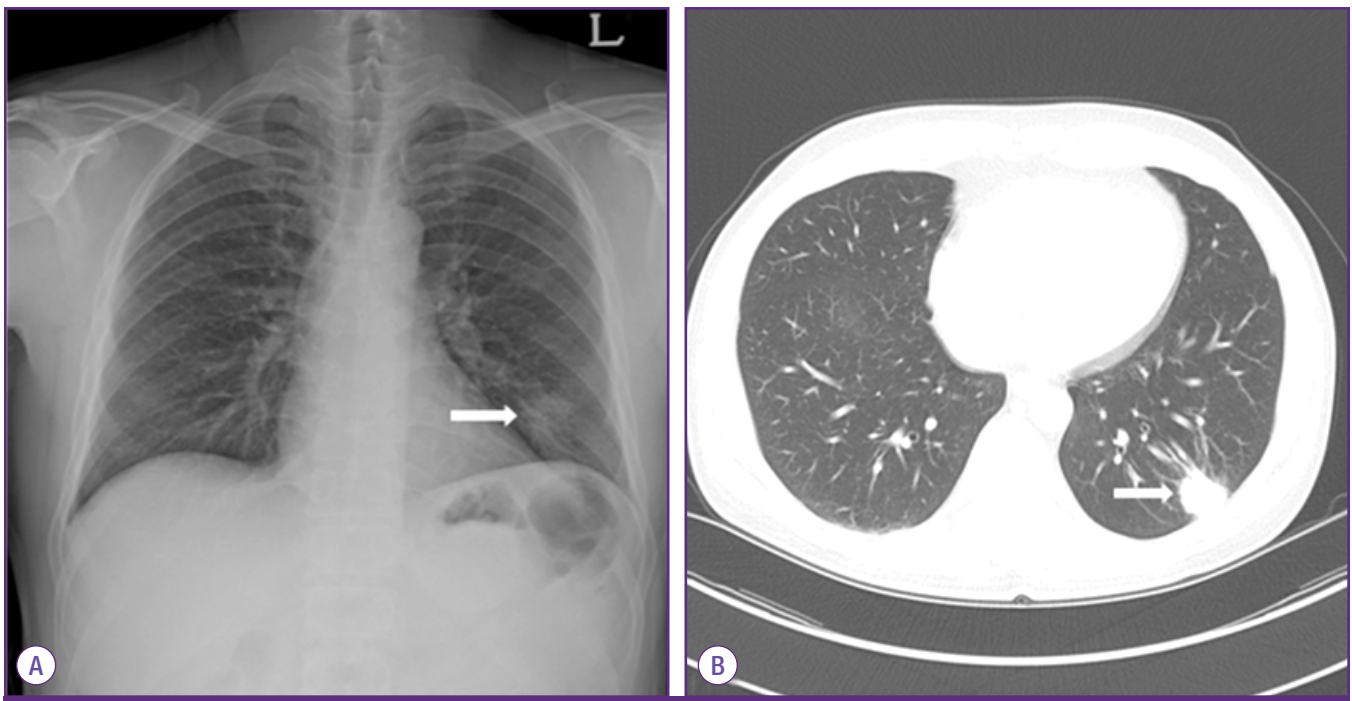


Figure 1. Initial chest roentgenogram shows mass-like opacity (arrow) in the left lower lobe (A). Initial chest CT shows a 2.2 cm mass (arrow) in the left lower lobe with a spiculated border and peripheral subsegmental atelectasis (B).

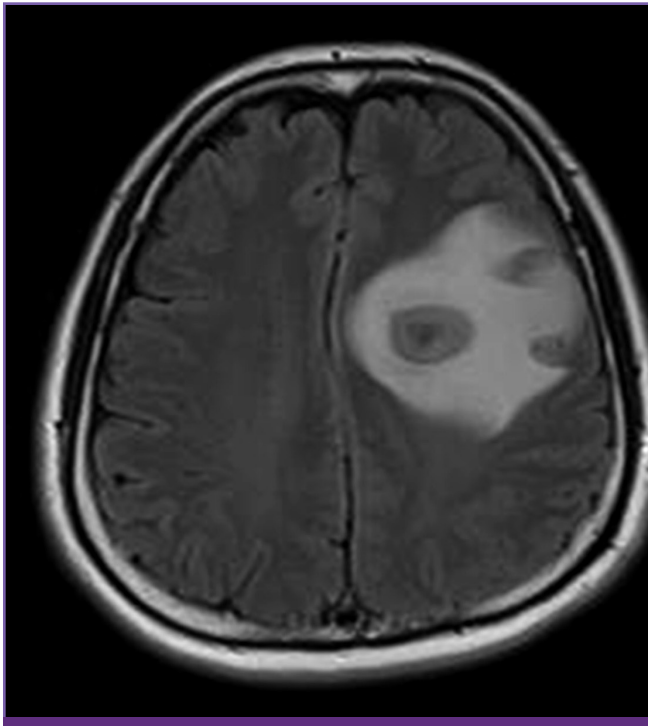


Figure 2. Initial brain MRI shows a 3.5 cm necrotic mass with peripheral enhancement in the left frontoparietal lobe, with perilesional edema and midline shifting.

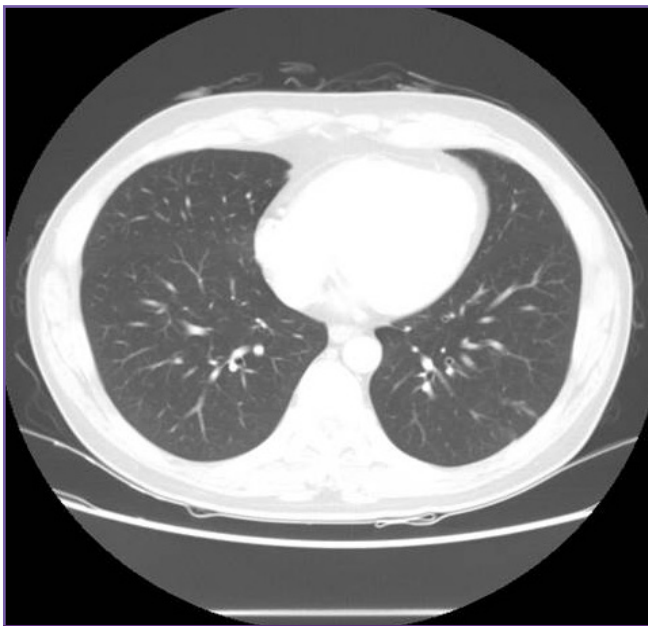


Figure 3. 4-month follow-up chest CT shows a marked decrease in the size of the nodule in the left lower lobe.

Propionibacterium acnes, and *Fusobacterium nucleatum*. The *Actinomyces* species was identified as *A. meyeri* using the 16S rRNA sequencing by Microgene Company (South Korea) and comparing the sequencing data in the GenBank databases at

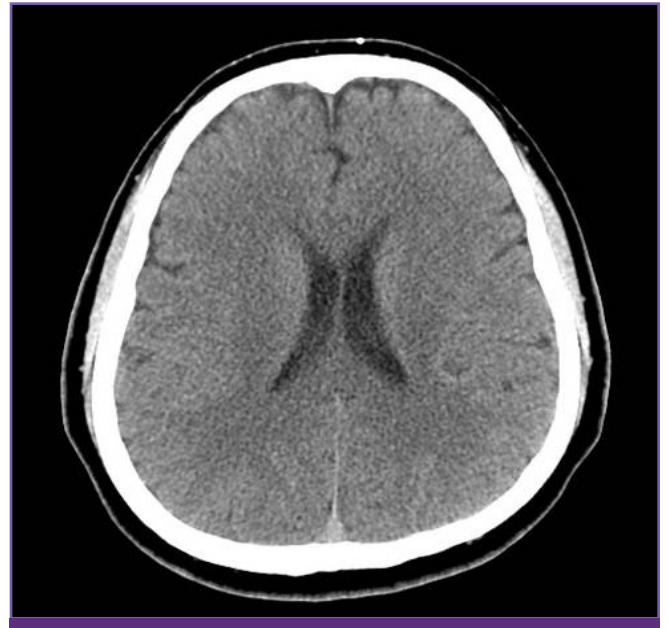

Figure 4. 7-month follow-up brain CT shows a subtle residual low-density lesion in the left frontal lobe cortex and subcortical white matter junction. The size of the abscess and the extent of the perilesional edema are reduced.

the National Center for Biotechnology Information (NCBI). At first, the pus from the brain abscess was identified biochemically as bionumber 6760001000101, 85% *A. meyeri* by Vitek ANI card (bioMérieux, Marcy l'Etoile, France), which is a relatively low rate of certainty. Thus, 16S rRNA gene sequencing was performed for further identification. Using primers amplifying 9-806 bp (8FPL 5'-AGT TTG ATC CTG GCT CAG-3'; 806R 5'-GGA CTA CCA GGG TAT CTA AT-3') and 515-1,390 bp (515FPL 5'-TGC CAG CAG CCG CGG TAA-3'; 13B 5'-AGG CCC GGG AAC GTA TTC AC-3'), polymerase chain reaction (PCR) was performed according to previously published methods [9]. The purified PCR products were directly sequenced using the Big-Dye Terminator v3.1 Cycle Sequencing kit (Applied Biosystems, Life Technologies, Grand Island, NY, USA). According to a search of the Basic Local Alignment Search Tool (BLAST) database (<http://www.ncbi.nlm.nih.gov/blast/>) and eztaxon-e [10], the sequence of this isolate was a 99.9% (1,346/1,347 bp) match to the *A. meyeri* strain Prevot 2477B (GenBank accession no. NR_029286). As a secondary match, the sequence of the isolate was 98.1% (1,322/1,347) match to the *A. odontolyticus* strain F0309 (GenBank accession no. GQ131411). In line with the Clinical and Laboratory Standard Institute guidelines [11], the organism was identified as *A. meyeri*.

The patient received a 6-week course of penicillin G (4 million units q 4 h) and metronidazole (500 mg q 8 h) intravenously in the hospital, and was then discharged home to com-

plete a 12-month course of oral amoxicillin (500 mg q 6 h).

At his five-month follow-up, the patient reported that his neurological symptoms had resolved completely, and follow-up radiographs showed marked decrease in the sizes of the lung nodules (Fig. 3) and brain lesion (Fig. 4).

Discussion

Actinomycosis is a rare infection caused by anaerobic or microaerophilic Gram-positive bacilli belonging to the genus *Actinomyces* [12]. Most actinomycotic infections are polymicrobial and include other anaerobic or microaerophilic flora such as *Actinobacillus actinomycetemcomitans*, *Fusobacterium* spp., and *Peptostreptococcus* spp. [2]. These associated pathogens also belong to the human oropharyngeal flora. Hypothetical mechanisms by which associated bacteria may enhance the pathogenicity of *Actinomyces* species include reduced oxygen tension and anaerobiosis-induced inhibition of phagocytes [3]. Pulmonary infections are believed to occur due to aspiration of the organism from the oral cavity. In our case, *A. meyeri* infection involved the lung and brain. In addition, polymicrobial organisms, including *Propionibacterium acnes* and *Fusobacterium nucleatum*, were cultured from the brain abscess. Even though the patient had smoked a pack of cigarettes a day for 20 years, he did not have poor dental hygiene, nor did he drink alcohol heavily.

A. meyeri is a rare cause of actinomycosis in humans. It was first isolated from a patient with empyema by Meyer in 1911, who termed it Streptothrix. The microorganism was reclassified as *Actinobacterium meyeri* in 1938. The nomenclature was changed to *Actinobacterium meyeri* by Prevot in 1956 and subsequently to *A. meyeri* by Holderman in 1977 [13]. Although actinomycosis by *A. meyeri* was discovered more than 100 years ago, it has been accepted that members of the genus *Actinomyces* are difficult to accurately identify down to the species [14]. Historically, classification of *Actinomyces* species was based upon differentiation in a few phenotypic tests [15]. Biochemical reactions, colonial morphology, and gas-liquid chromatography were used to identify *Actinomyces* species. Recent advances in microbiological identification techniques, particularly 16S rRNA sequencing, have been used successfully to identify new *Actinomyces* species such as *A. meyeri*, *A. europaeus*, *A. neuii*, *A. radingae*, *A. graevenitzii*, *A. turicensis*, *A. georgiae*, *A. funkei*, *A. lingnae*, *A. houstonensis* and *A. cardiffensis*, which are also reported as human pathogens [1].

Actinomycosis of the central nervous system is rare. The

source may be hematogenous, or it may develop through extension of oral-cervicofacial disease. In our case, the patient did not have poor dental hygiene, nor did he have oral-cervicofacial disease. Therefore, brain abscess caused by *A. meyeri* might have been from hematogenous spread.

Unlike *A. israelii*, which predominantly causes cervicofacial disease, the most common organ system involved by *A. meyeri* is pulmonary [1]. *A. meyeri* often causes disseminated disease, which can arise secondarily to frequent pulmonary infections [1]. According to one study, of 26 cases of *A. meyeri* infection, 10 (38%) were disseminated (defined as the involvement of two or more distant organs) [3]. The propensity of *A. meyeri* to disseminate is difficult to explain because this organism does not differ from other actinomycetes in its microbiological characteristics [3]. It has been postulated that pulmonary infection is often the source of hematogenous dissemination [16], and this assumption is supported by the observation that in eight out of 10 cases of disseminated actinomycosis due to *A. meyeri*, pulmonary infection was present [3]. In the case reported here, it is presumed that hematogenous spread from the pulmonary lesions which led to disseminated actinomycosis with brain abscesses that were initially misdiagnosed as a metastatic tumor. Also, the finding that lung lesion had showed good response to penicillin treatment suggests that lung lesion be caused by *A. meyeri*.

Compared to the cases of disseminated actinomycosis due to *A. meyeri* that have been reported abroad [2-5], only few cases of cerebral actinomycosis presenting as brain abscess have been reported in Korea [6-8]. With the exception of the first Korean report of a brain abscess caused by *A. meyeri* [6], all Korean cerebral actinomycosis cases were confirmed by the presence of sulfur granules on biopsy, which is a typical finding associated with actinomycosis [7, 8]. To our knowledge, this is the first report of disseminated *A. meyeri* infection.

Treatment of most patients with actinomycosis infection involves a prolonged course of antibiotics, accompanied by surgical or percutaneous drainage when indicated. Similar to other *Actinomyces* species, *A. meyeri* remains susceptible to several antibiotic classes. Penicillin continues to be the drug of choice for *Actinomyces* spp., including *A. meyeri*. Other antibiotics that have good *in vitro* activity and that have been used extensively with favorable clinical outcomes include erythromycin, tetracycline, doxycycline, and clindamycin. For localized disease, especially in the cervicofacial region, a relatively short course of oral penicillin (500 mg – 1 g q 6 h) for two months seems adequate [12]. For more extensive and disseminated disease, current expert opinion suggests intrave-

nous penicillin (18-24 million units per day) for a period of two to six weeks, followed by oral penicillin or amoxicillin (500 mg q 6 h) [17]. The recommended duration of antibiotics therapy is six to twelve months, but this must be individualized based on the patient's clinical and radiologic response. The prognosis was favorable, even in patients with disseminated disease, including the brain [1]. In our case, the patient had undergone stereotactic aspiration of brain abscess, and he had received a 6-week course of penicillin G (4 million units q 4 h) and metronidazole (500 mg q 8 h) intravenously for *A. meyeri* and isolated anaerobes. After being discharged from the hospital, he was scheduled to complete a 12-month course of oral amoxicillin (500 mg q 4 h). At his five-month follow-up, he reported that his neurological symptoms resolved completely, and follow-up radiographs showed a marked decrease in the size of the lung nodules and brain lesion.

A case initially presumed as lung cancer with brain metastasis in a patient who presented with headache and aphasia was confirmed as an uncommon disseminated infection due to *A. meyeri*, which was accurately identified by 16S rRNA sequencing. Through surgical drainage of brain abscess and a 12-month, penicillin-based antibiotic regimen, the patient recovered completely. Disseminated infections with *A. meyeri* have rarely been reported in Korea. Here, we report a case of pulmonary actinomycosis with brain abscess caused by *A. meyeri* that was confirmed by 16S rRNA sequencing.

Conflicts of interest

No conflicts of interest.

References

- Fazili T, Blair D, Riddell S, Kiska D, Nagra S. Actinomyces meyeri infection: case report and review of the literature. J Infect 2012;65:357-61.
- Colmegna I, Rodriguez-Barradas M, Rauch R, Clarridge J, Young EJ. Disseminated Actinomyces meyeri infection resembling lung cancer with brain metastases. Am J Med Sci 2003;326:152-5.
- Apothéoz C, Regamey C. Disseminated infection due to Actinomyces meyeri: case report and review. Clin Infect Dis 1996;22:621-5.
- Marty HU, Wüst J. Disseminated actinomycosis caused by Actinomyces meyeri. Infection 1989;17:154-5.
- Kuijper EJ, Wiggerts HO, Jonker GJ, Schaal KP, de Gans J. Disseminated actinomycosis due to Actinomyces meyeri and Actinobacillus actinomycetemcomitans. Scand J Infect Dis 1992;24:667-72.
- Song EH, Kwon HH, Jang EY, Kim MN, Lee SO, Kim YS, Woo JH. A case of brain abscess caused by Actinomyces meyeri and Haemophilus aphrophilus. Korean J Med 2008;74 (Suppl 1):S144-8.
- Park YM, Won IS, Kim JI, Cho HJ, Seo JG, Kim JY, Kim EY, Park SH, Park YS, Seo YH, Cho YK. A case of central nervous system actinomycosis presenting as brain abscess. Infect Chemother 2009;41:249-52.
- Ham HY, Jung S, Jung TY, Heo SH. Cerebral actinomycosis: unusual clinical and radiological findings of an abscess. J Korean Neurosurg Soc 2011;50:147-50.
- Kolbert CP, Persing DH. Ribosomal DNA sequencing as a tool for identification of bacterial pathogens. Curr Opin Microbiol 1999;2:299-305.
- Kim OS, Cho YJ, Lee K, Yoon SH, Kim M, Na H, Park SC, Jeon YS, Lee JH, Yi H, Won S, Chun J. Introducing EzTaxon-e: a prokaryotic 16S rRNA gene sequence database with phylotypes that represent uncultured species. Int J Syst Evol Microbiol 2012;62:716-21.
- Clinical and laboratory standards institute (CLSI). Interpretive criteria for identification of bacteria and fungi by DNA target sequencing; approved guideline. MM18-A. Wayne, PA: CLSI; 2008.
- Smego RA, Foglia G. Actinomycosis. Clin Infect Dis 1998;26:1255-61; quiz 1262-3.
- Pordy RC. Lumpy jaw due to Actinomyces meyerii: report of the first case and review of the literature. Mt Sinai J Med 1988;55:190-3.
- Hall V, Talbot PR, Stubbs SL, Duerden BI. Identification of clinical isolates of actinomyces species by amplified 16S ribosomal DNA restriction analysis. J Clin Microbiol 2001; 39:3555-62.
- Holdeman LV, Cato EP, Moore WE. Anaerobe laboratory manual. 4th ed. Blacksburg, Virginia: Virginia Polytechnic Institute and State University; 1977:61-2.
- Hennrikus EF, Pederson L. Disseminated actinomycosis. West J Med 1987;147:201-4.
- Russo T. Agents of actinomycosis. In: Mandell, Douglas and Bennett's principles and practice of infectious diseases. 7th ed. Philadelphia, PA: Churchill Livingstone Elsevier; 2010:209-19.