

Repair of Acute Post Infarction Mitral Regurgitation with Papillary Muscle Reimplantation

— A case report —

Won Kyoun Park, M.D.*, Joon Bum Kim, M.D.*, Suk Jung Choo, M.D.*

A 53-year-old man presenting with dyspnea and chest pain was diagnosed with acute myocardial infarction secondary to occlusion of the left circumflex coronary artery. Urgent revascularization by percutaneous stenting was successfully performed. However, the post-echocardiography revealed a ruptured papillary muscle that was causing severe mitral regurgitation and aggravation of congestive heart failure. The patient subsequently underwent mitral valve repair with papillary muscle re-implantation. Postoperative echocardiography showed a competent mitral valve without residual stenosis or regurgitation. The patient was discharged from the hospital with an uneventful recovery and has been doing well on outpatient follow up.

Key words: 1. Mitral valve repair
2. Mitral valve regurgitation
3. Papillary muscle rupture

CASE REPORT

A 52-year-old previously healthy male patient visited the emergency department of a local clinic due to dyspnea with the recent onset of chest pain. An emergency coronary angiogram (CAG), which was prompted by a 12 lead EKG study suggesting precordial lead ST segment elevation myocardial infarction revealed a totally occluded distal left circumflex coronary artery. Although percutaneous stenting of the culprit vessel was successfully performed, the symptoms of dyspnea had persisted. A subsequent trans-thoracic echocardiogram showed severe mitral regurgitation (MR) caused by a ruptured papillary muscle head. The patient was, therefore, subsequently transferred to our hospital for urgent surgery of the mitral valve. A preoperative echocardiogram showed severe

prolapsing mitral regurgitation (a proximal isovelocity surface area radius of 14 mm at an aliasing velocity of 40 cm/sec) due to rupture of the posteromedial papillary muscle and a decreased left ventricular ejection fraction of 48%. Mild to moderate pulmonary hypertension with a tricuspid regurgitation (TR) velocity of 3.3 m/sec was also noted.

At surgery, the heart was exposed through a standard median sternotomy. Moderate hypothermic cardiopulmonary bypass at 27°C esophageal temperature was performed through selective cannulation of the aorta, superior vena cava, and inferior vena cava. Cardioplegic induction was achieved by antegrade root infusion of cold blood cardioplegic solution. Maintenance of cardioplegia was achieved by continuous retrograde coronary sinus infusion of cold blood cardioplegia. The mitral valve was exposed by transseptal incision ex-

*Department of Thoracic and Cardiovascular Surgery, Asan Medical Center, University of Ulsan College of Medicine

Received: January 13, 2011, Revised: February 25, 2011, Accepted: April 1, 2011

Corresponding author: Suk Jung Choo, Department of Thoracic and Cardiovascular Surgery, Asan Medical Center, University of Ulsan College of Medicine, 338-1, Pungnap 2-dong, Songpa-gu, Seoul 138-736, Korea
(Tel) 82-2-3010-3580 (Fax) 82-2-3010-6966 (E-mail) sjchoo@amc.seoul.kr

© The Korean Society for Thoracic and Cardiovascular Surgery. 2011. All right reserved.

© This is an open access article distributed under the terms of the Creative Commons Attribution Non-Commercial License (<http://creativecommons.org/licenses/by-nc/3.0>) which permits unrestricted non-commercial use, distribution, and reproduction in any medium, provided the original work is properly cited.

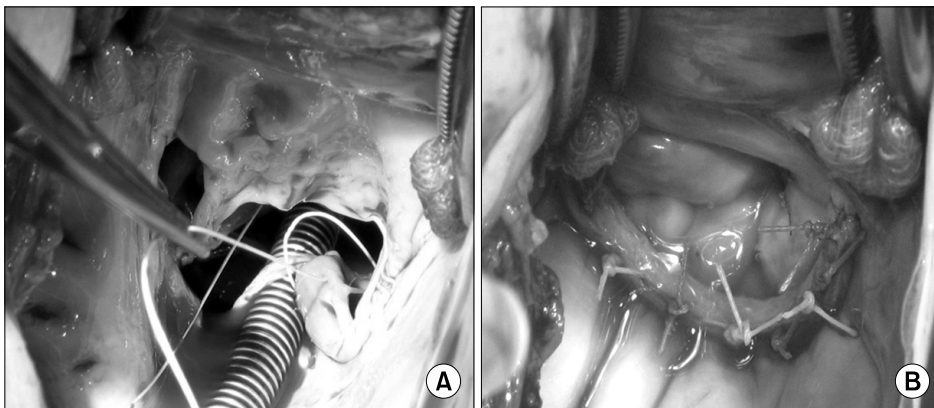


Fig. 1. Operative finding. The anterior leaflet of the mitral valve was prolapsed due to rupture of the posteromedial papillary muscle (A). The repaired mitral valve was found competent in a saline test (B).

tended to the left atrial roof, as exposure would otherwise have been extremely difficult through Sondergaard's groove in the relatively small-sized normal left atrium of this patient. When viewed directly, it became clear that the anterior mitral valve A3 prolapse was caused by the disruption of a sub-papillary muscle head of the posteromedial papillary muscle. After careful examination to rule out any additional structural valvular pathology that could have complicated the planned simple repair, the disrupted papillary muscle tip was re-attached to the papillary muscle base with three interrupted mattress sutures of 5-0 polytetrafluoroethylene buttressed by a pledget. The approximating sutures were passed through healthy tissue adjacent to the endocardial surface at the base, thereby avoiding suturing the friable, necrotic tissue of the detached margins. Finally, a 26 mm Cosgrove-Edwards annuloplasty band (Edwards Lifesciences, Irvine, California, USA) was used to perform the undersized mitral annuloplasty (Fig. 1). Two interrupted stitches of 5-0 polypropylene sutures were placed to approximate the lateral commissural portions of the anterior and posterior mitral leaflets to correct the residual trivial MR on saline testing. After an uneventful weaning of the cardiopulmonary bypass (CPB), the proceeding trans-esophageal echocardiography showed no residual mitral stenosis or regurgitation. The aortic cross clamping and CPB times were 125 and 164 minutes, respectively.

The patient was extubated 16 hours postoperatively after an uncomplicated recovery. Follow up echocardiography on the fifth postoperative day showed no mitral regurgitation but persistent mild left ventricular dysfunction with an ejection fraction of 42%. The patient was uneventfully discharged on

postoperative day 7. The patient remained in excellent clinical condition on the 4th postoperative month, which was the last follow up.

DISCUSSION

Severe MR occurs in about 3% of patients presenting with an acute myocardial infarction, and is associated with an in-hospital mortality of up to 70%. Although progress in surgical management has led to improved outcomes over the decades, operative mortality remains high [1].

The papillary muscle is a contiguous structure of the adjacent left ventricular wall that serves to preserve the contractile function and acts as an anchor for the chordae tendinae. There are usually one anterolateral and two or three posteromedial papillary muscles [2]. While the anterolateral papillary muscle receives dual blood supply from the left anterior descending and circumflex coronary arteries, the posteromedial papillary muscle usually receives a single blood supply from either the right or left circumflex coronary artery. As a result, the posteromedial papillary muscle is relatively more vulnerable to rupture than the anterolateral papillary muscle, with a nearly three- to six-fold higher reported rate of disruption after acute myocardial infarction [3].

Repair is usually recommended over replacement for the treatment of functional ischemic MR, as it is generally conducive to superior survival outcomes [4]. However, in acute postinfarction papillary muscle rupture, experience is limited and most surgeons prefer to replace rather than repair the mitral valve. This is mainly due to their uncertainty regarding

the durability of a repair that inevitably requires suturing onto friable and infarcted myocardial tissue. In addition, the potential for a longer aortic cross clamping time, greater technical difficulties in achieving a successful repair, and the likelihood of ventricular remodeling progression with consequent recurrence of mitral regurgitation have also led to a greater preference for valve replacement in this subset of patients [5,6].

In the present case, one of two papillary projections of the posteromedial papillary muscle was disrupted. The basal portion of the main posteromedial papillary muscle appeared to be non-necrotic. Therefore, from the perspective of the papillary muscle mass involvement, the posteromedial papillary muscle was partially infarcted and thus considered to be amenable to repair by re-attaching the detached papillary muscle head to normal tissue. Fasol et al. [7] reported a modified papillary muscle re-implantation technique involving reattaching the ruptured papillary muscle tip to a healthy area of the papillary muscle and reinforcing the repair with additional sandwiched pericardial pledgetted PTFE sutures. We avoided approximating necrotic tissue directly with necrotic tissue by placing the sutures through healthier-appearing tissue that was closer to the ventricular endocardium at the papillary muscle base.

A search of the literature published in Korea revealed surgery for acute post infarction papillary muscle rupture performed in nine patients [3,8,9]. Of note, in all of them, the mitral valve was replaced instead of being repaired. Therefore, to the best of our knowledge, this is the first reported case of a post infarction papillary muscle rupture that was treated with reimplantation of the papillary muscle in

Korea. Although the repair was successfully performed, further studies are warranted to substantiate and validate the durability of this method.

REFERENCES

1. Chevalier P, Burri H, Fahrat F, et al. *Perioperative outcome and long-term survival of surgery for acute post-infarction mitral regurgitation.* Eur J Cardiothorac Surg 2004;26:330-5.
2. Oh JH, Lee KS, Park HW. *The morphologic study of the mitral valve complex in Korean adult hearts.* Korean J Thorac Cardiovasc Surg 1990;23:1128-38.
3. Kim YD, Moon SW, Jo KH. *Rupture of the anterior papillary muscle caused by occlusion of the first diagonal branch: report of 1 case.* Korean J Thorac Cardiovasc Surg 2006;39:64-7.
4. Gillinov AM, Wierup PN, Blackstone EH, et al. *Is repair preferable to replacement for ischemic mitral regurgitation?* J Thorac Cardiovasc Surg 2001;122:1125-41.
5. Loisançe DY, Deleuze P, Hillion ML, et al. *Are there indications for reconstructive surgery in severe mitral regurgitation after acute myocardial infarction?* Eur J Cardiothorac Surg 1990;4:394-7.
6. Tavakoli R, Weber A, Vogt P, et al. *Surgical management of acute mitral valve regurgitation due to post-infarction papillary muscle rupture.* J Heart Valve Dis 2002;11:20-5; discussion 26.
7. Fasol R, Lakew F, Wetter S. *Mitral repair in patients with a ruptured papillary muscle.* Am Heart J 2000;139:549-54.
8. Kim S, Bang JH, Woo JS. *Operative treatment of mitral valve regurgitation due to chordal rupture and/or papillary muscle rupture.* Korean J Thorac Cardiovasc Surg 2004;37:401-9.
9. Oh JH, Kim HK, Lee CK, et al. *Papillary muscle rupture of the left ventricle.* Korean J Thorac Cardiovasc Surg 1992; 25:936-42.