

Contents lists available at [ScienceDirect](http://www.sciencedirect.com)

## International Journal of Surgery Case Reports

journal homepage: [www.casereports.com](http://www.casereports.com)

# The hanging manoeuvre to complete liver resection for a locally advanced angiosarcoma: A case report



Shamir O. Cawich\*, Dexter Thomas, Vindra Ragoonanan, Vijay Naraynsingh

Department of Clinical Surgical Sciences, University of the West Indies, St. Augustine Campus, Trinidad and Tobago

## ARTICLE INFO

### Article history:

Received 13 June 2015

Received in revised form

10 September 2015

Accepted 12 September 2015

Available online 16 September 2015

### Keywords:

Surgery

Angiosarcoma

Hepatectomy

Hepatic

## ABSTRACT

**INTRODUCTION:** Angiosarcomas arising in the liver are rare tumours in the Western world. We report a case of a locally advanced primary hepatic angiosarcoma and also describe the manoeuvres used to achieve operative resection.

**PRESENTATION OF A CASE:** A 52-year old woman presented with vague right upper quadrant pain. Abdominal imaging revealed a heterogeneous tumour in the right liver measuring 15 centimetres in maximal diameter. Although the tumour was deemed to be resectable, there was free fluid in the right paracolic gutter suggestive of rupture.

Intra-operatively, the peritoneal cavity was noted to be free of metastatic disease. However, tumour was adherent to the diaphragm precluding traditional mobilization of the liver. Therefore, a modified hanging manoeuvre was performed using a nasogastric tube. This allowed controlled mobilization of the right liver, parenchymal transection and en-bloc resection of the diaphragm with good hemostasis. Histologic examination revealed a primary angiosarcoma with uninvolved margins.

**DISCUSSION:** When they occur, primary hepatic angiosarcomas are most often locally advanced. Nevertheless, surgeons should be aggressive in the pursuit of complete resections because this is the only therapeutic modality that has been shown to have a survival advantage.

**CONCLUSION:** Hepatobiliary surgeons should keep the hanging manoeuvre in their armamentarium when performing complex liver resections for locally advanced angiosarcomas.

© 2015 The Authors. Published by Elsevier Ltd. on behalf of Surgical Associates Ltd. This is an open access article under the CC BY-NC-ND license (<http://creativecommons.org/licenses/by-nc-nd/4.0/>).

## 1. Introduction

Angiosarcomas account for 0.58% of all primary liver tumours [1]. These patients usually present late when the tumour is locally advanced and therapeutic options are limited [2]. We report the case of a 52-year old woman who presented with a locally advanced angiosarcoma originating from the right liver. The lesion could only be excised safely using an anterior parenchymal transection aided by the hanging manoeuvre.

## 2. Report of a case

This report is in line with the CARE criteria [3]. A 52-year old woman with no chronic medical illnesses experienced worsening vague right upper quadrant pain for 5 days prior to presentation. She was otherwise well and there was no weight loss, anorexia, gastrointestinal symptoms and/or history of trauma. Physical examination was normal.

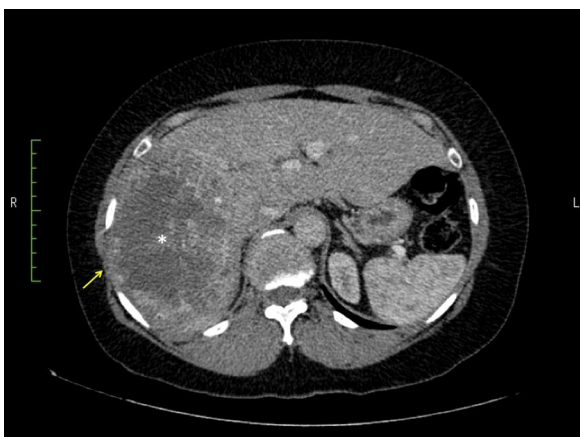Blood investigations revealed a haemoglobin count of 10,000/dl. Electrolytes, renal function and liver function tests were normal. With a suspicion of gallstone disease, an abdominal ultrasound was ordered. Ultrasound did not identify any gallstones but noted the presence of a tumour in the right liver. Endoscopic evaluation excluded the presence of upper and lower gastrointestinal primaries.

Contrast enhanced CT scan revealed a large heterogeneous tumour in the right hepatic lobe measuring 10 × 12 × 15 centimetres in maximal diameter (Figs. 1 and 2). There was evidence of free fluid in the right paracolic gutter suggestive of rupture. The tumour extended to Cantlie's line but did not involve portal vein or hepatic artery bifurcation. The left liver was normal and there were no metastatic foci in the chest or pelvis.

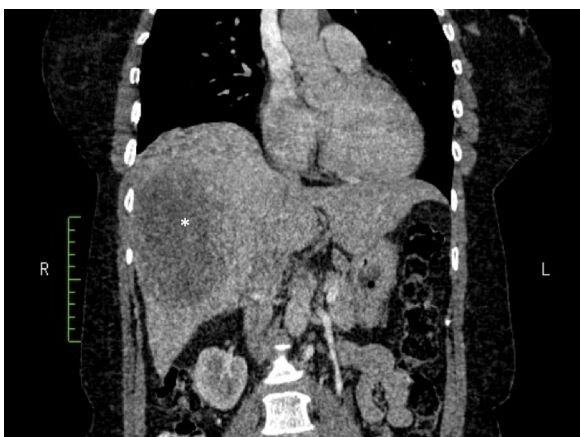
This patient was prepared for general anaesthesia and taken to the operating room for extended right hepatectomy. Intra-operatively, the peritoneal cavity was noted to be free of metastatic disease. The tumour had a bossellated surface (Fig. 3) and was adherent to the diaphragm. Since traditional mobilization of the right liver was not possible, a hanging manoeuvre was performed. The avascular space anterior to the inferior vena cava was developed from the lower border of the liver to the supra-hepatic

\* Correspondence author.

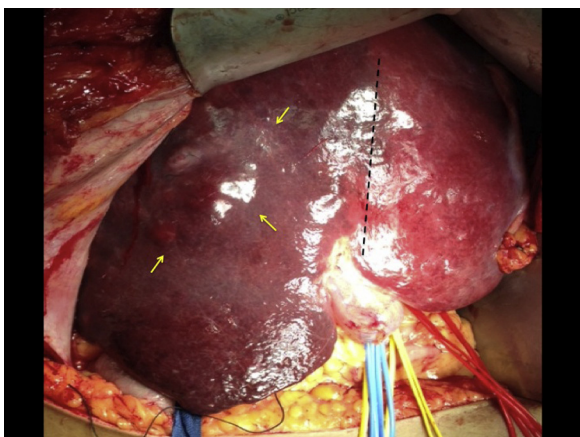
E-mail address: [socawich@hotmail.com](mailto:socawich@hotmail.com) (S.O. Cawich).



**Fig. 1.** Axial views of a contrast enhanced CT scan of the liver revealing a large heterogenous tumour in the right hepatic lobe (Asterix). Yellow arrows point to an area of tumour that breaches Glisson’s capsule.

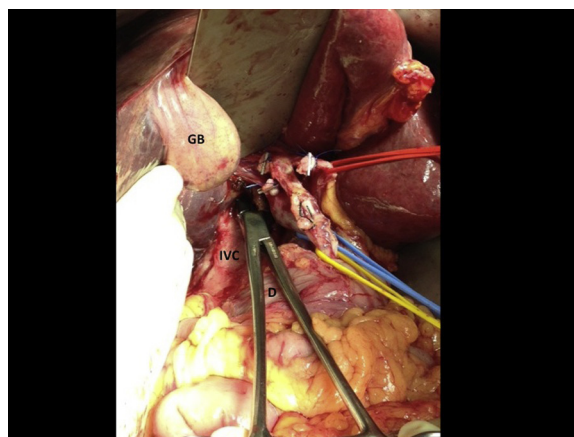


**Fig. 2.** Coronal views of a contrast enhanced CT scan of the liver revealing a large heterogenous tumour in the right hepatic lobe (Asterix).

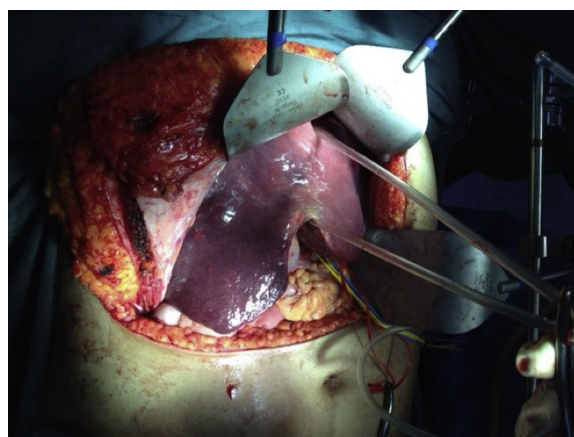


**Fig. 3.** The peritoneum has been entered to reveal the anterior surface of the liver. Yellow arrows demonstrate the tumour with a bosselated surface. The right hepatic artery and portal vein have already been ligated (not visible in this figure), resulting in ischemic change to the right liver as indicated by the broken black line.

space (Fig. 4). A large bore nasogastric tube was advanced into the avascular space and used to elevate the liver and facilitate anterior parenchymal transection without prior mobilization (Fig. 5). Hemostasis was ensured and this allowed controlled mobilization of the right liver to the point at which the tumour invaded the



**Fig. 4.** In preparation for a hanging manoeuvre, a large vascular clamp is passed anterior to the duodenum (D) and used to develop the avascular space anterior to the inferior vena cava (IVC). The plane is developed along the plane of Cantlie’s line from the IVC to the gallbladder (GB). Multiple vessel loops are seen encircling the main portal vein (blue sling), hepatic artery proper (red sling) and the common bile duct (yellow sling).

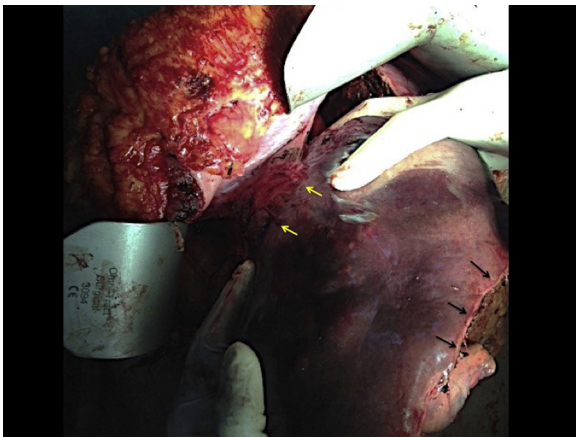


**Fig. 5.** A large bore nasogastric tube has been passed along the avascular space anterior to the IVC and used to carry out a hanging manoeuvre that will facilitate parenchymal transection.

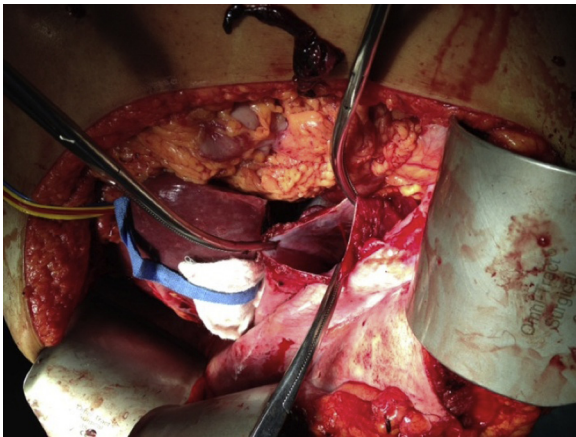
diaphragm (Fig. 6). Complete removal demanded en-bloc resection of the diaphragm (Fig. 7). The diaphragm was repaired primarily in two layers using 1/0 polypropylene sutures. Hemostasis was ensured and drains left in-situ.

Pathologic examination confirmed the presence of 9 × 12 × 15 cm tumour with several haemorrhagic cystic areas ranging in size from 0.5–2 cm in diameter and scattered areas of necrosis. Resection margins were clear and uninvolved liver tissue was grossly unremarkable. The tumour invaded but did not penetrate the diaphragm.

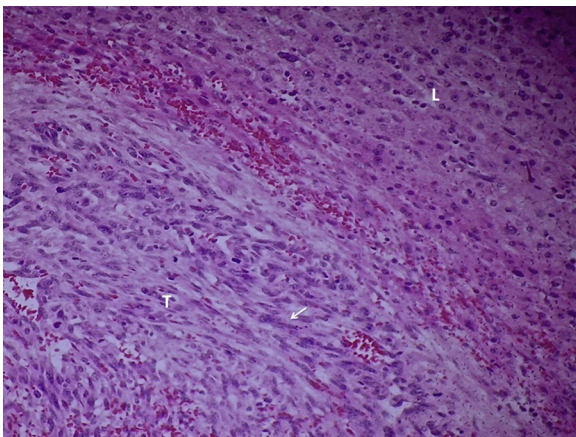
Histologic examination revealed a primary angiosarcoma with uninvolved margins. There were numerous foci of infarction and tumour necrosis. The malignant cells were poorly differentiated. There were numerous spindle-shaped and bizarre multi-nucleated giant cells with indistinct cell margins, large nucleoli, prominent chromatin and frequent mitotic figures (Fig. 8). These bizarre cells spread along the hepatic sinusoids in sheets as they invaded into the adjacent hepatocytes (Fig. 9). Immuno-histochemical staining revealed that this tumour was positive for CD31 antigen but negative for Desmin, Keratin and S-100 proteins.



**Fig. 6.** Parenchymal transection is completed as indicated by black arrows. This allowed controlled mobilization of the right liver down to the point at which the tumour invades into the diaphragm (marked by yellow arrows).



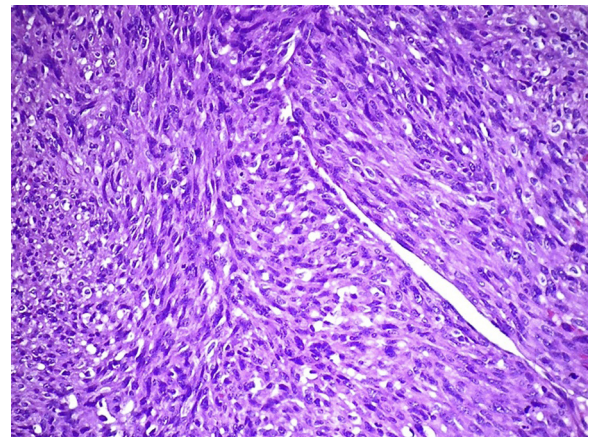
**Fig. 7.** Complete resection of the right lobe demanded en bloc resection of the diaphragm. The margins of the resected diaphragm are held open by multiple artery forceps to reveal the pleural space.



**Fig. 8.** A view of the periphery of the tumour (T) at 10× magnification demonstrating poorly differentiated spindle cells arranged in sheets (arrow). The cells are arranged in sheets along the hepatic sinusoids. The tumour abuts a normal portion of liver (L).

### 3. Discussion

Angiosarcomas arising in the liver are rare in the Western world, where they account for 0.58% [1] of primary hepatic neoplasms.



**Fig. 9.** A high power (×20) view of the malignant cells demonstrating the poorly differentiated, bizarre multi-nucleated giant cells. These cells are poorly differentiated and possess indistinct cell margins, large irregular nucleoli and prominent chromatin.

They are usually detected at autopsy [4,5] because they produce vague symptoms such as constitutional symptoms of malignancy [6,7], non-specific abdominal pain [2,4,5], jaundice [8,9] or hepatomegaly [1,2].

It is unusual to make the diagnosis in living patients—and when it is the tumour is often found at an advanced stage. Multifocal and/or bi-lobar disease is present in 70% [10–11] to 89% [4] of cases at diagnosis. Extra-hepatic metastases are seen in up to 23% of patients at diagnosis, [12] most commonly to lung and spleen [3,8,10]. Therefore, it was not surprising that our patient had locally advanced disease with a large primary that had already invaded into the diaphragm.

Our patient was a 52-year old female. This was unusual because the diagnosis is usually made in the 7th decade of life [4] and occurs more commonly in males [4,12,13]. The reported male to female ratio ranges from 1.9:1 in Taiwan [12] to as high as 4:1 in Britain [14]. We did not identify any of the recognized environmental aetiological factors [4,12] such as exposure to thorotrast, vinyl, arsenic, pesticides or radium in our case.

In this case, we detected the tumour on imaging but the diagnosis but we did not consider angiosarcoma as a differential. This is because there are no pathognomonic features for angiosarcomas on CT or MRI. They enhance with contrast but are difficult to distinguish from other vascular tumours [2,15]. Therefore, as in this case, the diagnosis is often made only at pathologic examination after a biopsy or liver resection.

In this case, we only made the diagnosis after hepatectomy. Because the tumour was locally advanced and had already invaded into the diaphragm, the right liver could not be mobilized by the usual procedure to divide coronary and triangular ligaments. The hanging manoeuvre was required to lift the tumour safely off the inferior vena cava. The original hanging manoeuvre was described by Belghiti et al. [16] in 2001 and then popularized in Hong Kong [17,18,19]. This allowed us to use the anterior transection technique to safely mobilize the right liver in a controlled fashion and hone down onto the point of diaphragmatic invasion. In the original hanging manoeuvre, Belghiti et al. [16] passed a tape in the avascular plane along the anterior surface of the IVC to suspend the liver. We used a large bore nasogastric tube to suspend the liver with similar effect. This served to facilitate anterior parenchymal transection and brought better control of bleeding from deep within the parenchyma and a lower risk of tumour rupture [20].

Using this manoeuvre we managed to completely resect the liver and the site of diaphragmatic invasion. This is important because angiosarcomas have an unpredictable response to adju-

vant therapies. There has not been any conclusive evidence that adjuvant chemotherapy or radiotherapy offer any survival advantage [21,22,23]. Currently, the only accepted therapy is surgical resection with clear margins [2].

Patients diagnosed with liver angiosarcomas have poor outcomes because the tumour is aggressive and poorly responsive to adjuvant therapies. Without treatment, the median survival from the time of diagnosis is only 6 months [2,4,5,15] and with surgical treatment the median two-year survival is only 3% [2,4,5,15].

In our case the patient had rupture of the primary, which is a common method of presentation [24,25,26] but it was also a double-edged sword. Although it prompted investigations that discovered the tumour, it can also lead to seeding of malignant cells within the peritoneum [2,4,26] that may adversely affect overall survival.

The pathologic features seen in this case were typical [2,4] and included normal hepatocytes with surrounding neoplastic islands of sinusoidal vascular channels lined by abnormal endothelial cells. On immunohistochemistry, the cells usually stain positively for CD31 [2,4], CD34 [2,4], factor VIII [4], and/or vimentin [2].

#### 4. Conclusion

Angiosarcomas arising in the liver are rare tumours in the Western world. When they occur, they are most often locally advanced. Nevertheless, surgeons should be aggressive in the pursuit of complete resections because this is the only treatment modality that has been shown to have a survival advantage. In this regard, hepatobiliary surgeons should keep the hanging manoeuvre in their armamentarium when performing complex liver resections for locally advanced angiosarcomas.

#### Conflicts of interest

The authors declare that there are no potential conflicts of interest to declare.

#### Sources of funding

No funding was available for the preparation of this manuscript.

#### Ethical approval

Consent from the patient was secured for this case report and is available upon request.

#### Guarantor

The guarantor for this manuscript is Shamir Cawich.

#### Consent

Written informed consent was obtained from the patient for publication of this case report and accompanying images. A copy of the written consent is available for review by the Editor-in-Chief of this journal upon request.

#### Acknowledgements

There are no additional acknowledgements and no source of funding was available for the preparation of this manuscript.

#### Open Access

This article is published Open Access at [scimedirect.com](http://scimedirect.com). It is distributed under the [IJSCR Supplemental terms and conditions](#), which permits unrestricted non commercial use, distribution, and reproduction in any medium, provided the original authors and source are credited.

#### References

- [1] E. Molina, A. Hernandez, Clinical manifestations of primary hepatic angiosarcoma, *Dig. Dis. Sci.* 48 (4) (2003) 677–682.
- [2] C.Y. Chien, C.C. Hwang, C.N. Yeh, H.Y. Chen, J.T. Wu, C.S. Cheung, C.L. Lin, C.L. Yen, W.Y. Chiang Wang, Liver angiosarcoma, a rare liver malignancy, presented with intra-abdominal bleeding due to rupture—a case report, *World J. Surg. Oncol.* 10 (2012) 23.
- [3] J. Gagnier, G. Kienle, D.G. Altman, D. Moher, H. Sox, D.S. Riley, and the CARE group: the CARE guidelines: consensus-based clinical case report guideline development, *J. Clin. Epidemiol.* 67 (1) (2014) 46–51.
- [4] N.C. Huang, S.R. Wann, H.T. Chang, S.L. Lin, J.S. Wang, H.R. Guo, Arsenic, vinyl chloride, viral hepatitis, and hepatic angiosarcoma: a hospital-based study and review of literature in Taiwan, *BMC Gastroenterol.* 11 (2011) 142.
- [5] G.Y. Locker, J.H. Doroshow, L.A. Zwelling, B.A. Chabner, The clinical features of hepatic angiosarcoma: a report of four cases and a review of the English literature, *Med. (Baltimore)* 58 (1979) 48–64.
- [6] C.H. Timaran, O.H. Grandas, J.L. Bell, Hepatic angiosarcoma: long-term survival after complete surgical removal, *Am. Surg.* 66 (2000) 1153–1157.
- [7] A. Forbes, B. Portmann, P. Johnson, R. Williams, Hepatic sarcomas in adults: a review of 25 cases, *Gut* 28 (1987) 668–674.
- [8] J.L. Poggio, D.M. Nagorney, A.G. Nascimento, C. Rowland, P. Kay, R.M. Young, J.H. Donohue, Surgical treatment of adult primary hepatic sarcoma, *Br. J. Surg.* 87 (2000) 1500–1505.
- [9] B.M. Jaffe, W.L. Donegan, F. Watson, J.S. Spratt Jr., Factors influencing survival in patients with untreated hepatic metastases, *Surg. Gynecol. Obstet.* 127 (1968) 1–11.
- [10] K.G. Ishak, Mesenchymal tumor of the liver, in: K. Okuda, R.L. Peters (Eds.), *Hepatocellular Carcinoma*, Wiley, New York, 1976, pp. 247–308.
- [11] T. Koyama, J.G. Fletcher, C.D. Johnson, M.S. Kuo, K. Notohara, L.J. Burgart, Primary hepatic angiosarcoma: findings at CT and MR imaging, *Radiology* 222 (2002) 667–673.
- [12] P.J. Baxter, The British hepatic angiosarcoma register, *Environ. Health Perspect.* 41 (1981) 115–116.
- [13] S.-Y. Ho, C.-C. Tsai, Y.-C. Tsai, H.-R. Guo, Hepatic angiosarcoma presenting as hepatic rupture in a patient with long-term ingestion of arsenic, *J. Formos. Med. Assoc.* 103 (2004) 374–379.
- [14] N.J. Vianna, J.A. Brady, A.T. Cardamone, Epidemiology of angiosarcoma of liver in New York State, *N.Y. State J. Med.* 81 (1981) 895–899.
- [15] H. Falk, J.T. Herbert, L. Edmonds, C.W. Heath Jr., L.B. Thomas, H. Popper, Review of four cases of childhood hepatic angiosarcoma—elevated environmental arsenic exposure in one case, *Cancer* 47 (1981) 382–391.
- [16] J. Belghiti, O.A. Guevara, R. Noun, P.F. Saldinger, R. Kianmanesh, Liver hanging manoeuvre: a safe approach to right hepatectomy without liver mobilization, *J. Am. Coll. Surg.* 193 (1) (2001) 109–111.
- [17] C.L. Liu, S.T. Fan, C.M. Lo, R. Tung-Ping Poon, J. Wong, Anterior approach for major right hepatic resection for large hepatocellular carcinoma, *Ann. Surg.* 232 (2000) 25–31.
- [18] E.C. Lai, S.T. Fan, C.M. Lo, K.M. Chu, C.L. Liu, Anterior approach for difficult major right hepatectomy, *World J. Surg.* 20 (1996) 314–318.
- [19] C.L. Liu, S.T. Fan, S.T. Cheung, C.M. Lo, I.O. Ng, J. Wong, Anterior approach versus conventional approach right hepatic resection for large hepatocellular carcinoma: a prospective randomized controlled study, *Ann. Surg.* 244 (2006) 194–203.
- [20] G. Liddo, E. Buc, G. Nagarajan, M. Hidaka, S. Dokmak, J. Belghiti, The liver hanging manoeuvre, *HPB* 11 (4) (2009) 296–305.
- [21] G. Almogy, S. Lieberman, M. Gips, O. Pappo, Y. Edden, O. Jurim, B. Simon Slasky, B. Uzieli, A. Eid, Clinical outcomes of surgical resections for primary liver sarcoma in adults: results from a single centre, *Eur. J. Surg. Oncol.* 30 (2004) 421–427.
- [22] C.A. Holden, M.F. Spittle, E.W. Jones, Angiosarcoma of the face and scalp, prognosis and treatment, *Cancer* 59 (1987) 1046–1057.
- [23] J.C. Maddox, H.L. Evans, Angiosarcoma of skin and soft tissue: a study of forty-four cases, *Cancer* 48 (1981) 1907–1921.
- [24] M.-H. Tsai, R.-N. Chien, S.-Y. Hsieh, C.-F. Hung, T.-C. Chen, I.-S. Sheen, Primary hepatic angiosarcoma: report of a case involving environmental arsenic exposure, *Changeng Yi Xue Za Zhi* 21 (1998) 469–474.
- [25] C.-C. Tsai, K.-S. Cheng, H.-C. Lai, C.-J. Yu, C.-H. Hsu, Ruptured angiosarcoma of the liver treated by emergency TAE—case report, *China Med. Univ. Reposit. Taichung China Medical University*, 2007.
- [26] S.W. Lee, C.Y. Song, Y.H. Gi, S.B. Kang, Y.S. Kim, S.W. Nam, D.S. Lee, J.O. Kim, Hepatic angiosarcoma manifested as recurrent hemoperitoneum, *World J. Gastroenterol.* 14 (2008) 2935–2938.