

Case Report: Bilateral Corneal Ectasia Developed during Pregnancy after Small-incision Lenticule Extraction

Tian-Ze Huang, MD¹ and Hong-Ying Jin, MD^{2*}

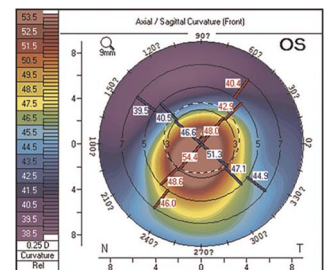
SIGNIFICANCE: This case highlights that hormonal changes during pregnancy could affect the biomechanical stability of the cornea and lead to corneal ectasia during pregnancy after corneal refractive surgery.

PURPOSE: We report an unusual case of bilateral corneal ectasia after small-incision lenticule extraction that developed during pregnancy.

CASE REPORT: A 27-year-old woman experienced post-small-incision lenticule extraction corneal ectasia. Her pre-operative corneal topography was normal, with a minimum central corneal thickness of 538 μm in the right eye and 530 μm in the left eye. The manifest refraction was $-7.75 -0.25 \times 180$ and $-7.50 -0.75 \times 10$, and the lenticule thickness was 140 and 139 μm in the right and left eyes, respectively. After 11 months, in her first trimester, the patient began to experience gradually deteriorating blurred vision. Two years post-operatively, corneal ectasia was diagnosed based on topographic data. The automatic optometer examination was $-7.25 -2.50 \times 42$ in the right eye and $-11.00 -5.00 \times 140$ in the left eye. Later, the patient underwent corneal collagen cross-linking to control further progression and was recommended to wear rigid gas-permeable contact lenses.

CONCLUSIONS: Surgeons should be alert for cornea ectasia after refractive surgery in pregnant patients, as hormonal changes during pregnancy may affect corneal biomechanical stability.

OPEN



Author Affiliations:

¹Chinese Academy of Medical Sciences, Peking Union Medical College, Beijing, China

²Eye Center, Second Affiliated Hospital, School of Medicine, Zhejiang University, Hangzhou, China

*hongyingjin@zju.edu.cn

Optom Vis Sci 2022;99:528–533. doi:10.1097/OPX.0000000000001877

Copyright © 2022 The Author(s). Published by Wolters Kluwer Health, Inc. on behalf of the American Academy of Optometry. This is an open-access article distributed under the terms of the Creative Commons Attribution-Non Commercial-No Derivatives License 4.0 (CCBY-NC-ND), where it is permissible to download and share the work provided it is properly cited. The work cannot be changed in any way or used commercially without permission from the journal.

Post-operative ectasia is the most serious complication after corneal refractive surgery. The incidence of corneal ectasia after excimer laser-assisted *in situ* keratomileusis (LASIK) was reported as 0.66%¹ in 2001, whereas, in 2018, it dropped to 0.033%,² because of the development of advanced pre-operative screening strategies. Recently, small-incision lenticule extraction (SMILE) has been widely applied in corneal refractive surgery. Compared with LASIK, SMILE brings less disruption to the anterior cornea surface and thus is thought to have less risk for ectasia. To date, only six cases of ectasia after SMILE have been reported.^{3–8} This case report is on an unusual case of post-SMILE bilateral corneal ectasia, as the corneal pathology developed with pregnancy.

CASE REPORT

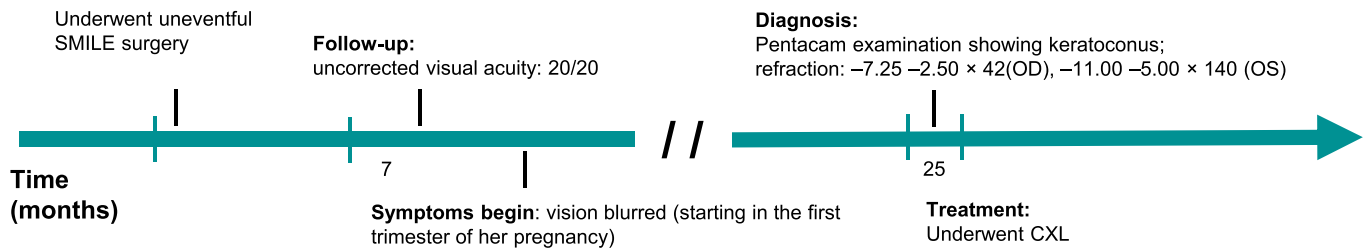
A 27-year-old woman developed bilateral corneal ectasia after SMILE during pregnancy. A clinical timeline of key events is shown in Fig. 1. The patient underwent SMILE surgery in our clinic on November 22, 2017. Pre-operatively, the manifest refraction was $-7.75 -0.25 \times 180$ in the right eye and $-7.50 -0.75 \times 10$ in the left eye, and her corrected distance visual acuity was 20/20 in both eyes. She had no other ocular disease, no family history of keratoconus, and no history of atopy or habit of eye rubbing. The pre-operative Scheimpflug-based corneal topography (Pentacam; Oculus Optikgeräte GmbH, Nuremberg, Germany; Fig. 2) displays

asymmetric astigmatism, with an elevated area on the inferior corneal surface in the right eye, yet with a steepening of less than 1.00 D. The posterior corneal surface elevation map shows the presence of posterior curvature bulging at the thinnest point of the cornea. However, this elevation was within the normal range. The Belin/Ambrosio Enhanced Ectasia Display showed a relatively normal graph without alerting for early stages of keratoconus. The maximum keratometry reading was 44.9 D in the right eye and 45.3 D in the left eye. The central corneal thickness measured with A-type ultrasound was 538 and 530 μm in the right and left eyes, respectively. Informed consent for the procedure was obtained.

Uneventful bilateral SMILE surgery was performed by an experienced surgeon. A femtosecond laser system (VisuMax; Carl Zeiss Meditec, Dublin, CA) was used for refractive correction, with a repetition rate of 500 kHz and pulse energy of 155 nJ. Cap diameter was 7.5 and 7.4 mm in the right and left eyes, respectively, with cap thickness designed at 110 μm , and the minimum lenticule side-cut thickness set at 10 μm . The lenticules were 6.5 and 6.4 mm in diameter and 140 and 139 μm in thickness. The residual stromal bed was 288 and 281 μm , respectively. After surgery, the patient received a topical antibiotic for 1 week and a topical steroid for 2 weeks. Artificial tears were used for 3 months.

The patient's uncorrected visual acuity remained at 20/20 during the 7-month follow-up period, and the manifest refraction was plano. Fig. 3 shows the corneal topographies at 7 months post-operatively.

Symptoms / Diagnosis



Interventions / Outcome

FIGURE 1. Clinical timeline: a 27-year-old woman developed bilateral corneal ectasia after SMILE during pregnancy. CXL = corneal cross-linking; SMILE = small-incision lenticule extraction.

The patient returned to our clinic on December 26, 2019, complaining of gradually deteriorating vision in both eyes for the past 14 months, starting in the first trimester of her pregnancy (11 months after her SMILE surgery). She explained that she did not think that the blurred vision was serious and thus did not return immediately after symptom onset, but waited until she had given birth and stopped breastfeeding. The automatic optometer (Topcon KR-800; Topcon Healthcare, Oakland, NJ) examination showed that her refraction was $-7.25 -2.50 \times 42$ in the right eye and $-11.00 -5.00 \times 140$ in the left eye. Her corrected distance visual acuity was 20/60 in both eyes. Slit-lamp microscopy revealed the conical protrusion without obvious Fleischer's rings and Vogt striae. Fundus examination showed no obvious abnormality. Fig. 4 displays the corneal topography at the time, which was more than 2 years after the refractive surgery. The topography showed inferior steeping with maximum corneal curvature of 50.4 D in the right eye and 54.4 D in the left eye and a minimum thickness of 357 and 353 μm , respectively. The patient was diagnosed with bilateral ectasia after SMILE surgery, and she underwent accelerated transepithelial corneal cross-linking in both eyes. She is currently instructed to continue clinical observation and was recommended rigid gas-permeable contact lenses (right eye: base curve, 7.10 mm; diameter, 9.20 mm; power, -6.75 D; corrected distance visual acuity, 20/20; left eye: base curve, 7.00 mm; diameter, 9.40 mm; power, -8.00 D; corrected distance visual acuity, 20/20).

DISCUSSION

To our knowledge, this is the first reported case of post-SMILE corneal ectasia in a female patient, as well as ectasia associated with pregnancy, and the seventh report in all population.³⁻⁸ Some cases of post-SMILE ectasia have been reported in patients with forme fruste keratoconus or mild keratoconus.^{3,5,6,8} However, others occurred without any predisposing risk factors.^{4,7} These reports are summarized in Table 1.

Corneal ectasia is one of the most serious complications after refractive surgery. Laser-assisted *in situ* keratomileusis and SMILE require cutting of the corneal lamellae that may reduce the cornea's biomechanical stability. However, SMILE preserves the collagen networks of the anterior stroma that account for 60% of the total corneal tensile strength.⁹ Therefore, the anterior corneal integrity and the corneal biomechanical strength are both better after

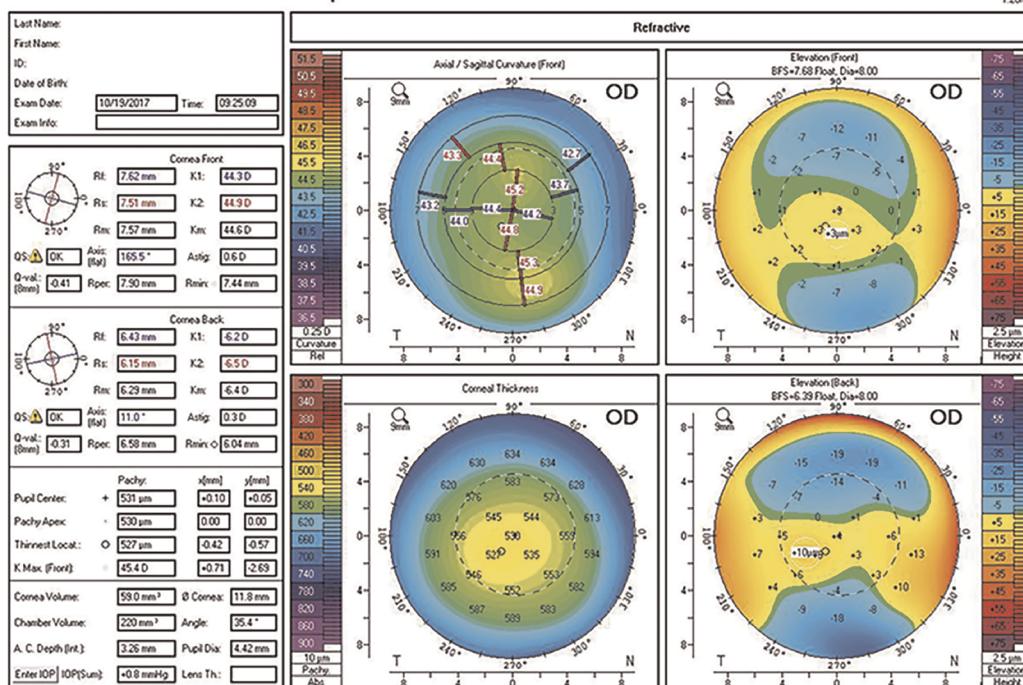
SMILE than those after LASIK. According to a retrospective case review of 1992 eyes by Moshirfar et al.,¹⁰ the rate of purely iatrogenic post-LASIK ectasia was 0.05%, whereas the total rate was 0.25%. Despite SMILE's wide application in recent years, only six cases of post-operative corneal ectasia have been reported, and the incidence of post-SMILE cornea ectasia cannot be obtained from the literature. As generally recommended for both SMILE and LASIK, the mean percentage of tissue altered (percentage of tissue altered = (flap thickness + ablation depth)/pre-operative central corneal thickness) should not exceed 40%.^{9,11} Percentage of tissue altered higher or equal to 40% should be considered the most significant predictor of ectasia, with significantly higher odds ratio than residual stromal bed, age, and the ectasia risk score in patients with normal topography after LASIK.¹¹ However, there is no definite safe limit for mean percentage of tissue altered in an at-risk cornea with suspicious topography or tomography.⁹ In the present case, the cap thickness was set at 110 μm to ensure a residual stromal bed more than 280 μm . Mean percentage of tissue altered was 46% for both eyes, and this is a possible risk factor for the occurrence of ectasia.

Pregnancy leads to dramatic changes in all body systems, including the eyes and the visual system; these effects are most commonly transient but can occasionally be permanent. Pathological changes due to pregnancy can be either ocular changes occurring *de novo* during pregnancy or an already existing ocular pathology that is modified by pregnancy. Previous studies have reported that corneal curvature tends to increase during the second and third trimesters¹² and the possible association of keratoconus progression with pregnancy.¹³⁻¹⁶ Bilgihan et al.¹³ reported cases of keratoconus without any accompanying diseases during pregnancy. They stated that patients with previously stable keratoconus can experience progression during pregnancy, which ceased post-partum or with termination.¹³ Padmanabhan et al.¹⁵ reported a case of corneal ectasia during the first trimester of pregnancy, 18 months after LASIK. Hafezi and Iseli¹⁶ reported a case of pregnancy-related exacerbation of iatrogenic ectasia despite corneal cross-linking after LASIK. A study has shown that women exposed to external estrogen have a higher risk for regression after photorefractive keratectomy or LASIK.¹⁷ Studies have found that estrogen receptors have been identified in the cornea, and its activation significantly reduces the corneal stiffness. During pregnancy, increased level of estrogen may predispose biomechanically weak corneas (such as keratoconic or post-refractive laser surgery cornea) to the development or progression of ectasia.¹⁸

A

OCULUS - PENTACAM 4 Maps Refractive

1.2087


 Oculus Optikgeräte GmbH
 Münchholzhauser Str. 29

35582 Wetzlar

 Tel: (0641) 20 05-0
 Fax: (0641) 20 05-255

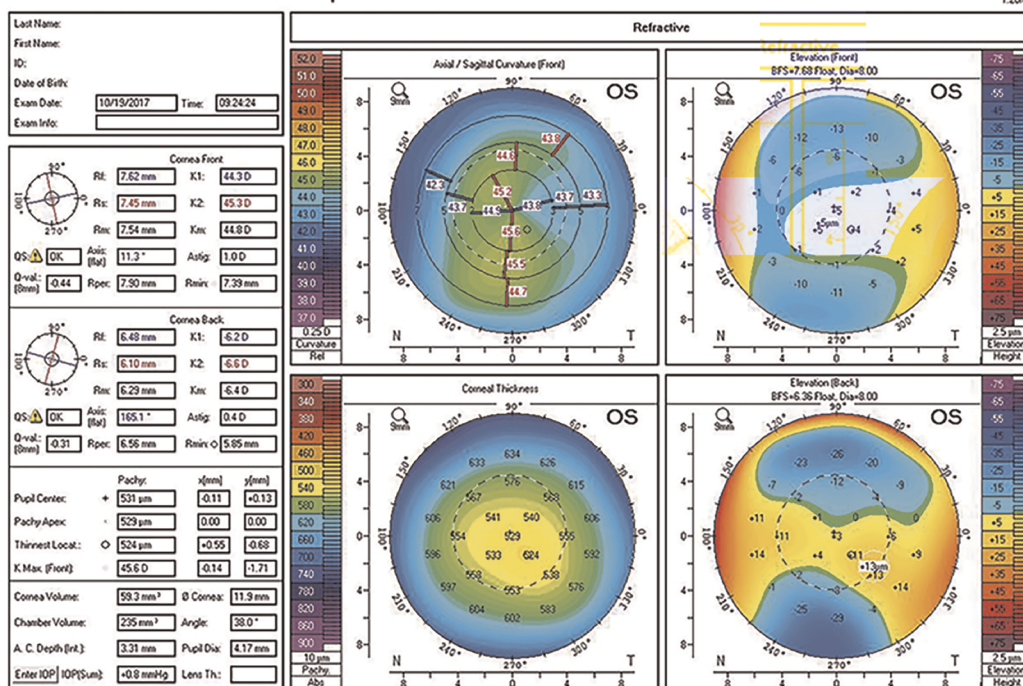
www.oculus.de



B

OCULUS - PENTACAM 4 Maps Refractive

1.2087


 Oculus Optikgeräte GmbH
 Münchholzhauser Str. 29

35582 Wetzlar

 Tel: (0641) 20 05-0
 Fax: (0641) 20 05-255

www.oculus.de

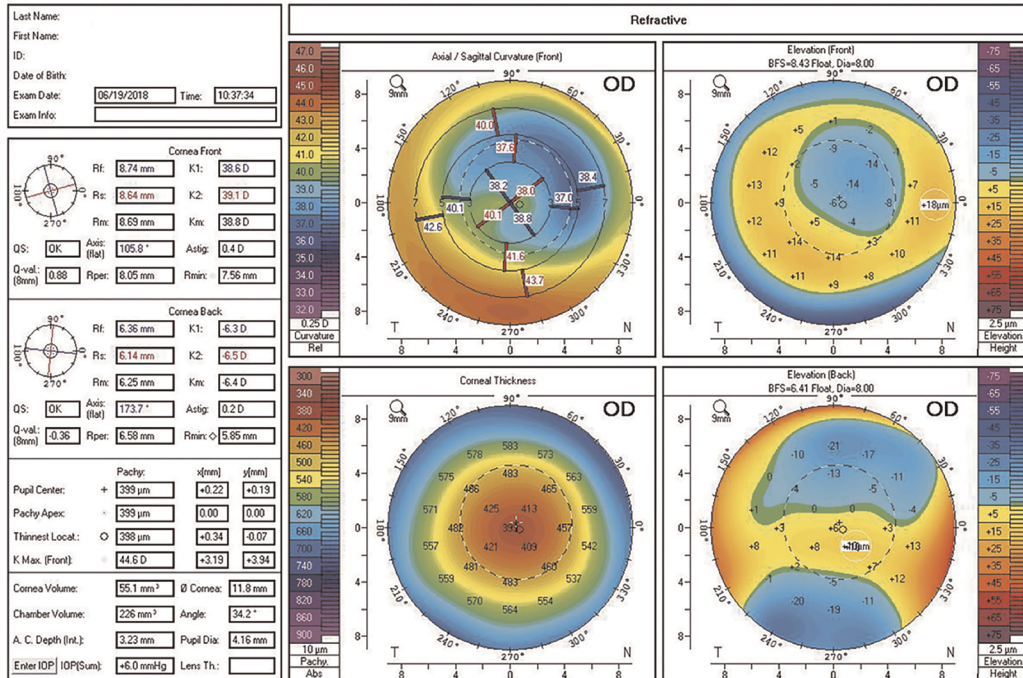


FIGURE 2. Pre-operative Scheimpflug topography of both eyes: (A) right eye and (B) left eye. The corneal topography displays asymmetric astigmatism, with an elevated area on the inferior corneal surface in the right eye, yet with a steepening of less than 1.00 D.

A

OCULUS - PENTACAM 4 Maps Refractive

1.2087


 Oculus Optikgeräte GmbH
 Münchholzhauser Str. 29

35582 Wetzlar

 Tel: (0641) 20 05-0
 Fax: (0641) 20 05-255

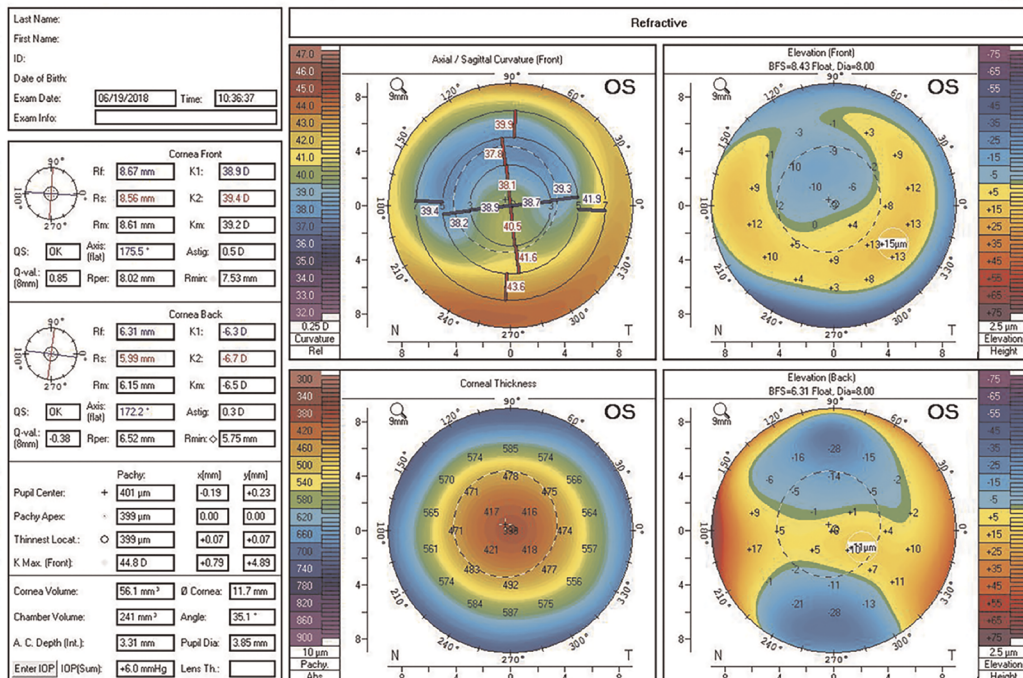
www.oculus.de



B

OCULUS - PENTACAM 4 Maps Refractive

1.2087


 Oculus Optikgeräte GmbH
 Münchholzhauser Str. 29

35582 Wetzlar

 Tel: (0641) 20 05-0
 Fax: (0641) 20 05-255

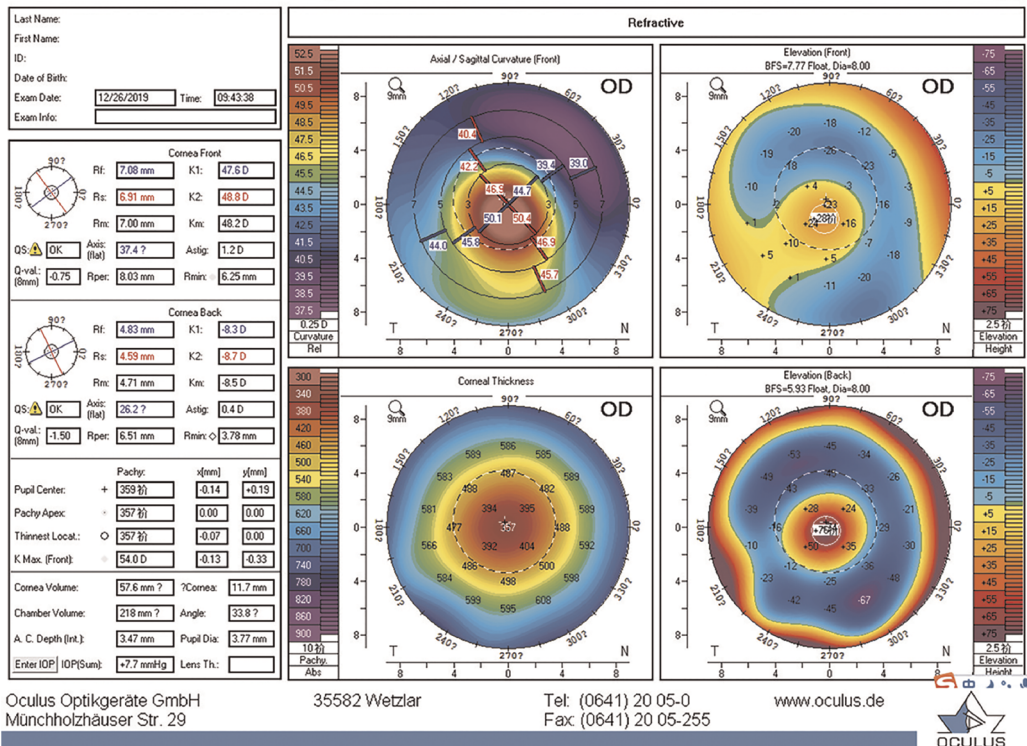
www.oculus.de



FIGURE 3. Seven-month post-operative Scheimpflug topography of both eyes: (A) right eye and (B) left eye. There are no signs of early detection of corneal ectasia.

A

OCULUS - PENTACAM 4 Maps Refractive



B

OCULUS - PENTACAM 4 Maps Refractive

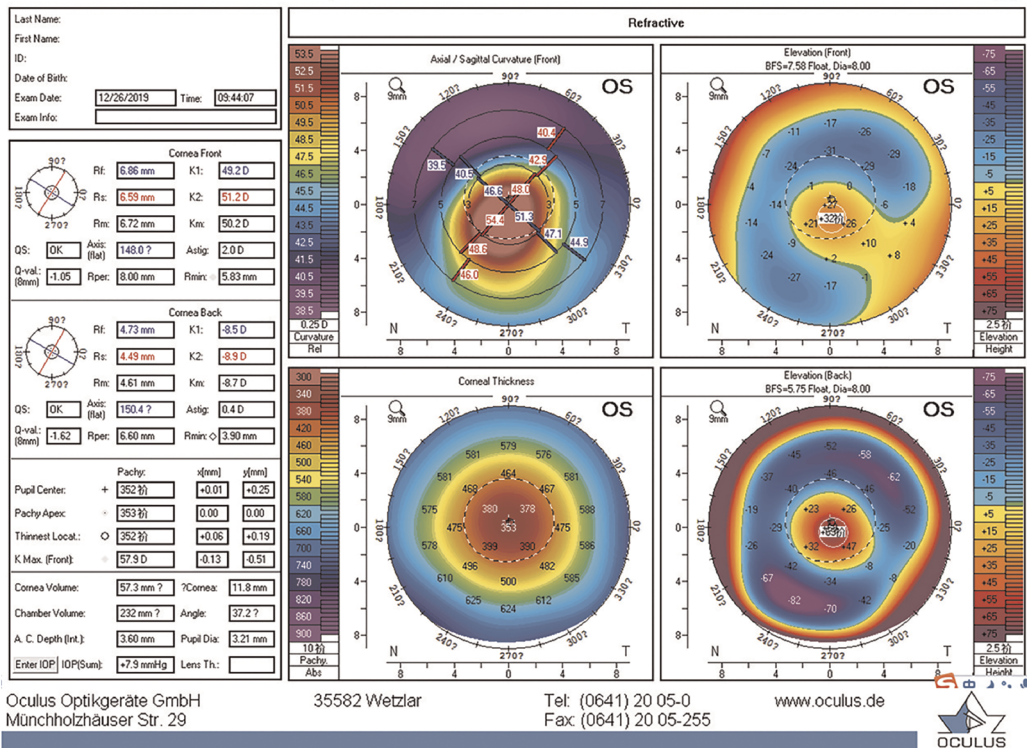


FIGURE 4. Two-year post-operative Scheimpflug topography of both eyes: (A) right eye and (B) left eye. Both eyes showed keratoconic changes with inferior steepening. The maximum corneal curvature was 50.4 D in the right eye and 54.4 D in the left eye.

TABLE 1. Summary of patient characteristic in reports of post-SMILE corneal ectasia

Author	Age (y)	Sex	Ectasia time after surgery	Eye	Preoperative refraction	CCT (μm)	CT (μm)	OZ (mm)	LT (μm)	RSB (μm)	Forme fruste keratoconus before surgery
Wang et al. (2015) ³	19	Male	6.5 mo	Right	-6.75 -1.00 × 45	546	120	6.6	137	274	Yes
				Left	-6.75 -0.75 × 140	542	120	6.6	134	273	Yes
Sachdev et al. (2015) ⁴	26	Male	12 mo	Left	-3.50 -1.50 × 165	513	110	6.0	82	305	No
El-Naggar (2015) ⁵	33	Male	6 mo	Right	-2.00 -1.00 × 65	481	NM	NM	NM	NM	Yes
				Left	-2.25 -1.25 × 105	482	NM	NM	NM	NM	Yes
Mattila and Holopainen (2016) ⁶	24	Male	28 mo	Right	-2.00 -0.50 × 170	527	NM	NM	NM	NM	Yes
				Left	-1.50 -1.50 × 173	559	NM	NM	NM	NM	Yes
Gavrilov et al. (2018) ⁷	43	Male	4 y	Right	-3.75 -1.25 × 5	522	120	6.5	94	308	No
Pazo et al. (2019) ⁸	23	Male	12 mo	Right	-3.50	582	135	6.5	63	384	Yes
Huang and Jin (present study-2020)	27	Female	11 mo	Right	-7.75 -0.25 × 180	538	110	6.5	140	288	No
				Left	-7.50 -0.75 × 10	530	110	6.4	139	281	No

CCT = central corneal thickness; CT = cap thickness; LT = lenticule thickness; NM = not mentioned; OZ = optical zone; RSB = residual stromal bed; SMILE = small-incision lenticule extraction.

Previous studies have reported that keratonic corneas are associated with an increased level of collagenase and matrix metalloproteinase, and a decreased level of tissue inhibitors of matrix metalloproteinase. Matrix metalloproteinase plays a critical role in the development and pathogenesis collagenase in keratoconus.¹³⁻¹⁵ Relaxin, which persists at a high level during pregnancy, promotes matrix metalloproteinase and collagen-degrading enzyme synthesis, which inhibit tissue inhibitors of matrix metalloproteinases synthesis. The physiological increase in relaxin hormone may lead

to increased tissue remodeling and thus decreased corneal rigidity.^{13,14} Therefore, gestational hormonal factors can be attributed to keratoconus development or progression.

To our knowledge, this is the first reported case of post-SMILE corneal ectasia in a female patient associated with pregnancy. Hormonal changes during pregnancy are a risk factor for the induction of cornea ectasia after corneal refractive surgery. High mean percentage of tissue altered and low residual stromal bed should be considered ectasia risks for both SMILE and LASIK surgeries.

ARTICLE INFORMATION

Submitted: May 1, 2021

Accepted: January 2, 2022

Funding/Support: Natural Science Foundation of Zhejiang Province (No. LY20H120010; to H-YJ).

Conflict of Interest Disclosure: None of the authors have reported a financial conflict of interest.

Study Registration Information: ChiCTR-ORC-17011040.

Author Contributions and Acknowledgments: Data Curation: H-YJ; Formal Analysis: H-YJ; Funding Acquisition: H-YJ; Investigation: H-YJ; Methodology: H-YJ; Project Administration: H-YJ; Resources: H-YJ; Supervision: T-ZH, H-YJ; Writing – Original Draft: T-ZH, H-YJ; Writing – Review & Editing: T-ZH, H-YJ.

The authors thank Xiu-Ming Jin, who performed accelerated transepithelial corneal cross-linking on the patient.

REFERENCES

- Pallikaris IG, Kymionis GD, Astyrakakis NI. Corneal Ectasia Induced by Laser *in Situ* Keratomileusis. *J Cataract Refract Surg* 2001;27:1796–802.
- Bohac M, Koncarevic M, Pasalic A, et al. Incidence and Clinical Characteristics of Post LASIK Ectasia: A Review of over 30,000 LASIK Cases. *Semin Ophthalmol* 2018;33:869–77.
- Wang Y, Cui C, Li Z, et al. Corneal Ectasia 6.5 Months after Small-incision Lenticule Extraction. *J Cataract Refract Surg* 2015;41:1100–6.
- Sachdev G, Sachdev MS, Sachdev R, et al. Unilateral Corneal Ectasia following Small-incision Lenticule Extraction. *J Cataract Refract Surg* 2015;41:2014–8.
- El-Naggar MT. Bilateral Ectasia after Femtosecond Laser-assisted Small-incision Lenticule Extraction. *J Cataract Refract Surg* 2015;41:884–8.
- Mattila JS, Holopainen JM. Bilateral Ectasia after Femtosecond Laser-assisted Small Incision Lenticule Extraction (SMILE). *J Refract Surg* 2016;32:497–500.
- Gavrilov JC, Atia R, Borderie V, et al. Unilateral Corneal Ectasia after Small-incision Lenticule Extraction in a 43-year-old Patient. *J Cataract Refract Surg* 2018;44:403–6.
- Pazo EE, McNeely RN, Arba-Mosquera S, et al. Unilateral Ectasia after Small-incision Lenticule Extraction. *J Cataract Refract Surg* 2019;45:236–41.
- Moshirfar M, Albarracin JC, Desautels JD, et al. Ectasia following Small-incision Lenticule Extraction (SMILE): A Review of the Literature. *Clin Ophthalmol* 2017;11:1683–8.
- Moshirfar M, Smedley JG, Muthappan V, et al. Rate of Ectasia and Incidence of Irregular Topography in Patients with Unidentified Preoperative Risk Factors Undergoing Femtosecond Laser-assisted LASIK. *Clin Ophthalmol* 2014;8:35–42.
- Ambrósio R, Jr., Dawson DG, Belin MW. Association between the Percent Tissue Altered and Post-laser *in Situ* Keratomileusis Ectasia in Eyes with Normal Preoperative Topography. *Am J Ophthalmol* 2014;158:1358–9.
- Park SB, Lindahl KJ, Temnycky GO, et al. The Effect of Pregnancy on Corneal Curvature. *CLAO J* 1992;18:256–9.
- Bilgihan K, Hondur A, Sul S, et al. Pregnancy-induced Progression of Keratoconus. *Cornea* 2011;30:991–4.
- Naderan M, Jahanrad A. Topographic, Tomographic and Biomechanical Corneal Changes during Pregnancy in Patients with Keratoconus: A Cohort Study. *Acta Ophthalmol* 2017;95:e291–6.
- Padmanabhan P, Radhakrishnan A, Natarajan R. Pregnancy-triggered iatrogenic (Post-laser *in Situ* Keratomileusis) Corneal Ectasia—A Case Report. *Cornea* 2010;29:569–72.
- Hafezi F, Iseli HP. Pregnancy-related Exacerbation of Iatrogenic Keratectasia despite Corneal Collagen Crosslinking. *J Cataract Refract Surg* 2008;34:1219–21.
- O'Doherty MA, O'Doherty JV, O'Keefe M. Outcome of LASIK for Myopia in Women on Hormone Replacement Therapy. *J Refract Surg* 2006;22:350–3.
- Spoerl E, Zubaty V, Raiskup-Wolf F, et al. Oestrogen-induced Changes in Biomechanics in the Cornea as a Possible Reason for Keratectasia. *Br J Ophthalmol* 2007;91:1547–50.