



Association between the Levofloxacin Plasma Concentration and Neurological Adverse Events in an Elderly Patient

Gaeun Kang^a
Seung Hyun Min^b
Jong-Keun Kim^{a,c}
Kyung Wook Kang^b

^aDivision of Clinical Pharmacology,
Chonnam National University Hospital,
Gwangju, Korea

^bDepartment of Neurology,
Chonnam National University
Medical School, Chonnam National
University Hospital, Gwangju, Korea

^cDepartment of Pharmacology,
Chonnam National University Medical
School, Hwasun, Korea

Dear Editor,

Levofloxacin is a fluoroquinolone antibiotic used to treat bacterial infections such as community-acquired pneumonia and complicated urinary-tract infections. The labels of drugs across the fluoroquinolone class mention side effects related to the central nervous system (CNS). The US Food and Drug Administration and the European Medicines Agency recently issued a warning regarding the CNS side effects related to fluoroquinolones.^{1,2} Here we report rare adverse effects of the fluoroquinolone drug levofloxacin along with the plasma drug concentration at the time of each occurrence, and assess the causality between levofloxacin administration and such events.

A 78-year-old man with diabetes mellitus, hypertension, and a past history of old left basal ganglia hemorrhage and cerebellar lacunar infarct (10 years previously) visited our hospital with a seizure. He had no prior psychiatric history or seizure episodes. For 2 days prior to his visit he had received daily intravenous infusions of 500 mg of levofloxacin for pneumonia at another hospital. On the second day after his admission at that hospital he presented with a confused mental state, difficulty of sleep initiation, and visual hallucinations in which he reported seeing people who were not there. His other medications at the time did not include sedative agents such as hypnotics, but included the following oral medications daily: clopidogrel (75 mg), choline alfoscerate (400 mg), rebamipide (100 mg), nizatidine (150 mg), and erdosteine (300 mg). On the third day of hospitalization the patient experienced two generalized tonic-clonic seizures (at around 4 a.m. and 8 a.m.), and so he was transferred to our hospital.

Levofloxacin had not been administered on the transfer day, on which his neurological signs normalized and he slept well. Upon admission to our hospital the patient exhibited an alert mental status without fever or focal neurological deficits except for the sequelae of the previous stroke. We ruled out other conditions such as dyselectrolytemia, hypoglycemia, and diabetic ketoacidosis via laboratory testing. Brain computed tomography and magnetic resonance imaging also produced no new abnormal findings. However, electroencephalography showed focal left-side slowing without epileptiform discharges. Our patient was diagnosed with remote poststroke seizure and was treated with oral lamotrigine for the seizures and intravenous levofloxacin for pneumonia.

On the fourth day of hospitalization, 500 mg of intravenous levofloxacin was restarted in our hospital at approximately 9 a.m. (producing a levofloxacin plasma concentration of 0.18 µg/mL), and by 11 p.m. the patient gradually showed irritability and a confused mental state again, at which time the levofloxacin concentration had reached 2.36 µg/mL. On the fifth day of hospitalization, 250 mg of levofloxacin (half the previous dose) was administered. The plasma concentration of levofloxacin at 2 hours after that injection was 4.87 µg/mL, and the patient continued to show irritability and confusion despite the absence of fever and decreased inflammatory markers. He also reported that all of the nurses were trying to hurt him. After

© This is an Open Access article distributed under the terms of the Creative Commons Attribution Non-Commercial License (<https://creativecommons.org/licenses/by-nc/4.0>) which permits unrestricted non-commercial use, distribution, and reproduction in any medium, provided the original work is properly cited.

Received January 16, 2019

Revised May 13, 2019

Accepted May 14, 2019

Correspondence

Kyung Wook Kang, MD
Department of Neurology,
Chonnam National University
Medical School,
Chonnam National University Hospital,
42 Jebong-ro, Dong-gu,
Gwangju 61469, Korea
Tel +82-62-220-6173
Fax +82-62-228-3461
E-mail kang8774@hanmail.net

Jong-Keun Kim, MD, PhD
Department of Pharmacology,
Chonnam National University
Medical School,
264 Seoyang-ro, Hwasun-eup,
Hwasun 58128, Korea
Tel +82-61-379-2831
Fax +82-61-373-6974
E-mail jkkim57@jnu.ac.kr

the sixth day of hospitalization, levofloxacin was not administered and the previous CNS adverse events dissipated (Fig. 1). We then used a combination of azithromycin plus ceftriaxone instead of levofloxacin to treat his pneumonia.

Levofloxacin-induced CNS adverse events have been reported previously, but there has not been sufficient evidence of a causal link.³ These adverse reactions were probably due to the known effect of fluoroquinolones inhibiting gamma-aminobutyric acid (GABA).⁴ Possible risk factors for CNS side effects in patients taking quinolones include a history of seizures or epilepsy, electrolyte imbalance, a history of renal or hepatic failure, increased age, and excessive doses.⁵

The serum levofloxacin concentrations in our patient were determined using a rapid and selective liquid chromatography—tandem mass spectrometry method. A positive correlation between the levofloxacin concentration and CNS toxicity was suggested. The neurological symptoms including seizure occurred in our patient after two injections of the drug under suspicion. These events could not be explained by other concomitantly administered drugs. The discontinuation of levofloxacin resulted in abatement of the CNS symptoms, and the adverse events were readily explainable by known pharmacological mechanisms of levofloxacin. We therefore reported these events to the regional pharmacovigilance center (Chonnam National University Hospital), and the committee interpreted the causality as being ‘certain.’ This report was also given

to the Korea Institute of Drug Safety & Risk Management.

The CNS symptoms unintentionally reappeared following a second course of levofloxacin. This case study has demonstrated ‘certain’ causality between levofloxacin and the observed CNS adverse effects as defined by the categorization of the World Health Organization Uppsala Monitoring Centre.⁶ Since the patient was an elderly man with a history of stroke, these risk factors may have predisposed him to the development of CNS adverse effects induced by levofloxacin. This case indicates that clinicians should administer levofloxacin with caution due to the possibility of it inducing CNS adverse events.

Author Contributions

Conceptualization: Gaeun Kang, Kyung Wook Kang. Data curation: Kyung Wook Kang, Gaeun Kang, Seung Hyun Min. Formal analysis: Gaeun Kang, Jong-Keun Kim. Investigation: Seung Hyun Min, Gaeun Kang, Kyung Wook Kang. Methodology: Jong-Keun Kim, Gaeun Kang, Kyung Wook Kang. Project administration: Gaeun Kang, Kyung Wook Kang. Resources: Seung Hyun Min. Software: Gaeun Kang, Kyung Wook Kang. Supervision: Jong-Keun Kim, Kyung Wook Kang. Validation: Gaeun Kang, Jong-Keun Kim. Visualization: Gaeun Kang. Writing—original draft: Gaeun Kang, Kyung Wook Kang. Writing—review & editing: Jong-Keun Kim, Gaeun Kang, Kyung Wook Kang.

ORCID iDs

Gaeun Kang <https://orcid.org/0000-0001-9841-1139>
 Seung Hyun Min <https://orcid.org/0000-0001-8665-2779>
 Jong-Keun Kim <https://orcid.org/0000-0001-5683-8732>
 Kyung Wook Kang <https://orcid.org/0000-0001-9362-8670>

Conflicts of Interest

The authors have no potential conflicts of interest to disclose.

Acknowledgements

This work was supported by Basic Science Research Program through the National Research Foundation of Korea (NRF) funded by the Ministry of Education (NRF-2018R1D1A1B07048873) and Chonnam National University Hospital Biomedical Research (BCRI-18020).

REFERENCES

1. U.S. FDA. FDA reinforces safety information about serious low blood sugar levels and mental health side effects with fluoroquinolone antibiotics; requires label changes [Internet]. Silver Spring, MD: U.S. FDA; 2018 [cited 2018 Jul 10]. Available from: <https://www.fda.gov/drugs/drug-safety-and-availability/fda-reinforces-safety-information-about-serious-low-blood-sugar-levels-and-mental-health-side>.
2. European Medicines Agency. Fluoroquinolone and quinolone antibiotics: PRAC recommends new restrictions on use following review of disabling and potentially long-lasting side effects Share [Internet]. Amsterdam: European Medicines Agency; 2018 [cited 2018 May 10]. Available from: <https://www.ema.europa.eu/en/news/fluoroquinolone-antibiotics-prac-recommends-new-restrictions-use-following-review>.
3. Bellon A, Perez-Garcia G, Coverdale JH, Chacko RC. Seizures associated with levofloxacin: case presentation and literature review. *Eur J Clin Pharmacol* 2009;65:959-962.
4. Akahane K, Tsutomi Y, Kimura Y, Kitano Y. Levofloxacin, an optical isomer of ofloxacin, has attenuated epileptogenic activity in mice and

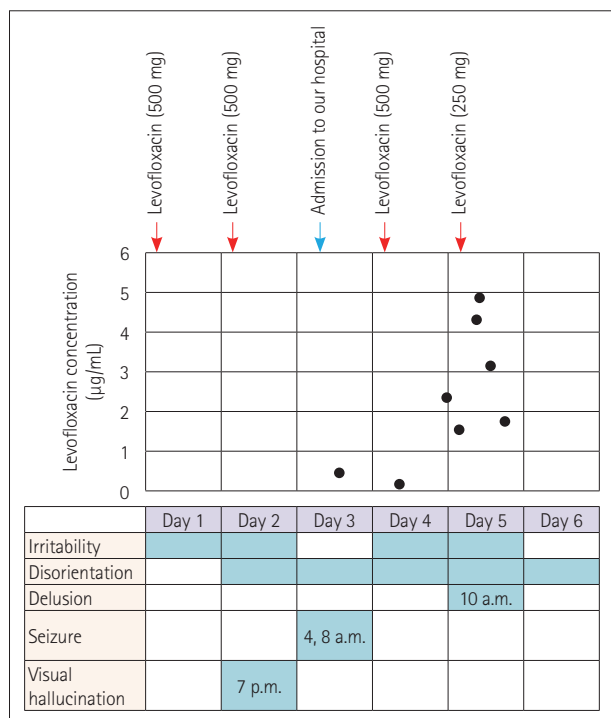


Fig. 1. Plasma levels of levofloxacin during the clinical course of our patient.

- inhibitory potency in GABA receptor binding. *Chemotherapy* 1994; 40:412-417.
- Tomé AM, Filipe A. Quinolones: review of psychiatric and neurological adverse reactions. *Drug Saf* 2011;34:465-488.
 - Edwards IR, Biriell C. Harmonisation in pharmacovigilance. *Drug Saf* 1994;10:93-102.