



Penetrating deep pelvic injury due to “less-lethal” beanbag munitions: a case report and policy implications

Christopher S Schenk ¹, Soum D Lokeshwar,^{1,2} Matthew D Riedel,^{1,3} Kimberly A Davis ^{1,4}

¹Yale School of Medicine, New Haven, Connecticut, USA

²Department of Urology, Yale School of Medicine, New Haven, Connecticut, USA

³Division of Orthopaedic Trauma, Department of Orthopaedics and Rehabilitation, Yale School of Medicine, New Haven, Connecticut, USA

⁴Division of Trauma, Surgical Critical Care and Surgical Emergencies, Department of Surgery, Yale School of Medicine, New Haven, Connecticut, USA

Correspondence to

Dr Matthew D Riedel; matthew.riedel@yale.edu

Received 22 April 2021

Accepted 23 April 2021

ABSTRACT

“Less-lethal” munitions are designed to cause incapacitation and are often used by law enforcement officers. Although these munitions are not designed to cause severe injury, recent reports have demonstrated that they can cause severe injury, permanent disability, and death. The long-term consequences of injury due to less-lethal munitions are not well understood. We present a case of osteomyelitis and pelvic abscess secondary to a retained beanbag munition following penetrating injury in the setting of a patient with delayed presentation for care. The patient underwent surgical removal of the retained beanbag munition and irrigation and debridement of the osteomyelitis and pelvic abscess with an excellent functional outcome. We discuss the public health and policy implications of serious injury due to less-lethal munitions.

BACKGROUND

“Less-lethal” munitions are designed to cause incapacitation and are often used by law enforcement officers for crowd control.¹ These include projectiles made of rubber, plastic, foam, or metal pellets covered in cloth (ie, beanbag munitions).² Although less-lethal munitions are not designed to inflict penetrating trauma or cause severe injury, recent reports have demonstrated that this type of munition can indeed cause severe injury associated with significant morbidity and mortality.^{3–7} A systematic review conducted by Haar and colleagues⁸ demonstrated that 15% of patients injured by these munitions experienced significant disability, with a mortality rate of 3%. Injury to the head and neck was described as particularly devastating.⁸ The long-term consequences of injury due to less-lethal munitions are not well understood. We present a case of osteomyelitis and pelvic abscess secondary to a retained beanbag munition following penetrating injury in the setting of a patient with delayed presentation for care.

CASE PRESENTATION

A previously healthy patient in their 20s presented to the emergency department with left hip pain and a non-healing, draining wound about the left anterolateral hip of 1 month duration. The patient reported worsening of pain with walking, sometimes requiring the use of a cane, dysuria, and episodic hematuria. The patient denied any

precipitating trauma, fevers, or chills. The patient had a history of opioid use disorder and did not take any daily medications. On physical examination, the temperature was 37.4 degrees Celsius, blood pressure was 120/76 mm Hg, heart rate was 72 beats per minute, respiratory rate was 16 breaths per minute, and oxygen saturation was 100% on room air. A 2.5 cm × 2 cm wound overlay the left hip with granulation tissue and purulent drainage (figure 1). A cotton-tipped probe could be inserted 1.5 cm into the soft tissue without direct tract noted to the bone.

INVESTIGATIONS

A complete blood count was within normal limits. Urinalysis revealed 3 to 5 red blood cells/high power field, >30 white cell count/high power field, and a few bacteria. A superficial wound culture obtained in the emergency department grew methicillin-sensitive *Staphylococcus aureus* (MSSA). X-rays and CT of the pelvis demonstrated a 2.3 × 1.4 × 4.5 cm foreign body abutting the urinary bladder with adjacent left superior pubic ramus fracture and associated cortical margin irregularity about the acetabulum and left superior pubic ramus concerning for osteomyelitis (figure 2). CT scan also noted a 12 cm long soft tissue tract tracking from the pelvis to the skin about the left hip wound.

CLINICAL COURSE

The patient was admitted to the trauma surgery service and was started on intravenous ceftriaxone and metronidazole. Orthopedic surgery, urology, and infectious disease medicine were consulted. The patient underwent cystoscopy given the proximity of the foreign body to the bladder and presence of microscopic hematuria. Cystoscopy revealed edema and inflammatory changes of the left bladder wall, without extravasation. The patient was subsequently brought to the operating room by orthopedic and trauma surgery for irrigation and debridement of the deep pelvis and removal of the foreign body. A standard Pfannenstiel approach was used to expose the deep pelvis. Peritoneal violation was identified along the left pelvic sidewall adjacent to the bladder without noted intra-abdominal injury. A rectangular cloth object with multiple metallic beads contained within it was removed from an area of scar tissue within the deep pelvis immediately adjacent to the left wall of the bladder. A separate plastic object which was partially incarcerated in the left superior

© Author(s) (or their employer(s)) 2021. Re-use permitted under CC BY-NC. No commercial re-use. See rights and permissions. Published by BMJ.

To cite: Schenk CS, Lokeshwar SD, Riedel MD, et al. *Trauma Surg Acute Care Open* 2021;**6**:e000754.

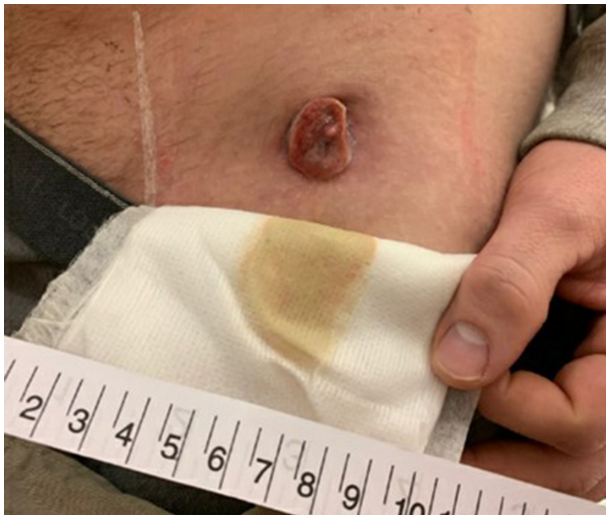

Figure 1 Entry wound about the left hip with purulent drainage and granulation tissue growth.

pubic ramus fracture site was also removed. These objects were consistent with a beanbag munition and shell casing (figure 3). The left superior pubic ramus fracture site was then inspected and debrided. The fracture, and overall pelvic ring, was stable and did not require fixation. Object removal and pelvic ring stability were confirmed using intraoperative fluoroscopic imaging and stress examination of the pelvis (figure 4). The soft tissue cutaneous tract was then also debrided, and the wounds and pelvis were thoroughly irrigated. Two grams of vancomycin powder were delivered into the wound before closure. MSSA was isolated from intraoperative cultures of the deep pelvis and left superior pubic ramus and the patient was started on intravenous cefazolin for treatment of osteomyelitis. At the conclusion of the surgery, mild hematuria was noted within the Foley catheter which resolved without intervention within a few hours. A repeat cystogram redemonstrated absence of extravasation, ruling out intraoperative injury to the bladder.

OUTCOME AND FOLLOW-UP

After surgical removal of the foreign body and irrigation and debridement of osteomyelitis and pelvic abscess, the patient had an uncomplicated hospital course. The patient continued a 6-week course of intravenous cefazolin for osteomyelitis. The patient was able to ambulate without assistance, had good pain control, and did not have further episodes of hematuria. The patient was discharged on hospital day 11 to a short-term rehabilitation center to complete the course of intravenous antibiotic therapy.

DISCUSSION

We present an unusual case of superior pubic ramus osteomyelitis and pelvic abscess with cutaneous fistula after penetrating injury from beanbag munition. This report contributes to the existing literature on severe injury from beanbag munitions. de Brito and colleagues³ report seven penetrating injuries in a retrospective case series of 39 individuals injured by beanbag munitions. They report one fatality secondary to massive hemothorax in the setting of penetrating thoracic trauma.³ Olson and colleagues⁷ report four cases of intracranial hemorrhage in a case series of 19 patients who sustained injuries from beanbag munitions in the setting of protests for racial justice.

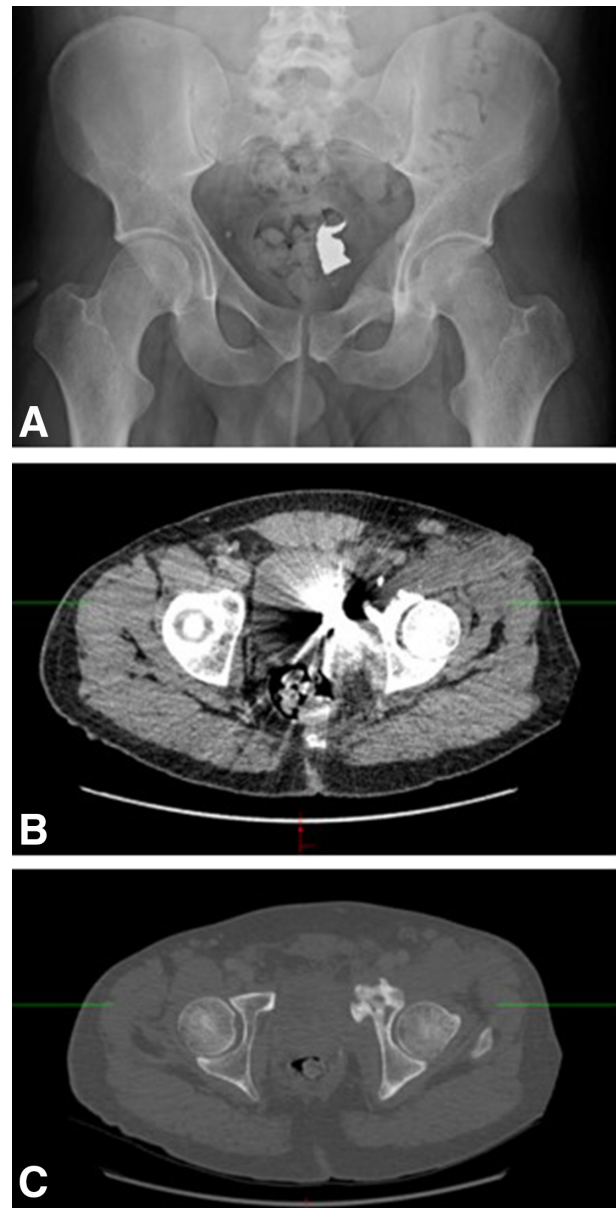


Figure 2 X-ray (A) and CT of the pelvis revealed a 2.3×1.4×4.5 cm foreign body abutting the urinary bladder (B) with adjacent cortical margin irregularity of the acetabulum and left superior pubic ramus (C) concerning for osteomyelitis.

The long-term sequelae of injury from less-lethal munitions are unknown. Ocular trauma and blindness are well described and are, unfortunately, common causes of long-term disability.^{9–11} Limb amputation¹² and perforated viscus requiring ostomy¹³ have also been reported following injury from less-lethal munitions. To our knowledge, osteomyelitis and pelvic abscess due to retained beanbag munition have not yet been previously reported.

This injury likely caused a substantial impact on multiple domains of this patient's life. Prior to admission but after the injury, the patient reported limited mobility and significant pain associated with the injury which exacerbated their opioid use. The prolonged hospital admission and need for short-term rehabilitation likely caused significant wage losses. Fortunately, the patient returned to baseline mobility rapidly during admission once the foreign body was removed. Further research should

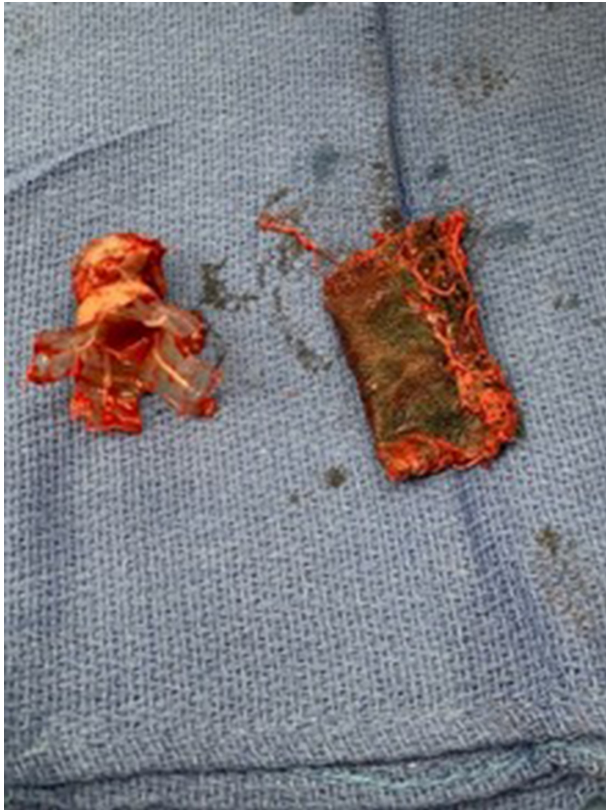

Figure 3 Beanbag munition and shell casing removed from the deep pelvis.

elucidate these long-term sequelae of injuries due to less-lethal munitions.

Importantly, the patient reported here did not present to care immediately after injury, likely experiencing barriers to seeking care. It is possible that the infectious complications of his injury would not have been as severe with prompt presentation to care. Because beanbag munitions are most commonly used by law enforcement, it is possible that the patient feared legal repercussions of seeking treatment.

PUBLIC HEALTH AND POLICY IMPLICATIONS

Injury from less-lethal munitions continues to pose an important public health challenge. Commonly, less-lethal munitions are used by military and police against marginalized populations, including individuals in Kashmir,¹¹ Palestine,⁹ Northern Ireland,⁶ and recently during protests for racial justice in the USA.^{5,7} Future research should examine the extent and nature of serious injuries due to less-lethal munitions, including the long-term sequelae of these injuries. As these injuries disproportionately affect individuals from marginalized groups who may experience barriers in presenting to care, healthcare systems may need to implement targeted outreach to potentially affected individuals to ensure optimal treatment, particularly in settings where the use of less-lethal munitions is common (eg, protests or areas of civil conflict).

Policies regarding the use of less-lethal munitions must reflect the findings from recent reports that these munitions can cause serious harm or death. In light of this risk, law enforcement agencies and governing bodies should consider updating procedures to employ alternative strategies for crowd control. The American Academy of Ophthalmology recently issued a statement calling for the end of use of rubber bullets for crowd dispersal following

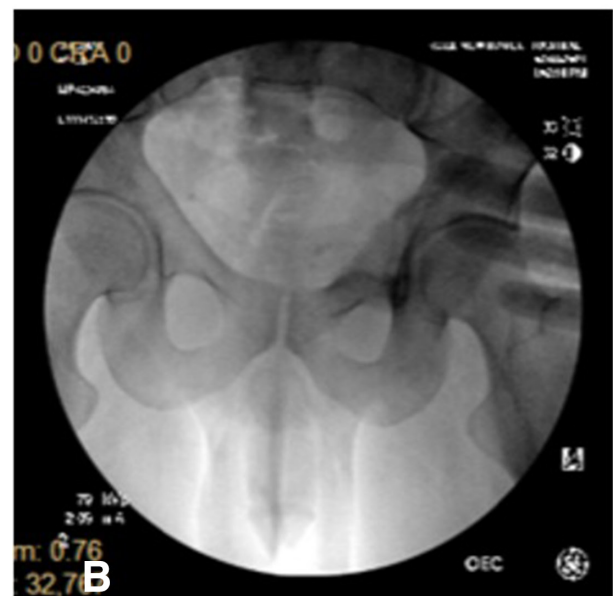
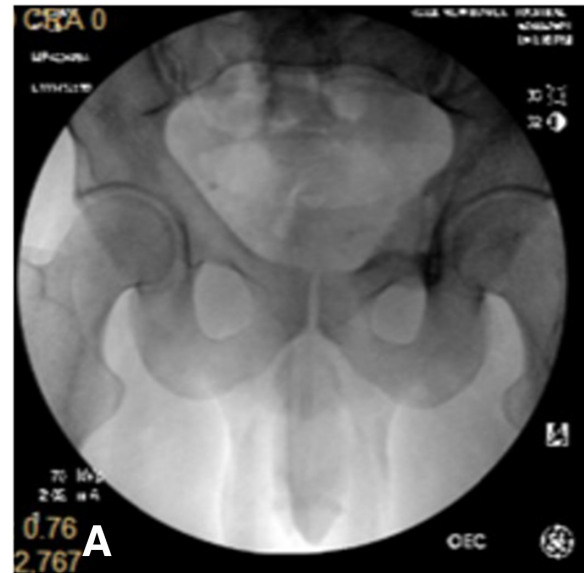


Figure 4 Intraoperative fluoroscopy of the pelvis under no stress (A) and stress (B). The superior ramus fracture was found to be stable.

their use across the USA in the summer of 2020 in response to protests for racial justice.¹⁴ We echo these concerns and add that our experience caring for the patient presented here and previously published reports have demonstrated the risk posed by less-lethal munitions to multiple organ systems with the potential for disability or death.

Acknowledgements The authors would like to thank the patient presented here for contributing to our understanding of severe injury from “less-lethal” munitions.

Contributors CSS and SDL reviewed the electronic medical record and literature. All authors contributed to the final article. MDR, an attending orthopedic surgeon, and KAD, an attending trauma and emergency general surgeon, oversaw the care of the patient presented.

Funding The authors have not declared a specific grant for this research from any funding agency in the public, commercial or not-for-profit sectors.

Competing interests KAD is the Associate Editor of Trauma Surgery & Acute Care Open for Challenges in Trauma and Acute Care Surgery, and is a member of the editorial board of the Journal of Trauma and Acute Care Surgery.

Patient consent for publication Not required.

Ethics approval The content of this article does not constitute research involving human participants and therefore was exempt from institutional review board review.

Provenance and peer review Not commissioned; internally peer reviewed.

Open access This is an open access article distributed in accordance with the Creative Commons Attribution Non Commercial (CC BY-NC 4.0) license, which permits others to distribute, remix, adapt, build upon this work non-commercially, and license their derivative works on different terms, provided the original work is properly cited, appropriate credit is given, any changes made indicated, and the use is non-commercial. See: <http://creativecommons.org/licenses/by-nc/4.0/>.

ORCID iDs

Christopher S Schenck <http://orcid.org/0000-0002-9659-2033>

Kimberly A Davis <http://orcid.org/0000-0001-5660-5293>

REFERENCES

- Hunter S, Greaves I. Baton rounds. *Trauma* 2002;4:29–37.
- Hubbs K, Klinger D. *Impact Munitions data base of use and effects*: Justice USDO, 2004.
- de Brito D, Challoner KR, Sehgal A, Mallon W. The injury pattern of a new law enforcement weapon: the police bean bag. *Ann Emerg Med* 2001;38:383–90.
- Hughes D, Maguire K, Dunn F, Fitzpatrick S, Rocke LG. Plastic baton round injuries. *Emerg Med J* 2005;22:111–2.
- Kaske EA, Cramer SW, Pena Pino I, Do TH, Ladd BM, Sturtevant DT, Ahmadi A, Taha B, Freeman D, Wu JT, et al. Injuries from Less-Lethal weapons during the George Floyd protests in Minneapolis. *N Engl J Med Overseas Ed* 2021;384:774–5.
- Maguire K, Hughes DM, Fitzpatrick MS, Dunn F, Rocke LGR, Baird CJ. Injuries caused by the attenuated energy projectile: the latest less lethal option. *Emerg Med J* 2007;24:103–5.
- Olson KA, Haselden LE, Zaunbrecher RD, Weinfeld A, Brown LH, Bradley JA, Cardenas TCP, Trust MD, Coopwood B, Teixeira PG, et al. Penetrating Injuries from “Less Lethal” Beanbag Munitions. *N Engl J Med Overseas Ed* 2020;383:1081–3.
- Haar RJ, Iacopino V, Ranadive N, Dandu M, Weiser SD. Death, injury and disability from kinetic impact projectiles in crowd-control settings: a systematic review. *BMJ Open* 2017;7:e018154.
- Balouris CA. Rubber and plastic bullet eye injuries in Palestine. *Lancet* 1990;335:415.
- Barnes AC, Hudson LE, Jain N. Rubber bullet ocular trauma. *Ophthalmology* 2020;127:1190.
- Khan S, Maqbool A, Abdullah N, Keng MQ. Pattern of ocular injuries in stone pelters in Kashmir Valley. *Saudi J Ophthalmol* 2012;26:327–30.
- Wani ML, Ahangar AG, Ganie FA, Wani SN, Lone GN, Dar AM, Bhat MA, Singh S. Pattern, presentation and management of vascular injuries due to pellets and rubber bullets in a conflict zone. *J Emerg Trauma Shock* 2013;6:155–8.
- Mahajna A, Aboud N, Harbaji I, Agbaria A, Lankovsky Z, Michaelson M, Fisher D, Krausz MM. Blunt and penetrating injuries caused by rubber bullets during the Israeli-Arab conflict in October, 2000: a retrospective study. *Lancet* 2002;359:1795–800.
- Ophthalmology AAo. Statement on Rubber Bullets for Crowd Dispersion. 2020. <https://www.aao.org/newsroom/news-releases/detail/statement-on-rubber-bullets-crowd-dispersion>.