

Treatment of Subtrochanteric Femoral Fractures Using Selfdynamisable Internal Fixator

Ivan D. Micic, MD, Milorad B. Mitkovic, MD, Il-Hyung Park, MD*, Desimir B. Mladenovic, MD, Predrag M. Stojiljkovic, MD, Zoran B. Golubovic, MD, In-Ho Jeon, MD[†]

Clinic for Orthopedic Surgery and Traumatology, Faculty of Medicine, Clinical Center, Nis, Serbia,

**Department of Orthopaedic Surgery, Kyungpook National University Hospital, Daegu,*

[†]Department of Orthopaedic Surgery, Asan Medical Center, Seoul, Korea

Background: Surgical treatment is the preferred method for treating subtrochanteric femoral fractures and the variety of extramedullary and intramedullary implants continues to evolve. The purpose of our study was to retrospectively evaluate the clinical and radiological results of subtrochanteric fractures that are treated with the Selfdynamisable internal fixator.

Methods: From January 2000 to January 2004, we treated 49 consecutive patients who had subtrochanteric fractures. According to the AO classification, 8 (16.3%) fractures were type 32-A, 16 (32.7%) were type 32-B and 25 (51%) fractures were type 32-C. The mean follow-up time was 22.3 months.

Results: The average operating time was 45 minutes (range, 32 to 90 minutes). The average blood loss was 250 mL (range, 125 to 350 mL). The average hospital stay was 10 days (range, 7 to 59 days). Implant failure was not observed and union was achieved in all the patients. Deep infection occurred in one (2%) patient in the early postoperative period. Fracture union was achieved at a mean of 14 weeks. Varus malalignment less than 10 degree was noted in three (6.1%) patients at the end of follow-up. Thirty-five patients were pain-free and 14 had mild pain.

Conclusions: The selfdynamisable internal fixator was successfully used for subtrochanteric fracture. It provides a short operative time, low blood loss, spontaneous biaxial dynamisation and healing in an optimal period of time without the need for secondary intervention.

Keywords: *Subtrochanteric fracture, Selfdynamisable internal fixator, Dynamisation*

Subtrochanteric fractures result from high energy trauma in young patients and most cases are associated with multiple injuries.¹⁾ In elderly patients, this fracture is often caused by low energy trauma because of osteoporosis.²⁾ Surgical treatment is the preferred method for subtrochanteric femoral fracture and a variety of implants have been introduced and they continue to evolve.³⁾ These implants fall into two main categories. Intramedullary nail fixation is

associated with short operative times and minimal blood loss and they have better biomechanical properties than do the extramedullary devices.⁴⁻⁶⁾ Extramedullary devices, dynamic condylar screws and 95° condylar blade-plates provide strong fixation in the cancellous bone of the neck and head with considerable rotational stability.⁷⁻⁹⁾ Implant failure in both groups was significantly associated with early full weight bearing and particularly in the elderly patients.¹⁰⁾

With keeping in mind the important factors for femoral union such as a minimal invasive technique, biological osteosynthesis and axial compression, we have used a new implant called the selfdynamisable internal fixator (SIF)¹¹⁾ (Traffix Ltd., Nis, Serbia) in clinical practice

Received September 17, 2008; Accepted January 13, 2010

Correspondence to: In-Ho Jeon, MD

Department of Orthopaedic Surgery, Asan Medical Center, 388-1 Pungnap 2-dong, Songpa-gu, Seoul 138-736, Korea

Tel: +82-2-3010-3530, Fax: +82-2-3010-2823

E-mail: jeonchoi@chol.com

Copyright © 2010 by The Korean Orthopaedic Association

This is an Open Access article distributed under the terms of the Creative Commons Attribution Non-Commercial License (<http://creativecommons.org/licenses/by-nc/3.0>) which permits unrestricted non-commercial use, distribution, and reproduction in any medium, provided the original work is properly cited.

Clinics in Orthopedic Surgery • pISSN 2005-291X eISSN 2005-4408

for treating femoral fractures since 1998. We conducted this study to review the outcome of using the SIF for treating patients with subtrochanteric fractures.

METHODS

From January 2000 to January 2004 we treated 49 patients with subtrochanteric fractures (Fig. 1A and Fig. 2A) using the SIF and we retrospectively analyzed the results. This study was approved by the university IRB. The patients with open and pathological fracture were not included in the study. Nineteen patients (38.8%) had multiple injuries (three with head trauma, five with thorax trauma, five with blunt abdominal injury and fifteen with various other fractures). There were 28 males and 21 women with

a mean age of 64 years (range, 31 to 92 years). Eighteen patients younger than 50 years were injured by high energy trauma, and mostly in traffic accidents. Thirty one elderly patients older than 50 years were injured by low energy trauma, and mostly by falls. The fractures were classified according to the AO classification.¹²⁾ Eight (16.3%) fractures were type 32-A (all type A3.1), 16 (32.7%) were type 32-B (eight type B1.1, six type B2.1, and two type B3.1), and 25 (51%) fractures were type 32-C (seventeen type C1.1, five type C2.2, and three type C3.1).

The average time from injury to operation was four days (range, 2 to 22 days). Surgery was often delayed due to the medical problems of the elderly patients. Preoperative planning included selecting the appropriate length of the implant (the length of the implant was either

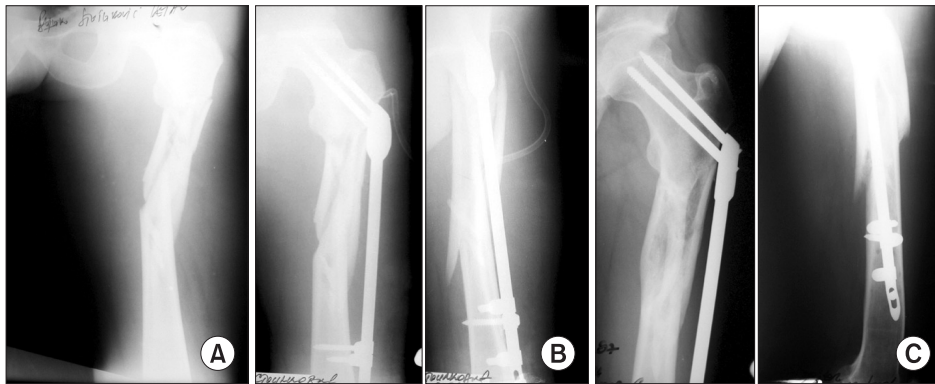


Fig. 1. (A) A subtrochanteric femoral fracture after a car vehicle accident. (B) The subtrochanteric femoral fracture was fixed with the selfdynamisable internal fixator. The implant length was 250 mm and the fracture was stabilized with two screws placed in the neck and head of the femur, with three self screws through the clamps in the femoral shaft and with one cortical screw through the antirotating/dynamic unit at the distal end of the implant. (C) Fracture healing is evident 15 months after surgery.

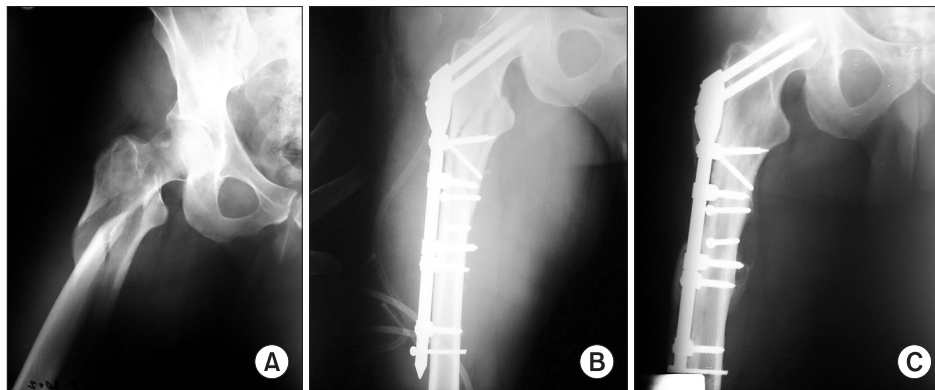


Fig. 2. (A) Fifty-four-year-old man sustained a subtrochanteric femoral fracture. (B) The subtrochanteric femoral fracture was stabilized using a self-dynamisable internal fixator. Two screws were placed in the femoral neck, five self-incising screws were placed through the clamps in the femoral diaphysis and three additional cortical screws as lag screws for femoral fragments fixation were also used. One cortical screw was used through the antirotating/dynamic unit at the distal end of the implant. (C) Consolidation of the fracture is apparent on the plain radiograph taken 20 months after surgery.

200 or 250 mL in all the patients). All the patients received pre and postoperative antibiotics for three days and also low molecular weight heparin (Lovenox[®], Sanofi-Aventis, Bridgewater, NJ, USA).

Implant Characteristics

This SIF, which was developed by the senior author (MBM), consists of three components: 1) a bar with a trochanteric unit on one end and a dynamic, antirotating unit on the opposite end, 2) clamps, and 3) screws (Fig. 3). The trochanteric unit has three diagonally oriented holes (at 130 degrees) for the 7 mm diameter screws for the femoral neck and head. One of these holes is just proximal to the fracture site and two are distal to the fracture site. The SIF is made of stainless steel (ASTM F 138-2).

Operative Technique

All the patients were positioned supine on a radiolucent fracture table and the operation were done with the patients under general anesthesia. Manual traction and indirect fracture reduction were attempted before the surgery, with checking the length, axial alignment and rotation clinically using radiographs, as well as checking the required implant length.

A standard, lateral, five to six centimeters long incision was made just distally from the trochanteric ridge. The tip of the SIF is positioned on the lateral cortex over the periosteum and then it was pushed distally toward the lateral femoral condyle. The tip of the bar easily passes under the vastus and intermedius and over the periosteum. If preferable, one or more clamps can be introduced onto the bar near to the trochanteric unit

before this step. Then a five centimeters long distal incision is made and the tip of the SIF should appear in this incision site. After the tip appears, two or three clamps are introduced over the tip onto the bar and the SIF is pushed further until the proximal end of the trochanteric unit is positioned 1.5 to 2 cm distal from the trochanteric ridge. The trochanteric unit has three holes, but two screws need to be introduced into the neck and head of the femur under radiology control. One hole remains empty except in very corpulent patients. Through the distal incision, one cortical antirotating screw is placed through the distal end of the dynamic unit and two or three self-incising screws are placed through the clamps after drilling (Fig. 1B). These screws need to be placed in different positions so that they are orientated to converge one from the other. If the fractured area was exposed, lag screws or screws through the clamps can be placed into the fractured bone fragments without detaching the soft tissue (Fig. 2B).

Isometric quadriceps exercise was begun from the second postoperative day. Full weight bearing was allowed from the third day after surgery for all the patients. Radiographic and clinical follow-up were performed monthly for the first 6 months and then at three and six months intervals thereafter. The evaluation included time to union (months) and the angular and rotational malalignment (external/internal rotation, varus/valgus, recurvatum/procurvatum, limb length discrepancy). The complications were recorded, as well as pain, the walking ability and the hip motion.

RESULTS

The average operating time was 45 minutes (range, 32 to 90 minutes). The blood loss averaged 250 mL (range, 125 to 350 mL). The average hospital stay was 10 days (range, 7 to 59 days). The mean follow-up time was 22.3 months (range, 15 to 30 months). Implant failure was not observed and fracture union was achieved in all the patients. The mean union time was 14 weeks (range, 12 to 20 weeks) (Fig. 1C and Fig. 2C). Varus malalignment less than 10° occurred in three (6.1%) patients at the end of follow-up. Shortening of the limb due to dynamisation was recorded in 17% of the patients with the average shortening being 0.6 cm (range, 0.2 to 1.0 cm) (Fig. 4). Rotational malalignment and deep venous thrombosis were not recorded in any patients. At the time of the review, 35 patients were pain-free and 14 had mild pain and they used medicine. Ten patients had pain due to arthritic changes in the lumbosacral region of the spine, while four patients had pain because of hip arthrosis. None of the fractures required a

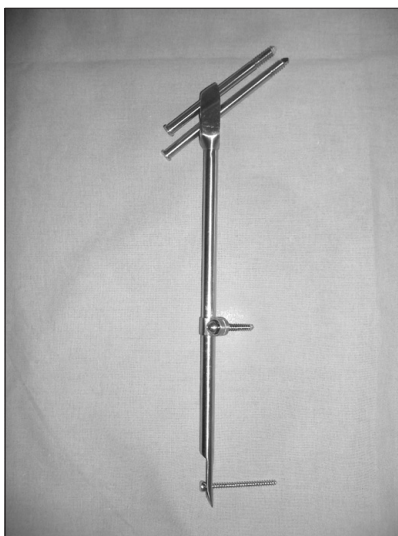

Fig. 3. Selfdynamisable internal fixator.

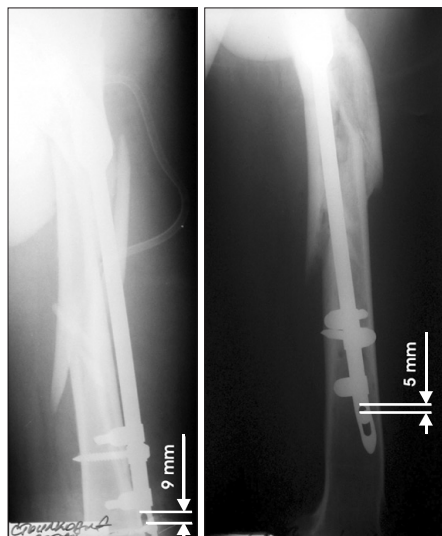

Fig. 4. Plain radiographs show dynamisation at the distal end of the selfdynamisable internal fixator. On the left radiograph taken during the time of healing, the screw is more proximal in the dynamic unit (marked on the radiographs) and the distance between the distal clamp with a screw and the proximal end of the dynamic unit is longer than the immediate postoperative distance.

bone graft.

All patients under 50 years old returned to their pre-injury residential status except one who had hip motion limitation. That patient required a cane for ambulation.

DISCUSSION

The goals of subtrochanteric fracture fixation are restoration of the normal neck-shaft angle, reestablishment of leg length-rotation, union and avoidance of abductor weakness. The proximal bone fragments of the subtrochanteric area are relatively small and they provide limited area for fixation, and high tensile and compressive stresses cross this region.¹³⁾ These fractures are known to be difficult to treat and various intra- and extramedullary devices have been advocated for this purpose in the past.

Intramedullary devices have been shown to have a minimal failure rate due to its rigid axial and rotational stability.^{4-6,14)} The central position of the intramedullary nail prevents excessive collapse with immediate weight bearing.^{5,13,15)} However, complications such as intraoperative nail protrusion, cephalic screw cutting-out, delayed union, malunion and fractures at the tip of the nail have been reported.^{9,13)}

As the medial cortex is subjected to compression forces and the lateral cortex is subjected to tensile force,

extramedullary implants in the lateral cortex have been reported to easily fail.^{16,17)} The Medoff sliding plate has obvious theoretical biomechanical advantages because it provides biaxial dynamisation and it reduces a rate of failure.¹⁷⁾ The potential disadvantage of extramedullary implants are the extended soft-tissue damage with the accompanying blood loss, difficulties in reduction, an increased surgical time, nonunion, malunion, implant rupture and pulling-out.¹⁸⁻²⁴⁾ However, the biological plating technique minimizes some of these disadvantages because this does not damage the medullary blood supply as occurs in reamed intramedullary nailing nor the vascularity of the medial fragment.⁹⁾ Using the SIF, we were able to achieve acceptable results for the treatment of subtrochanteric fractures. There were only three patients (6.1%) with varus malunion (varus angulation less than 10°) and this did not require further intervention. Stripping of the soft tissue of the lateral cortex is kept to the minimum so that the vitality of the fragments is not further compromised. Therefore, the result of the current report is encouraging with no failure and with an excellent union rate (100%). Early joint mobilization and ambulation without complications were our goals and we applied this SIF for treating all the fractures, and even the type A fracture.

We do not have the biomechanical data on this implant, yet stability of the implant was achieved by two pins on the trochanteric unit and by screws with clamps fixed on the femoral diaphysis and this provided three-dimensional fixation of each main bone fragment, as each clamp can rotate around the bar and screws can be applied in a convergent configuration (from different sides of the bar). The antirotation screw also contributes to the stability of the implant, and not only by preventing rotation.

In our clinical series, the use of the SIF was proven to be safe and successful for treating subtrochanteric fracture. It provides a short operative time, low blood loss, spontaneous biaxial dynamisation and healing in an optimal period of time without secondary intervention. One of the advantages of our implant is the low cost of our implant because the results we achieved with this implant were similar to those of the other costly implants. For all patients full weight bearing can be allowed shortly after surgery without the complications that accompany the other implants.

CONFLICT OF INTEREST

No potential conflict of interest relevant to this article was reported.

REFERENCES

1. Robinson CM, Court-Brown CM, McQueen MM, Christie J. Hip fractures in adults younger than 50 years of age. Epidemiology and results. *Clin Orthop Relat Res.* 1995; (312):238-46.
2. Koval KJ, Egol KA, Zuckerman JD. Hip fractures and dislocations. In: Dee R, Hurst LC, Gruber MA, Kottmeier SA, ed. *Principles of orthopaedic practice.* 2nd ed. New York: McGraw-Hill; 1997. 465-81.
3. Datir SP, Bedi GS, Curwen CH. Unreamed femoral nail with spiral blade in subtrochanteric fractures: experience of 55 cases. *Injury.* 2004;35(2):191-5.
4. Borens O, Wettstein M, Kombot C, Chevalley F, Mouhsine E, Garofalo R. Long gamma nail in the treatment of subtrochanteric fractures. *Arch Orthop Trauma Surg.* 2004;124(7): 443-7.
5. Hotz TK, Zellweger R, Kach KP. Minimal invasive treatment of proximal femur fractures with the long gamma nail: indication, technique, results. *J Trauma.* 1999;47(5):942-5.
6. Roberts CS, Nawab A, Wang M, Voor MJ, Seligson D. Second generation intramedullary nailing of subtrochanteric femur fractures: a biomechanical study of fracture site motion. *J Orthop Trauma.* 2002;16(4):231-8.
7. Blatter G, Janssen M. Treatment of subtrochanteric fractures of the femur: reduction on the traction table and fixation with dynamic condylar screw. *Arch Orthop Trauma Surg.* 1994;113(3):138-41.
8. Brien WW, Wiss DA, Becker V Jr, Lehman T. Subtrochanteric femur fractures: a comparison of the Zickel nail, 95 degrees blade plate, and interlocking nail. *J Orthop Trauma.* 1991; 5(4):458-64.
9. Vaidya SV, Dholakia DB, Chatterjee A. The use of a dynamic condylar screw and biological reduction techniques for subtrochanteric femur fracture. *Injury.* 2003;34(2):123-8.
10. Kulkarni SS, Moran CG. Results of dynamic condylar screw for subtrochanteric fractures. *Injury.* 2003;34(2):117-22.
11. Mitkovic M, Bumbasirevic M, Golubovic Z, et al. New biological method of internal fixation of the femur. *Acta Chir Iugosl.* 2005;52(2):113-6.
12. Muller ME, Nazarian S, Koch P. *The AO classification of fractures.* New York: Springer; 1988.
13. Tornetta P 3rd. Subtrochanteric femur fracture. *J Orthop Trauma.* 2002;16(4):280-3.
14. Grosse A, Favreul E, Taglang G. The long gamma nail experience: 79 cases. *Orthopedics* 1994;2(1):3-5.
15. Hoover GK, Browner BD, Cole JD, Comstock CP, Cotler HB. Initial experience with a second generation locking femoral nail: the Russell-Taylor reconstruction nail. *Contemp Orthop.* 1991;23(3):199-208.
16. Cheng MT, Chiu FY, Chuang TY, Chen CM, Chen TH, Lee PC. Treatment of complex subtrochanteric fracture with the long gamma AP locking nail: a prospective evaluation of 64 cases. *J Trauma.* 2005;58(2):304-11.
17. Miedel R, Ponzer S, Tornkvist H, Soderqvist A, Tidermark J. The standard Gamma nail or the Medoff sliding plate for unstable trochanteric and subtrochanteric fractures: a randomised, controlled trial. *J Bone Joint Surg Br.* 2005; 87(1):68-75.
18. Kinast C, Bolhofner BR, Mast JW, Ganz R. Subtrochanteric fractures of the femur: results of treatment with the 95 degrees condylar blade-plate. *Clin Orthop Relat Res.* 1989; (238):122-30.
19. Nungu KS, Olerud C, Rehnberg L. Treatment of subtrochanteric fractures with the AO dynamic condylar screw. *Injury.* 1993; 24(2):90-2.
20. Ruff ME, Lubbers LM. Treatment of subtrochanteric fractures with a sliding screw-plate device. *J Trauma.* 1986; 26(1):75-80.
21. Sanders R, Regazzoni P. Treatment of subtrochanteric femur fractures using the dynamic condylar screw. *J Orthop Trauma.* 1989;3(3):206-13.
22. Siebenrock KA, Muller U, Ganz R. Indirect reduction with a condylar blade plate for osteosynthesis of subtrochanteric femoral fractures. *Injury.* 1998;29 Suppl 3:C7-15.
23. Lunsjo K, Ceder L, Thorngren KG, et al. Extramedullary fixation of 569 unstable intertrochanteric fractures: a randomized multicenter trial of the Medoff sliding plate versus three other screw-plate systems. *Acta Orthop Scand.* 2001; 72(2):133-40.
24. Goldhagen PR, O'Connor DR, Schwarze D, Schwartz E. A prospective comparative study of the compression hip screw and the gamma nail. *J Orthop Trauma.* 1994;8(5):367-72.