



Eleven minutes of bispectral index data during the cessation of spontaneous circulation: a case description

Huixian Bian[#], Xue Yan[#], Xijia Sun, Wenfei Tan

Department of Anesthesiology, the First Hospital of China Medical University, Shenyang, China

[#]These authors contributed equally to this work.

Correspondence to: Xijia Sun; Wenfei Tan. Department of Anesthesiology, the First Hospital of China Medical University, Nanjingbei Street 155#, Shenyang 110001, China. Email: xijia0822@163.com; winfieldtan@hotmail.com.

Submitted May 17, 2022. Accepted for publication Oct 27, 2022. Published online Nov 15, 2022.

doi: 10.21037/qims-22-498

View this article at: <https://dx.doi.org/10.21037/qims-22-498>

Introduction

Currently, the bispectral index (BIS) is widely used in anesthetic monitoring during surgeries. A recent systematic review and meta-analysis demonstrated that the BIS can predict neurological outcomes in patients experiencing return of spontaneous circulation after cardiac arrest (CA), noting good diagnostic performance (1).

Moreover, evidence from recent case reports suggests that good neurological recovery can occur in post-CA patients experiencing very low BIS values after resumption of spontaneous circulation (2). Herein, we provide a description based on 11 minutes of the BIS data of a patient who underwent CA after anesthesia induction and ultimately presented with predicted fair neurological outcomes at our medical center.

Case presentation

A 53-year-old female was admitted to our hospital with a diagnosis of coronary disease and unstable angina pectoris. In April 2021, the patient underwent coronary angiography and intravascular ultrasonography (IVUS), followed by percutaneous transluminal coronary angioplasty (PTCA) at the left main (LM) lesion (showing 90% stenosis) and stent implantation.

In October 2021, she was readmitted with the same diagnosis and subsequently underwent coronary angiography followed by PTCA and stent implantation at the left anterior descending-LM (LAD-LM) lesion (the LM

showed 90% stenosis in the stent), which was assisted with intra-aortic balloon pump (IABP) use.

She was once again readmitted with a diagnosis of coronary artery disease in February 2022, which was now accompanied with acute non-ST segment elevation myocardial infarction (Killip class II), valvular heart disease, and aortic insufficiency (moderate-severe regurgitation). Coronary artery bypass grafting, mechanical aortic valve replacement, and IABP implantation were performed in March 2022.

At the time of her surgery, BIS monitoring using the Vista monitor (Medtronic-Covidien, Dublin, Ireland) was started after radial artery puncture and dexmedetomidine sedation. At 10:34 am, the patient was noted to be irritable, sweaty, and unable to lie supine. At 11:15 am, anesthesia was induced, after which the patient's blood pressure dropped and her circulation collapsed. Cardiopulmonary bypass (CPB) was subsequently established between 11:18 am and 11:29 am with cardiopulmonary resuscitation, and there was no spontaneous circulation during this period (although with a non-zero BIS; see *Figure 1A*). The total CPB time was 244 minutes, and the total operation time was 666 minutes (*Figure 1A*).

The patient was unresponsive the night after the operation. The muscle strength of her left limb was evaluated as grade 0, whereas her right limb could move involuntarily. On the second postoperative day, the patient was able to open her eyes voluntarily, the muscle strength of her left limb remained at grade 0, and the

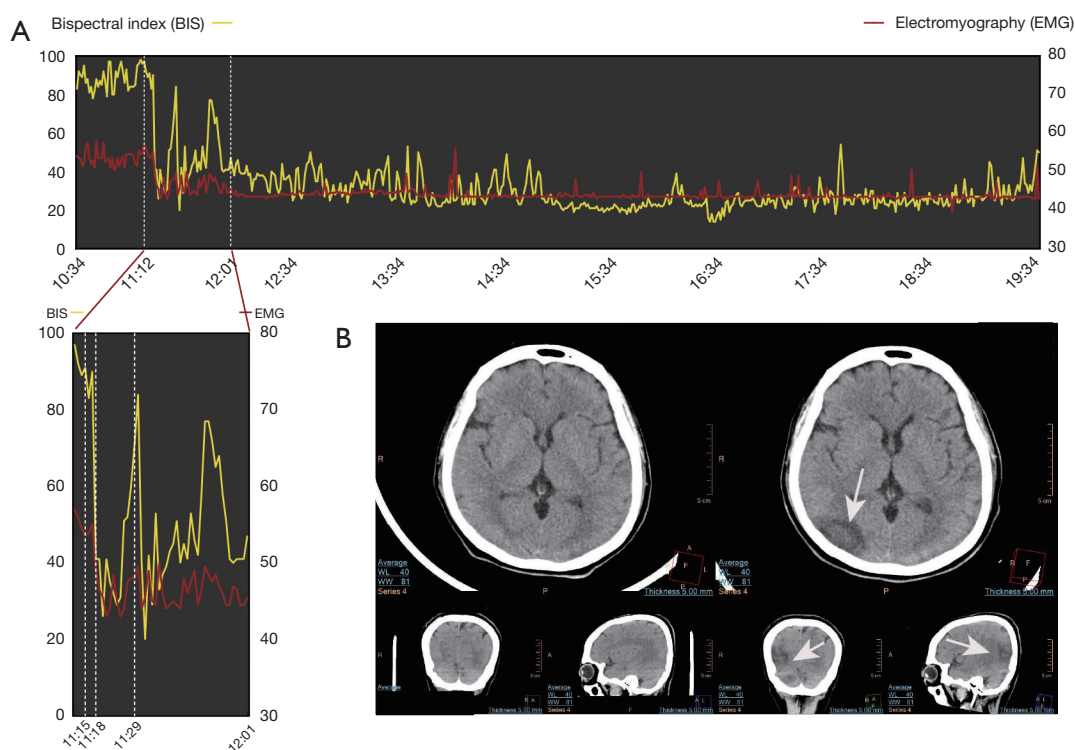


Figure 1 BIS data and the brain computed tomography scan. (A) BIS data during 11 minutes of cessation of spontaneous circulation. (B) The brain CT scan on the seventh postoperative day. White arrows, ischemic infarcts. BIS, bispectral index; EMG, electromyography; CT, computed tomography.

muscle strength of her right limb was evaluated as grade 4. On the sixth postoperative day, the muscle strength of her left lower extremity was evaluated as grade 1. On the seventh postoperative day, the muscle strength of her right limb was evaluated as grade 5. By the 21st postoperative day, the muscle strength of her left upper limb was evaluated as grade 1. This asymmetry in muscle strength was expected due to the patient's right-sided cerebral infarction. Brain computed tomography performed on the seventh postoperative day indicated the presence of multiple ischemic infarcts (*Figure 1B*, white arrow). On the 41st postoperative day, the patient was transferred to the rehabilitation department of our hospital for rehabilitation treatment.

All procedures performed in this study were in accordance with the ethical standards of the institutional and/or national research committee(s) and with the Declaration of Helsinki (as revised in 2013). Written informed consent was obtained from the patient for publication of this case report and accompanying images. A copy of the written consent is available for review by the editorial office of this journal.

Discussion

Herein, we present the BIS data of a patient who underwent CA after anesthesia and who experienced right-sided cerebral infarction.

Postresuscitation BIS monitoring values have been correlated with neurologic outcomes in patients undergoing therapeutic hypothermia treatment within prior research. Moreover, a zero BIS at any timepoint has been uniformly correlated with poor neurological outcomes; however, a nonzero BIS is insufficient as a sole predictor of good neurologic survival (3). In our case, 11 minutes of BIS monitoring data showed only nonzero BIS readings throughout the entire CA episode and the duration of chest and cardiac compressions. With chest and cardiac compressions, the patient's lowest mean artery pressure was noted to be 40 mmHg, and her lowest BIS reading was 28. By the second postoperative day, the patient was found to be responsive (e.g., could open her eyes in response to vocalization by the attending physician) We also noted that her BIS readings increased to approximately 80 when the

CPB was successfully established. However, we are unsure about how this increase in the BIS might have correlated with the patient's awareness or with her postoperative course.

As the BIS reflects consciousness disturbance in patients with acute cerebral infarction (ACI), evaluating the potential application value of the BIS requires elucidating the effects of a decreasing BIS (4). The increased BIS values postresuscitation seen herein may reflect the immediately increasing blood flow support occurring due to the establishment of CPB. Conversely, within the 11 minutes of emergency CPB establishment, insufficient blood flow might have triggered the ACI. To the best of our knowledge, this is the first case report with real-time BIS monitoring data during CA although there have been reports published regarding postoperative BIS monitoring (e.g., after CA) (5,6).

In conclusion, although the effect of BIS monitoring cannot be proven through clinical trials during CA, given the inaccessibility and impracticality of such research, all serious cardiac patients should be monitored with regard to their neurological state on a case-by-case basis, and more information should be collected that will enable physicians to better predict patient outcomes.

Acknowledgments

We would like to thank Dr. Jiaqi Wang's assistant for the preparation of the image.

Funding: None.

Footnote

Conflicts of Interest: All authors have completed the ICMJE uniform disclosure form (available at <https://qims.amegroups.com/article/view/10.21037/qims-22-498/coif>). The authors have no conflicts of interest to declare.

Ethical Statement: The authors are accountable for all aspects of the work in ensuring that questions related to the accuracy or integrity of any part of the work are appropriately investigated and resolved. All procedures performed in this study were in accordance with the ethical standards of the institutional and/or national research committee(s) and with the Declaration of Helsinki (as revised in 2013). Written informed consent was obtained from the patient for publication of this case report and accompanying images. A copy of the written consent is available for review by the editorial office of this journal.

Open Access Statement: This is an Open Access article distributed in accordance with the Creative Commons Attribution-NonCommercial-NoDerivs 4.0 International License (CC BY-NC-ND 4.0), which permits the non-commercial replication and distribution of the article with the strict proviso that no changes or edits are made and the original work is properly cited (including links to both the formal publication through the relevant DOI and the license). See: <https://creativecommons.org/licenses/by-nc-nd/4.0/>.

References

1. Chang CY, Chen CS, Chien YJ, Lin PC, Wu MY. The Effects of Early Bispectral Index to Predict Poor Neurological Function in Cardiac Arrest Patients: A Systematic Review and Meta-Analysis. *Diagnostics (Basel)* 2020;10:271.
2. Aibiki M, Kikuchi S, Umakoshi K, Ohtsubo S, Ohshita M, Matsumoto H, Nishiyama T. Good neurological recovery of a post-cardiac arrest patient with very low bispectral index values and high suppression ratios after resumption of spontaneous circulation. *Resuscitation* 2012;83:e87-8.
3. Leary M, Fried DA, Gaieski DF, Merchant RM, Fuchs BD, Kolansky DM, Edelson DP, Abella BS. Neurologic prognostication and bispectral index monitoring after resuscitation from cardiac arrest. *Resuscitation* 2010;81:1133-7.
4. Qin W, Wang S, Yang L, Yuan J, Niu S, Hu W. Correlation between Bispectral Index and Prognosis of Patients with Acute Cerebral Infarction. *Curr Neurovasc Res* 2021;18:389-94.
5. Eertmans W, Genbrugge C, Vander Laenen M, Boer W, Mesotten D, Dens J, Jans F, De Deyne C. The prognostic value of bispectral index and suppression ratio monitoring after out-of-hospital cardiac arrest: a prospective observational study. *Ann Intensive Care* 2018;8:34.
6. Haesen J, Eertmans W, Genbrugge C, Meex I, Demeestere J, Vander Laenen M, Boer W, Mesotten D, Dens J, Jans F, Ernon L, De Deyne C. The validation of simplified EEG derived from the bispectral index monitor in post-cardiac arrest patients. *Resuscitation* 2018;126:179-84.

Cite this article as: Bian H, Yan X, Sun X, Tan W. Eleven minutes of bispectral index data during the cessation of spontaneous circulation: a case description. *Quant Imaging Med Surg* 2023;13(1):550-552. doi: 10.21037/qims-22-498