

# Disseminated *Nocardia beijingensis* Masquerading as Pulmonary Tuberculosis in a Patient With Human Immunodeficiency Virus/Acquired Immune Deficiency Syndrome

Jovanna Bertrán-López,<sup>1</sup> Andrew Abbott,<sup>2</sup> Lennox K. Archibald,<sup>3</sup> Lauryn Benninger,<sup>4</sup> Jorge Lascano,<sup>5</sup> and Gautam Kalyatanda<sup>6</sup>

<sup>1</sup>Division of Infectious Diseases and Global Health, University of Florida College of Medicine, Gainesville, Florida, USA, <sup>2</sup>Division of Infectious Diseases and Global Health, University of Florida College of Medicine, Gainesville, Florida, USA, <sup>3</sup>Malcolm Randall Veterans Health Administration Medical Centre, Gainesville, Florida, USA, <sup>4</sup>Division of Pulmonary, Critical Care and Sleep Medicine, University of Florida College of Medicine, Gainesville, Florida, USA, <sup>5</sup>Division of Pulmonary, Critical Care and Sleep Medicine, University of Florida College of Medicine, Gainesville, Florida, USA, <sup>6</sup>Division of Infectious Diseases and Global Health, University of Florida College of Medicine, Gainesville, Florida, USA

Case of disseminated *Nocardia beijingensis*, initially diagnosed and treated by health department as tuberculosis, presented with worsening symptoms and new lesions. Adjustment to antinocardial treatment resulted in significant clinical and radiographic improvement. Maintain a high index of suspicion for *Nocardia* in patients diagnosed with tuberculosis with worsening lesions despite therapy.

**Keywords.** disseminated *Nocardia*; HIV/AIDS; *Nocardia beijingensis*; tuberculosis.

*Nocardiae* are Gram-positive, branching, filamentous, aerobic and weakly acid-fast bacteria that are ubiquitous in soil and aqueous environments. Nocardiosis usually manifests in 2 major forms: cutaneous and pulmonary. The cutaneous form occurs via direct inoculation of the microorganism into the skin. The pulmonary form of the disease usually results from inhalation of aerosolized bacteria resulting in establishment of a pulmonary focus leading to an acute bronchopneumonia. Pulmonary nocardiosis is more often seen in immunocompromised persons, such as those with disorders of cell-mediated immunity, on immunosuppressive therapy or persons with conditions that otherwise compromise the immune system. The brain is one of the most common secondary sites of infection.

Received 28 February 2020; editorial decision 12 May 2020; accepted 15 May 2020.

Correspondence: Jovanna Bertrán-López, MD, MPH, 1120 NW 14th Street, Suite 863, Miami FL 33136 (jovanna.bertran@gmail.com).

Open Forum Infectious Diseases®

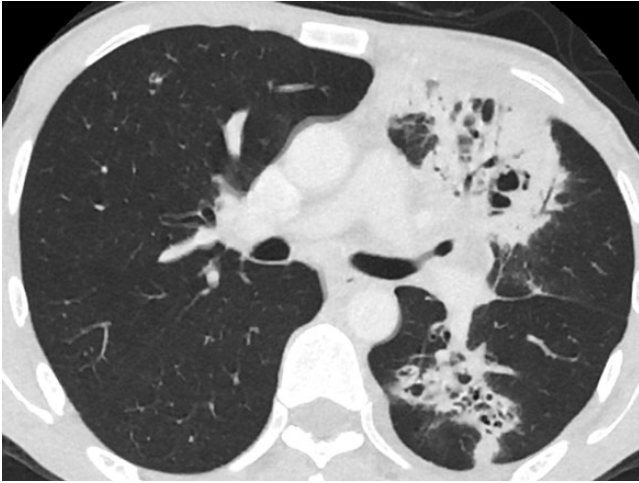
© The Author(s) 2020. Published by Oxford University Press on behalf of Infectious Diseases Society of America. This is an Open Access article distributed under the terms of the Creative Commons Attribution-NonCommercial-NoDerivs licence (<http://creativecommons.org/licenses/by-nc-nd/4.0/>), which permits non-commercial reproduction and distribution of the work, in any medium, provided the original work is not altered or transformed in any way, and that the work is properly cited. For commercial re-use, please contact journals.permissions@oup.com DOI: 10.1093/ofid/ofaa186

*Nocardia* infections are suppurative with destruction of healthy tissues and production of local or multifocal abscesses [1, 2]. In the United States, there are approximately 500–1000 new cases of nocardiosis yearly; 60% of these cases are associated with pre-existing compromised immune systems [1, 3]. Therapy differs depending on the clinical syndrome and species [1]. In this study, we present a case of *Nocardia beijingensis* in a patient who was initially diagnosed and treated for tuberculosis (TB) but later found to have disseminated nocardiosis.

## CASE REPORT

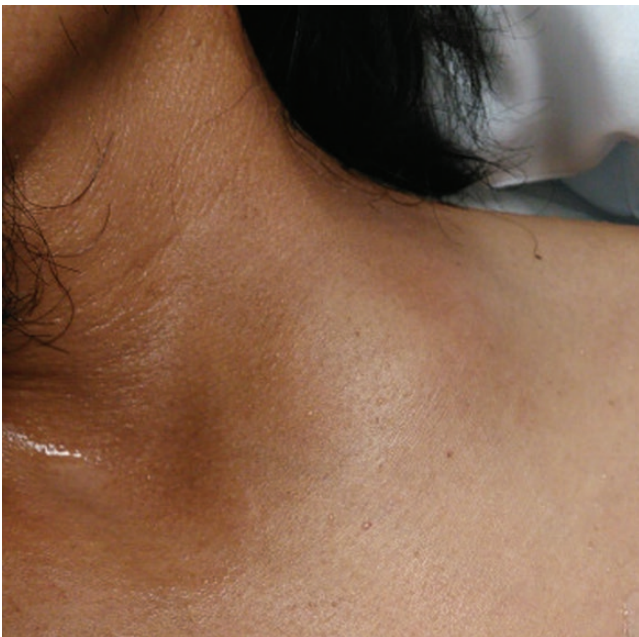A 45-year-old pine straw baler, originally from Mexico and with no known medical history, presented to his primary care physician with hiccups that had progressed to hemoptysis during the previous 2 months. Additional symptoms included subjective fevers, night sweats, and a 40-pound weight loss. He was referred to a pulmonology clinic after a chest radiograph revealed a spiculated left hilar soft tissue mass. A computed tomography (CT) scan of the thorax showed pulmonary cavitory lesions with mediastinal and hilar lymphadenopathy (Figure 1). Because the patient's symptoms and imaging findings were suggestive of pulmonary TB, he was referred to the Health Department where he was commenced on first-line, anti-tuberculous therapy with isoniazid, rifampin, pyrazinamide, and ethambutol. A human immunodeficiency virus (HIV) test was positive; *Mycobacterium tuberculosis* (MTB) nucleic acid amplification test (NAA) was negative for TB. Two weeks after starting anti-tuberculous therapy, the patient presented to the emergency department with complaints of masses in the left supraclavicular region and the scalp. On physical examination, he had tachycardia, mild confusion, and cachectic physique. There were fluctuant masses without surrounding erythema in the occipital and parietal scalp and the supraclavicular region (Figures 2 and 3). Baseline laboratory test results revealed a normochromic, normocytic anemia with hemoglobin of 8.1 g/dL, CD4 count of 49 cells/μL, and an HIV viral load of 100 000 copies/mL (Supplementary Table 1).

Computed tomography imaging of the head and neck showed multiple soft tissue lesions about the calvarium with adjacent osseous destruction and intracranial extension with an epidural component and areas of vasogenic edema with associated ring-enhancing features in the right temporal lobe that were concerning for cerebritis and abscess formation (Figure 4). There was also a large necrotic mass in the left supraclavicular area. The left supraclavicular and scalp abscess were aspirated, and specimens were sent for bacterial and acid-fast bacilli (AFB) culture. The differential diagnosis at that juncture included nocardiosis, MTB, immune reconstitution inflammatory syndrome (IRIS)

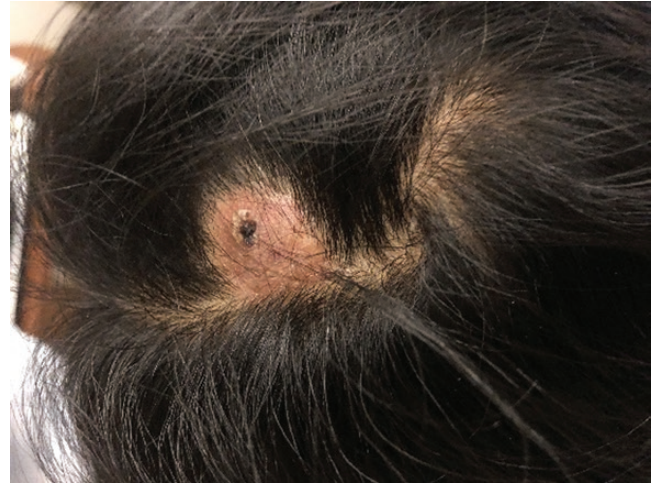

**Figure 1.** Initial computed tomography thorax showing cavitary pulmonary lesions.

from anti-tuberculous therapy, and disseminated fungal infection. Microscopy revealed branching, beaded Gram-positive rods (Figure 5). A lumbar puncture was performed, and analysis of the cerebrospinal fluid was unremarkable. Repeat MTB NAA was negative. Other tests for *Blastomyces* antibody, *Aspergillus* galactomannan, cryptococcal antigen, and antibody for *Toxoplasma* immunoglobulin (Ig)G and IgM were all negative. Cerebrospinal fluid analyses for AFB and fungal and routine bacterial cultures, cryptococcal antigen, and *Toxoplasma* polymerase chain reaction were all negative (Supplementary Table 2).

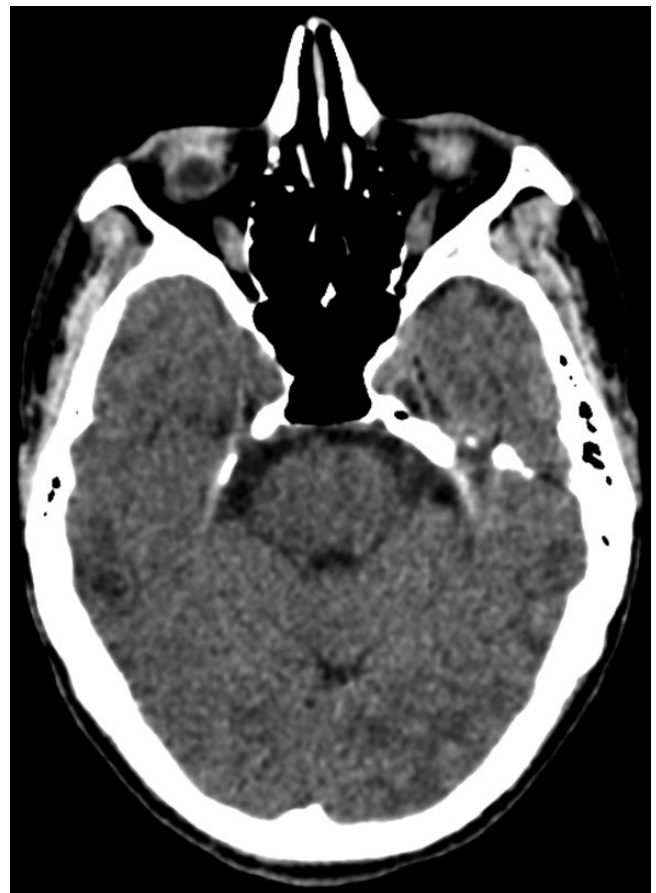

**Figure 2.** Left supraclavicular mass on presentation.

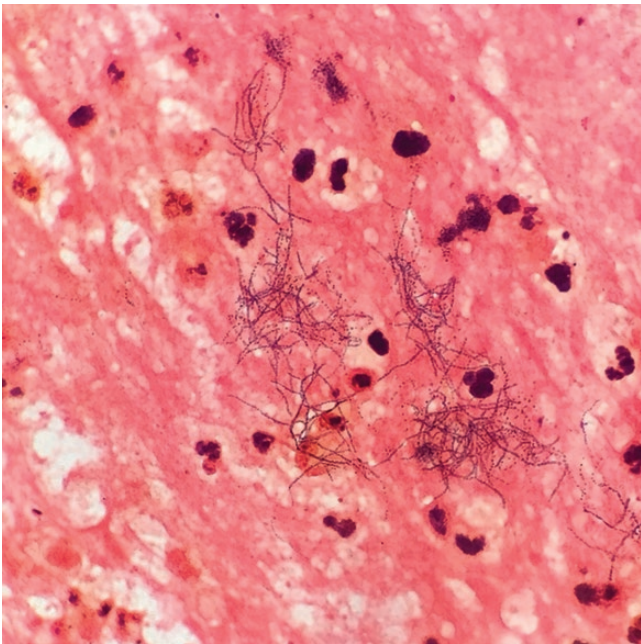


**Figure 3.** Parietal scalp lesion on presentation.

*Nocardia* sp was confirmed on culture so treatment for TB was therefore discontinued and replaced with trimethoprim-sulfamethoxazole (TMP/SMX), imipenem, and amikacin while awaiting final speciation and susceptibility test results.



**Figure 4.** Initial computed tomography of the head revealing a lesion in the right temporal lobe.



**Figure 5.** Gram stain of left supraclavicular mass.

After 2 weeks of treatment, antiretroviral therapy (ART) with bictegravir/emtricitabine/tenofovir alafenamide was started. Hsp65 deoxyribonucleic acid sequencing by the Florida Health Department identified the *Nocardia* isolate as *N. Beijingensis* that was susceptible to amikacin, azithromycin, ceftriaxone, ciprofloxacin, imipenem, linezolid, minocycline, and TMP/SMX, but resistant to amoxicillin-clavulanate.

Three weeks after discharge, the patient presented to another hospital acutely with seizures, which were thought to be secondary to the imipenem. His antibiotic regimen was therefore changed—imipenem was discontinued and ceftriaxone was started. A repeat CT scan of the head demonstrated increased ring enhancement and edema around multiple parenchymal lesions. He also had bilateral supraclavicular swelling. Due to the concern of nonadherence to prescribed antibiotics, the patient was re-admitted to hospital and the new antibiotic regimen was initiated. Intravenous antibiotics were continued for approximately 8 weeks, during which time he showed both radiological and clinical improvement (Supplementary Figures 1–4). After completion of IV therapy, he was transitioned to oral minocycline and TMP/SMX.

## DISCUSSION

*Nocardia Beijingensis* was first isolated in 2001 from the soil in Beijing, the capital of the People's Republic of China [4]. Although initially described as a human pathogen in Asia in 2004, subsequent case reports have depicted disease in humans in Australia, Europe, United States, and Latin America [5]. Few cases of infection caused by this species of *Nocardia* have been

reported in the Western Hemisphere; the first case report was published by Crozier et al [6] in 2014 in an immunocompetent host presenting with a hilar mass.

*Nocardia* species are well recognized causes of infections in both immunocompromised and immunocompetent hosts. Disseminated nocardiosis, as in our patient, most frequently begins in the respiratory tract via inhalation of spores that can be found in the soil and organic matter [7]. Secondary sites of infection include the brain, bone, skin, lung, eyes, and lymphatics; multiorgan involvement can occur [1]. Our patient's initial pulmonary findings followed by involvement of the central nervous system (CNS), calvarium, scalp, and the supraclavicular region underscore this pattern of disease progression. Based on his history, we believe that our patient acquired the original infection through occupational exposure while gathering pine straw from the ground here in the United States.

Uncontrolled HIV and other immunosuppressed states can contribute to disseminated *Nocardia* disease. Disseminated nocardiosis is more common in immunosuppressed patients, as was described in a retrospective study of *Nocardia* cases at a large teaching hospital in Michigan [8]. Overall, the incidence of nocardiosis among patients with acquired immune deficiency syndrome is relatively low (0.1% to 0.4%) compared with other opportunistic diseases [9]. However, this is approximately 140 times the incidence of the general population, and a review of all cases of nocardiosis from 1999 to 2004 from a tertiary hospital in Miami reported that 76% were also infected with HIV [9, 10]. The reasons for the relatively low overall incidence of the disease compared with other opportunistic infections in populations with HIV infection is not well understood and is likely multifactorial [7]. The degree of dysfunction of cell-mediated immunity, cellular immune dysfunction that is not present in all patients with HIV, a noncellular immune response active against *Nocardia*, underdiagnosis or underreporting, and *Pneumocystis jiroveci* pneumonia prophylaxis with TMP/SMX have been postulated as reasons behind the low incidence [7, 11].

The clinical presentation of pulmonary nocardiosis can be mistaken for pulmonary TB [12]. In 1888, Edmond Nocard, a 19th century veterinarian and biologist, described the disease as a pseudo-TB; recent studies have shown no significant difference in the presenting symptoms between pulmonary TB and pulmonary nocardiosis [13–15]. Radiographic changes include consolidation, nodules (often cavitory), masses, and interstitial involvement; upper lobe involvement—a classic finding of pulmonary TB—is commonly seen in pulmonary nocardiosis and may lead to incorrect inferences [3]. Moreover, the presence of either pulmonary TB or pulmonary nocardiosis does not necessarily rule out the other, especially in patients with significant immunosuppression, such as those with HIV infection. Thus, concomitant *Nocardia* sp and MTB pulmonary infections can occur [16]. In our patient,

coinfection was excluded as multiple cultures for mycobacteria and MTB NAA testing remained negative.

Due to the mentioned similarity with TB, the diagnosis of pulmonary nocardiosis may be delayed, which can increase the risk of poor outcomes and higher morbidity and mortality rates [9, 11, 17]. Compounding the problem is the fact that pulmonary nocardiosis masquerades as TB more frequently than expected. Studies in China, Ghana, and Tanzania have reported 4.5% to 18% of patients presenting with pulmonary findings concerning for TB, who in fact have pulmonary infection caused by *Nocardia* spp [13, 15, 18, 19]. When evaluating the etiology of pulmonary lesions, the African studies have shown a pulmonary TB-to-nocardiosis ratio among patients with HIV ranging anywhere from 9:1 to 90:1 depending on the country and methodology [20]. However, these studies were conducted in countries with a higher incidence of TB than the United States. Based on our literature review in PubMed with terms *Nocardia* and TB, there have been no studies in the United States that have ascertained the prevalence of *Nocardia* in patients with suspected pulmonary TB. In addition, there have been relatively few US case reports in the HIV era of patients with *Nocardia* being mistakenly diagnosed and treated for TB. Furthermore, approximately 1%–2% of all brain lesions could be due to *Nocardia* [21]. For all these reasons, we believe that, for patients being evaluated for TB, there should be a high index of suspicion for *Nocardia*, especially if there are concomitant pulmonary and brain lesions or worsening symptoms without a confirmed diagnosis of TB.

Treatment of disseminated nocardiosis is based mainly on retrospective reviews and expert opinion with recommendations for a 3-drug regimen in severe disease with a total duration of at least 12 months to prevent relapse [2, 22]. Trimethoprim-sulfamethoxazole is considered the backbone of therapeutic regimens for *Nocardia* spp infection because most species are susceptible. Notable exceptions include *Nocardia otitidiscaviarum*, which is commonly resistant, and *Nocardia nova* and *Nocardia farcinica*, which are occasionally resistant [22]. The selection of antibiotics for empiric combination therapy should be based on the species of *Nocardia* if known. Susceptibilities should be requested, and therapy should be adjusted based on the organism's profile. Trimethoprim-sulfamethoxazole, linezolid, and carbapenems have good CNS penetration and are used in disseminated disease and brain lesions [2].

Patient's clinical course was complicated by seizure and a CT head with an increase in ring enhancement and edema of the brain lesions while on empiric therapy with TMP/SMX, imipenem, and amikacin. Seizure is a well recognized, albeit uncommon, adverse effect of imipenem [23]. The patient was switched to ceftriaxone based on susceptibilities before repeat CT scanning of the head was performed. However, the increasing ring enhancement and edema of the brain lesions

later seen on repeat imaging was concerning for IRIS or nonadherence with therapy. Immune reconstitution inflammatory syndrome is rarely reported with *Nocardia* treatment, but with his recent initiation of ART in the preceding weeks, this was high on the differential [24]. By the time the patient was re-admitted and a second CT scan was performed, the lesions had begun to improve, and his seizures had resolved; accordingly, steroid therapy was not started. The patient completed 8 weeks of intravenous therapy with ceftriaxone, amikacin, and TMP/SMX with a good clinical response and was transitioned to oral minocycline and TMP/SMX. Outpatient follow up 5 months later showed radiologic improvement and complete clinical resolution of symptoms and lesions (Supplement Figures 1–4). The Infectious Diseases Service at our facility continued to follow the patient during and after he completed 1 year of antimicrobial therapy. Since completing therapy, he has not had any clinical signs of disease recurrence. At the present time, his only medications are antiretroviral therapy (bictegravir/emtricitabine/tenofovir alafenamide) and prophylactic TMP/SMX, with an undetectable HIV viral load and most recent CD4 count of 130.

## CONCLUSIONS

Our patient's case highlights several crucial learning points regarding *Nocardia* including acknowledging the lack of available data within the United States in regard to the incidence and prevalence of *Nocardia*, particularly *N. beijingensis*, in people with HIV having suspected pulmonary TB. A comprehensive list of differential diagnoses and meticulous diagnostic evaluation of these patients is of paramount importance to prevent the morbidity and mortality associated with a delayed or missed diagnosis. Prompt diagnosis and treatment will allow these patients to have a favorable clinical outcome.

## Supplementary Data

Supplementary materials are available at *Open Forum Infectious Diseases* online. Consisting of data provided by the authors to benefit the reader, the posted materials are not copyedited and are the sole responsibility of the authors, so questions or comments should be addressed to the corresponding author.

## Acknowledgments

We thank the patient and his family for permitting the publication of his case and their cooperation with care during the past months.

**Potential conflicts of interest.** All authors: No reported conflicts of interest. All authors have submitted the ICMJE Form for Disclosure of Potential Conflicts of Interest.

## References

1. Beaman BL, Beaman L. *Nocardia* species: host-parasite relationships. *Clin Microbiol Rev* 1994; 7:213–64.
2. Anagnostou T, Arvanitis M, Kourkoumpetis TK, et al. Nocardiosis of the central nervous system: experience from a general hospital and review of 84 cases from the literature. *Medicine (Baltimore)* 2014; 93:19–32.
3. Yaşar Z, Acat M, Onaran H, et al. An unusual case of pulmonary nocardiosis in immunocompetent patient. *Case Rep Pulmonol* 2014; 2014:963482.

4. Wang L, Zhang Y, Lu Z, et al. *Nocardia beijingensis* sp. nov., a novel isolate from soil. *Int J Syst Evol Microbiol* **2001**; 51:1783–8.
5. Kageyama A, Poonwan N, Yazawa K, et al. *Nocardia beijingensis*, is a pathogenic bacterium to humans: the first infectious cases in Thailand and Japan. *Mycopathologia* **2004**; 157:155–61.
6. Crozier JA, Andhavarapu S, Brumble LM, Sher T. First report of *Nocardia beijingensis* infection in an immunocompetent host in the United States. *J Clin Microbiol* **2014**; 52:2730–2.
7. McNeil MM, Brown JM. The medically important aerobic actinomycetes: epidemiology and microbiology. *Clin Microbiol Rev* **1994**; 7:357–417.
8. Steinbrink J, Leavens J, Kauffman CA, Miceli MH. Manifestations and outcomes of nocardia infections: comparison of immunocompromised and nonimmunocompromised adult patients. *Medicine (Baltimore)* **2018**; 97:e12436.
9. Ambrosioni J, Lew D, Garbino J. Nocardiosis: updated clinical review and experience at a tertiary center. *Infection* **2010**; 38:89–97.
10. Castro JG, Espinoza L. *Nocardia* species infections in a large county hospital in Miami: 6 years experience. *J Infect* **2007**; 54:358–61.
11. Pintado V, Gómez-Mampaso E, Cobo J, et al. Nocardial infection in patients infected with the human immunodeficiency virus. *Clin Microbiol Infect* **2003**; 9:716–20.
12. Khadka P, Basnet RB, Rijal BP, Sherchand JB. Pulmonary nocardiosis masquerading renaissance of tuberculosis in an immunocompetent host: a case report from Nepal. *BMC Res Notes* **2018**; 11:488.
13. Dong G, Chu P, Guo J, et al. Nontuberculous mycobacterial and *Nocardia* infections mimicking pulmonary tuberculosis: a retrospective study of a general hospital patient population in China. *J Med Microbiol* **2019**. doi:10.1099/jmm.0.000961
14. Shariff M, Gunasekaran J. Pulmonary nocardiosis: review of cases and an update. *Can Respir J* **2016**; 2016:7494202.
15. Hoza AS, Mfinanga SGS, Moser I, König B. Isolation, biochemical and molecular identification of *Nocardia* species among TB suspects in northeastern, Tanzania; a forgotten or neglected threat? *BMC Infect Dis* **2017**; 17:407.
16. Ekrami A, Khosravi AD, Samarbaf Zadeh AR, Hashemzadeh M. *Nocardia* co-infection in patients with pulmonary tuberculosis. *Jundishapur J Microbiol* **2014**; 7:e12495.
17. Uttamchandani RB, Daikos GL, Reyes RR, et al. Nocardiosis in 30 patients with advanced human immunodeficiency virus infection: clinical features and outcome. *Clin Infect Dis* **1994**; 18:348–53.
18. Alnaum HM, Elhassan MM, Mustafa FY, Hamid ME. Prevalence of *Nocardia* species among HIV-positive patients with suspected tuberculosis. *Trop Doct* **2011**; 41:224–6.
19. Sakyi SA, Danquah KO, Ephraim RD, et al. Evaluating the contribution of *Nocardia* spp. and *Mycobacterium tuberculosis* to pulmonary infections among HIV and non-HIV patients at the Komfo Anokye Teaching Hospital, Ghana. *Can J Infect Dis Med Microbiol* **2018**; 2018:2910198.
20. Jones N, Khoosal M, Louw M, Karstaedt A. Nocardial infection as a complication of HIV in South Africa. *J Infect* **2000**; 41:232–9.
21. Sherbuk J, Saly D, Barakat L, Ogbuagu O. Unusual presentation of disseminated *Nocardia abscessus* infection in a patient with AIDS. *BMJ Case Rep* **2016**; 2016. doi:10.1136/bcr-2016-215649
22. Wilson JW. Nocardiosis: updates and clinical overview. *Mayo Clin Proc* **2012**; 87:403–7.
23. Cannon JP, Lee TA, Clark NM, et al. The risk of seizures among the carbapenems: a meta-analysis. *J Antimicrob Chemother* **2014**; 69:2043–55.
24. Soman R, Koparkar V, Almeida A, et al. Paradoxical response in cerebral nocardiosis in a renal transplant recipient. *J Assoc Physicians India* **2018**; 66:91–2.