

CASE REPORT

Open Access



# Chronic hepatitis B infection presenting with chronic lymphocytic inflammation with pontine perivascular enhancement responsive to steroids (CLIPPERS): a case report

Ching-Fu Weng<sup>1†</sup>, Ding-Cheng Chan<sup>1,2†</sup>, Ya-Fang Chen<sup>3</sup>, Fei-Chih Liu<sup>4</sup> and Horng-Huei Liou<sup>4\*</sup>

## Abstract

**Introduction:** Chronic lymphocytic inflammation with pontine perivascular enhancement responsive to steroids is a brainstem disorder characterized by perivascular pathologic reaction with lymphocyte infiltration and leading to diplopia, facial palsy, dysarthria, and gait ataxia. It was thought to be an autoimmune disorder without distinct pathogenesis. Chronic hepatitis B virus infection has been proposed in correlation with autoimmune diseases, including central nervous system demyelinating disease. Patients with chronic hepatitis B infection may develop the syndrome of chronic lymphocytic inflammation with pontine perivascular enhancement responsive to steroids.

**Case presentation:** A 34-year-old Taiwanese man who had been a hepatitis B virus carrier for a decade presented to our emergency room. He had influenza symptoms and progressive symptoms of left hemifacial numbness, double vision, and an unsteady gait of 2 days' duration. Chronic lymphocytic inflammation with pontine perivascular enhancement responsive to steroids was diagnosed, with increased hepatitis B viral load at the same time. He had no past history of similar neurologic deficits, and his liver function tests had been within normal limits before this episode. After corticosteroid and entecavir treatments, his neurological deficits and neuroimaging anomalies improved and his serum hepatitis B virus DNA viral load normalized.

**Conclusions:** Hepatitis B virus infection may induce central nervous system autoimmune reactions, including chronic lymphocytic inflammation with pontine perivascular enhancement responsive to steroids. In such cases, concomitant administration of corticosteroids and antiviral agent was helpful. We suggest further investigations in patients with regulatory T cell dysfunction, which may assist in clarifying a loss of immune tolerance in patients with such disorders.

**Keywords:** Autoimmunity, CLIPPERS, Demyelinating disease, Encephalomyelitis, Hepatitis B, Regulatory T cell

## Introduction

Chronic lymphocytic inflammation with pontine perivascular enhancement responsive to steroids (CLIPPERS) is a disorder established since 2010 [1]. Its clinical features include diplopia, facial palsy, dysarthria, and gait ataxia, which result from a brainstem perivascular pathologic reaction with lymphocytic infiltration. Brain magnetic

resonance imaging (MRI) reveals punctate and curvilinear gadolinium enhancement in the pons, sometimes with midbrain, cerebellum, spinal cord, or basal ganglia involvement. CLIPPERS responds well to corticosteroid treatment [1]. Even with good improvement in clinical symptoms and resolution observed by neuroimaging after treatment, recurrence or relapse may develop after discontinuing or tapering corticosteroid therapy. The distinct pathophysiology of CLIPPERS is still unknown. Several studies suggested CLIPPERS as an autoimmune disorder, but the hypothesis is still not well established,

\* Correspondence: hhl@ntu.edu.tw

†Equal contributors

<sup>4</sup>Department of Neurology, National Taiwan University Hospital, No.1, Changde Street, Zhongzheng District, Taipei City 10048, Taiwan  
Full list of author information is available at the end of the article

owing to a paucity of data [1, 2]. In this report, we describe a case of a patient with a clinical diagnosis of CLIPPERS. He was a chronic hepatitis B virus (HBV) carrier with elevated HBV DNA viral load. His presentation raised the possibility of HBV-associated immunity and regulatory T cell (Treg) dysfunction as the cause of the pathogenesis of CLIPPERS. To our knowledge, this is the first case of CLIPPERS associated with the chronic HBV infection reported to date.

### Case presentation

A 34-year-old Taiwanese man was a known HBV carrier for about 10 years. Headache, lightheadedness, neck stiffness, and nausea and vomiting had developed 3 weeks before admission. One week after admission, left hemifacial numbness, double vision, easily choking when swallowing, frequent hiccup, and unsteady gait developed and progressed.

The patient had no cough, rhinorrhea, abdominal pain, diarrhea, dysuria, urinary frequency, convulsive movement, consciousness disturbance, or body weight loss. He sought Chinese traditional medical therapy and acupuncture, but his neurologic symptoms persisted, especially the easily choking when swallowing. Therefore, he presented to our emergency room.

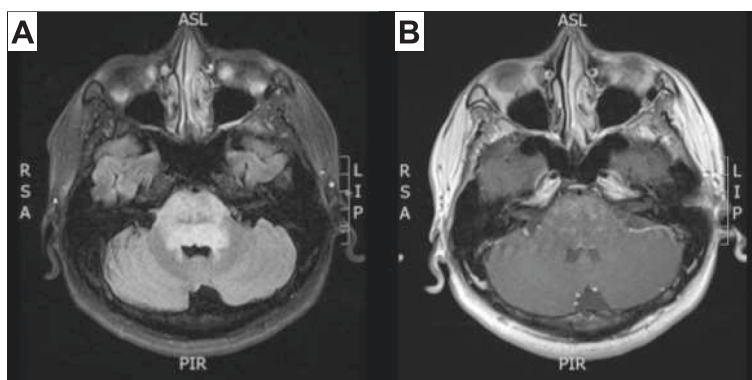
Upon admission, the patient's initial blood pressure was 126/76 mmHg and his temperature was 37.3 °C. His pulse rate was 68 beats/minute. A neurological examination revealed impaired lateral gaze of both eyes and mild deviation of the tongue to the left side. Cerebellar dysarthria, wide-based gait ataxia, and bilateral upper limb dysmetria were detected. The patient's brain MRI showed swelling of the pons with extensive hyperintensity on T2-weighted images that extended to the midbrain and medulla. Punctate and curvilinear enhancement was observed after contrast dye injection (Fig. 1). A cerebrospinal fluid (CSF) study disclosed pleocytosis (106 cells/ $\mu$ l) with lymphocyte

predominance (lymphocytes/neutrophils 97%/9%). Oligoclonal bands were detected (total protein 79.9 mg/dl, normal 15–45 mg/dl; immunoglobulin G (IgG) 9.72 mg/dl, normal <3.4 mg/dl). Test results for herpes simplex virus DNA and cryptococcal antigen in the CSF were both negative. Serial autoimmune serum examination results, including antinuclear antibodies, anti-DNA, cytoplasmic antineutrophil cytoplasmic antibodies, perinuclear antineutrophil cytoplasmic antibodies, rheumatoid factor, complement C3 and C4 nephritic factors, IgM, IgG, were all within normal limits, except for a slightly elevated IgA level (409 mg/dl, normal 70–400 mg/dl). The patient's anti-hepatitis B e (anti-HBe) antibody test was positive. His total bilirubin was 0.56 mg/dl, and his aspartate aminotransferase (AST) concentration was 24 U/L. An elevated HBV DNA viral load (2250 IU/ml, normal <20 IU/mL) was detected.

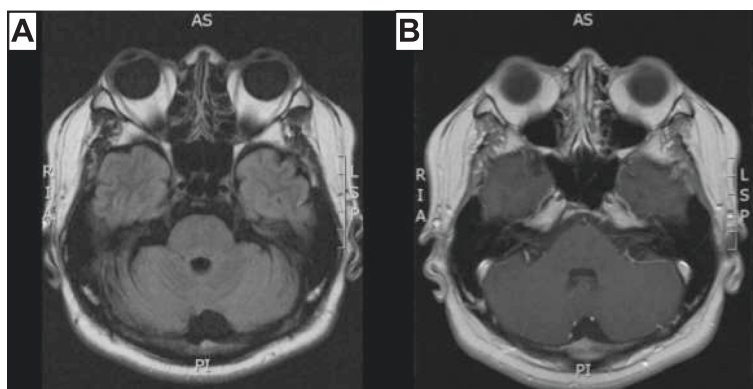
Corticosteroid therapy was considered based on a tentative diagnosis of CLIPPERS. Entecavir 1 mg/day was given before a high-dose corticosteroid (1 g/day) after consultation with a gastroenterologist. A maintenance dose of 0.5 mg/day was started subsequently, followed by prednisolone 70 mg/day. The patient's bilateral lateral gaze limitation, unsteady gait, dysarthria, and dysphagia improved promptly. The patient was discharged 3 weeks later with a good clinical response, and treatment was continued with gradual tapering of prednisolone to 30 mg/day over the course of 6 months. Six months later, nearly complete resolution of the brainstem lesion was seen on MRI scans (Fig. 2). Normalization of the patient's serum HBV DNA viral load (<20 IU/mL) and disappearance of his neurologic deficit also were noted.

### Discussion

Our patient had several clinical and typical radiologic findings that met the diagnostic criteria for CLIPPERS, although the tissue proof was not acquisitive. The diagnosis of CLIPPERS is generally based on clinical,



**Fig. 1** **a** Fluid-attenuated inversion recovery image shows ill-defined hyperintensity involving the whole pons, which was associated with swelling of the pons. **b** Postcontrast T1-weighted image shows multiple punctate and curvilinear enhancing lesions in the pons bilaterally



**Fig. 2** Images obtained 6 months after corticosteroid treatment. **a** Fluid-attenuated inversion recovery image. **b** Postcontrast T1-weighted image showing nearly complete resolution of the patient's pontine lesions

radiological, and pathological findings and glucocorticoid response. Brain biopsy in critical areas of the brainstem has potential complications. A clinical diagnosis based on typical image appearance is crucial [3], but clinicians should still be aware of a constellation of various presentations of CLIPPERS. Cautious exclusion of similar central nervous system (CNS) inflammation disorders is mandatory.

The differential diagnosis should include Bickerstaff's brainstem encephalitis, CNS vasculitis (primary angiitis of the CNS), neuromyelitis optica, Sjögren's syndrome with CNS involvement, CNS lymphoma, and glioma (especially when atypical clinical or MRI findings are encountered), or when resistance to corticosteroid treatment occurs [4]. Once the diagnosis is made, the treatment should be started immediately to achieve an optimal outcome, even if a biopsy is not performed for pathologic proof.

Investigators proposed that this disorder is an autoimmune process involving perivascular inflammatory reaction, but the exact mechanism remains unknown. Kastrup and colleagues described two cases of CLIPPERS with elevated IgE level, and eosinophilic granulocytes were absent in both cases [2]. IgE-related neuroinflammation was considered [5]. Influenza vaccination-induced CLIPPERS has been reported as well [6]. Nevertheless, such hypersensitivity reactions may not fully explain the pathogenesis of CLIPPERS. Furthermore, there is still no specific antineural surface antigen antibody that can be recognized [7].

Our patient had been diagnosed as a chronic HBV carrier for more than 10 years. He had undergone regular abdominal ultrasonography imaging and serum liver function tests during that time. The liver echotexture and serum biomarkers were all within normal limits. Before corticosteroid administration after his admission to our hospital, elevated HBV DNA viral load (2250 IU/

ml) was detected. His serum HBe antigen was negative, his anti-HBe antibody was positive, and his AST and alanine aminotransferase levels were within normal limits. With high-dose corticosteroid use, a flare-up of his HBV infection was possible; thus, adding antiviral therapy was a reasonable choice from both therapeutic and prevention standpoints [8].

HBV infection has been proposed in correlation with autoimmune diseases, such as multiple sclerosis (MS), systemic lupus erythematosus, rheumatoid arthritis, polymyalgia rheumatica, polymyositis, and autoimmune liver disease. Several possible mechanisms have been postulated: molecular mimicry, epitope spreading and modification, viral or bacterial superantigens, release of autoantigens during inflammation, or bystander activation [9–12]. For example, investigators who used an animal model of MS experimental autoimmune encephalomyelitis showed that rabbit T cells were reactive to both injected HBV polymerase peptide and myelin basic protein at the same amino acid, resulting in autoimmune demyelinating encephalomyelitis [13]. In patients with autoimmune liver disease caused by occult HBV infection, isolated serum HBV DNA was also detected in significant proportions [14].

Xu and colleagues pointed that high serum HBV DNA viral load has a positive correlation with circulating CD4<sup>+</sup>CD25<sup>+</sup>Treg frequency in peripheral blood, suggesting that an increase in Tregs correlates with impairment in viral clearance [15], leading to persistence of HBV infection [16]. Tregs are able to maintain immunological homeostasis and suppress autoimmunity against self-antigens [17]. Impaired Treg function in peripheral blood caused by complex genetic defects or environmental factors may play a role in HBV-related, cell-mediated autoimmunity and may have contributed to the increased HBV DNA viral load in our patient.

We suggest adding anti-HBV therapy to steroid therapy and monitoring of HBV viral activity in individuals diagnosed with CLIPPERS concomitant with chronic HBV infection. Further surveys of the role of Tregs in CLIPPERS may lead to a better understanding of the pathogenesis of this disorder and help clinicians to find a new strategy in developing more effective therapy.

## Conclusions

Increasing numbers of reports have recently indicated that CLIPPERS is an emerging entity associated with an autoimmunologic process involving the CNS. To the best of our knowledge, we report the first case associated with HBV infection. In our patient, the neurologic manifestation correlated well with HBV viral load. Long-term corticosteroid use had been recommended for CLIPPERS because of the easily relapsing-remitting character of the disease. When this disorder is accompanied by chronic HBV infection, antiviral therapy is strongly recommended. Thus, we assumed that dual use of an antiviral agent and a steroid for suppression of virus-associated autoimmune reaction is beneficial for treatment. Further investigation of Tregs in CLIPPERS may help to clarify the disease process.

## Consent

Written informed consent was obtained from the patient for publication of this case report and any accompanying images. A copy of the written consent is available for review by the Editor-in-Chief of this journal.

## Abbreviations

AST: aspartate aminotransferase; CLIPPERS: chronic lymphocytic inflammation with pontine perivascular enhancement responsive to steroids; CNS: central nervous system; CSF: cerebrospinal fluid; HBe: hepatitis B e; HBV: hepatitis B virus; Ig: immunoglobulin; MRI: magnetic resonance imaging; MS: multiple sclerosis; Treg: regulatory T cell.

## Competing interests

The authors declare that they have no competing interests.

## Authors' contributions

CFW, DCC, and HHL made substantial contributions to the conception and writing of the report. YFC and FCL added comments regarding radiology and assisted in manuscript completion. All authors read and approved the final manuscript. The authors extend special thanks to Professor HHL, who provided instruction and made a major contribution to completing the report.

## Author details

<sup>1</sup>Department of Gerontology and Geriatrics, National Taiwan University Hospital, Taipei, Taiwan. <sup>2</sup>Department of Internal Medicine, National Taiwan University Hospital, Taipei, Taiwan. <sup>3</sup>Department of Medical Imaging, National Taiwan University Hospital, Taipei, Taiwan. <sup>4</sup>Department of Neurology, National Taiwan University Hospital, No.1, Changde Street, Zhongzheng District, Taipei City 10048, Taiwan.

Received: 11 May 2015 Accepted: 26 October 2015

Published online: 19 November 2015

## References

- Pittock SJ, Debruyne J, Krecke KN, Giannini C, van den Aremeele J, De Herdt V, et al. Chronic lymphocytic inflammation with pontine perivascular enhancement responsive to steroids (CLIPPERS). *Brain*. 2010;133(9):2626–34.
- Kastrup O, van de Nes J, Gasser T, Keyvani K. Three cases of CLIPPERS: a serial clinical, laboratory and MRI follow-up study. *J Neurol*. 2011;258(12):2140–6.
- Simon NG, Parratt JD, Barnett MH, Buckland ME, Gupta R, Hayes MW, et al. Expanding the clinical, radiological and neuropathological phenotype of chronic lymphocytic inflammation with pontine perivascular enhancement responsive to steroids (CLIPPERS). *J Neurol Neurosurg Psychiatry*. 2012;83(1):15–22.
- Limousin N, Praline J, Motica O, Cottier JP, Rousselot-Denis C, Mokhtari K, et al. Brain biopsy is required in steroid-resistant patients with chronic lymphocytic inflammation with pontine perivascular enhancement responsive to steroids (CLIPPERS). *J Neurooncol*. 2012;107(1):223–4.
- Tohge R, Nagao M, Yagishita A, Matsubara S. A case of chronic lymphocytic inflammation with pontine perivascular enhancement responsive to steroids (CLIPPERS) in East Asia. *Intern Med*. 2012;51(9):1115–9.
- Hillesheim PB, Parker JR, Parker Jr JC, Escott E, Berger JR. Chronic lymphocytic inflammation with pontine perivascular enhancement responsive to steroids following influenza vaccination. *Arch Pathol Lab Med*. 2012;136(6):681–5.
- Maddison P, Damian MS, Sewry C, McGorrian C, Winer JB, Odgerel Z, et al. Clinical and myopathological characteristics of desminopathy caused by a mutation in desmin tail domain. *Eur Neurol*. 2012;68(5):279–86.
- Bárcena Marugán R, García GS. DNA-guided hepatitis B treatment, viral load is essential, but not sufficient. *World J Gastroenterol*. 2009;15(4):423–30.
- Matsui M, Kakigi R, Watanabe S, Kuroda Y. Recurrent demyelinating transverse myelitis in a high titer HBs-antigen carrier. *J Neurol Sci*. 1996;139(2):235–7.
- Ichiki Y, He XS, Shimoda S, Ishibashi H, Keeffe EB, Rossaro L, et al. T cell immunity in hepatitis B and hepatitis C virus infection: implications for autoimmunity. *Autoimmun Rev*. 2005;4(2):82–95.
- Maya R, Gershwin ME, Shoenfeld Y. Hepatitis B virus (HBV) and autoimmune disease. *Clin Rev Allergy Immunol*. 2008;34(1):85–102.
- Chastain EM, Miller SD. Molecular mimicry as an inducing trigger for CNS autoimmune demyelinating disease. *Immunol Rev*. 2012;245(1):227–38.
- Fujinami RS, Oldstone MB. Amino acid homology between the encephalitogenic site of myelin basic protein and virus: mechanism for autoimmunity. *Science*. 1985;230(4729):1043–5.
- Georgiadou SP, Zachou K, Liaskos C, Gabetta S, Rigopoulou EI, Dalekos GN. Occult hepatitis B virus infection in patients with autoimmune liver diseases. *Liver Int*. 2009;29(3):434–42.
- Xu D, Fu J, Jin L, Zhang H, Zhou C, Zou Z, et al. Circulating and liver resident CD4<sup>+</sup>CD25<sup>+</sup> regulatory T cells actively influence the antiviral immune response and disease progression in patients with hepatitis B. *J Immunol*. 2006;177(1):739–47.
- Stoop JN, van der Molen RG, Baan CC, van der Laan LJ, Kuipers EJ, Kusters JG, et al. Regulatory T cells contribute to the impaired immune response in patients with chronic hepatitis B virus infection. *Hepatology*. 2005;41(4):771–8.
- Costantino CM, Baecher-Allan CM, Hafler DA. Human regulatory T cells and autoimmunity. *Eur J Immunol*. 2008;38(4):921–4.

**Submit your next manuscript to BioMed Central and take full advantage of:**

- Convenient online submission
- Thorough peer review
- No space constraints or color figure charges
- Immediate publication on acceptance
- Inclusion in PubMed, CAS, Scopus and Google Scholar
- Research which is freely available for redistribution

Submit your manuscript at  
www.biomedcentral.com/submit

