

Received: 2019.03.06
Accepted: 2019.10.17
Published: 2019.12.28

e-ISSN 1941-5923
© Am J Case Rep, 2019; 20: 1956-1960
DOI: 10.12659/AJCR.916071

Legionella Pneumonia in Late Pregnancy

Authors' Contribution:
Study Design A
Data Collection B
Statistical Analysis C
Data Interpretation D
Manuscript Preparation E
Literature Search F
Funds Collection G

E Hany K. Mosaad-Boktor
BEF Stephen A. Lee

Hospitalist Department, Arnot Ogden Medical Center (AOMC), Elmira, NY, USA





Corresponding Author: Hany K. Mosaad-Boktor, e-mail: hanyboktor@aol.com
Conflict of interest: None declared

Patient: Female, 18-year-old
Final Diagnosis: Legionella pneumonia in late pregnancy
Symptoms: Cough • shortness of breath
Medication: —
Clinical Procedure: CT scan
Specialty: Infectious Diseases

Objective: Rare co-existence of disease or pathology
Background: Legionella pneumonia can be an aggressive form of pneumonia. However, it is rare in pregnant women, particularly in the peripartum period. To the best of our knowledge this is the only case of Legionella pneumonia with endometrial sepsis. We are reporting a patient with this rare condition.
Case Report: The patient was an 18-year-old female, pregnant with her first baby, who developed symptoms of the common cold near term. The patient was seen at another major facility initially and was discharged home with a diagnosis of "cold". She was still uncomfortable and came to our facility Arnot Ogden Medical Center Elmira, NY, USA, where she had rupture of membranes and underwent C-section. She was suspected clinically of having pneumonia. Initial chest x-ray was negative, but computed tomography (CT)-scan did show bilateral pneumonia. Further workup confirmed the diagnosis of Legionella pneumonia and was treated for that as well as for endometritis. She did require Intensive Care Unit (ICU) care during her hospital stay. The patient was seen and evaluated by multiple subspecialties, including Critical Care, Infectious Disease, and Gastroenterology subspecialties. The patient improved steadily, and was later discharged home in the care of her family with a healthy baby and was advised to follow up with her Primary Medical Provider as outpatient.
Conclusions: Legionella pneumonia in pregnancy may be more common than we think, and could be easily overlooked in that patient population, have to be in the back mind of medical provider. Overlooking diagnosis could lead to serious adverse consequences for these patients.

MeSH Keywords: Legionnaires' Disease • Pneumonia • Pregnancy • Sepsis

Full-text PDF: <https://www.amjcaserep.com/abstract/index/idArt/916071>

 2115  1  2  4



Background

Legionella pneumonia (Legionnaire's disease) is a form of bacterial pneumonia first described in attendees of the American Legion convention in Philadelphia in 1976. More than 90% of all cases are caused by the bacteria *Legionella pneumophila*, most commonly serotype 1. *Legionella* bacteria are aerobic, nutritionally fastidious Gram-negative bacilli and facultative intracellular pathogens. However, it is rare in pregnant women. A search of the literature revealed that as of 2015, only 8 such cases have been reported [1]. We are reporting here a case of *Legionella* in a pregnant patient who also had endometritis and sepsis. This could be the only case with this combination.

Case Report

Our patient was an 18-year-old white female patient who was evaluated by the obstetrics and gynecology (OB/GYN) service and initially found to have increasing abdominal pain, and frequency and intensity of uterine contractions accompanied by suprapubic pain, urinary discomfort, and vaginal discharge. She was seen 3 days prior at another facility for abnormal vaginal discharge and low abdominal pain. She had a positive fetal fibronectin test (which indicated risk of preterm labor) but no rupture of membranes. She was discharged with expectant management and instructed to present to Arnot Ogden Medical Center due to prematurity should she have an increase in uterine contractions.

Her past medical history was significant for seizures as a child and depression, but she was not currently on medication. She also had a remote history of smoking.

The patient reported some respiratory symptoms occurring over the past 1 to 2 weeks, including some shortness of breath and coughing with rhinorrhea. At 3 days prior to presentation, she was instructed to use over-the-counter medications for symptomatic relief and was told that these symptoms would eventually resolve on their own since it was presumably a viral illness. Of note, she was previously living in a place that had water damage and was utilizing a humidifier. She moved out of this location about 1 week prior to admission.

She was G1P0 at 34 weeks 6 days on presentation to our facility having had routine and consistent prenatal care with the exception of non-completion of her glucose tolerance test (GTT). She had remained normotensive with appropriate fetal growth and total weight gain of 14 pounds to this point. She also had a normal 20-week anatomy scan. She did report some persistent productive cough and shortness of breath at the time of presentation to our facility along with intermittent nausea. She denied chest pain, lower extremity swelling

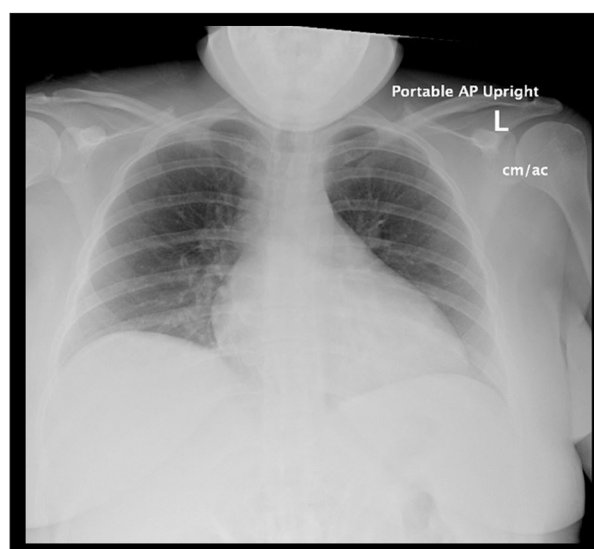


Figure 1. Portable chest x-ray did not show any infiltrate.

or pain. Her vital signs were normal except for tachycardia of 111 beats per minute. Initial examination revealed rupture of membranes with a closed cervix. Her lungs were clear to auscultation. She did have lower extremity edema 1+. The patient was found to have a urinary tract infection. Her group B streptococcus (GBS) status was unknown. She was started on steroid prophylaxis and GBS prophylaxis. She was also given a dose of ampicillin intravenous (IV) and started on cefazolin.

On hospital day 3, the patient underwent a cesarean section. Medical consult was requested after the patient developed a fever of 40.2°C (104.3°F) and tachycardia early on postpartum day 1 (hospital day 4) with suspicion of sepsis. OB/GYN team started the patient on gentamicin and clindamycin for endometritis. Portable chest x-ray (CXR) showed no acute cardiopulmonary disease (Figure 1). Blood cultures were drawn which later returned negative. Initial laboratory tests are shown in Table 1. Further workup included influenza type A and B, respiratory syncytial virus (RSV), urine *Legionella* antigen, urine mycoplasma, and urine streptococcus antigen. All of those returned negative except for the *Legionella* urine antigen. Thyroid function tests were also within normal limits. Lower extremity ultrasound (US) was negative for deep vein thrombosis (DVT). The patient was found to have transaminitis as indicated in Table 1. Right upper quadrant (RUQ) ultrasound the next morning showed a normal liver and common bile duct (CBD) 0.5 cm. There was questionable mild gallbladder wall thickening. The patient was placed empirically on ceftriaxone 1 gm IV and azithromycin 500 mg IV which would also treat her urinary tract infection. Azithromycin was changed to levofloxacin when the urine *Legionella* urine antigen was found to be positive. The patient had recurrent fever and tachycardia (heart rate up to 130 beats per minute) on the night of postoperative day 1 prior to receiving the IV levofloxacin, so she was transferred to the Intensive Care Unit (ICU).

Table 1. Laboratory data.

Variable	Reference range	Hospital Day 1	Day 4	Day 5	Day 6
GBS screen		Detected			
Urinalysis		Small leukocyte esterase, 20–30 WBC no RBC, 5–10 squamous epithelial cells, moderate bacteria			
White cell count (per uL)	4000–11 000	5000			
Hemoglobin (g/dL)	11.6–15.2	12.2	10.4	9.9	9.2
Hematocrit (%)	34–45	36.2			
Platelet count (per uL)	150 000– 450 000	134 000	106 000	109 000	113 000
Mean corpuscular volume (fl)	80–97	81			
Sodium (mmol/L)	136–144		135	135	133
Potassium (mmol/L)	3.6–5.1		3.7		
Chloride (mmol/L)	101–111		107		
Carbon dioxide (mmol/L)	22–32		20		
Glucose (mg/dL)	74–118		90		
Urea nitrogen (mg/dL)	8–20		7		
Creatinine (mg/dL)	0.3–1.0		0.7		
Calcium (mg/dL)	8.9–10.3		7.9 (corrected=9.7)		
Albumin (g/dL)	3.1–4.8		1.7		
Total protein (g/dL)	6.1–8.0		4.4		
Alkaline phosphatase (units/L)	38–126		85	87	85
Total bilirubin (mg/dL)	0.3–1.2		0.3	0.6	0.8
Aspartate aminotransferase (units/L)	14–37		382	635	813
Alanine aminotransferase (units/L)	8–29		202	362	440
C reactive protein (mg/dL)	0–0.9			19.5	
Procalcitonin (ng/mL)	0–0.09			0.39	
Haptoglobin (mg/dL)	30–200			191	
Lactate dehydrogenase (IU/L)	98–192			615	

On postoperative day 2, computed tomography (CT) scan of the chest showed bilateral small basilar infiltrates (Figure 2), confirming the diagnosis of pneumonia. There was also a small ground glass opacity in the left upper lobe. CT scan of the abdomen and pelvis (same day as first RUQ US) revealed hepatic steatosis and hepatomegaly.

Infectious disease (ID) consultation was obtained. The patient wanted to breastfeed her baby, so she was switched back to oral azithromycin starting on postoperative day 3. The patient was treated for endometritis with Zosyn for an additional 3 days. The patient's condition steadily improved. The patient was transferred out of the ICU after 2 days, on hospital day 6, and was discharged on hospital day 9. She was to complete an additional 4 days of therapy with azithromycin for a 10-day

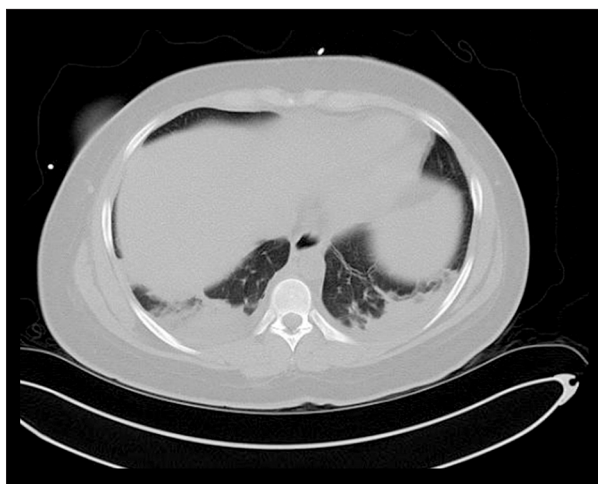

Figure 2. CT scan of the chest image without contrast showing bibasilar infiltrates.

total course. The patient's blood pressure remained essentially within a normal range throughout the entire hospitalization.

The transaminitis peaked on hospital day 6, just over 4 days after admission on postpartum day 3 (Table 1). Aspartate aminotransferase (AST) was 813 U/L, alanine aminotransferase (ALT) 440 U/L and subsequently improved. The international normalized ratio (INR) and bilirubin were normal. Gastroenterology service was consulted. They did obtain an extensive serologic evaluation which came back negative including the hepatitis panel. After discharge, herpes simplex virus (HSV)-1 and HSV-2 IgM as well as parvovirus B19 IgM were positive. The ammonia level was normal. Repeat US on postpartum day 4 showed hepatic steatosis and hepatomegaly (in accordance with the CT scan) with edema adjacent to the gallbladder. The gallbladder itself and the common bile duct (2 mm) were normal. Hepatic arterial and venous flow appeared to be normal. The patient was treated with N-acetyl cysteine by mouth. She received the loading dose plus 15 out of 17 follow-up doses; the patient refused the last 2 doses after discussion with a hepatologist at a nearby university hospital since she did receive some Tylenol on hospital day 4 (a total of 2300 mg). Patient refused transfer to that university hospital which has a liver transplant program.

Repeat liver function tests (LFT) at 1 week after discharge had normalized with the exception of lactic acid dehydrogenase (LDH) which was only slightly elevated at 212 U/L.

The patient also had mild thrombocytopenia and anemia which nadired on postpartum day 1 and day 3 (hospital day 4 and day 6) respectively (Table 1). Haptoglobin was normal (Table 1) and LDH was 615 U/L on postpartum day 4 (the LDH level went back down after that). The sodium level was relatively normal throughout, with the lowest measurement of 133 mEq/L on postpartum day 3.

Discussion

Pneumonia generally is not uncommon in pregnancy; susceptibility in pregnancy is higher taking into consideration immunologic alterations. There is also diminished respiratory reserve in pregnant women due to elevation of the diaphragm from the pregnant uterus, alteration of chest shape, and increased maternal oxygen consumption.

Pregnancy also is known to increase the risk of maternal complications of pneumonia including mechanical ventilation and empyema formation [2].

Fetal complications of pneumonia include low birth weight and higher risk of preterm birth.

Full workup for pregnant patients with respiratory symptoms should include evaluation for viral causes (including influenza) and bacterial pathogens including atypical pathogens like *Legionella*.

Legionellosis has 2 forms: the more severe form includes pneumonia known as legionnaires disease and the milder form known as Pontiac fever. Both conditions are caused by the bacterium *Legionella pneumophila* of which there are 48 species and 15 serogroups.

L. pneumophila is a gram-negative intracellular bacillus that lives in aquatic environment. It reaches the respiratory system by ingestion of contaminated water droplets. Once ingested in the lungs, *Legionella* replicates in the alveolar macrophages.

Our patient had flooding secondary to water leakage in the basement of her house which she had to deal with initially by herself until other family members were able to take care of this problem.

Legionella pneumonia is not common in young people. More than 75% of cases occur in people 50 years of age or older, which makes our patient atypical in that respect. It is most often diagnosed in hospitalized patients and can be severe. Up to 44% of cases have been reported to require ICU admission with an associated mortality of approximately 1% to 10%. Our patient was in late pregnancy.

For the treatment of *Legionella pneumonia*, fluoroquinolone is the drug of first choice compared to macrolides. However, generally speaking, this is not necessarily the case in pregnancy. Our patient also wanted to breast feed her baby, which made our choice the macrolide Zithromax. Our patient improved subsequently as explained in this report. Of note, her clinical course was also complicated by sepsis and elevated LFTs, which can be seen in *Legionella* infections and which is not

unexpected; however, our gastroenterology service prescribed N-acetyl cysteine (NAC N), acetylcysteine full oral dose to cover for possible contribution of Tylenol which she received initially but was still within therapeutic dose range. The gastroenterology team also contemplated that the elevated LFT was drug induced due to the ceftriaxone and Zosyn she received.

In the end, we concluded that the elevated LFT was in the context of Legionella infection.

Few other cases of Legionella in pregnancy have been reported in the medical literature. One case was reported in 1997 by Tewari et al. [3] of a patient with fever 104°F (40°C), respiratory distress, and circulatory compromise requiring emergency C section at 35 6/7 weeks of gestation. This patient required intubation and antibiotics for 12 days; the newborn was acidotic and suffered bowel perforation and required partial bowel resection [3]. Another case was reported by Gaillac [4] in 2006 with favorable outcome at 31 weeks of gestation; the patient was treated appropriately with good outcome. We also have in the medical literature a case by Xu et al. [1] of a 30-year-old woman at 28 weeks of gestation in respiratory distress who presented with high fever, nausea, and vomiting. She was initially presumed to have urosepsis and was treated accordingly, but deteriorated and was transferred to ICU and intubated for 10 days. She received cardiovascular support as well as antiviral, antifungal, and multiple broad-spectrum antibiotics. Urine Legionella antigen testing was performed on hospital day 1 which returned positive. Azithromycin was continued for 14 days and the patient recovered.

Epping [2] discussed a 26-year-old pregnant woman with Crohn's disease who required surgery and who received infliximab during pregnancy (immunosuppressed) and developed fever, nonproductive cough, nausea and vomiting, but no diarrhea. She did have slightly elevated transaminases. She was successfully treated with erythromycin for a total of 14 days with full recovery and carried her pregnancy to term.

Our patient was a challenge from day one. She was seen at a major facility in the area a few days prior to presentation to Arnot Ogden Medical Center, with upper respiratory symptoms in context of later term pregnancy. She was told to take

over-the-counter medications for her symptoms. However, she did not improve. Had she not been correctly diagnosed, and if her Legionella pneumonia had been overlooked, the outcome could have been tragic. Thankfully, and despite hurdles such as a negative CXR initially, our clinical index of suspicion for pneumonia was high to support and justify full pneumonia workup, resulting in correct diagnosis of Legionella pneumonia with its sequelae such as elevated LFT.

Conclusions

Respiratory infections in pregnancy can be challenging. Legionella pneumonia is generally rare in pregnancy, not many cases are reported in the medical literature.

Legionella pneumonia infection should be considered if there is maternal deterioration despite being on broad spectrum antibiotic coverage.

Good history taking is essential and extremely important and cannot be over emphasized. A high index of suspicion is required to ensure that these infections are diagnosed and treated promptly and appropriately. Close follow-up is imperative in pregnant patients, even if symptoms seem benign, to identify any deterioration early and to minimize the chance of an unfavorable outcome.

As discussed, pneumonia in pregnancy can be harmful to both the mother and the fetus. In our patient, a multidisciplinary system involvement, including ICU care, proved to be essential for good outcome.

Acknowledgements

Gary Nicholson, Obstetrics and Gynecology (OB/GYN) called for the consultation and later provided link and information on the topic on the internet.

Conflicts of interest

None.

References:

1. Xu J, Odibo IN, Eastham DG, Dajani NK: Legionella infection in pregnancy: The forgotten pathogen in septic shock. *Obstet Gynecol*, 2015; 126(5): 1085–87
2. Epping G, van der Valk PD, Hendrix R: Legionella pneumophila pneumonia in a pregnant woman treated with anti-TNF-α antibodies for Crohn's disease: A case report. *J Crohns Colitis*, 2010; 4(6): 687–89
3. Tewari K, Wold SM, Asrat T: Septic shock in pregnancy associated with Legionella pneumonia: Case report. *Am J Obstet Gynecol*, 1997; 176(3): 706–7
4. Gaillac N, Floccard B, Ould T et al: Legionella pneumophila pneumonia during pregnancy: A case report. *J Infect*, 2006; 52(6): e163–64