

Endoscopic ultrasound-guided fine-needle aspiration plus KRAS and GNAS mutation in malignant intraductal papillary mucinous neoplasm of the pancreas

Authors

Barbara Bournet^{1,2}, Alix Vignolle-Vidoni², David Grand³, Céline Roques³, Florence Breibach³, Jérôme Cros⁴, Fabrice Muscari⁵, Nicolas Carrère^{2,6}, Janick Selves^{2,3}, Pierre Cordelier², Louis Buscaïl^{1,2}

Institutions

Institutions are listed at the end of article.

submitted

20. February 2016

accepted after revision

19. August 2016

Bibliography

DOI <http://dx.doi.org/10.1055/s-0042-117216>

Published online: 10.11.2016

Endoscopy International Open

2016; 04: E1228–E1235

© Georg Thieme Verlag KG

Stuttgart · New York

E-ISSN 2196-9736

Corresponding author

Louis Buscaïl, MD, PhD

Department of

Gastroenterology and INSERM

U1037

CHU Rangueil

1 avenue Jean Poulhès

TSA 50032

31059 Toulouse Cedex 9

France

Phone: +33 5 61 32 30 55

Fax: +33 5 61 32 22 29

Buscaïl.L@chu-toulouse.fr

Background: *KRAS* and *GNAS* mutations are common in intraductal papillary mucinous neoplasia of the pancreas (IPMN). The aims of this study were to assess the role of pre-therapeutic cytopathology combined with *KRAS* and *GNAS* mutation assays within cystic fluid sampled by endoscopic ultrasound-guided fine-needle aspiration (EUS-FNA) to predict malignancy of IPMN.

Patients and methods: We prospectively included 37 IPMN patients with clinical and/or imaging predictors of malignancy (men: 24; mean age: 69.5 years). Cytopathology (performed on cystic fluid and/or IPMN nodules), *KRAS* (Exon 2, codon 12) and *GNAS* (Exon 8, codon 201) mutations assays (using TaqMan[®] allelic discrimination) were performed on EUS-FNA material. The final diagnosis was obtained from IPMN resections (n=18); surgical biopsies, EUS-FNA analyses, and fol-

low-up (n=19): 10 and 27 IPMN were benign and malignant, respectively.

Results: Sensitivity, specificity, positive and negative predictive values, and accuracy of cytopathology alone to diagnose IPMN malignancy were 55%, 100%, 100%, 45%, and 66%, respectively. When *KRAS*-mutation analysis was combined with cytopathology these values were 92%, 50%, 83%, 71%, and 81%, respectively. *GNAS* assays did not improve the performances of cytopathology alone or those of cytopathology plus a *KRAS* assay.

Conclusions: In patients with a likelihood of malignant IPMN at pre-therapeutic investigation, testing for *KRAS* mutations in cystic fluid sampling by EUS-FNA improved the results of cytopathology for the diagnosis of malignancy whereas *GNAS* mutation assay did not.

Introduction

Intraductal papillary mucinous neoplasia of the pancreas (IPMN) is characterized by adenomatous proliferation of the pancreatic-duct epithelium and may involve the main pancreatic duct (MPD), the branch ducts (BD), or both [1]. Accordingly, IPMNs are named after the structure from which they are derived and are classified into 3 groups: the MPD, branch duct, or mixed (when they originate from both the main duct and branch ducts).

Without exception, all cases of IPMN are considered to be potentially malignant [1,2] and surgical resection of pancreatic lesions is recommended to prevent transformation into malignancy. In most cases, BD-IPMNs are benign, but there is a 15% risk of invasive carcinoma [3–8]. Conversely, MPD- and mixed-IPMN cases are frequently malignant with a 50% risk of invasive carcinoma [9–12]. Until now, predictive factors for malignancy have not been fully defined and are still de-

bated, even considering the consensus meeting held in 2012 [2].

Many studies, including ours, have provided several clinical and imaging pre-therapeutic criteria for malignancy, which greatly influence the prognosis and mortality from IPMN, such as age (>70 years), presence of symptoms, a BD lesion with a diameter >3 cm, dilatation of the MPD, presence of mural solid nodules and/or thickening of a branch-duct cyst or the MPD wall, lymph nodes, peri-pancreatic extension, and positive cytology [11–14]. The recent consensus divided these indications into “high-risk stigmata” and “worrisome features” [2].

Taking into consideration that surgical resection of IPMN with a “malignancy signature” is the best-recommended treatment, the benefit–risk ratio should be considered. Surgical intervention may include major pancreatic resection, such as the Whipple procedure, or total pancreatectomy, as is routinely used for multifocal lesions: these procedures have risks of mortality and morbidity of 0% to 5% and 30% to 50%, respectively [15].

License terms



Therefore, in aged patients and/or patients with comorbidities, a preoperative diagnosis or a prediction of malignancy could be highly useful in current clinical practice.

Endoscopic ultrasound (EUS) is a highly sensitive imaging modality used to evaluate pancreatic cystic lesions. Assessment of cyst fluid for carcinoembryonic antigen (CEA) levels does not differentiate IPMN from mucinous cystic neoplasm and does not correlate with the degree of dysplasia or malignancy [16–18].

Molecular pathology and genetic changes have been studied in IPMN and have shown that a point *KRAS* mutation is found in 48% of benign cases of IPMN (low-grade or intermediate dysplasia) [19,20]. *GNAS* mutations are present in 50% to 64% of cases of IPMN (predominantly of the intestinal subtype and to a lesser extent the gastric subtype) [21–24]. Recent studies report that *GNAS* and/or *KRAS* mutations were found in 90% of cases of IPMN [24,25]. However, the role of *KRAS* and *GNAS* assays for the diagnosis of malignancy remains controversial and preliminary, taking into account that mutations of *KRAS* and *GNAS* were found in 50% to 83% and 25% to 83% of malignant IPMN, respectively [19,23,24]. In other terms, whether DNA-based mutation assays are good biomarkers for predicting malignancy of IPMN remains to be demonstrated.

The aims of our study were to assess the role of pre-therapeutic cytopathology combined with *KRAS* and *GNAS* mutation assays within cystic fluid, sampled by EUS-FNA, to predict malignancy in a subgroup of patients with a likelihood of degenerative IPMN.

Patients and methods



Patients and inclusion criteria

Forty-one patients with BD, MPD-IPMN, or mixed-IPMN were prospectively enrolled between January 2010 and December 2014. A diagnosis of BD IPMN was established from radiologic criteria when unilocular or multilocular lesions with grapelike structures were observed communicating with the pancreatic ducts. In cases of mixed- or MPD-IPMN, MPD dilatation ≥ 5 mm was present in all patients. These imaging criteria were formerly identified (including communication between BD-cyst and MPD) from at least 2 morphologic examinations, including computed tomography (CT) scan, magnetic resonance cholangiopancreatography (MRCP), and EUS.

We selected jaundice, acute pancreatitis, diabetes, BD dilatation > 30 mm, mural-tissue component or thickening (branch-duct cyst or MPD wall), MPD size > 10 mm, and lymph nodes as predictors of malignancy (i.e., a high likelihood of degenerative IPMN) as previously described [1, 10, 11, 13].

We excluded patients with IPMN and without clinical and/or imaging predictors of malignancy, a pancreatic cystic tumor that was different from IPMN, a solid pancreatic tumor, evidence of metastasis or a non-resectable pancreatic cystic tumor, and a contraindication to undergo an EUS-FNA.

Data, imaging, and EUS-FNA at inclusion

The clinical data recorded were age, gender, medical history, circumstances of diagnosis, and symptoms related to IPMN. All patients underwent helical triple-phase CT examinations and MRCP was performed in 81% of patients [8,11]. EUS-FNA procedures were performed, as previously described [8,11,26] (Olympus GF-UC140T echo-endoscope–Hamburg, Germany). Data recorded at imaging were maximal diameter of the MPD and branch-duct cyst, the tissular component surrounding the MPD, mural

modules and/or tissular thickening of the MPD and/or BD cyst wall (mainly at EUS), localization of BD lesions, and maximal diameter of the side-branch IPMN.

In each patient with predictor signs of malignancy, a fine-needle aspiration of cystic fluid was obtained using a Wilson Cook USN1 22G needle biopsy (Limerick, Ireland). All the cystic fluid was systematically sampled (with a collapse of cystic walls) and placed in a dry sterile tube for cytologic analysis (a minimum of 1 mL), except 500 to 750 microliters that was kept for molecular analyses. In cases where there was a mural nodule or a solid component within the IPMN, another FNA was systematically performed during the same procedure, using a different needle, in order to obtain tissue for a histologic microbiopsy (core biopsy). In cases where IPMN was resected, the pathology and IPMN histologic subtypes were assessed. The pathologic classification of IPMN was adopted in this work as follows: low-grade dysplasia, high-grade dysplasia, and invasive carcinoma [1,2]. We considered malignant IPMN as having high-grade dysplasia and invasive carcinoma. In patients where an IPMN resection was not performed, clinical and biological follow-up were systematically conducted at least every 6 months (hospitalization or consultation), together with abdominal imaging (MRCP or CT) performed every 6 months for the first year, and then annually. In cases of clinical and/or radiologic evolution of IPMN, another EUS-FNA was performed.

For all patients, decisions on management were systematically made during a multidisciplinary meeting dedicated to pancreatic disease and that included at least 2 gastrointestinal surgeons, 2 gastroenterologists, an anesthesiologist, a pathologist and a radiologist. The regional platform committee for somatic genetics of tumors in the Midi-Pyrénées approved the protocol for the *KRAS* and *GNAS* assays from the EUS-FNA samples. Informed written and signed consent for investigations was obtained from each patient and the research was conducted in full accordance with ethical principles outlined in the Declaration of Helsinki.

KRAS and *GNAS* mutation assays

The cystic fluid from IPMN was sampled using EUS-FNA: 500–700- μ L aliquots were placed in dry sterile 1-mL Eppendorf tubes, and were rapidly frozen at -20°C until DNA was extracted. Samples were then centrifuged for 10 minutes at 8000 rpm. DNA was extracted from the pellets using a QIAamp DNA micro kit (QIAGEN–Les Ulis, France). Nucleic acids were quantified using a Nanovue spectrophotometer (GE Healthcare, Buckinghamshire, UK).

To identify *KRAS* exon 2, codon-12 mutations, we performed a mutation-detection assay based on custom TaqMan[®] MGB[™] dual probes (*KRAS* codon-12 mutations: c.34G $>$ C/p.G12R; c.35G $>$ A/p.G12D; c.35G $>$ T/p.G12V). Polymerase chain reaction (PCR) sequences were detected using 20 ng of genomic DNA, as previously described [27]. The remaining DNA was subsequently used to assess *GNAS* mutations.

To identify the *GNAS* exon 8, codon-201 mutations, we performed a mutation-detection assay based on custom TaqMan[®] MGB[™] dual probes (*GNAS* codon-201 mutations: c.601C $>$ T/p.R201C and c.602G $>$ A/p.R201H). Each probe incorporated a 5' reporter dye (VIC/FAM) specific to the WT or SNP sequence, and a 3' non-fluorescent quencher. Positive controls included DNA that was extracted from resected IPMN specimens and with known *GNAS* R201C and R201H mutations (sequencing). The negative control included DNA extracted from human pancreatic cancer cells (MiaPaca2 cells) with a known *GNAS* wild type [28]. Ampli-

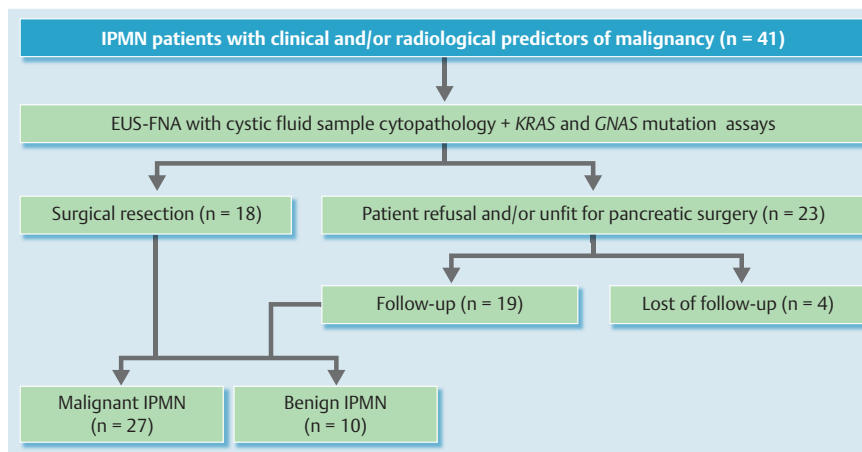


Fig. 1 Flowchart of the study, including distribution of intraductal papillary mucinous neoplasia of the pancreas (IPMN) in patients depending on resection or not and the follow-up. IPMN with predictors of malignancy that indicated a high likelihood of malignancy were: jaundice, branch-duct dilatation >30 mm, a mural-tissue component, dilatation of the main pancreatic duct >10 mm, or lymph nodes. Malignant IPMN means high-grade dysplasia and invasive carcinoma; benign IPMN means low-grade dysplasia.

fication of the probe-specific product caused cleavage of the probe and generated an increase in reporter fluorescence. The use of a dual probe in each experiment made it possible to discriminate the signal for WT- and SNP-specific fluorescence in a single PCR and closed-tube format. Each alternation was screened with a dual-probe assay, with a wild-type and mutant for each of the 2 mutations screened. The runs were performed on a ROCHE LightCycler 480II (Roche Life Science, Boulogne-Billancourt, France) real-time PCR system. PCR was done in 10- μ L reaction volumes that included 20 ng of genomic DNA and a 1X final master-mix custom Taqman[®] SNP genotyping assay (Life Technologies, Gent, Belgium). The cycling condition was a 3-step PCR in 96-well plates, as follows: denaturation at 95 °C for 15 min, amplification for 40 cycles at 95 °C for 10 s, at 60 °C for 1 min, and then cooling at 40 °C for 30 s. Each run included positive and negative controls. Investigators who performed the *KRAS* and *GNAS* assays were blinded to the diagnoses.

Statistical analyses

Results are expressed as mean \pm SE. Qualitative and quantitative data were analyzed using Student's *t*-test, the chi-squared test, or Fisher's exact test, and Spearman's and Pearson's correlation tests, as appropriate, using GraphPad-Instat (version 3.1a) and GraphPad-Prims (version 6) software.

Results

Patient characteristics and diagnoses

Among the 41 patients diagnosed with IPMN, 18 underwent surgical resection with confirmation of IPMN in all cases (a Whipple procedure in 9, a left pancreatectomy in 7, a total pancreatectomy in 2). Twenty-three patients did not undergo resection because 3 cases of IPMN displayed signs of unresectability at laparotomy, 3 patients refused surgery, and 17 patients had contraindications for pancreatic surgery because of age and/or multiple comorbidities, including concomitant extra-pancreatic carcinoma.

In the non-surgical group, 4 patients refused follow-up, so a diagnosis could not be confirmed. Among the 41 patients included, 37 could be analyzed (the flowchart for the study is shown in [Fig. 1](#)). [Table 1](#) and [Table 2](#) show the clinical, imaging, cytopathologic, and molecular characteristics at EUS-FNA of these 37 patients (men: 24; women: 13; mean age 69.5 years, median age 70 years). Half of the patients presented with at least 2 predictive signs of malignancy at diagnosis. No complication

occurred during or after the EUS-FNA procedure. A final histologic diagnosis was obtained for all patients from resected specimens ($n=8$) ([Table 1](#)). For non-resected IPMN the final diagnosis was obtained ([Table 2](#)): from biopsy tissue material obtained during a laparotomy ($n=3$), from core biopsy at initial EUS-FNA ($n=12$) and/or subsequent follow-up with second biopsy (EUS- or CT-guided) and occurrence of metastasis in case of malignant IPMN. On the whole, all 19 patients with non-resected IPMN were followed up after diagnosis (median 13 months, range 4–60). In 8 patients with invasive carcinoma or high-grade dysplasia at baseline FNA ($n=6$), or who had a surgical biopsy during laparotomy ($n=2$) disease progressed both clinically and anatomically (median follow-up 7.5 months, deaths $n=5$). In the 6 patients with no malignancy found on EUS-FNA (low-grade dysplasia or normal/hyperplasia), an invasive carcinoma was subsequently diagnosed based on clinical and/or imaging evidence (including a subsequent EUS-guided or CT-guided FNA with histologic analysis of a microbiopsy as well as a surgical biopsy during laparotomy): the median time to diagnosis of carcinoma was 8.5 months (range 2–24) and there were 4 deaths. The 5 remaining patients did not have disease progression (median follow-up 52 months: range 14–58 months), and this included 3 subsequent EUS-FNAs that still showed low-grade dysplasia. In these 5 patients, a diagnosis of benign IPMN was definitively attributed. Taking into account resected and non-resected IPMN, the final diagnoses were benign IPMN in 10 and malignant IPMN in 27 patients (i. e., 2 with high-grade dysplasia; 25 with invasive carcinoma).

Cytopathology and yield of *KRAS* and *GNAS* assays at the baseline EUS-FNA

Cytology and/or histologic analysis of EUS-FNA materials are detailed in [Table 1](#) and [Table 2](#) for patients with confirmed IPMN and carcinoma ($n=11$, 30%), for IPMN with high-grade dysplasia ($n=4$, 11%), and for IPMN with low-grade dysplasia and normal/hyperplasia ($n=22$, 59%). *KRAS* and a *GNAS* assays were possible in all cases except one because of insufficient DNA material for subsequent *GNAS*-mutation analysis after assessing *KRAS* status. [Fig. 2](#) shows the representative curve plots for wild-type and mutated *KRAS* and *GNAS* samples. The mean quantity of DNA extracted per sample was 269 ± 58 ng (min: 35 ng; max: 1660 ng). There was no statistical difference in terms of quantity of DNA extracted from the subgroups with wild-type (232 ± 73 ng) or mutated (290 ± 86 ng) *KRAS* and *GNAS* ($P=0.65$), or between the 2 subgroups with malignant (250 ± 78 ng) or be-

Table 1 Clinical, anatomical, and molecular characteristics, and pathologic findings in patients with resected branch-duct (BD)-, mixed-, or main pancreatic duct (MPD) intraductal papillary mucinous neoplasia of the pancreas (IPMN).

#	Sex	Age	signs	Type	BD size (mm)	MPD size (mm)	Site	Cytopathology at EUS-FNA	KRAS status	GNAS status	Final histology and diagnosis
1	M	62	Pain	Mixed	27	6	Head	Normal	G12D	R201C	IC, gastric
2	W	75	None	Mixed	60	8	Head	Carcinoma	WT	WT	HGD pancreato-biliary
3	M	58	Pain	Mixed	32	11	Head	Carcinoma	G12V	WT	IC, intestinal
4	W	76	Diabetes	BD	35	3.5	Body	Carcinoma	G12V	WT	IC, intestinal
5	W	71	None	Mixed	6	12	Head	Normal	WT	WT	IC, intestinal
6	M	72	Pain	Mixed	70	8	Head	Carcinoma	WT	WT	IC, intestinal
7	M	59	AP	Mixed	35	7	Head	Carcinoma	WT	WT	IC intestinal
8	M	65	None	Mixed	25	6	Body	Carcinoma	G12V	WT	IC, intestinal
9	W	80	None	Mixed	50	6	Tail	LGD	G12D	WT	HGD, gastric
10	M	57	None	Mixed	40	8	head	LGD	WT	WT	LGD, gastric
11	M	61	AP	Mixed	40	5	head	Normal	G12D	R201H	LGD, gastric
12	W	72	Weight loss	BD	90	5	head	HGD	WT	R201H	IC, gastric
13	W	66	None	Mixed	18	6	body	Carcinoma	WT	WT	IC, intestinal
14	M	65	none	Mixed	33	6	head	Normal	G12V	R201H	IC, gastric
15	M	68	Weight loss	Mixed	30	7	head	LGD	G12D	R201C	LGD, intestinal
16	M	77	Pain	Mixed	32	12	body	Normal	G12D	WT	LGD, gastric
17	M	62	Pain	Mixed	40	9	head	LGD	G12D	WT	IC, pancreato-biliary
18	M	70	AP	BD	25	3	head	LGD	G12D	R201C	LGD, gastric

IC: IPMN with invasive adenocarcinoma; HGD = high-grade dysplasia IPMN; LGD = intermediate or low-grade dysplasia IPMN; AP: acute pancreatitis; BD: branch duct IPMN; MD: main-duct IPMN; mixed: mixed IPMN. WT: wild-type.

nign (288 ± 103 ng) IPMN at the final diagnosis ($P=0.85$) (unpaired Student's *t* test). In addition, there was no correlation between the size of the BD-IPMN in which fluid samples had been made by EUS and the amount of extracted DNA (Pearson's and Spearman's correlation tests: $0.027 < r < 0.05$, data not shown). This indicates that neither the presence of malignancy nor the size of the side-branch IPMN influenced the amount of DNA in the cystic fluid.

Combination of cytopathology and the KRAS/GNAS mutation assays to predict IPMN malignancy

Data on sensitivity, specificity, predictive values, overall accuracy of the cytopathology alone, the KRAS analysis alone, the GNAS analysis alone, and the combination of either 2 or 3 tests to diagnose malignant versus benign IPMN are detailed in **Table 3**. We observed that combining cytopathologic analysis and the KRAS mutation assay increased the sensitivity (from 53 to 92%), the negative predictive value (NPV) (from 45 to 71%), and the accuracy (from 66 to 81%) compared to cytopathology alone to diagnose malignant IPMN. This was not observed when using the combined cytopathologic analysis and GNAS-mutation assay. In addition, combining the cytopathology and KRAS and GNAS assays did not improve the performance of combining cytopathology and the KRAS assay. In **Table 4** we compared the performances of cytopathology alone and the combination of cytopathology plus KRAS status in the 2 subgroups of patients that did or did not undergo resection of their IPMN. In these 2 subgroups, the sensitivity, the NPV, and the accuracy of cytopathology alone to diagnose IPMN malignancy were also increased when they were combined with the cystic fluid KRAS-mutation assay. Overall, we can conclude that when the EUS-FNA cytopathology and KRAS mutation assay are combined we can predict a malignancy in 80% of cases of IPMN.

Discussion

In this prospective study, we investigated a subgroup of IPMN patients who had clinical predictors of malignancy assessed at diagnosis. We demonstrated that when the KRAS-mutation analysis was added to the cytopathology data from EUS-FNA materials, this improved the ability to diagnose malignancy. This is of importance as it will improve our ability to identify patients with high-grade dysplasia or invasive malignant IPMN and who might benefit from surgical resection. We also observed that testing for the GNAS mutation did not improve the performance of cytopathology alone or the combination of cytopathology plus the KRAS assay to diagnose this indication.

As previously observed in solid tumors, despite the paucity of material collected for molecular analysis from IPMN cystic fluid, which rarely exceeds 500 μ l, DNA extraction can be performed in 100% of cases [27]. Use of an extraction micro-kit enables this success rate. The amount of DNA was half that observed from EUS-FNA materials from solid pancreatic tumors [27]. In addition, the amount of DNA was not influenced by the mutational status, the size of the cyst or its stage. To our knowledge, this study demonstrates, for the first time, that TaqMan allelic discrimination is feasible on material collected from pancreatic cystic fluid to assess both KRAS and GNAS mutation status.

As already observed, cytopathology has a sensitivity of ~50% (with high specificity) in diagnosing malignancy of IPMN [16–18] but it is inferior to pre-therapeutic clinical imaging. In comparison, the codon-12 KRAS mutation assay alone had performance similar to that of cytopathology, with lower specificity and positive predictive value due to false-positive results (i.e., the presence of KRAS mutations in patients with low-grade dysplasia). However, when cytopathology and the KRAS assay are combined, sensitivity, NPV, and accuracy were substantially increased (sensitivity increased from 55 to 92%, NPV from 45% to 71%, and accuracy from 66% to 81%). This indicates that associating cytopathology and testing KRAS in EUS-FNA material from

Table 2 Clinical, anatomic, and molecular characteristics, and pathologic findings of patients with non-resected branch-duct (BD)-, mixed-, or main pancreatic duct (MPD) intraductal papillary mucinous neoplasia of the pancreas (IPMN).

#.	Gender	Age	Signs	Type	BD size (mm)	MPD size (mm)	Site	Cytopathology at EUS-FNA	KRAS status	GNAS status	Final diagnosis (assessment)
1	W	56	Pain	BD	30	4	Head	Carcinoma (cytology)	G12D	WT	IC, gastric (surgical biopsy)
2	M	73	Pain	BD	50	4	Head	Normal (cytology)	G12D	WT	IC, intestinal (surgical biopsy)
3	M	75	Pain	BD	60	4	Body	HGD (core biopsy)	WT	R201C	IC (surgical biopsy)
4	W	82	Jaundice	Mixed	20	12	Body	HGD (core biopsy)	G12D	WT	IC (follow-up)
5	M	79	Weight loss	Mixed	30	7	Head	LGD (core biopsy)	G12V	WT	IC (follow-up)
6	M	64	None	Mixed	33	8	Head	LGD (core biopsy)	G12V	WT	LGD (second biopsy)
7	M	73	Jaundice	BD	35	3.5	Head	HGD (core biopsy)	G12D	WT	IC, intestinal (follow-up)
8	M	78	Diabetes	BD	32	5	Head	LGD (cytology)	WT	WT	LGD (follow-up)
9	M	67	None	Mixed	35	7	Head	Normal (cytology)	G12D	WT	IC (follow-up)
10	M	85	Jaundice	Mixed	40	8	Head	Normal (cytology)	G12V	WT	IC (follow-up)
11	W	57	Pain	Mixed	75	6	Body	Normal (cytology)	G12D	WT	IC (second biopsy)
12	W	58	None	BD	50	3	Body	LGD (core biopsy)	WT	WT	LGD (follow-up)
13	W	67	Pain	BD	30	4	Body	HGD (core biopsy)	G12R	WT	IC (follow-up)
14	W	78	None	BD	31	3	Body	LGD (core biopsy)	WT	WT	LGD (follow-up)
15	M	64	Jaundice	Mixed	33	8	Head	Carcinoma (core biopsy)	WT	R201C	IC, intestinal (follow-up)
16	W	70	Jaundice	Mixed	30	5	Head	LGD (cytology)	WT	WT	IC (follow-up)
17	M	84	Pain	Mixed	60	6	Head	Normal (core biopsy)	WT	WT	LGD (second biopsy)
18	M	67	Bowel obstruct.	Mixed	35	11	Body	Carcinoma (core biopsy)	G12D	WT	IC, gastric (follow-up)
19	M	78	None	Mixed	28	7	Head	Carcinoma (core biopsy)	G12D	ND	IC (follow-up)

IC: IPMN with invasive adenocarcinoma; HGD=high-grade dysplasia IPMN; LGD=intermediate or low-grade dysplasia IPMN; AP: acute pancreatitis; BD: branch duct IPMN; MD: main-duct IPMN; mixed: mixed IPMN. WT: wild-type. For initial EUS-cytopathology the material obtained is detailed in parenthesis: cytology alone (cytology n=7) or histology on core biopsies (core biopsy n=12). For the final diagnosis the assessment is detailed in parenthesis: surgical biopsy during laparotomy, second biopsy (EUS- or CT-guided) and follow-up (subsequent occurrence of metastasis).

IPMN may help predict malignancy in patients with BD or a mixed form of IPMN.

Conversely, the codon 201 *GNAS* mutation assay did not improve diagnosis. Moreover *GNAS* mutation (22%, intestinal and gastric subtypes) appeared less frequently than previously observed in micro-dissected specimens of resected IPMN, in cystic fluid, or in duodenal fluid sampled under secretin stimulation (50%–66% of mutated *GNAS*) [21,24,25,29]. Interestingly, when considering the subgroup of IPMN with high-grade dysplasia and invasive carcinoma, frequency of *GNAS* mutations ranges from 15%–33% and is found to be significantly less in cases of IPMN with invasive carcinoma when compared to other histopathologic grades [24,25,30]. Regarding the current study, almost 75% of patients with IPMN were diagnosed with high-grade dysplasia and invasive carcinoma. Such a patient population may account for the low frequency of *GNAS* mutations in our study.

A recent study from Tan et al., performed on micro-dissected IPMN tissues, did not find any significant difference in terms of *KRAS* or *GNAS* mutations according to the degree of dysplasia [22]. However, *GNAS* mutations were more frequent in colloidal-type (89%) than in tubular-type (32%) invasive carcinoma, respectively [22]. Conversely, *KRAS* mutations were significantly more frequent in the tubular-subtype (89% vs. 52%). In our work, almost 50% of cases with resected IPMN and invasive carcinoma were either gastric or pancreatobiliary subtypes that generated adenocarcinoma with a tubular shape. Such an observation may also explain the low incidence of *GNAS* mutations in our series. Another explanation could be that cystic fluid sampled by EUS-FNA may contain only neoplastic cells from a limited area and does not reflect the entire pancreas, including the MPD. However, the frequency of *KRAS* mutations in our patient cohort was 62%, an amount that is commonly found in IPMN tissues and fluid, including within high-grade or invasive cases [23–25].

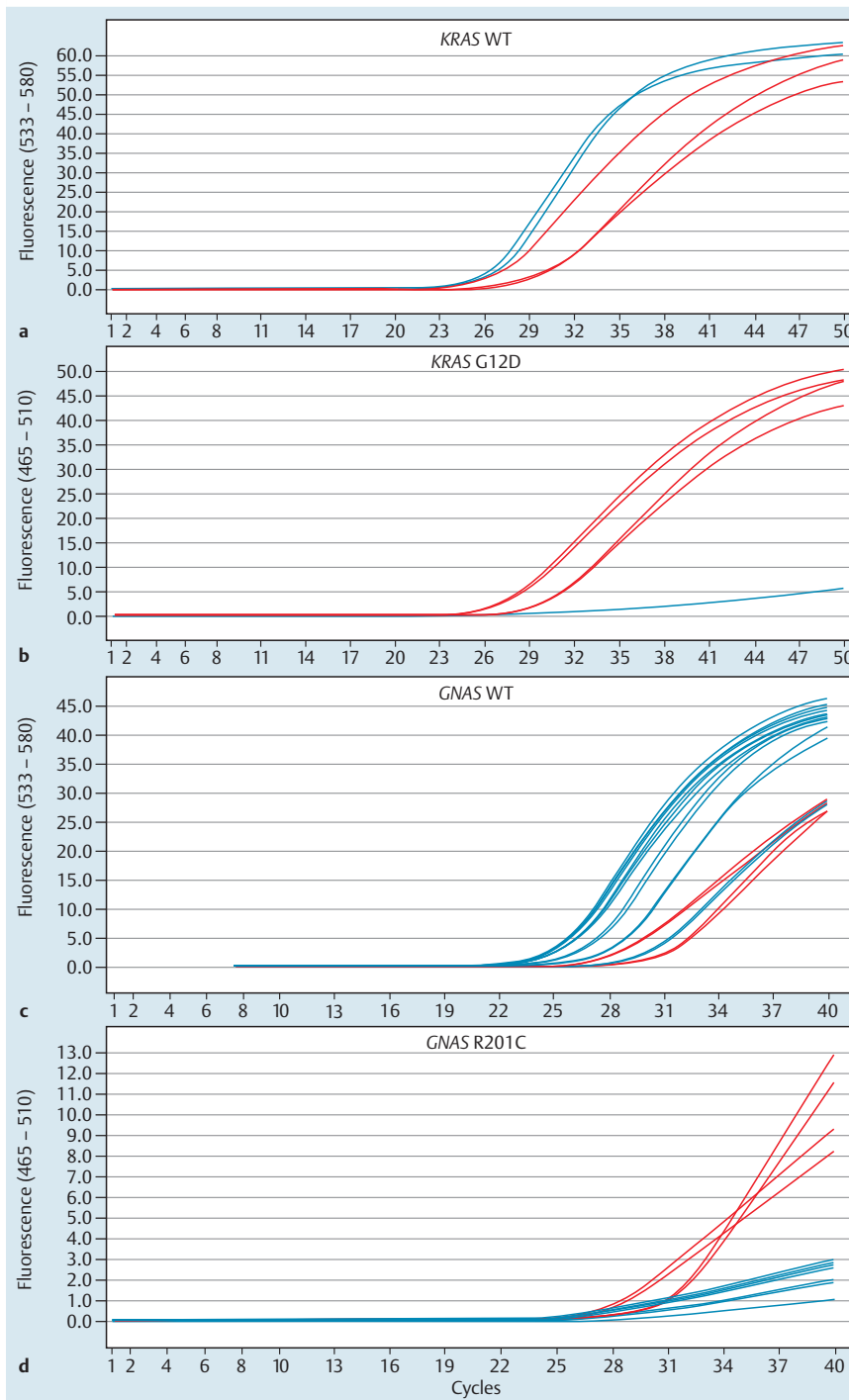


Fig. 2 Representative chromatogram of TaqMan allelic discrimination analysis of G12D *KRAS* and R201C *GNAS* mutations obtained from EUS-guided fine-needle cystic-fluid aspiration from intraductal papillary mucinous neoplasia of the pancreas (IPMN). Panels **a** and **c**: plots of a wild-type DNA sample; panels **b** and **d**: plots of mutated DNA samples with distinct curves generated by mutated and wild-type probes.

Table 3 Performance of cystic fluid EUS-FNA, EUS-FNA and a *KRAS* assay, EUS-FNA and a *GNAS* assay, EUS-FNA and a *KRAS* plus a *GNAS* assay to diagnose malignant intraductal papillary mucinous neoplasia of the pancreas (IPMN) in 37 patients with clinical and/or radiologic predictors of malignancy.

	Sensitivity (95% CI)	Specificity (95% CI)	PPV (95% CI)	NPV (95% CI)	Accuracy (95% CI)
EUS-FNA	55 (35–94)	100 (69–100)	100 (78–100)	45 (24–67)	66 (54–96)
<i>KRAS</i>	66 (46–83)	50 (18–80)	78 (56–92)	36 (12–64)	61 (48–92)
<i>GNAS</i>	19 (6–38)	70 (34–93)	62 (24–91)	24 (10–43)	61 (43–87)
EUS-FNA + <i>KRAS</i>	92 (75–99)	50 (18–81)	83 (66–93)	71 (29–96)	81 (67–96)
EUS-FNA + <i>GNAS</i>	62 (42–80)	70 (34–93)	85 (62–96)	41 (18–67)	64 (37–83)
EUS-FNA + <i>KRAS</i> + <i>GNAS</i>	92 (75–99)	50 (18–81)	83 (66–93)	71 (29–96)	81 (67–96)

PPV: positive predictive value; NPV: negative predictive value; EUS-FNA: endoscopic ultrasound-fine-needle guided aspiration.

This document was downloaded for personal use only. Unauthorized distribution is strictly prohibited.

Table 4 Performance of cystic fluid EUS-FNA and EUS-FNA plus a *KRAS* assay to diagnose malignant intraductal papillary mucinous neoplasia of the pancreas (IPMN) in two subgroups of patients with and without resection of IPMN and pre-therapeutic clinical and/or radiologic predictors of malignancy.

	Sensitivity (95% CI)	Specificity (95% CI)	PPV (95% CI)	NPV (95% CI)	Accuracy (95% CI)
<i>Resected IPMN</i> (n = 18)					
EUS-FNA	61 (31–86)	100 (47–100)	100 (63–100)	50 (18–81)	72 (48–91)
EUS-FNA + <i>KRAS</i>	91 (61–99)	33 (4–77)	73 (44–92)	66 (9–99)	72 (43–99)
<i>Non-resected IPMN</i> (n = 19)					
EUS-FNA	50 (23–76)	100 (47–100)	100 (59–100)	42 (15–72)	63 (45–87)
EUS-FNA + <i>KRAS</i>	78 (49–95)	80 (28–99)	92 (61–99)	57 (18–90)	79 (52–99)

PPV: positive predictive value; NPV: negative predictive value; EUS-FNA: endoscopic ultrasound-fine-needle guided aspiration. There is no statistical difference in term of sensitivity and specificity between the two groups (resected versus non-resected –0.65 < P < 0.73, Fischer's exact test) except for the specificity of EUS-FNA + *KRAS* that was statistically lower in the resected group (P = 0.002).

From a clinical point of view, allelic discrimination assays for *KRAS* mutations are currently performed on somatic genetic tumors in colon cancer specimens, thus this approach now can be readily transferred into routine clinical practice for pre-therapeutic evaluation of IPMN in EUS-FNA material (and recently Next Generation Sequencing). When treating patients with high-risk of stigmata, EUS-FNA associated with a *KRAS* mutation assay could be useful when making therapeutic decisions [30]. From our results, in cases of high-grade dysplasia, combining cytopathology and/or *KRAS*-mutation assessment enabled prediction of malignancy in 80% of cases. Recent studies have underscored the importance of combining both clinical and radiologic findings to assessment of hotspots mutations of pancreatic cyst fluid for detection of advanced neoplasia, especially IPMN [31, 32].

From a practical point of view, payment for additional molecular analysis can be an issue. In our study, only 9 of 37 patients (24%) had a normal or LGD cytology at EUS with mutated *KRAS* and a final diagnosis of invasive carcinoma arising in the IPMN. Therefore, we would suggest reserving *KRAS* mutation analysis for cases with normal or non-contributive or LGD cytopathology (keeping thus a minimum 500 microliters of cystic fluid to a possible subsequent molecular analysis).

In addition, following the international consensus for IPMPN, Crippa et al. recently reported some significant predictor signs of disease-specific survival after multivariate analysis. They were age > 70 years, presence of atypical or malignant cytology, jaundice, and main pancreatic duct size > 15 mm [2, 33]. These data are important from a clinical point of view and, in our series, 54% of patients (20 over 37) had at least 1 of these criteria. Besides the results of cytopathology after EUS-FNA, some of these criteria should be taken into account and finally *KRAS* mutation analysis also can be reserved for patients who meet longer survival criteria.

Conclusion

In conclusion, in patients with a pre-therapeutic likelihood of IPMN-associated malignancy, use of EUS-FNA to obtain cystic fluid was safe, and the TaqMan allelic discrimination assay for *KRAS* and *GNAS* mutations was feasible. Although testing for *GNAS* mutations did not substantially improve diagnosis IPMN malignancy, the *KRAS* mutation assay, when combined with cytopathology, increased performance of cytopathology alone, especially in sensitivity, NPV, accuracy, and as a predictor of malignancy in 80% of cases.

Competing interests: Financial support received from STIC Program Inca 2008, Inca PRK 2012 and gifts from A. C., M-H. C. and L. G.

Institutions

- ¹ Department of Gastroenterology and INSERM UMR 1037, CHU Toulouse Rangueil, University of Toulouse, Toulouse, France
- ² INSERM UMR 1037, University Institute of Cancer of Toulouse, University of Toulouse, Toulouse, France
- ³ Department of Pathology, University Institute of Cancer of Toulouse, University of Toulouse, Toulouse, France
- ⁴ Department of Pathology, Beaujon Hospital, University of Paris Diderot, Clichy, France
- ⁵ Department of Digestive Surgery, CHU Toulouse Rangueil, University of Toulouse, Toulouse, France
- ⁶ Department of Digestive Surgery, CHU Toulouse Purpan, University of Toulouse, Toulouse, France

References

- ¹ Tanaka M, Chari S, Adsay V et al. International consensus guidelines for management of intraductal papillary mucinous neoplasms and mucinous cystic neoplasms of the pancreas. *Pancreatol* 2006; 6: 17–32
- ² Tanaka M, Fernández-del Castillo C, Adsay V et al. International consensus guidelines 2012 for the management of IPMN and MCN of the pancreas. *Pancreatol* 2012; 12: 183–197
- ³ Nagai K, Doi R, Kida A et al. Intraductal papillary mucinous neoplasms of the pancreas: clinicopathologic characteristics and long-term follow-up after resection. *World J Surg* 2008; 32: 271–278
- ⁴ Sadakari Y, Ienaga J, Kobayashi K et al. Cyst size indicates malignant transformation in branch duct intraductal papillary mucinous neoplasm of the pancreas without mural nodules. *Pancreas* 2010; 39: 232–236
- ⁵ Kanno A, Satoh K, Hirota M et al. Prediction of invasive carcinoma in branch type intraductal papillary mucinous neoplasms of the pancreas. *J Gastroenterol* 2010; 45: 952–959
- ⁶ Hwang DW, Jang JY, Lee SE et al. Clinicopathologic analysis of surgically proven intraductal papillary mucinous neoplasms of the pancreas in SNUH: a 15-year experience at a single academic institution. *Langenbecks Arch Surg* 2012; 397: 93–102
- ⁷ Mimura T, Masuda A, Matsumoto I et al. Predictors of malignant intraductal papillary mucinous neoplasm of the pancreas. *J Clin Gastroenterol* 2010; 44: e224–229
- ⁸ Arlix A, Bournet B, Otal P et al. Long-term clinical and imaging follow-up of nonoperated branch duct form of intraductal papillary mucinous neoplasms of the pancreas. *Pancreas* 2012; 41: 295–301
- ⁹ Anand N, Sampath K, Wu BU. Cyst features and risk of malignancy in intraductal papillary mucinous neoplasms of the pancreas: a meta-analysis. *Clin Gastroenterol Hepatol* 2013; 11: 913–921
- ¹⁰ Sugiyama M, Izumisato Y, Abe N et al. Predictive factors for malignancy in intraductal papillary-mucinous tumours of the pancreas. *Br J Surg* 2003; 90: 1244–1249
- ¹¹ Bournet B, Kirzin S, Carrère N et al. Clinical fate of branch duct and mixed forms of intraductal papillary mucinous neoplasia of the pancreas. *J Gastroenterol Hepatol* 2009; 24: 1211–1217
- ¹² Daudé M, Muscari F, Buscail C et al. Outcomes of nonresected main-duct intraductal papillary mucinous neoplasms of the pancreas. *World J Gastroenterol* 2015; 21: 2658–2667

- 13 *Salvia R, Fernández-del Castillo C, Bassi C et al.* Main-duct intraductal papillary mucinous neoplasms of the pancreas: clinical predictors of malignancy and long-term survival following resection. *Ann Surg* 2004; 239: 678–685
- 14 *Ogura T, Masuda D, Kurisu Y et al.* Potential predictors of disease progression for main-duct intraductal papillary mucinous neoplasms of the pancreas. *J Gastroenterol Hepatol* 2013; 28: 1782–1786
- 15 *Wang H, Chen T, Wang H et al.* A systematic review of the Physiological and Operative Severity Score for the enUmeration of Mortality and morbidity and its Portsmouth modification as predictors of post-operative morbidity and mortality in patients undergoing pancreatic surgery. *Am J Surg* 2013; 205: 466–472
- 16 *Rockacy M, Khalid A.* Update on pancreatic cyst fluid analysis. *Ann Gastroenterol* 2013; 26: 122–127
- 17 *Suzuki R, Thosani N, Annangi S et al.* Diagnostic yield of EUS-FNA-based cytology distinguishing malignant and benign IPMNs: a systematic review and meta-analysis. *Pancreatology* 2014; 14: 380–384
- 18 *Maker AV, Carrara S, Jamieson NB et al.* Cyst fluid biomarkers for intraductal papillary mucinous neoplasms of the pancreas: a critical review from the international expert meeting on pancreatic branch-duct-intraductal papillary mucinous neoplasms. *J Am Coll Surg* 2015; 220: 243–253
- 19 *Nissim S, Idos GE, Wu B.* Genetic markers of malignant transformation in intraductal papillary mucinous neoplasm of the pancreas: a meta-analysis. *Pancreas* 2012; 41: 1195–1205
- 20 *Distler M, Aust D, Weitz J et al.* Precursor lesions for sporadic pancreatic cancer: PanIN, IPMN, and MCN. *Biomed Res Int* 2014; 2014: 474905
- 21 *Kanda M, Knight S, Topazian M et al.* Mutant GNAS detected in duodenal collections of secretin-stimulated pancreatic juice indicates the presence or emergence of pancreatic cysts. *Gut* 2013; 62: 1024–1033
- 22 *Tan MC, Basturk O, Brannon AR et al.* GNAS and KRAS mutations define separate progression pathways in intraductal papillary mucinous neoplasm-associated carcinoma. *J Am Coll Surg* 2015; 220: 845–854
- 23 *Hosoda W, Sasaki E, Murakami Y et al.* GNAS mutation is a frequent event in pancreatic intraductal papillary mucinous neoplasms and associated adenocarcinomas. *Virchows Arch* 2015; 466: 665–674
- 24 *Singhi AD, Nikiforova MN, Fasanella KE et al.* Preoperative GNAS and KRAS testing in the diagnosis of pancreatic mucinous cysts. *Clin Cancer Res* 2014; 20: 4381–4389
- 25 *Amato E, Molin MD, Mafficini A et al.* Targeted next-generation sequencing of cancer genes dissects the molecular profiles of intraductal papillary neoplasms of the pancreas. *J Pathol* 2014; 233: 217–227
- 26 *Bournet B, Souque A, Senesse P et al.* Endoscopic ultrasound-guided fine-needle aspiration biopsy coupled with KRAS mutation assay to distinguish pancreatic cancer from pseudotumoral chronic pancreatitis. *Endoscopy* 2009; 41: 552–557
- 27 *Bournet B, Selves J, Grand D et al.* Endoscopic ultrasound-guided fine-needle aspiration biopsy coupled with a KRAS mutation assay using allelic discrimination improves the diagnosis of pancreatic cancer. *J Clin Gastroenterol* 2015; 49: 50–56
- 28 *Komatsu H, Tanji E, Sakata N et al.* A GNAS mutation found in pancreatic intraductal papillary mucinous neoplasms induces drastic alterations of gene expression profiles with upregulation of mucin genes. *PLoS One* 2014; 9: e87875
- 29 *Ideno N, Ohtsuka T, Matsunaga T et al.* Clinical significance of GNAS mutation in intraductal papillary mucinous neoplasm of the pancreas with concomitant pancreatic ductal adenocarcinoma. *Pancreas* 2015; 44: 311–320
- 30 *Aso T, Ohtsuka T, Matsunaga T et al.* "High-risk stigmata" of the 2012 international consensus guidelines correlate with the malignant grade of branch duct intraductal papillary mucinous neoplasms of the pancreas. *Pancreas* 2014; 43: 1239–1243
- 31 *Springer S, Wang Y, Dal Molin M et al.* A combination of molecular markers and clinical features improve the classification of pancreatic cysts. *Gastroenterology* 2015; 149: 1501–1510
- 32 *Singhi AD, Zeh HJ, Brand RE et al.* American Gastroenterological Association guidelines are inaccurate in detecting pancreatic cysts with advanced neoplasia: a clinicopathologic study of 225 patients with supporting molecular data. *Gastrointest Endosc* 2016; 83: 1107–1117
- 33 *Crippa S, Bassi C, Salvia R et al.* Low progression of intraductal papillary mucinous neoplasms with worrisome features and high-risk stigmata undergoing non-operative management: a mid-term follow-up analysis. *Gut* 2016; pii: DOI 10.1136/gutjnl-2015-310162