


CASE REPORT

A brother and sister with the same karyotype: Case report of two siblings with partial 3p duplication and partial 9p deletion and sex reversal

Susan Cordes Selby¹ | Aiko Iwata-Otsubo² | Paula Delk² | Todd D. Nebesio³ | Anisha Gohil³ | Peggy Matlock² | Wilfredo Torres-Martinez² | Gail H. Vance² 

¹Community Health Network, Maternal-Fetal Medicine, Indianapolis, IN, USA

²Department of Medical and Molecular Genetics, Indiana University School of Medicine, Indianapolis, IN, USA

³Division of Pediatric Endocrinology/Diabetology, Department of Pediatrics, Indiana University School of Medicine, Indianapolis, IN, USA

Correspondence

Gail H. Vance, Department of Medical and Molecular Genetics, Indiana University School of Medicine, 975 W Walnut Street IB-350, Indianapolis, IN, USA.
Email: ghvance@iu.edu

Funding information

The publication of this manuscript is supported by funds from Dr Vance's Sutphin Professorship

Abstract

Two siblings with the same male unbalanced karyotype demonstrate sex reversal. The older sib appeared phenotypically female and the younger sib demonstrated a male gender. The female had gonadal dysgenesis with bilateral ovotestes. The male had bilateral testes. The report discusses the phenotypical differences and genes associated with sex reversal.

KEYWORDS

3p duplication, 9p deletion, disorders of sex development, *DMRT1*

1 | INTRODUCTION

Duplications of 3p and deletions of 9p occurring separately are well described; however, there are few reports of individuals with unbalanced translocations resulting in both of these chromosomal abnormalities together. Here, we report two siblings with the same unbalanced male karyotype, with a duplication of distal 3p and a deletion of distal 9p, due to adjacent segregation of a balanced reciprocal translocation inherited from their father. Although the siblings have the same karyotype of 46,XY,der(9)t(3;9)(p25.1;p24.3)pat, they demonstrate different phenotypes, particularly in sex development. This sibling pair further delineates cases with unbalanced translocations and disorders of sex development.

There have been few patients reported with both partial duplication of 3p and partial deletion of 9p due to an unbalanced translocation with variable breakpoints (Figure S1).¹⁻³ Two prior reports of individuals with similar unbalanced translocations to the patients in this report, suggested that the clinical features overlap with those of individuals with isolated 3p duplications and 9p deletions; however, they are generally milder than expected for the degree of imbalance.^{4,5}

Patients with 3p duplications have variable clinical features that include intellectual disability, hypotonia, short stature, heart defects, and facial features such as brachycephaly, microcephaly, square face, hypertelorism, wide and depressed nasal bridge, short nose, full cheeks, and cleft lip with and without cleft palate.⁶⁻⁸

This is an open access article under the terms of the Creative Commons Attribution-NonCommercial License, which permits use, distribution and reproduction in any medium, provided the original work is properly cited and is not used for commercial purposes.

© 2021 The Authors. *Clinical Case Reports* published by John Wiley & Sons Ltd.

Clinical features of the 9p deletion syndrome, (OMIM #158170), include developmental and psychomotor delay, hypotonia, widely spaced nipples, and dysmorphic facial features, such as midface hypoplasia, short palpebral fissures, hypertelorism, depressed nasal bridge, and micrognathia.⁹⁻¹² A significant number of patients with a distal 9p deletion with a male karyotype exhibit disorders of sex development (DSD).^{2,13}

Here, we report a brother and sister with the same male karyotype with an unbalanced translocation resulting in partial duplication of 3p and deletion of distal 9p. Both patients' clinical features include those seen in 3p duplication and 9p deletion, including abnormal sex development.

2 | CLINICAL REPORTS

2.1 | Patient 1

Patient 1 was born at 38 weeks gestation by repeat Cesarean section to a 33-year-old G2P1001 mother. Prenatal ultrasound detected a Dandy-Walker malformation, confirmed after birth with brain MRI. There were no other prenatally detected abnormalities. The remainder of the pregnancy was unremarkable. The family history was remarkable for a sister (patient 2) with an atrial septal defect (ASD) and clubfeet. The remainder of the family history was negative for birth defects, intellectual disability, and recurrent miscarriages. The mother and father are second cousins (their mothers are first cousins).

The patient's birth weight was 3.78 kg (69th percentile), length was 54.0 cm (93rd percentile), and Apgar scores were 8 and 9 at 1 and 5 minutes, respectively. He had neonatal hypoglycemia, which resolved spontaneously within the first day of life, and feeding difficulties, which resolved by 6 months of age. A patent foramen ovale was identified.

At birth, the patient had ambiguous genitalia with a bifid scrotum. Specifically, he had a penoscrotal transposition with buried penis and prominent suprapubic fat pad. He also had ventral chordee, left-sided hydrocele, and a left inguinal hernia. The patient had a low luteinizing hormone (LH) and lower limits of normal follicle-stimulating hormone (FSH) in the newborn period. Testosterone and dihydrotestosterone levels were normal for age, but anti-Müllerian hormone was low for newborn males, suggesting normal Leydig cell function but abnormal Sertoli cell function. A renal ultrasound showed normal-appearing kidneys bilaterally with no evidence of hydronephrosis. At 7 months of age, the patient had a penoplasty, scrotoplasty, and repair of the left inguinal hernia and hydrocele.

The patient had both developmental and speech delays. He sat alone at approximately 5 months, crawled at 11 months, and was not walking independently at

16 months of age. Growth parameters at 16 months of age were 11.4 kg (53rd percentile) for weight, 78.6 cm (29th percentile) for length, and an OFC of 49 cm (87th percentile). Mildly dysmorphic features observed included short palpebral fissures with hypertelorism, cupped ears with overfolded helices, short nose, a smooth philtrum, full cheeks, and micrognathia. (Figure 1A). Other features noted were displaced nipples, tapered fingers, edema of the feet, and loose skin.

At age 9 years, he underwent an adenoidectomy and turbinate cauterization due to concerns for apnea. His growth parameters for height, weight, and head circumference were at the 75th-90th percentile. He had moderate expressive and receptive language delays and received speech intervention, occupational, music, physical, and recreational therapies. He was diagnosed with ADHD and is homeschooled, working at a 3rd grade level. At age 10 years 11 months, he is prepubescent. A testicular ultrasound revealed healthy appearing bilateral testes located within the scrotum without mass or concerning features. His gender identity remains male.

G-banded chromosome analysis, performed at birth, identified additional unknown material on 9p. Parental blood studies demonstrated that the patient's father had a balanced reciprocal translocation between 3p and 9p written as 46,XY,t(3;9)(p25.1;p24.3). Based on paternal results, the patient's karyotype was revised to 46,XY,der(9)t(3;9)(p25.1;p24.3)pat, resulting in partial 3p duplication and partial 9p deletion (Figure 1D).

Chromosomal microarray analysis (CMA) identified a duplication at 3p26.3p25.1, approximately 13.5 Mb in size involving 55 OMIM genes (chr3:61,891-13,562,132, hg19 coordinates) and a deletion at 9p24.3, approximately 1.17 Mb in size involving 5 OMIM genes (chr9:203,861-1,373,611, hg19 coordinates). Also identified were segments of copy-neutral absence of heterozygosity (AOH) across multiple chromosomes encompassing around 2.2% of the genome (Figure S2).

2.2 | Patient 2

Patient 2 (older sister to patient 1 by 2 years, Figure 1B) was born at term by Cesarean section due to large size posterior positioning, and failure to progress. The pregnancy was without complications. Birth weight was 3.94 kg (87th percentile) and birth length was 48.9 cm (43rd percentile). Hypoglycemia developed shortly after birth, which resolved spontaneously. She had bilateral talipes equinovarus and a moderate-sized ASD noted by echocardiogram.

A chromosome study of Patient 2 demonstrated the same karyotype as her brother, 46,XY,der(9)t(3;9)(p25.1;p24.3)pat. However, she had normal-appearing female external

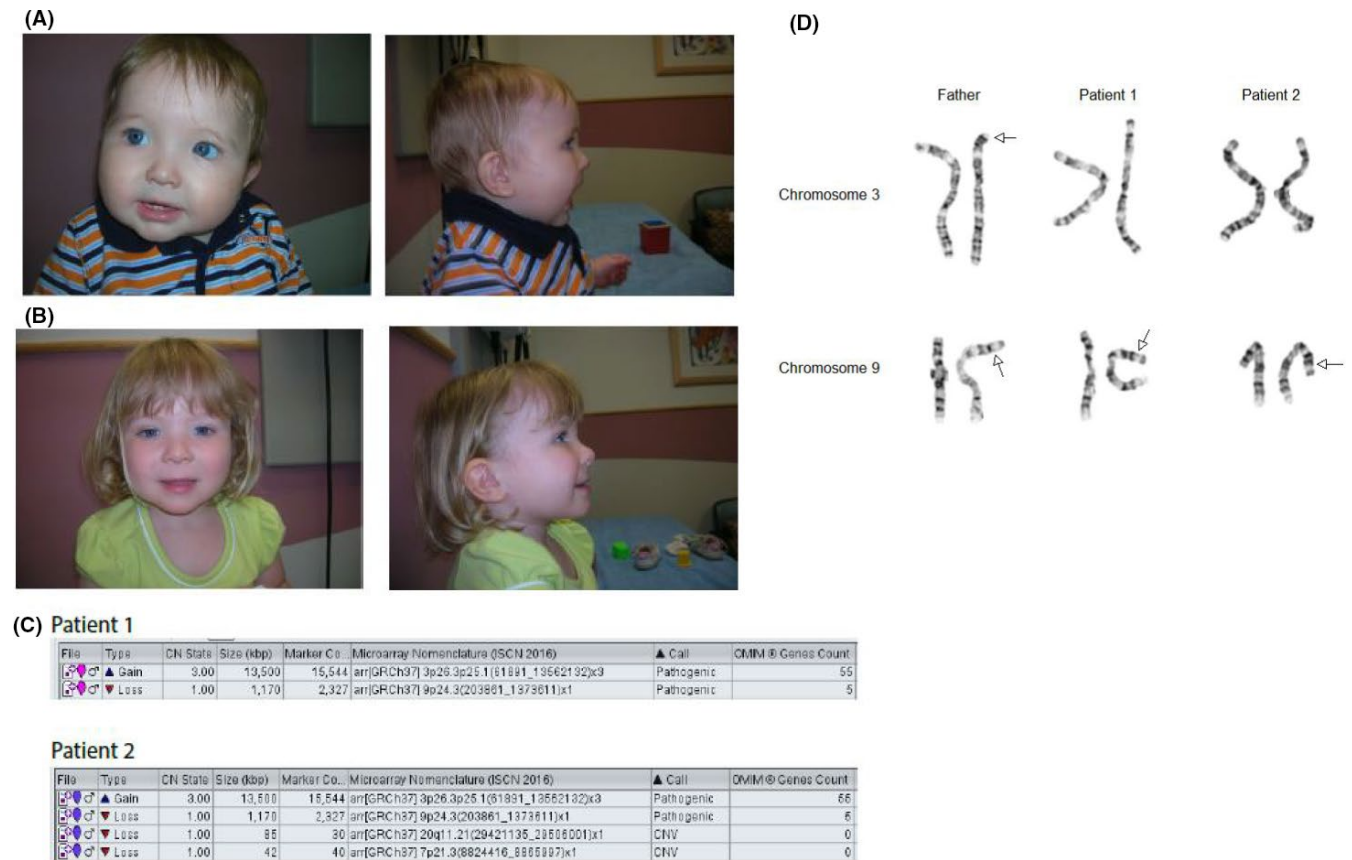


FIGURE 1 Pictures, chromosomes, and CMA results of the two patients and their father. A, Frontal and lateral views of the patient 1 at the age of 9 mo showing a square face, hypertelorism, short palpebral fissures, short nose, full cheeks, cupped ears, smooth philtrum, and micrognathia. B, Frontal and lateral views of the patient 2 at the age of 2 y 10 mo showing hypertelorism, epicanthal folds, smooth philtrum, and depressed nasal bridge. C, CMA results of patient 1 and patient 2. Both patients have the same deletion on chromosome 9p and duplication on chromosome 3p. Patient 2 has additional 85 kb- and 42 kb-deletions with no genes present in these regions. These CNVs are considered insignificant. D, Chromosomes 3 and 9 from the father, patient 1 and patient 2. Arrows on chromosomes 3 and 9 indicate the translocated segments. Arrows for each of the chromosomes 9 for patient 1 and 2 indicate the duplication of 3p on the short arm of chromosome 9

genitalia. A renal ultrasound was normal, and a pelvic ultrasound initially appeared normal with both ovaries and a uterus present. Gonadotropins measured at 2 years 8 months demonstrated her LH was normal but FSH was markedly elevated, suggesting gonadal dysgenesis and primary ovarian dysfunction. Laparoscopy showed a normal uterus and Fallopian tubes. The ovaries appeared normal except for a right cystic structure. The patient had a bilateral gonadectomy. Pathology reports of the left gonad revealed a streak testis containing a gonadoblastoma while the right gonad was an ovotestis.

The patient had developmental delays, especially with gross motor and language skills. She walked at 20 months and said her first words at 18 months. At 3 years 2 months, her vocabulary consisted of reportedly more than 100 single words and she was able to use two-word phrases.

The patient's growth parameters at 3 years 5 months of age were 15.4 kg (64th centile) for weight, 98 cm (56th centile) for height, and she had an OFC of 51.2 cm (80th centile). At age 11 years, her growth parameters were at

75th-90th percentiles for height, weight, and head circumference. Dysmorphic features included brachycephaly, broad forehead, short nasal bridge, and hypoplastic alar nasi. Percutaneous closure of her ASD was performed, and she has remained asymptomatic. On endocrine evaluation at age 11 year 7 months, her breasts were at Tanner stage I and pubic hair was Tanner stage III. She began treatment for hypergonadotropic hypogonadism with an estradiol patch at 12.5 mcg twice weekly. Her bone age was concordant with her chronological age of between 10 and 11 years. An exam at age 13 years 8 months, noted Tanner stage III breasts and Tanner stage IV pubic hair. She has not yet had menarche. Her gender identity remains female.

Developmentally, the patient was functioning with moderate cognitive delays and severe language delay. She was receiving speech, occupational, and recreational therapies. She has been homeschooled and is performing near the 4th grade level.

Similarly, a CMA showed a duplication at 3p26.3p25.1, approximately 13.46 Mb in size involving 55 OMIM genes

TABLE 1 Clinical features and karyotypes of our cases with duplication 3p and deletion 9p and those reported in the literature

	Patient 1	Patient2	Fryns et al 1986	Game et al 1990	McClure et al 1996
Karyotype	46,XY,der(9)t(3;9) (p25.1;p24.3)pat	46,XY,der(9)t(3;9) (p25.1;p24.3)pat	46,XY, der(9) t(3;9)(p21.3;p22) mat	46,XX, der(9) t(3;9)(p24;p22) mat	46,XX,der(9)t(3;9) (p25;p23)mat
Sex	Male	Female	Female	Female	Female
General					
Developmental delay/Intellectual disability	+	+		+	
Speech delay	+	+			
Motor delay	+	+			
Hypotonia	+(infantile)	+(infantile)		+	+
Short stature	-	-			
Brain					
Dandy-Walker malformation	+	-			
Facial characteristics					
Trigonocephaly	-	-			
Brachycephaly	+	+			
Midface hypoplasia					
Short palpebral fissures	+	-			
Epicanthal fold	-	+	+	+	+
High arched eyebrows					
Microcephaly					
Full cheeks	+	-	+	+	+
Hypertelorism	+	+	+	+	+
Square face	+	-		+	
Depressed nasal bridge	-	+	+	+	
Short nose	+	-			
Cupped ears	+	-			
Prominent philtrum					
Smooth philtrum	+	+			
Cleft lip ±palate	-	-	+		
Micrognathia	+	-	+		
Neck					
Short neck	-	-	+	+	
Thorax					
Wildly spaced nipples	+	+		+	
Cardiovascular					
Congenital heart defect	+	+			
Urogenital					
Genital abnormality	+	+	+	+	
Extremities					
Club feet	-	+			

^a12-wk fetus.

Ounap et al 2004	Witters et al 2004 ^a	Hauge et al 2008	Smeets et al 2001	Natera-de Benito et al 2014	Huret et al 1988
46,XX,der(9)t(3;9) (p23~24;p22.3 ~ 23)	46,XY, der(9)t(3;9) (p14.2;p24)mat	46,XX,der(9)t(3;9) (26.1;24.2)	46,XX.dup(3)(pter to p26::p22 to p26::p26 to qter)	Two isolated 3p duplication of segments 3p24-26 and one with 46,XY,der(7)t(3;7) (p24.1;p22)	Isolated 9p deletion with both male and female karyotypes
Female	Female	Female	Female		
+			+	3/3	36/36
+		+			
			+	2/2 1/3	12/22
+		+	+		32/32
					6/7 14/14
+					22/27 9/12
				2/3	
+				3/3	
+			+	2/3	
+			+		
			+	2/3	27/28
	+			1/3	
	+				26/30
				3/3	26/27
					31/31
	+	-		1/3	16/35
-	+				15/36

(chr3:61,891–13,562,132, hg19 coordinates) and a deletion at 9p24.3, approximately 1.17 Mb in size involving 5 OMIM genes (chr9:203,861–1,373,611, hg19 coordinates; Figure 1C). The microarray also identified segments of copy-neutral AOH across multiple chromosomes encompassing around 3.8% of the genome (Figure S2).

3 | MATERIALS AND METHODS

High-resolution chromosome analysis was performed on 20 metaphases on PHA-stimulated cultured lymphocytes using the standard GTG (G-banding using trypsin and Giemsa) banding protocol. CMA analysis was performed on genomic DNA extracted from peripheral blood using the Applied Biosystems CytoScan HD array platform (ThermoFisher Scientific, Carlsbad, CA) consisting of 1,953,246 unique nonpolymorphic copy number probes and 743,304 single nucleotide polymorphism probes spanning the whole genome. CytoScan array CEL files were processed and visualized with the Chromosome Analysis Suite (ChAS) 3.3 version software (ThermoFisher Scientific, Carlsbad, CA) The copy number variants (CNVs) were analyzed and reported using the NCBI human genome build 37.1 (GRCh37/hg19).

4 | DISCUSSION

In this report, we present phenotypically male and female siblings each with the same male karyotype with partial 3p duplication and partial 9p deletion. Their clinical features overlap those associated with 3p duplication and 9p deletion (Table 1). The duplicated 3p and deleted 9p regions are smaller in our patients compared to the common sizes associated with patients reported in the literature, which could account for the milder phenotype in our patients.

The 9p deletion syndrome is associated with DSD. Patients with a distal 9p deletion and a male karyotype, show a wide spectrum of abnormal sex development ranging from females with complete gonadal dysgenesis to males with hypospadias. The critical region for complete gonadal dysgenesis has been localized to the 9p24.3, extending from the *DMRT* genes to the telomere.^{13–15} This region is separate from the 9p deletion syndrome critical region (9p22.3–9p23).^{15,16} The *DMRT* genes (*DMRT1*, *DMRT2*, and *DMRT3*) located at 9p24.3 are considered as gene candidates for gonadal dysgenesis.¹⁷ These genes encode for proteins with a DM (doublesex/MAB-3) domain, a zinc-finger-like DNA binding, and are involved in downstream pathways of sex determination.¹³ In mice, *Dmrt1* is expressed in both germ cells and Sertoli cells of the testis, and has been shown to be essential to maintain

testis determination.¹⁸ Recent studies in humans support that haploinsufficiency of *DMRT1*, associated with 9p deletions, is the most likely explanation of DSD. Macdonald et al¹⁹ used a novel approach to repress *DMRT1* in the tissue of human fetal testes and showed *DMRT1* repression induces testicular dysgenesis. Furthermore, a recent exome study identified a missense mutation in *DMRT1* in a patient with XY sex reversal²⁰ further supporting that *DMRT1* is a candidate gene for XY sex reversal.

It has been shown that haploinsufficiency for *DMRT1* results in gonadal dysgenesis and DSD with variable penetrance and expressivity.²¹ A review of 88 cases of monosomy 9p with a male karyotype revealed that ~80% (72/88) had genital abnormalities and/or complete gonadal dysgenesis, while ~20% of them had no genital abnormalities. The underlying mechanism of this variability has been unclear. Since a large percentage of 46,XY patients with 9p deletions that had DSD harbored a secondary copy number variation (CNV), the authors hypothesized that abnormal sex development may be due to the presence of a second hit (CNV or other molecular mechanism) in addition to *DMRT1* haploinsufficiency. In our study, we did not detect significant CNVs however, regions of AOH were detected with the regions of AOH in patient 2 being larger (3.78% of the entire genome including 62 Mb AOH on chromosome 7) than in patient 1 (2.22% of the entire genome; Figure S2). It may be possible that a homozygous state of a gene or genes in the AOH regions in patient 2 served as a second hit, accounting for her sex reversal phenotype. Alternatively, it may be possible that additional small CNVs or other genetic changes undetectable by CMA account for the difference in sex development between the two patients.

In conclusion, the two patients reported here add to the study of individuals with partial 3p duplication and 9p deletion. Of reported cases, only two have had 46,XY and sex reversal.^{1,3} Our two patients are also of interest as they are a brother and sister with the same genotype defined by karyotype and CMA, but their phenotypes, specifically in regards to sex development and gender identity, are different.

ACKNOWLEDGMENTS

We thank the family for their cooperation with this study.

CONFLICT OF INTEREST

All authors disclose no conflict of interest in contributing to this manuscript.

AUTHOR CONTRIBUTIONS

SCS, PD, TDN, AG, WTM: involved in clinical evaluation. AIO, PM, GHV: involved in data analysis. SCS, AIO and GHV: prepared the manuscript. All authors reviewed and contributed to the drafts and approved the final manuscript.

ETHICAL APPROVAL

This study conforms to recognized standards outlined in the Declaration of Helsinki.

DATA AVAILABILITY STATEMENT

The data that support the findings of this study are available from the corresponding author upon reasonable request.

ORCID

Gail H. Vance  <https://orcid.org/0000-0002-7424-2921>

REFERENCES

- Fryns JP, Kleczkowska A, Casaer P, Van Den Berghe H. Double autosomal chromosomal aberration (3p trisomy/9p monosomy) and sex reversal. *Ann Genet.* 1986;29(1):49-52.
- Önup K, Uibo O, Zordania R, et al. Three patients with 9p deletions including DMRT1 and DMRT2: A girl with XY complement, bilateral ovotestes, and extreme growth retardation, and two XX females with normal pubertal development. *Am J Med Genet Part A.* 2004;130A(4):415-423.
- Witters I, Vermeesch JR, Moerman PH, Fryns JP. Partial trisomy 3p/monosomy 9p with sex reversal. *Ultrasound Obstet Gynecol.* 2004;23(4):418-419.
- Game K, Friedman JM, Kalousek DK. Mild phenotypic abnormalities in combined del 9p2 and dup 3p2. *Am J Med Genet Part A.* 1990;35(3):370-372.
- McClure RJ, Telford N, Newell SJ. A mild phenotype associated with der(9)t(3;9) (p25;p23). *J Med Genet.* 1996;33(7):625-627.
- Bittel DC, Kibiryeve N, Dasouki M, Knoll JHM, Butler MG. A 9-year-old male with a duplication of chromosome 3p25.3p26.2: Clinical report and gene expression analysis. *Am J Med Genet Part A.* 2006;140A(6):573-579.
- Natera-de Benito D, García-Pérez MA, Martínez-Granero MÁ, Izquierdo-López L. A patient with a duplication of chromosome 3p (p24.1p26.2): a comparison with other partial 3p trisomies. *Am J Med Genet Part A.* 2014;164A(2):548-550.
- Smeets E, Vandenbossche L, Fryns JP. Partial distal trisomy 3p. A partial autosomal trisomy without major dysmorphic features. *Genet Couns.* 2001;12(1):85-89.
- Alfi O, Donnell GN, Crandall BF, Derencsenyi A, Menon R. Deletion of the short arm of chromosome # 9 (46,9p-). A new deletion syndrome. *Ann Genet.* 1973;16(1):17-22.
- Hauge X, Raca G, Cooper S, et al. Detailed characterization of, and clinical correlations in, 10 patients with distal deletions of chromosome 9p. *Genet Med.* 2008;10(8):599-611.
- Huret JL, Leonard C, Forestier B, Rethore MO, Lejeune J. Eleven new cases of del(9p) and features from 80 cases. *J Med Genet.* 1988;25(11):741-749.
- Swinkels MEM, Simons A, Smeets DF, et al. Clinical and cytogenetic characterization of 13 Dutch patients with deletion 9p syndrome: delineation of the critical region for a consensus phenotype. *Am J Med Genet Part A.* 2008;146A(11):1430-1438.
- Barbaro M, Balsamo A, Anderlid BM, et al. Characterization of deletions at 9p affecting the candidate regions for sex reversal and deletion 9p syndrome by MLPA Sweden. *Eur J Hum Genet.* 2009;17(11):1439-1447.
- Guioli S, Schmitt K, Critcher R, et al. Molecular analysis of 9p deletions associated with XY sex reversal: refining the localization of a sex-determining gene to the tip of the chromosome. *Am J Hum Genet.* 1998;63(3):905-908.
- Veitia R, Nunes M, Brauner R, et al. Deletions of distal 9p associated with 46, XY male to female sex reversal: definition of the breakpoints at 9p23.3-p24.1. *Genomics.* 1997;41(2):271-274.
- Flejter WL, Fergestad J, Gorski J, Varvill T, Chandrasekharappa S. A gene involved in XY sex reversal is located on chromosome 9, distal to marker D9S1779. *Am J Hum Genet.* 1998;63(3):794-802.
- Muroya K, Okuyama T, Goishi K, et al. Sex-determining gene(s) on distal 9p: clinical and molecular studies in six cases¹. *J Clin Endocrinol Metab.* 2000;85:3094-3100.
- Raymond CS. Dmrt1, a gene related to worm and fly sexual regulators, is required for mammalian testis differentiation. *Genes Dev.* 2000;14:2587-2595.
- Macdonald J, Kilcoyne KR, Sharpe RM, et al. DMRT1 repression using a novel approach to genetic manipulation induces testicular dysgenesis in human fetal gonads. *Hum Reprod.* 2018;33(11):2107-2121.
- Murphy MW, Lee JK, Rojo S, et al. An ancient protein-DNA interaction underlying metazoan sex determination. *Nat Struct Mol Biol.* 2015;22:442-451.
- Quinonez SC, Park JM, Rabah R, et al. 9p partial monosomy and disorders of sex development: Review and postulation of a pathogenetic mechanism. *Am J Med Genet Part A.* 2013;161A(8):1882-1896.

SUPPORTING INFORMATION

Additional supporting information may be found online in the Supporting Information section.

How to cite this article: Cordes Selby S, Iwata-Otsubo A, Delk P, et al. A brother and sister with the same karyotype: Case report of two siblings with partial 3p duplication and partial 9p deletion and sex reversal. *Clin Case Rep.* 2021;9:e04141. <https://doi.org/10.1002/ccr3.4141>