



**CASE REPORT**

# High-resolution 3D mapping of epicardial conduction during Marshall bundle-related atrial tachycardia

Rintaro Hojo MD  | Seiji Fukamizu MD, PhD | Satoshi Miyazawa MD |  
Iwanari Kawamura MD 

Department of Cardiology, Tokyo  
Metropolitan Hiroo Hospital, Tokyo, Japan

**Correspondence**

Rintaro Hojo, Department of Cardiology,  
Tokyo Metropolitan Hiroo Hospital, Shibuya-  
ku, Tokyo, Japan.  
Email: rinrintaro1979@hotmail.co.jp

**Abstract**

A 73-year-old woman was admitted for atrial tachycardia (AT) ablation. The activation map and pacing study indicated that the AT propagated around the left pulmonary vein and that the Marshall bundle (MB) bypassed the scar area of the left pulmonary vein ridge and mitral isthmus. The Rhythmia Mapping System revealed double potentials propagated along the assumed position of the MB. The mapping system includes a confidence mask that can be used to visually identify low-confidence areas of the map based upon extremely low-voltage signals. Given the low-voltage area in the endocardial side, the epicardial conduction was emphasized.

**KEYWORDS**

atrial fibrillation, atrial tachycardia, epicardium, high-resolution mapping, Marshall bundle

## 1 | INTRODUCTION

Atrial tachycardia (AT) with an epicardial connection involving the Marshall bundle (MB) has been previously reported.<sup>1,2</sup> We present a case in which the epicardial conduction using the MB was observed using a high-resolution 3D mapping system.

## 2 | CASE REPORT

A 73-year-old woman with a history of mitral valve plasty and multiple catheter ablations was admitted for atrial tachycardia (AT) ablation. Previously, she underwent pulmonary vein isolation and linear ablation for the roof and anterior wall in the left atrium (LA). An electrophysiological study was performed after the patient had provided informed consent.

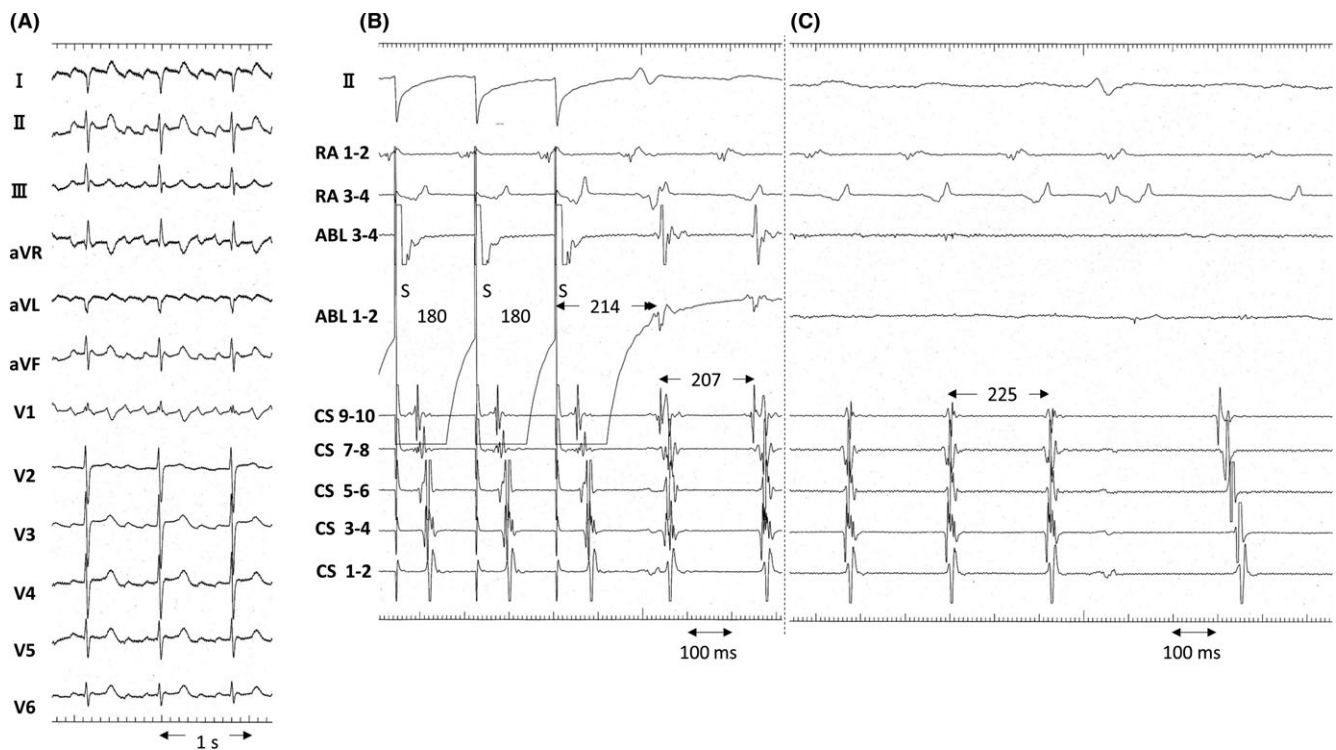
Activation mapping in the LA was performed with the Rhythmia Mapping System (Boston Scientific, Marlborough, MA, USA) during AT. After the ablation for the anterior line gap and fragmented

potential recorded at the left pulmonary vein ridge, the AT continued with a tachycardia cycle length of 204 ms (Figure 1A). The LA activation map revealed a centrifugal pattern at the lower lateral mitral isthmus (Figure 2). The activity propagated to the left atrial appendage along the mitral annulus and the roof side of the left atrial appendage surrounded by the LA anterior line and roof line was dead end. The coronary sinus venography was performed to detect and cannulate the vein of Marshall, but did not reveal the vein. The postpacing interval at the center of the centrifugal propagation site (Figure 1B) and the left posterior wall was equal to the tachycardia cycle length. Those at the mitral isthmus beneath the scar area and mitral annulus were longer by more than 50 ms. This indicated that the AT propagated around the left pulmonary vein in a counterclockwise manner and that the MB bypassed the scar area of the left pulmonary vein ridge and mitral isthmus.

The confidence mask threshold was <0.03 mV; the tiny potentials propagated to the centrifugal site along the assumed position of the MB (Figure 2B-D and Video S1) in the scar area. The local activation time from the top of the left pulmonary vein ridge to the

This is an open access article under the terms of the Creative Commons Attribution-NonCommercial License, which permits use, distribution and reproduction in any medium, provided the original work is properly cited and is not used for commercial purposes.

© 2018 The Authors. *Journal of Arrhythmia* published by John Wiley & Sons Australia, Ltd on behalf of the Japanese Heart Rhythm Society.



**FIGURE 1** A, Twelve-lead electrocardiogram of the AT. B, The intracardiac electrocardiogram of the entrainment pacing at the focal activation site showed that the postpacing interval was almost equal to the tachycardia cycle length. C, The AT was terminated by catheter ablation (Figure 2 red tag) with tachycardia cycle length prolongation

centrifugal activation site required 52% of the tachycardia cycle length (106 ms/204 ms). According to the activation map, the preceding potentials (white arrow heads) were suspected of being the far-field potential of the MB, while the following potentials (red arrow heads) were endocardial potentials. At sites B and C, the epicardial potentials were larger than the endocardial potentials; thus, the epicardial potential was detected as local activation timing. Conversely, the endocardial potential was detected as the local activation timing at site D.

We performed radiofrequency ablation on the opposite side of the MB from the left atrial appendage side (Figure 2, red tag), which terminated the AT (Figure 1C). The MB conduction block was confirmed using activation mapping and AT was no longer induced by programmed stimulations.

### 3 | DISCUSSION

In this case, the AT did not have epicardial data, but had the following characteristics, which indicated epicardial conduction through the MB: (i) focal activation pattern at the assumed position of the MB, (ii) the local activation time did not fulfill a tachycardia cycle length, and (iii) the postpacing interval was equal to the tachycardia cycle length and the AT was terminated by catheter ablation far from the centrifugal activation site.

This AT propagated in a reverse manner compared to the AT reported by Yamamoto et al.<sup>2</sup> The high-resolution 3D mapping

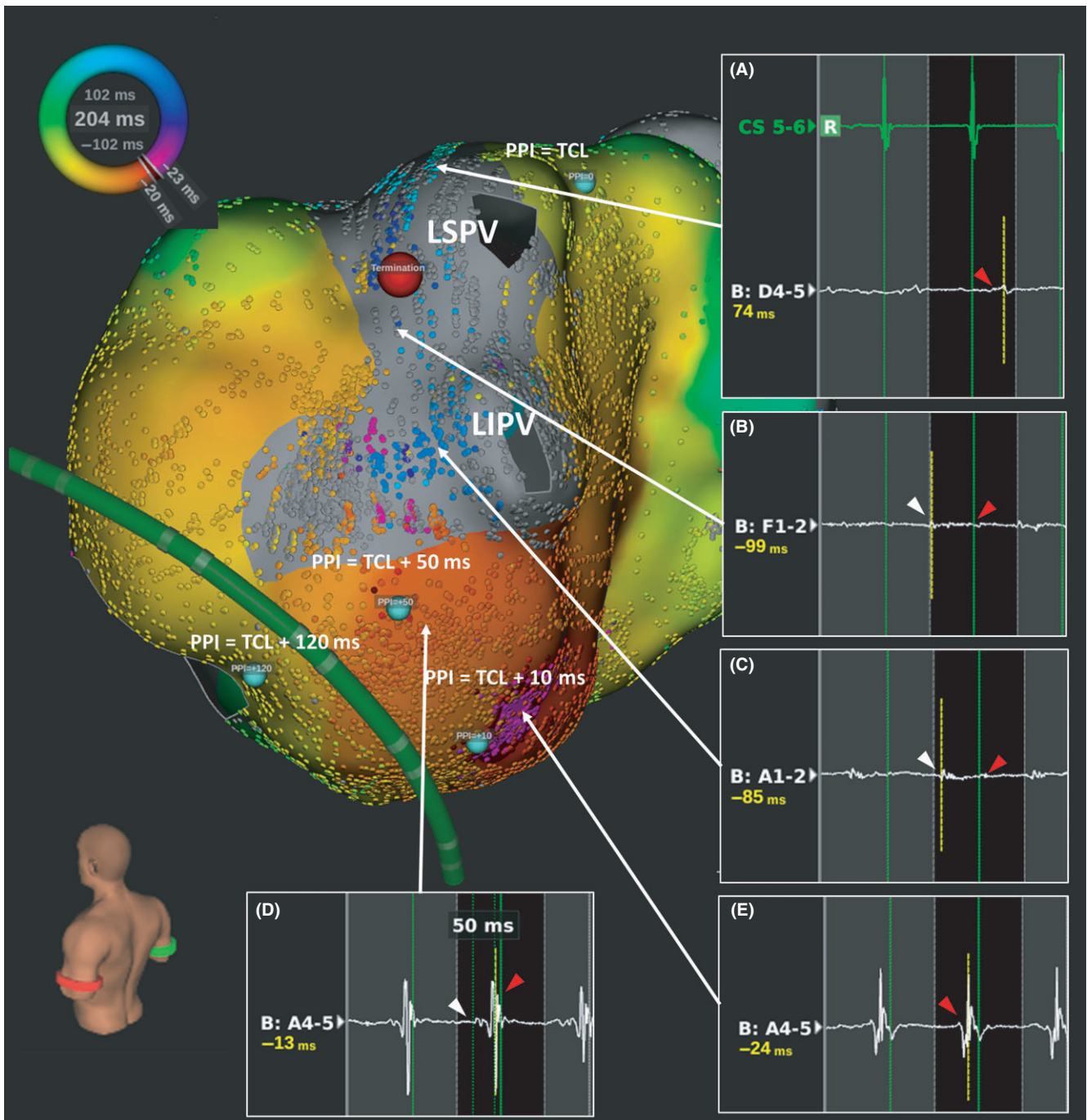
precisely revealed the connection of the MB and LA as a centrifugal activation pattern.

The most important aspect of this case was that the epicardial conduction through the MB was observed in the scar area (Video S1). The Rhythmia Mapping System includes a confidence mask that can be used to visually gray out areas of the map in which the system has a low confidence in its signal annotation because of extremely low voltage, a locally large variation in annotation times, or a mixture of both. It is important to note that there is a potential even in the part displayed in gray in this system. As a scar area was created by a previous ablation in the endocardial side, the epicardial conduction via the MB was more prominent in the Rhythmia Mapping System.

This case had no electrogram or anatomical information of the MB, which is a limitation. However, the patients without vein of Marshall are not able to undergo chemical ablation, so they undergo catheter ablation from endocardial side. The tiny potentials in the scar might be helpful to locate and ablate the MB. Physicians should know these characteristics of this mapping system and titrate the confidence mask threshold to reveal these potentials.

### 4 | CONCLUSIONS

The epicardial conduction through the MB was detected as tiny potentials in the scar area in this case. An electrophysiologist should pay attention to the potentials in the part displayed in gray in the Rhythmia Mapping System.



**FIGURE 2** A-D, According to the activation map, the preceding potentials (white arrow heads) were suspected of being the far-field potential of the Marshall bundle, while the following potentials (red arrow heads) were endocardial potentials. E: At the centrifugal activation site, the postpacing was similar to the tachycardia cycle length. PPI = postpacing interval; TCL = tachycardia cycle length; LSPV = left superior pulmonary vein; LIPV = left inferior pulmonary vein

#### CONFLICT OF INTEREST

Authors declare no conflict of interests for this article.

#### ORCID

Rintaro Hojo  <http://orcid.org/0000-0001-6332-2355>

Iwanari Kawamura  <http://orcid.org/0000-0002-6431-9278>

#### REFERENCES

- Hayashi T, Fukamizu S, Mitsuhashi T, et al. Peri-mitral atrial tachycardia using the Marshall bundle epicardial connections. *JACC Clin Electrophysiol.* 2016;2:27–35.
- Yamamoto T, Maruyama M, Seino Y, Shimizu W. Marshall bundle reentry: a novel type of macroreentrant atrial tachycardia. *Heart Rhythm.* 2014;11:1229–32.

**SUPPORTING INFORMATION**

Additional supplemental material may be found online in the Supporting Information section at the end of the article.

**How to cite this article:** Hojo R, Fukamizu S, Miyazawa S, Kawamura I. High-resolution 3D mapping of epicardial conduction during Marshall bundle-related atrial tachycardia. *J Arrhythmia*. 2018;34:298–301.  
<https://doi.org/10.1002/joa3.12067>