

Pyoderma gangrenosum-like necrotizing panniculitis associated with Imatinib: A case report

Jorge Hernández,^{1,2} Alicia Sanz,³ Beatriz Isla-Tejera,^{1,2} Juan Ruano^{2,4}

¹Department of Pharmacy, Reina Sofia University Hospital; ²Instituto Maimonides de Investigacion Biomedica de Cordoba - IMIBIC, Reina Sofia University Hospital, University of Cordoba; ³Department of Pathology, Reina Sofia University Hospital; ⁴Department of Dermatology, Reina Sofia University Hospital, Córdoba, Spain

Abstract

Imatinib mesylate is a small tyrosine kinase inhibitor that targets BCR-ABL, c-kit and platelet-derived growth factor receptor. It is prescribed by hematologists for chronic myeloid leukemia and acute lymphoblastic leukemia and by oncologists for Gastrointestinal Stromal Tumors (GIST). Cutaneous reactions to *Imatinib* are common but their incidence and severity widely varies between patients. A self-limited skin rash is the most common adverse effect but there have been reported cases of patients with maculopapular rash, pigmentary changes, superficial edema and rarer and clinically distinctive features such as lichenoid reactions or psoriasis. We here describe for the first time a case of pyoderma gangrenosum-like necrotizing panniculitis, a rare dermatological condition, after initiating therapy with *Imatinib*.

Case Report

A 53-year-old man with stage IIIa gastrointestinal tumor of the stomach (pT3cN0cM0) positive for KIT (CD117) and high risk of relapse was started with *Imatinib* 400mg daily for 36 months in an adjuvant setting after laparoscopic removal of the tumor. The patient exhibited durable response and acceptable tolerance, however, after a year and two months he presented one black crusted plaque on the anterior surface of the right lower limb that caused redness and swelling of the surrounding skin (Figure 1a). No history of trauma was reported and no signs of systemic infection were present. Blood tests showed no abnormalities.

Under the clinical suspicion of tick bite or spider bite he was started on 1 month-course of doxycycline with ibuprofen, but failed to improve and after two weeks new lesions appeared in the form of ulcers with erythematous-violaceous raised edges and a fibrinous layer, all localized in the same extremity close to the first lesion (Figure 1b). After a risk-benefit analysis, *Imatinib* was discontinued under suspicion of a late onset adverse effect. Punch biopsy of the ulcer edge showed acute and non-specific chronic inflammation of the dermis (Figure 2a) with extensive necrosis of the subcutaneous tissue (Figure 2b) Full-body computed tomography found no evidence of disease progression while anti-cardiolipin antibodies, antinuclear antibodies, anti-neutrophil cytoplasmic antibodies and anticentromere antibodies tests resulted negative. Laboratory and biopsy results led to the definitive diagnosis of pyoderma gangrenosum-like necrotizing panniculitis.

In addition to *Imatinib* withdrawal, the patient received 1mg of intralesional triamcinolone acetonide and was started on prednisone 0.5 mg/kg/d for 45 days and cyclosporine 4mg/kg/d and for 30 days. He rapidly improved and on 3 weeks the size of the injuries had reduced to 40% with no new lesions and no signs of infection, to finally resolve completely (Figure 1c). After 6 months, no relapse was observed and he still remains asymptomatic.

Discussion

It is often difficult to categorize a panniculitis given their heterogeneous nature. Regrettably, commonly used punch biopsies yield insufficient amounts of subcutaneous adipose tissue for a full histopathologic assessment. When possible, panniculitides are categorized by the pattern of the inflammatory cell infiltrate into lobular panniculitides, such as erythema induratum (also known as “nodular vasculitis”) or septal panniculitides like erythema nodosum,¹ but histopathological findings depend on the stage of evolution and may vary among samples. In our case the biopsy showed perivascular inflammation with septal vascular alterations and lymphohistiocytic infiltration that had intensively extended into the lobule, but necrosis was so prevalent it was not possible to establish the predominance with certainty. Interestingly, erythema induratum is typically characterized for presenting ulcerating nodular lesions. Its predominant relation to tuberculosis is well-known, but it has also been associated with hepatitis C, inflammatory

Correspondence: Juan Ruano, Instituto Maimonides de Investigacion Biomedica de Cordoba, Menedez Pidal s/n, 14004 Cordoba, Spain
Tel.: +34 606 88 7057
E-mail: juanruanorui@mac.com

Key Words: Imatinib; pyoderma gangrenosum-like; necrotizing panniculitis.

Conflict of Interest: The Authors declare no potential conflict of interests.

Received for publication: 16 November 2019.
Accepted for publication: 20 June 2020.

This work is licensed under a Creative Commons Attribution-NonCommercial 4.0 International License (CC BY-NC 4.0).

©Copyright: the Author(s), 2020

Licensee PAGEPress, Italy
Dermatology Reports 2020; 12:8381
doi:10.4081/dr.2020.8381

bowel disease or drugs.²

In our patient, *Imatinib* withdrawal and steroid-cyclosporine therapy led to an almost complete resolution of the lesions. Anti-phospholipid syndrome and Wegener’s granulomatosis were discarded after antibodies tests resulted negative, and a full body computed tomography discarded pancreatitis or disease progression. Patients with pancreatitis or α -1-antitrypsin deficiency have been reported to develop panniculitis with zones of fat necrosis as a complication,³ in our case lab tests results did not show this deficiency. Based on our findings, a cause-effect relationship for *Imatinib* was deemed highly likely in the Naranjo and WHO-UMC probability scales for drug adverse reactions,⁴ and so it was reported to our local Pharmacovigilance Center.

Imatinib mesylate has often been reported for its cutaneous manifestations (rash,⁵ hypopigmentation,⁶ superficial edema, psoriasis,⁷ and lichenoid reactions⁸) but it has seldom been associated with panniculitis with necrotic ulceration. Ugurel *et al*,⁹ and Breccia *et al*,¹⁰ both described a case of panniculitis in patients with chronic myelogenous leukemia using *Imatinib*. Also, *Imatinib* has several times been linked to neutrophilic dermatoses, such as acute generalized exanthematous pustulosis, Sweet syndrome and neutrophilic eccrine hidradenitis,¹¹⁻¹³ but the mechanism behind these adverse effects has yet to be fully understood. A case of pyoderma gangrenosum, a rare ulcerative neutrophilic dermatosis has also been documented in a patient treated with *Imatinib*.¹⁴ Myeloproliferation has been documented in mice at 10-fold

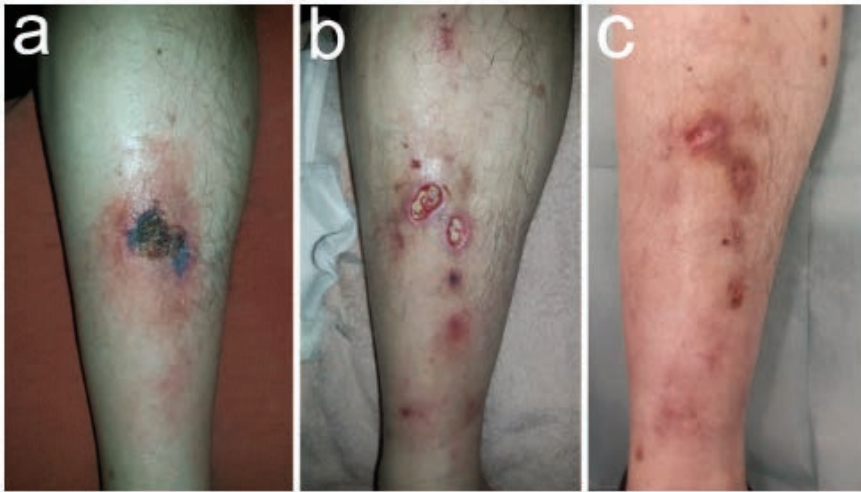


Figure 1. Clinical presentation and skin lesions evolution. a) A solitary initial lesion appeared pre-tibially on the right limb as a large and painful exulceration covered by a necrotic scar. b) Several painful ulcers with a fibrinous bed and an elevated, violaceous, undermined border, were observed two weeks after. c) Almost complete healing was observed three weeks after Imatinib was withdrawal.

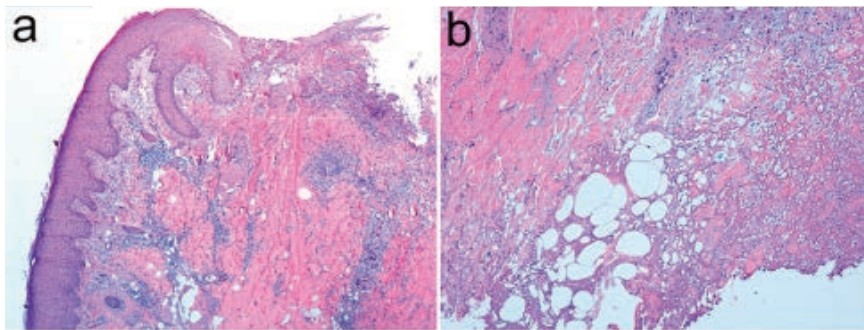


Figure 2. Hematoxiline-eosin stain of a 5 mm-punch biopsy taken on the advancing edge/raised border of established lesion. a) A combination of acute and non-specific chronic perivascular inflammation of the dermis shown at 40x. b) Lymphohistiocytic infiltrate, with occasional formation of multinucleated giant cells, extended into the septa and the lobule, along with extensive lipophagic necrosis, shown at 100x.

lower doses than the usual, mimicking a physiological increment in number of circulating monocytes and neutrophils to a bone marrow infection.¹⁵ It has also been associated to endothelial apoptosis and increased endothelial permeability.¹⁶ Both phenomena could explain the induced subcutaneous ischemia, necrosis, and subsequent neutrophil infiltration seen in our patient. Interestingly, there have also been reports of drug-induced panniculitis with other c-Kit inhibitors such as ponatinib and nilotinib,^{17,18} and pyoderma gangrenosum-like ulcerations with sunitinib and pazopanib,^{19,20} hinting at a common mechanism.

Conclusions

Clinicians should be aware of potential necrotizing panniculitis pyoderma gangrenosum-like in patients treated with *Imatinib* and consider stopping treatment until resolution of symptoms. Further studies ought to be performed to determine the exact mechanism linking *Imatinib* and other c-Kit inhibitor with their cutaneous side effects.

References

- 1 Segura S, Requena L. Anatomy and Histology of Normal Subcutaneous Fat, Necrosis of Adipocytes, and Classification of the Panniculitides. *Dermatol Clin* 2008;26:419-24.

- 2 Gilchrist H, Patterson JW. Erythema nodosum and erythema induratum (nodular vasculitis): Diagnosis and management. *Dermatol Ther* 2010;23:320-7.
- 3 Lyon MJ. Metabolic panniculitis: Alpha-1 antitrypsin deficiency panniculitis and pancreatic panniculitis. *Dermatol Ther* 2010;23:368-74.
- 4 Zaki S. Adverse drug reaction and causality assessment scales. *Lung India* 2011;28:152.
- 5 Basso FG, Boer CC, Corrêa MEP, Torrezan M, Cintra ML, De Magalhães MHCG et al. Skin and oral lesions associated to Imatinib mesylate therapy. *Support Care Cancer* 2009;17:465-8.
- 6 Tsao AS, Kantarjian H, Cortes J, O'Brien S, Talpaz M. Imatinib Mesylate Causes Hypopigmentation in the Skin. *Cancer* 2003;98:2483-7.
- 7 Valeyrie L, Bastuji-Garin S, Revuz J, Bachot N, Wechsler J, Berthaud P et al. Adverse cutaneous reactions to Imatinib (STI571) in Philadelphia chromosome-positive leukemias: A prospective study of 54 patients. *J Am Acad Dermatol* 2003;48:201-6.
- 8 Ena P, Chiarolini F, Siddi GM, Cossu A. Oral lichenoid eruption secondary to Imatinib (Gleevec®). *J Dermatolog Treat* 2004;15:253-5.
- 9 Ugurel S, Lahaye T, Hildenbrand R, Glorer E, Reiter A, Hochhaus A et al. Panniculitis in a patient with chronic myelogenous leukaemia treated with Imatinib. *Br J Dermatol* 2003;149:678-9.
- 10 Breccia M, Carmosino I, Russo E, Morano SG, Latagliata R, Alimena G. Early and tardive skin adverse events in chronic myeloid leukaemia patients treated with Imatinib. *Eur J Haematol* 2005;74:121-3.
- 11 Liu D, Seiter K, Mathews T, Madahar CJ, Ahmed T. Sweet's syndrome with CML cell infiltration of the skin in a patient with chronic-phase CML while taking Imatinib Mesylate. *Leuk Res* 2004;28:61-3.
- 12 Dib EG, Ifthikharuddin JJ, Scott GA, Partilo SR. Neutrophilic eccrine hidradenitis induced by Imatinib mesylate (Gleevec) therapy. *Leuk Res* 2005;29:233-4.
- 13 Brouard MC, Prins C, Mach-Pascual S, Saurat J-H. Acute Generalized Exanthematous Pustulosis Associated with STI571 in a Patient with Chronic Myeloid Leukemia. *Dermatol* 2001;203:57-9.
- 14 Sharma R, Pinato D. Imatinib induced pyoderma gangrenosum. *J Postgrad Med* 2013;59:244.

- 15 Napier RJ, Norris BA, Swimm A, Giver CR, Harris WAC, Laval J et al. Low Doses of Imatinib Induce Myelopoiesis and Enhance Host Anti-microbial Immunity. *PLoS Pathog* 2015;11:1-27.
- 16 Vrekoussis T, Stathopoulos EN, De Giorgi U, Kafousi M, Pavlaki K, Kalogeraki A et al. Modulation of Vascular Endothelium by Imatinib: A Study on the EA.hy 926 Endothelial Cell Line. *J Chemother* 2014;18:56-65.
- 17 Zhang M, Hassan KM, Musiek A, Rosman IS. Ponatinib-induced neutrophilic panniculitis. *J Cutan Pathol* 2014;41:597-601.
- 18 Kitayama N, Otsuka A, Hamamoto C, Kaku Y, Shiragami H, Okumura Y et al. Nilotinib-induced panniculitis in a patient with chronic myelogenous leukaemia. *J Eur Acad Dermatol Venereol* 2017;31:e418-9.
- 19 Lopez Pineiro M, Willis E, Yao C, Chon SY. Pyoderma gangrenosum-like ulceration of the lower extremity secondary to sunitinib therapy: a case report. *SAGE Open Med Case Rep* 2018;6:2050313X18783048.
- 20 Usui S, Otsuka A, Kaku Y, Dainichi T, Kabashima K. Pyoderma gangrenosum of the penis possibly associated with pazopanib treatment. *J Eur Acad Dermatol Venereol* 2016;30:1222-3.