

Visual Hemifield Loss in Thalamic Hematoma

Prakashchand Agarwal, Saroj Gupta, Sushil Jindal, Shefali Bansal, Pathak, Rakesh Biswas

Department of Ophthalmology, People's College of Medical Sciences.

Corresponding Author:

Prakash Agarwal, MD
Department of Ophthalmology,
People's College of Medical Sciences.
Tel.: +91 8085133033
E-mail: drpinkuol@yahoo.co.in

ABSTRACT

A 45 year old hypertensive patient presented to the emergency medical room (EMR) with sudden onset of severe headache, episode of vomiting, visual loss and confusion. A C.T scan and MRI brain was done revealing a large hematoma in the region of posterior part of left thalamus. The patient was disoriented in time, place and had right visual field hemianopia. The headache and higher functions became normal with control of intracranial pressure and supportive therapy. There were no motor or sensory symptoms or signs. This case is unique as a large thalamic hematoma presented with only visual field deficit and no sensory or motor system affection.

KEY WORDS: Hemianopia, Hematoma, Hemorrhage, Thalamus

doi : 10.5214/ans.0972.7531.111812

Report

A 45 year male patient presented to Emergency medical room (EMR) with history of sudden onset left sided headache and multiple episodes of vomiting. The patient was conscious but with poor orientation of time, place and person. He complained of blurring of vision of both eyes. There was no significant past medical history.

On examination Glasgow coma scale (GCS), the pulse was 62/min regular, rhythmic and good volume. The blood pressure (BP) recorded in left upper arm in supine position was 190/110 mm Hg. The patient was afebrile with no pallor, icterus or cyanosis. Cardiovascular and chest examination was normal. Abdomen was soft with no organomegaly. On evaluation of the neurological system higher were altered due to poor orientation and low GCS i.e. 8. The motor system was normal with grade 4+ power and reflex were normal. There was no sensory deficit on any side of the body. Cerebellar signs could not be elicited as patient was not cooperative at presentation; however they were normal when examined later. There were no signs of meningitis such as neck stiffness and Kernig's test. No obvious cranial nerve involvement was noted.

On examination of visual system, the vision was at least 20/400 in both eyes. On confrontation there was right homonymous hemianopia. Pupillary reflexes were normal from left hemifield but not from right hemifield (Wernike's pupil). Anterior segment of the eye was normal and there was no papilledema. The retinal arteries were attenuated in a ratio 1:3. Fovea and macula was normal.

A clinical suspicion of intracranial lesion was made in view of sudden onset severe headache with vomiting along with altered sensorium.

A contrast Computed Tomogram (CT) scan of the brain revealed a 39X19X14 mm hemorrhage in the posterior part of left thalamus with caudal and medial extension towards the optic radiations. To rule out bleeding from aneurysm magnetic resonance angiogram was done (MRA) which did not reveal any aneurysm but showed haemorrhage. The spin echo (SE) and gradient echo (GRE) images

reveal hemorrhagic signal in the region of left thalamic nucleus. There is relative sparing of posterior limb of internal capsule.

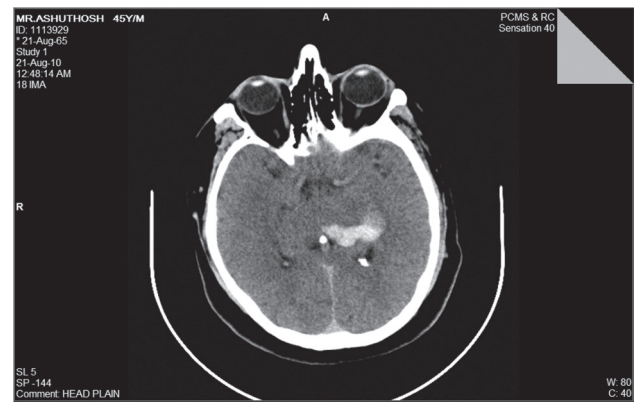
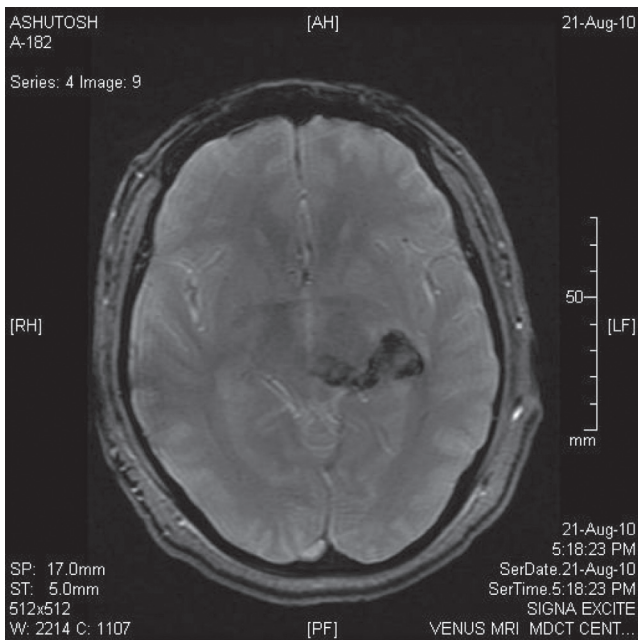
Blood hemogram done was normal. Renal and liver function test were also normal. The lipid profile revealed elevated LDL of 128 mg%, VLDL 32 mg% and Triglycerides of 242 mg%. The automated static perimetry revealed right homonymous hemianopia.

In view of clinical findings and neuroimaging along with evidence of right homonymous hemianopia, affection of left lateral geniculate body (LGB) due to thalamic hemorrhage was confirmed. For control of raised intracranial tension (ICT) the patient was started on injection mannitol (100ml, 20%) TDS and supportive treatment of injection Phenytoin (100 mg TDS) and injection Citicoline 500 mg BD. For control of systemic hypertension the patient was started on tablet amlodipine (5 mg) which stabilised BP at 150/100 mm Hg. The patient was reviewed 3 months later and there were no motor or sensory deficits. The visual field loss recovered partially and the hematoma size decreased on repeat CT scan.

According to a review of 100 patients of thalamic bleed, ocular features are commonly seen in patients with posterolateral, anterolateral, and medial thalamic hemorrhage. Gaze preference toward the lesion was seen in 72% with large thalamic hemorrhage (> 4 cm diameter). Other common signs seen were horizontal or vertical gaze palsy, skew deviation, one and a half syndrome, pupillary abnormality and hemianopia. Only 3 out 100 (3%) patients have demonstrated contralateral visual field hemianopia.¹

A few case reports also describe isolated visual field loss as sole feature of localised small hematoma of the lateral geniculate body.^{2,3}

Large intracranial bleed involving the basal ganglia and thalamus were present as acute emergency with signs of raised intracranial pressure and neurological deficit. Severe motor and sensory deficit may be present along with speech or higher function loss. Damage to the neighbouring cortical structures or brainstem may progress to involve cranial nerves. However, our patient had mainly visual field loss with a large hematoma involving the posterior thalamus.



References:

1. Kumral E, Kocael T, Ertübey NO, *et al.* Thalamic Hemorrhage: A Prospective Study of 100 Patients. *Stroke*. 1995; 26:964–970.
2. Tsuda H, Oi Y, Yoshioka M, *et al.* Homonymous Hemianopia due to Localized Hemorrhage of the Lateral Geniculate Body. *Internal Medicine*. 2006; 21: 1257–1258.
3. Kosmorsky G, Lancione R. When Fighting Makes You See Black Holes Instead of Stars. *Journal of Neuro-Ophthalmology*. 1998; 18: 255–257.