



Unusual Presentation of Pleural Space Ascariasis Infection from Eastern Sudan: A Case Report

Nader Ahmed Mohammed¹, Abdulrahman OE Adam², Monzir Ahmed Hassan Osman^{2,3}, Hibatallah MA Abass^{2,3}, Awad MA Salih^{2,3}, Ameer AM Abaker^{2,3} , Alamin Mustafa^{3,4}, Mamoun Magoub ⁵

¹Department of Medicine, Faculty of Medicine, University of Kassala, Kassala, Sudan; ²Faculty of Medicine, Omdurman Islamic University, Omdurman, Sudan; ³Patient Support Organization Research Unit, Khartoum, Sudan; ⁴Faculty of Medicine, Al-Neelain University, Khartoum, Sudan; ⁵Department of Microbiology & Parasitology, Faculty of Medicine & Health Science, West Bank of Gash River, University of Kassala, Kassala, Sudan

Correspondence: Mamoun Magoub, Department of Microbiology & Parasitology, Faculty of Medicine & Health Science, West Bank of Gash River, University of Kassala, Kassala, Sudan, Tel +24991291999, Email mamounmagzoub@kassalauni.edu.sd; Alamin Mustafa, Faculty of Medicine, Al-Neelain University, JG37+2RM, 52nd St, Khartoum, Sudan, Tel +249902612984, Email alamin900005@gmail.com

Background: *Ascaris lumbricoides* is a common infectious parasite of the gastrointestinal tract worldwide, but the invasion of the pleural cavity is rare.

Case Report: A 45-year-old man from Eastern Sudan presented to the emergency department complaining of breathlessness, cough stained with blood, and chest pain one month before his presentation. Also, he complained of high-grade fever for two weeks associated with sweating. Diagnosis of hydropneumothorax was made and a chest tube was inserted, two days later we found three adult *A. lumbricoides* worms in the chest drain.

Conclusion: The patient was treated with Albendazole 200 mg, orally twice, daily for seven days, he improved and was referred to a cardiothoracic surgeon for more assessment. Our study highlights that internal medicine specialists should know about pleural ascariasis when patients present with respiratory signs and symptoms, especially in *A. lumbricoides* endemic regions like Eastern Sudan.

Keywords: neglectable tropical diseases, pulmonology, pleural cavity, ascariasis, *Ascaris lumbricoides*

Introduction

Ascaris lumbricoides is a common infectious parasite of the gastrointestinal tract worldwide, transmitted by ingesting embryonated eggs from fecal-contaminated food or drink. Risk factors include poverty, poor sanitation, and poor personal hygiene. The prevalence is high in children less than five years of age and it is rarely found in the gallbladder, also invasion of the pleural cavity is rare. Intestinal obstruction is a common ascariasis complication.^{1–7} *A. lumbricoides* larvae can affect the respiratory system through an allergic reaction called Löffler's syndrome.⁸

Ascaris lumbricoides Life Cycle

When both adult female and male worms are present in the intestine, the female adult worms begin to lay fertile eggs approximately nine to 11 weeks after infection.⁹ In the setting of infection with only female worms the eggs do not develop into the infectious stage because they are unfertilized, while in the case of infection with only male worms, no eggs will be formed. Eggs can survive for up to ten years and they are resistant to chemical water purification; nevertheless, they can be removed through filtration or boiling.¹⁰ The infective larvae hatch from fertilized eggs in 18 days to several weeks, based on ideal conditions such as moist, warm, and shaded soil. When infective eggs are consumed, the larvae hatch, enter the intestinal mucosa, and travel to the lungs via the portal and systemic circulation. After about two weeks, the larvae mature in the lungs before penetrating alveolar walls, ascending the bronchial tree to the throat, and swallowing again. Then, they grow into full adult worms (measuring 15 to 35 cm) once they come to the small intestine.¹¹ The adult female's entire cycle, from egg swallowing to laying, takes approximately two to three months and adult worm may live for less than two years¹² (Figure 1a). In the intestinal tract, most worms live in the

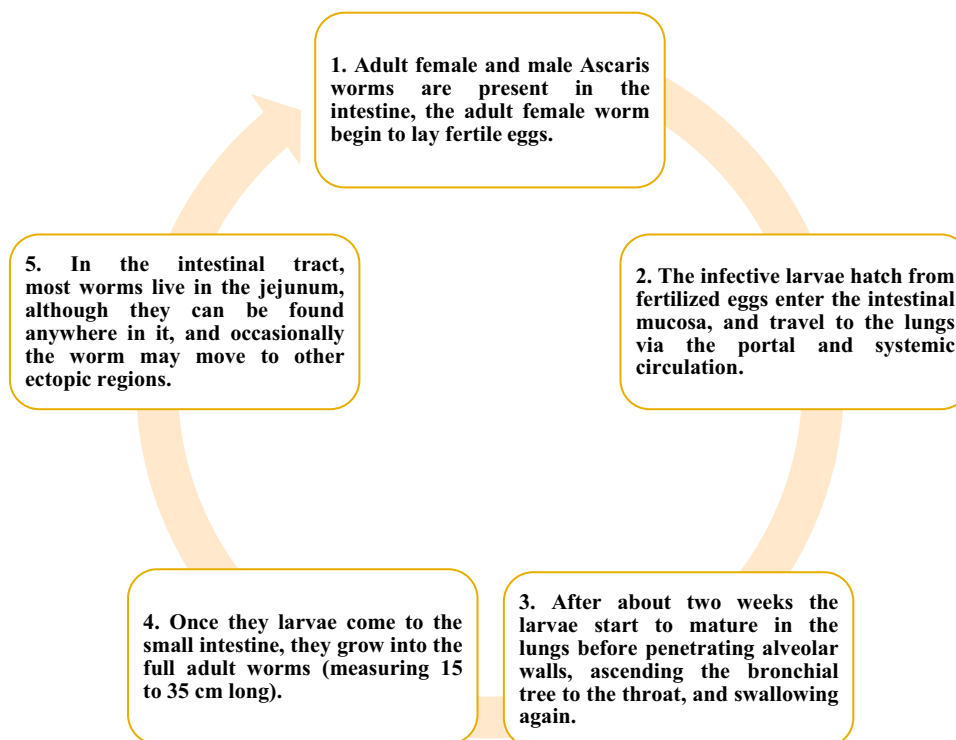


Figure 1 This figure shows the life cycle of *Ascaris lumbricoides*.

jejunum, although they can be found anywhere in it, and occasionally the worms may move to other ectopic regions. It is rare for *A. lumbricoides* worms to reach the pleural cavity as there is no natural orifice that connects the pleura with another body part. However, adult worms can perforate the lung and the pleura, though this is a rare occurrence that has been reported in the literature.¹³ Here, we present a rare case of a 45-year-old male who presented with ascariasis complicated with pleural effusion. To our knowledge, this association with pleural cavity ascariasis has rarely been reported in the literature.

Case Presentation

A 45-year-old man came to the emergency department at Kassala Teaching Hospital in Eastern Sudan complaining of a cough persisting for one month, a fever lasting for two weeks, and developed sudden shortness of breath that began one day before his visit. The patient initially experienced a gradual increase in cough severity one month before admission, with the production of a small amount of white sputum without an odor. The color of the sputum later changed to yellowish, and three days before admission, it became stained with blood. The patient also reported having intermittent episodes of high to moderate fever accompanied by sweating. One day before admission, the cough worsened, and the patient developed sudden shortness of breath that occurred at any time of the day. The patient also experienced mild pleuritic chest pain primarily in the lower part of the chest, and there were no palpitations, lower limb swelling, wheezing, or syncope. The patient denied abdominal pain, diarrhea, constipation, or weight loss—no past medical history of a similar condition or hospitalization.

Upon assessment, the patient seemed unwell, exhibited respiratory distress, and was positioned in a cardiac bed. His respiratory rate was elevated at 28 breaths per minute, and his oxygen saturation level was considerably low at 78%. There was decreased chest movement and tactile vocal fremitus on the left side, which was dull upon percussion, particularly in the lower zone. Air entry on the left side was reduced, accompanied by bronchial breathing and a decrease in vocal resonance. No abdominal distension, mass, increased warmth, or tenderness were observed.

Investigations

Laboratory examination results revealed that the total white blood cell count (WBCs) was 15.7×10^3 cells/mL, showing neutrophilia and mild eosinophilia. Hemoglobin was 11.6 g/dL, platelet count was 365×10^3 cells/mL with serum urea of 20 mg/dL and serum creatinine of 0.7 mg/dL. The chest X-ray revealed a massive left-sided pleural effusion with an air-fluid level indicating hydropneumothorax (Figure 2). The pleural fluid analysis showed a reddish appearance pleural fluid with an RBCs count of 18,000, WBCs count of 3396, 94% neutrophils, 6% lymphocytes, a protein level of 4.9 g/dL and a glucose level of 80 mg/dL.

Treatment and Management

The patient was admitted to the intensive care unit (ICU) and received high-flow oxygen, broad-spectrum antibiotics, a proton pump inhibitor, and after sterilization, the chest tube insertion involved making an incision in the safety triangle and dissecting the intercostal muscles using artery forceps. The chest tube was inserted into the intercostal space using a trocar, after which pleural fluid began to drain from the chest tube, and the patient became stable. Two days after the insertion of the chest tube the pleural fluid revealed the presence of three adult *A. lumbricoides* worms. The worms were sent to the laboratory (Figure 3), and a parasitologist was consulted and confirmed the identification of the worms, after

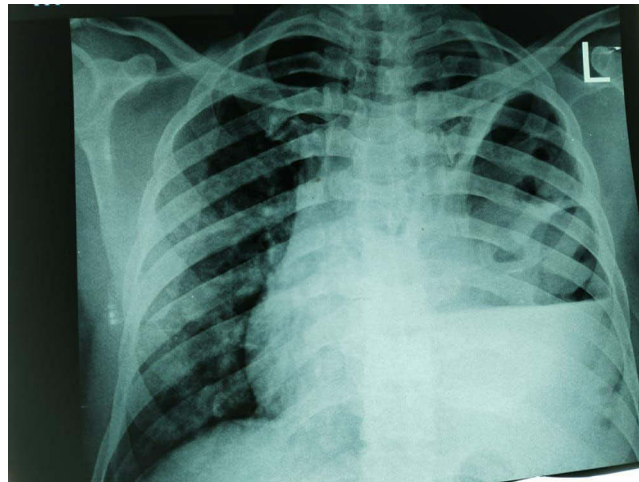


Figure 2 This chest X-ray shows left massive pleural effusion with an air-fluid level indicating left-sided hydropneumothorax shown in a red arrow.

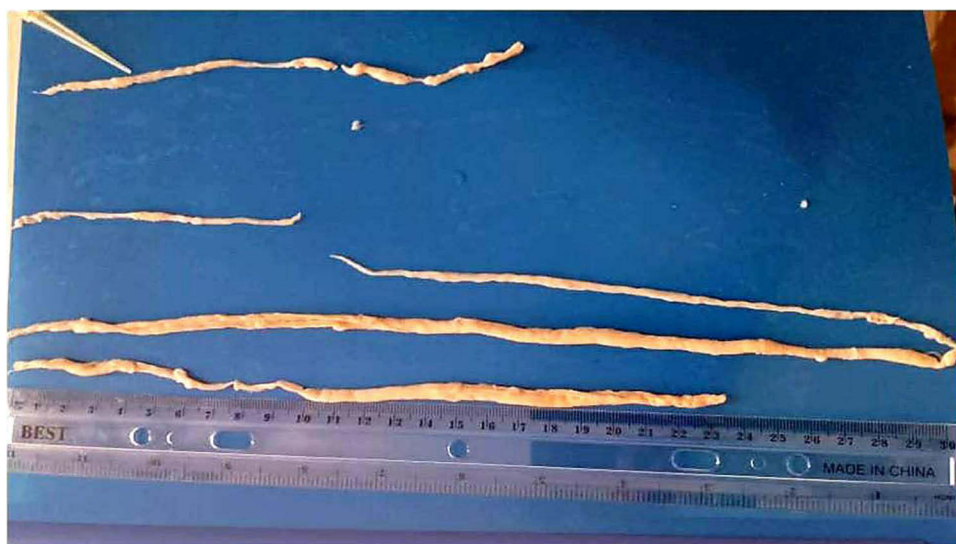

Figure 3 This picture shows the *Ascaris lumbricoides* adult worms more than a year after they were collected and isolated from the chest tube.

which Albendazole was immediately added to the treatment plan. A chest physician recommended thoracoscopic surgery with or without decortication for the patient. Stool analysis conducted on the same day was negative for *A. lumbricoides* eggs. Six days after admission, a CT chest scan showed evidence of a left pleural collection with an air-fluid level suggestive of empyema. On the eighth day of admission, an abdominal ultrasound was done and it was normal. The patient was discharged from the ICU 15 days after admission and referred to a specialized chest hospital, where the medical team removed the chest tube and discharged the patient. The patient returned three weeks later with a recurrence of symptoms and a gradual reemergence of cough. As a result, the patient was referred again to the specialized chest hospital for the surgery. The patient was admitted and a decortication was done; then, he was discharged in good condition and now he is doing well.

Discussion

A. lumbricoides is a prevalent infection caused by intestinal roundworm that affects over 700 million individuals globally.^{14,15} *A. lumbricoides* infections are passed between hosts by the fecal-oral transmission of eggs containing infective larvae. Freshly excreted eggs require a few weeks for embryonation before they become infective. However, embryonation occurs faster in warm moist soil and water which is the typical weather in Eastern Sudan for most of the year.

The small intestine is the primary site of infection for *Ascaris* worms, but the adult worms will attempt to enter any orifice and move forward into any channel branching off from it when the living environment becomes unfavorable; this can happen during gastrointestinal disorders, hunger, fever, failed anti-ascaris medication, or the impaction of a mass of worms in the intestinal lumen.¹⁶ Intestinal obstruction, a common ascariasis complication, can cause intestinal perforation, peritonitis, liver abscess, and other abdominal complications, including appendicitis and others.^{16,17} Sometimes, these worms may even move in the opposite direction, from the stomach to the pharynx, and are referred to as ectopic wanderers.^{16,18} *A. lumbricoides* worms have been reported to enter the trachea, especially in young children and patients with poor health who have impaired cough and pharyngeal reflexes, which can result in an obstruction.^{7,16,18,19} Also, *A. lumbricoides* in the upper respiratory tract can produce stridor and cyanosis even in fully conscious adult patients.²⁰ In a review, Ali et al²¹ identified 14 cases of lower airway obstruction due to *A. lumbricoides*. People infected with *A. lumbricoides* typically generate detectable antibodies; however, it seems that IgG antibodies do not provide protective immunity against the infection, and there is often cross-reactivity of these antibodies with antigens from other parasitic worms.^{9,22} Serology is generally reserved for epidemiologic studies rather than clinical diagnosis. Here, a definitive diagnosis can be established through the visualization of *Ascaris* larvae in respiratory secretions or gastric aspirate.

Pleural ascariasis is a rare condition caused by larvae or adult stages. We found in the literature a case of an 11-year-old boy who had a recurrent spontaneous pneumothorax due to *A. lumbricoides* larvae, which was treated with pleurodesis.²³ Infestation with *A. lumbricoides* can be so severe that it resembles meningitis; some authors believe this is caused by toxins released by the parasite. This severe infection was reported in a 4-year-old boy who was presented in a deep coma and died 12 hours following admission. At autopsy, there was no evidence of infection in the meninges; however, the middle ear exhibited a purulent discharge with granulation tissue, indicating inflammation. The intestine showed numerous *Ascaris* worms, suggesting an advanced infestation. In addition, there was left pleural effusion and early gangrene with an adult *Ascaris* worm perforating the lower lobe of the left lung.¹³ According to Elhadidy et al,⁵ a case of pleural ascariasis was diagnosed when the treating doctors noticed an eight cm long *Ascaris* worm in the pleural biopsy needle. In a reported case by Lone et al²⁴ *Ascaris* worm had recovered from a chest tube in a patient who suffered from a liver abscess that had ruptured into the right pleural cavity. In another case, an adult *Ascaris* worm emerged from a chest tube due to a wrong insertion, leading to perforation of the diaphragm and the intestine where the worms were present.²⁵ Sen et al²⁶ defined a case of a mature *Ascaris* worm migrating from the intestines to settle in the pleural cavity in a patient with tuberculous pyopneumothorax and bronchopleural fistula. Also and similar to our case, Zamora reported a case of adult *Ascaris* worm that was discovered in the pleural cavity during a thoracotomy for lung apicoectomy in a patient who had undergone thoracic surgery.²⁷

Here, we highlight in our case the significance of being aware of pulmonary ascariasis, a very rare complication that may be discovered accidentally as in our case. Symptoms of pulmonary diseases are similar to each other, our patient complained of a cough that started dry, then became productive, then stained with blood, fever, and shortness of breath; this course is very

common and not specific to a certain pulmonary disease, so pulmonary ascariasis came at the end in the list of differential diagnosis. Although the course of the patient was unexpected for us, thoracoscopy was not performed following the *Ascaris* identification. Due to limited resources in our hospital, we sent the patient to a specialized chest hospital in the capital of the Sudan where surgery was available, but unfortunately, they removed the chest tube and sent the patient home, after which he subsequently experienced a return of symptoms. Then, he was sent back to them, and they performed a decortication – the removal of the adhesions and thickened pleura lining the lung – for him.

In this case, we were unable to definitively determine the pathway through which the *Ascaris* entered the pleural cavity as our primary focus was on treating the patient. We have two hypotheses for the patient's symptoms; one hypothesis is that the *Ascaris* worms reached maturity in the lung and started causing irritation, eventually leading to lung perforation and hydropneumothorax. This would explain the negative stool analysis for *Ascaris* eggs, but it does not account for the unexpected onset of respiratory symptoms that began approximately one month before the hydropneumothorax. Furthermore, the maturation of *Ascaris* larvae in the lung is not explained in the literature to the best of our knowledge. The other hypothesis is that the patient was infected with intestinal ascariasis and for reasons that are not apparent from the patient history, the worms migrated to the lung, causing respiratory symptoms that worsened gradually, ultimately leading to the perforation of the lung and the development of hydropneumothorax, this may not explain the negative stool analysis for *Ascaris* eggs. We did not repeat the stool analysis as the presence of the adult worms was sufficient for diagnosis, and determining the source of the *Ascaris* infection was not our primary aim at that moment.

Physicians in *A. lumbricoides* endemic and neglectable regions like Kassala in Eastern Sudan should be aware of potential complications associated with ascariasis, including intestinal obstruction, malnutrition, growth delays, and impaired cognitive development, particularly in schoolchildren, due to reduced absorption of dietary proteins, lactose, and vitamins A and C.^{28,29} Ascariasis can also lead to hepatobiliary and pancreatic involvement, resulting in conditions such as biliary colic, strictures, cholecystitis, ascending cholangitis, obstructive jaundice, and liver abscesses. Additionally, other complications may arise, such as bile duct perforation and the formation of biliary stones.^{9,16,17} We encourage the physicians from endemic regions to report their rare clinical findings related to tropical disease.

Conclusion

This report presented a rare case of ascariasis complicated with pleural effusion and associated with the presence of adult *A. lumbricoides* worms in the pleural cavity, causing unspecific respiratory symptoms and treated with Albendazole.

Data Sharing Statement

Data that support this case presentation is available upon contacting the corresponding author.

Ethics Approval

The publication of a single case report does not require ethics approval according to the policies of the Omdurman Islamic University.

Consent for Publication

Written informed consent for publication was obtained from the patient after informing him of the importance of the identified clinical findings.

Funding

There is no funding to report.

Disclosure

The authors report no conflicts of interest in this work.

References

1. Leung AKC, Leung AAM, Wong AHC, Hon KL. Human ascariasis: an updated review. *Recent Pat Inflamm Allergy Drug Discov.* 2020;14(2):133–145. doi:10.2174/1872213x14666200705235757.
2. Dold C, Holland CV. Ascaris and ascariasis. *Microb Infect.* 2011;13(7):632–637. doi:10.1016/j.micinf.2010.09.012
3. Imtiaz W. Gallbladder ascariasis. *Turk J Gastroenterol.* 2011;22(2):178–182. doi:10.4318/tjg.2011.0187
4. Aldiabat M, Saeed Y, Hani DB, Rabah S, Yu B. A rare case of ascariasis-induced cholangitis complicated with Klebsiella pneumoniae bacteremia and liver microabscesses. *Cureus.* 2021;13(1). doi:10.7759/cureus.12503
5. Elhadidy T, Eldesoqy ME, Morsy NE, Abdelwahab HW, Tohlob M. Ascaris lumbricoides through pleural biopsy needle. a rare case of intrapleural ascariasis. *Archivos de Broncon.* 2016;53(3):171–172. doi:10.1016/j.arbres.2016.08.014
6. Shah OJ, Zargar SA, Robbani I. Biliary ascariasis: a review. *World J Surg.* 2006;30(8):1500–1506. doi:10.1007/s00268-005-0309-1
7. Gan RWC, Gohil R, Belfield K, Davies P, Daniel M. Acute airway obstruction by ascaris lumbricoides in a 14-month-old boy. *Intern J Pediatr Otorh.* 2014;78(10):1795–1798. doi:10.1016/j.ijporl.2014.07.031
8. Sarinas P, Chitkara RK, editors. *Ascariasis and Hookworm. Seminars in Respiratory Infections.* 1997.
9. Karin Leder PFW, Nageshwar Reddy D. Ascariasis (2022). Available from: <https://www.uptodate.com/contents/ascariasis>. Accessed July 16, 2024.
10. Khuroo MSA. ASCARIASIS. *Gastroenterol Clin North Am.* 1996;25(3):553–577. doi:10.1016/s0889-8553(05)70263-6
11. CDC. Ascariasis. Available from: <https://www.cdc.gov/dpdx/ascariasis/index.html>. 2024.
12. Reeder MM. The radiological and ultrasound evaluation of ascariasis of the gastrointestinal, biliary, and respiratory tracts. *Seminars in Roentgenology.* 1998;33(1):57–78. doi:10.1016/S0037-198X(98)80031-X
13. Middleton L. Pulmonary gangrene with empyema and acute meningismus, due to ascaris lumbricoides. *Can Med Assoc J.* 1929;20(5):510.
14. Pullan RL, Smith JL, Jasrasaria R, Brooker SJ. Global numbers of infection and disease burden of soil transmitted helminth infections in 2010. *Parasites Vectors.* 2014;7(1):1–19. doi:10.1186/1756-3305-7-37
15. Betson M, Nejsum P, Bendall RP, Deb RM, Stothard JR. Molecular epidemiology of ascariasis: a global perspective on the transmission dynamics of ascaris in people and pigs. *J Infect Dis.* 2014;210(6):932–941. doi:10.1093/infdis/jiu193
16. Li QY, Zhao DH, Qu HY, Zhou CN. Life-threatening complications of ascariasis in trauma patients: a review of the literature. *World J Emerg Med.* 2014;5(3):165–170. doi:10.5847/wjem.j.issn.1920-8642.2014.03.001.
17. De Silva N, Guyatt H, Bundy D. Morbidity and mortality due to ascaris-induced intestinal obstruction. *Trans Royal Soc Trop Med.* 1997;91(1):31–36. doi:10.1016/S0035-9203(97)90384-9
18. Ramchander V, Ramcharan J, Muralidhara K. Fatal Respiratory Obstruction Due to Ascaris Lumbricoides—A. Case Report. *Ann Trop Paediatrics.* 1991;11(3):293–294. doi:10.1080/02724936.1991.11747517
19. Singh R, Garg C, Vajifdar H. Near fatal respiratory obstruction due to ascaris lumbricoides. *Trop doctor.* 2005;35(3):185. doi:10.1258/0049475054620815
20. Faraj JH. Upper airway obstruction by ascaris worm. *Can J Anaesthesia.* 1993;40(5):471. doi:10.1007/BF03009524
21. Ali SR, Mehta AC. Alive in the airways: live endobronchial foreign bodies. *Chest.* 2017;151(2):481–491. doi:10.1016/j.chest.2016.10.041
22. Das AK. Hepatic and biliary ascariasis. *J Glob Infect Dis.* 2014;6(2):65–72. doi:10.4103/0974-777x.132042.
23. Santini M, Baldi A, Vicidomini G, Di Marino M, Baldi F. Relapsing pneumothorax due to ascaris lumbricoides larvae. monaldi archives for chest disease= archivio monaldi per le malattie del torace. *Mona Arch for Chest Dis.* 1999;54(4):328–329.
24. Lone RA, Wani ML, Manzoor M, et al. Ascaris through a chest tube: a rare presentation. *Ulus Travma Acil Cerrahi Derg.* 2010;16(2):183–184.
25. Mohite PN, Mistry JH, Mehta H, Patra BS. Ascaris worm in the intercostal drainage bag: inadvertent intercostal tube insertion into jejunum: a case report. *J Cardiothorac Surg.* 2010;5(1):125. doi:10.1186/1749-8090-5-125.
26. Sen MK, Chakrabarti S, Ojha UC, Daima SR, Gupta R, Suri JC. Ectopic ascariasis: an unusual case of pyopneumothorax. *Indian J Chest Dis Allied Sci.* 1998;40(2):131–133.
27. Zamora Almeida O. Localization of ascaris lumbricoides in the thoracic cavity. report of a case. *Rev Cubana Med Trop.* 1976;28(2):71–75.
28. Hlaing T. Ascariasis and Childhood Malnutrition. *Parasitology.* 1993;107(S1):S125–S36.
29. Blumenthal DS, Schultz MG. Effects of ascaris infection of nutritional status in children. *American J Trop Med Hyg.* 1976;25(5):682–690. doi:10.4269/ajtmh.1976.25.682

Research and Reports in Tropical Medicine

Dovepress

Publish your work in this journal

Research and Reports in Tropical Medicine is an international, peer-reviewed, open access journal publishing original research, case reports, editorials, reviews and commentaries on all areas of tropical medicine, including: Diseases and medicine in tropical regions; Entomology; Epidemiology; Health economics issues; Infectious disease; Laboratory science and new technology in tropical medicine; Parasitology; Public health medicine/health care policy in tropical regions; and Microbiology. The manuscript management system is completely online and includes a very quick and fair peer-review system. Visit <http://www.dovepress.com/testimonials.php> to read real quotes from published authors.

Submit your manuscript here: <http://www.dovepress.com/research-and-reports-in-tropical-medicine-journal>