

Perinatal sacroiliitis diagnostic challenges

SAGE Open Medical Case Reports
Volume 9: 1–5
© The Author(s) 2021
Article reuse guidelines:
sagepub.com/journals-permissions
DOI: 10.1177/2050313X211052442
journals.sagepub.com/home/sco



Emam M Kheder¹ , Hussain H Sharahili², Salma Y Albahrani³,
Abdullah M Alfarhan¹, Abdulrahman M Alquraynis¹,
Mahmoud B Maitigue¹ and Ahmed M Al Wehaibi¹

Abstract

Lumbo-pelvic pain is a common and non-specific problem during pregnancy and postpartum. Although perinatal pyogenic sacroiliitis is uncommon during this time, it might be difficult to distinguish from reactive sacroiliitis in women who are experiencing significant lower back and pelvic girdle pain, as the symptoms and signs are not clear and the tests are not definitive. A 34-year-old primigravida went to the emergency department with severe lower back pain radiating to the right gluteal region and down to the back of the right thigh. This pain began 12 days prior to her presentation and eventually worsened to the point that she could not stand or walk. Her vital signs were within normal ranges, and she was experiencing a fever. Apart from a slight widening of the symphysis pubis, her pelvic and lumbo-sacral pain X-rays revealed no important findings. With the clinical impression of right lumbo-pelvic pain, the patient was admitted for pain management and further inquiries. Despite the fact that the antibiotherapy was prescribed to treat a urinary tract infection, the significant recovery of the patient's symptoms, even in the absence of a definitive culture of aspirate from the right sacroiliac joint, supported the diagnosis of pyogenic sacroiliitis.

Keywords

Pelvic pain, sacroiliac joint, infection, magnetic resonance imaging and pregnancy

Date received: 30 June 2021; accepted: 23 September 2021

Introduction

The pelvis and sacroiliac joints (SIJs) undergo significant alterations during pregnancy, which have a deleterious impact on dynamic stability and may cause pelvic girdle and lower back pain.^{1,2} While pregnancy-related pyogenic sacroiliitis (PSI) is uncommon, with fewer than 20 cases reported in the literature,³ it is tough to diagnose because it necessitates a high level of clinical suspicion and diagnostic imaging confirmation.⁴ Medical care should not be postponed because it risks not only joint and bone damage but also septicemia in both the mother and the child.⁵

Case presentation

A grossly obese 26-year-old lady with a body mass index (BMI) of 43, gravida-1, para-1 + 0, type 2 diabetes mellitus, and hypothyroidism. She came to the causality with 12 days history of severe continuous right-sided lower back pain, right side pelvic pain increased with ambulation. Her pain started in a mild way prior to her recent admission for elective cesarean section for twin babies, using spinal epidural anesthesia, got worse and began to radiate to the back of the

right thigh, increased with ambulation. There was no history of trauma, fever, chills, urinary, gynecological, or other systemic symptoms. Her physical examination revealed a temperature of 37.1°C, severe tenderness over the lower back, and right side of the pelvic region with intact neurology. Her cesarean section wound in the abdomen has healed. Her lower back and pelvis were stiff with severe pain on movements, standing, or sitting. The straight leg raising test was positive (30–40°), and the FABER Patrick's test was difficult to evaluate due to intense pain despite the strong analgesia.

The lumbo-sacral spine X-ray was unremarkable, but the pelvis X-ray revealed a 12mm widening of the symphysis pubis (Figure 1).

¹Department of Orthopedics, King Fahd Military Medical Complex, Dhahran, Saudi Arabia

²Department of Radiology, King Fahd Military Medical Complex, Dhahran, Saudi Arabia

³Department of Internal Medicine, King Fahd Military Medical Complex, Dhahran, Saudi Arabia

Corresponding Author:

Emam M Kheder, Department of Orthopedics, King Fahd Military Medical Complex, 31932 Dhahran, Saudi Arabia.

Email: emamkheder@gmail.com



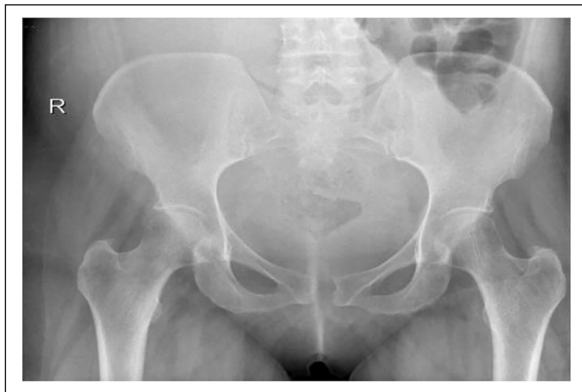

Figure 1. AP plain radiographic of the pelvis and sacroiliac joints revealed minor widening of the symphysis pubis and no other abnormalities.

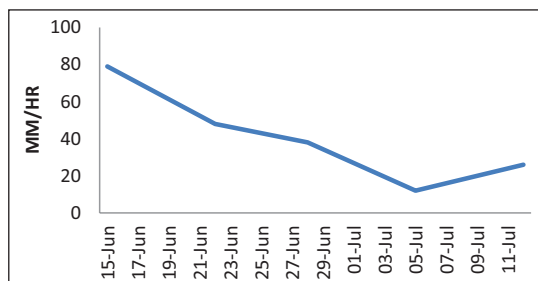


Figure 2. ESR mm/h.

She was hospitalized for further examinations and pain control after a clinical diagnosis of perinatal right-sided lumbo-pelvic pain (LPP). Laboratory testing found 6.85 white blood cells (WCC) G/l with 69.2% neutrophils, a 48mm/h elevated erythrocyte sedimentation rate (ESR) (Figure 2), normal procalcitonin (0.02), and a 68.7 mg/L elevated C- reactive protein (Figure 3).

The lumbar spine magnetic resonance imaging (MRI) was negative, but the pelvic MRI found minor fluid signal amplitude in the right SIJ, which was associated with myositis (Figure 4).

The patient was accused of developing unilateral sacroiliac arthritis and piriformis muscle syndrome. In the context of pain modality and incremental mobilization, we started her treatment with narcotic and non-narcotic analgesics, as well as non-steroidal anti-inflammatory medicines and physiotherapy. Her pain could not be controlled, and she became worse, unable to ambulate or step in or out of bed. Neurosurgery, neurology, rheumatology, anesthesia, obstetrics, and gynecology teams were consulted, but nothing was added to the preliminary diagnosis or the treatment plan. Despite the absence of any symptoms or signs indicating an acute or chronic infection, urine and blood cultures, protein purified derivative (PPD) for tuberculosis, and serology for brucella were required on Day 8. Because it was impossible to place the patient in the prone position on the same day,

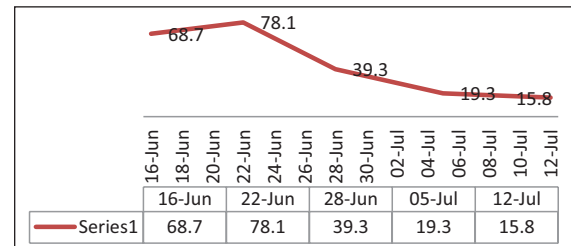


Figure 3. CRP mg/L.

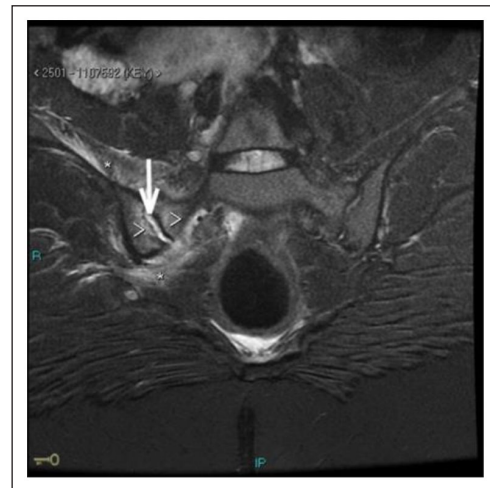


Figure 4. Pelvic MRI on admission showing bone marrow edema (arrowheads), small intraarticular fluid (arrow) and muscle edema-like change, myositis (asterisk).

CT-guided aspiration of the right SIJ was performed in the left lateral position (Figure 5), but no aspirated fluid was obtained; however, SIJ block was performed using 20 mL of 0.25% bupivacaine after which she briefly noticed some relief of her shooting pain.

Although the blood culture, brucella serology, and PPD all came back negative, the urine culture revealed asymptomatic *Escherichia coli* bacteriuria. The patient was started on IV ceftriaxone 1 g every 12 h and gentamicin 400 mg once a day by the infectious disease (ID) team. She showed steady and progressive clinical improvement just 48 h after intravenous antibiotics (IVAB). Ceftriaxone was given for another 2 weeks, and gentamicin was given for another 10 days. Her pain score (visual analogue scale (VAS) 2 out of 10) improved significantly, as did her walking capacity, bathroom privileges, and blood parameters. Following discharge on Day 26, the patient was sent home with oral ciprofloxacin 750 mg twice daily for 6 weeks. Nevertheless, her MRI on institutional discharge showed no substantial improvement compared to the initial one. She did well with regular ambulation and normal blood parameters at 6-week, 3-month, and 6-month follow-up visits. Her 1-year follow-up MRI was uneventful (Figure 6), while she did have periodic minor right-sided LPP that did not interfere with her daily activities.

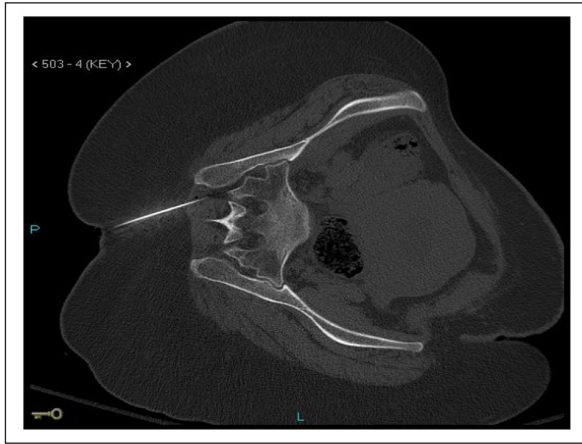

Figure 5. CT-guided right SI joint needle aspiration in the left lateral position.

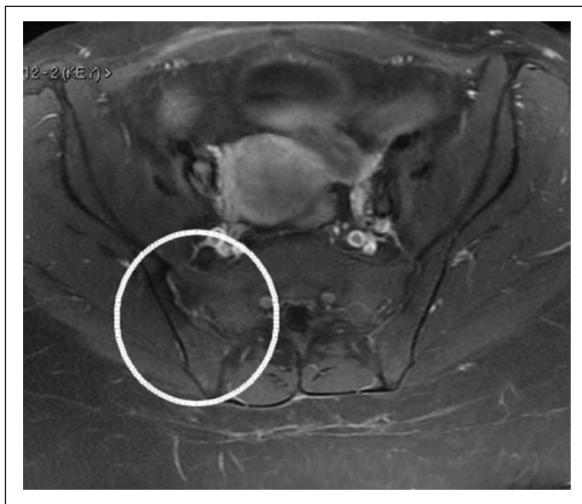


Figure 6. A pelvic MRI a year later revealed normal bone marrow signal and normal surrounding muscle. There are no fluids within the joints.

Discussion

Pain in the lower back and buttocks is widespread and vague in 20% of pregnant women, making SIJ diseases difficult to diagnose.⁶ Despite the fact that PSI accounts for just 1%–1.5% of all instances of septic arthritis, it is estimated that 10% or more of these infections occur in women during pregnancy, postpartum, or following an abortion.^{7,8}

In PSI, the SIJ is always involved unilaterally, with the left side predominating in 59% of cases. On admission, the diagnosis is infrequently suspected (12.85%), and the clinical picture can be misunderstood as sciatica or spondylodiscitis. This unique clinical presentation looked to be the reason for the long period between diagnosis and treatment.⁹ The pelvic ligaments loosen with increasing pelvic motions as a result of increased weight and hormone-induced alterations in the pelvis, which

can influence the microvasculature of joint surfaces, rendering the periosteum more susceptible to transient bacteremia and bacterial invasion.^{10–12} Furthermore, the venous plexus system, which drains the paravertebral and pelvic areas and the subchondral circulation in the ilium have a sluggish blood flow, which is thought to increase the risk of blood-borne bacteria forming a host site in the SIJs.^{13,14}

PSI can be diagnosed if bacteriological confirmation of sacroiliitis is achieved, or if clinical, biological, and radiological evidence are consistent with this diagnosis in the absence of pathogenic agents, and if the patient's evolution was favorable on antibiotic therapy, as in our case.⁹ Despite the fact that urinary tract infection is one of the most common causes of reactive arthritis and may be a risk factor for infectious sacroiliitis (ISI), yet it was extremely difficult to distinguish between reactive and infectious arthritis in our case.¹⁵

The explosive onset of the disease is seen in two-thirds of patients and typically includes high- or low-grade fever and severe continuous pain, originating from the affected SIJ and felt most often in the buttock, low back, and/or hip area.¹⁶ Physical examinations and particular tests, such as pain provocation tests, P4/thigh thrust, Patrick's FABER, and the active straight leg raise (ASLR) test, are suggested but not definitive.¹⁷

Due to their non-specific nature, laboratory testing initially made diagnosis more challenging. Although the amount of C-reactive protein (CRP) and ESR may be relatively sensitive indices of PSI, the leukocyte count has not been found to be a sensitive marker of PSI, and one-third of patients have a normal WCC.^{3,8,9} Only one-third to two-thirds of patients have positive blood cultures.¹⁸ Gram-positive cocci, primarily *Staphylococcus aureus*, have been reported to be the most often cultured organisms, with gram-negative bacillus, primarily *Pseudomonas aeruginosa* and *E. coli*, accounting for fewer than 20% of previously reported instances.¹⁹ Invasive diagnostic methods are a last resort in patients whose blood culture results fail to reveal a causal pathogen, as collecting synovial fluid from the SIJ is challenging in such individuals who are in pain during positioning and the surgery itself. A CT-guided needle aspiration or a fluoroscopically guided fine-needle aspiration are routinely used for confirmation.²⁰

At the time of presentation, a plain pelvic roentgenogram is usually normal.^{1,8} Because considerable bone loss is required before changes can be noticed on plain films, the earliest changes on plain films include blurring of joint borders, an increased joint space, or periarticular erosion, which emerge 2 weeks after onset of symptoms.⁷ As a result, false negative radiographs are usual in acute cases, and caution should be exercised when ruling out a recent infection based on initially normal-looking photos.^{21–23} In the perinatal phase, MRI is most likely the imaging diagnostic tool of choice for detecting sacroiliitis. It provides a detailed evaluation of the joint and surrounding soft tissues, demonstrating prominent bone marrow edema

adjacent to the SIJ surfaces, synovitis of SIJ itself, and edema in the neighborhood soft tissues, which may help to distinguish mimickers of spondyloarthritis, such as crystal arthropathies, reactive arthritis, insufficiency fractures, septic arthritis, IgG4-related disease, sarcoidosis, hematologic conditions, and neoplastic disorders.^{24–26} PSI might be detected when low signal intensity on T1 and high signal intensity on T2 were observed on orientated MRI slices.⁹ This test also allows physicians to see whether the infection has spread to nearby muscle tissues, which was seen in 48.1% of cases.²⁷ Because MRI signal anomalies can last for months, even though there is no fever or clinical and biological progress appears to be on the way, it should be done in a systematic manner.²⁸ The most sensitive imaging modality for infection is ^{99m}Tc radionuclide scanning. Increased radionuclide uptake in the sacroiliac region can happen as early as 2 to 7 days after the illness begins.^{6,22} As a result, a positive bone scan will help to avoid delays in diagnosis and care. Although highly sensitive for infection, the specificity of bone scanning is low. A Technetium scan should be accompanied by a Gallium-67 citrate (⁶⁷Ga) scan in cases of suspected sacroiliac infection. This radiopharmaceutical is useful for detecting infections because it has a preference for polymorphonuclear leukocytes (PMNs).²⁷ Although radionuclide scans can be useful for monitoring post-delivery care, they should not be used during pregnancy.^{29–31} CT can reliably direct joint aspiration of joint fluid in cases of suspected PSI. If an aspirate is not obtained, flushing the joint with normal saline and aspirating the saline will boost the chances of a positive culture. A para-articular bone biopsy may be used to confirm or rule out infection if SIJ fluid cannot be collected despite saline flushing, as in tuberculous sacroiliitis. Pigtail insertion into PSI abscesses can also be guided by CT.³² The treatment for pregnancy-related PSI is similar to that for non-pregnancy instances.⁴ Delaying medical intervention can result in joint and bone damage, as well as maternal and newborn septicemia.⁵ Although there is no unanimity on how long antibiotic treatment should last in PSI, it seems reasonable to propose 2 weeks of parenteral antibiotics followed by 6 weeks of oral antibiotics. Prolonging care beyond 6 weeks does not seem to be justified, as it does not reduce the likelihood of relapse.³³ In suspected PSI or in the absence of any known microorganism, empirical antibiotic treatment active against *Staphylococcus*³⁰ should be considered before the specific organism(s) and antimicrobial sensitivities have been identified, and should be expanded to include Gram-negative bacteria in the event of failure.^{9,32} When used in conjunction with antimicrobial medication, surgical intervention, such as incision and drainage, has been found to promote clinical recovery.²⁷ Long-term monitoring may be required, as lumbogluteal pain that exacerbated during daily activities was reported to continue in almost one-third of cases in the literature.³³

Conclusion

Perinatal sacroiliitis is a difficult diagnosis to make since the symptoms and signs are non-specific, and investigations are inconclusive, thus delaying proper care. The extreme intensity of the patient's lumbogluteal pain on presentation, which is increased by weight-bearing or some effort to displace the SIJ, may aid in distinguishing PSI from other musculoskeletal pain sources. Pain aversion to opioids and/or non-narcotic analgesics, a dramatic clinical reaction to parenteral antibiotics, and the existence of a defined source of infection are all additional diagnostic clues. In the absence of a fever or a positive blood culture, and standard biological parameters, such as ESR, CRP, and WCC, MRI is the most effective imaging technique for determining early and subsequent joint changes.

Acknowledgements

The authors thank Dr. rer. nat. Areeg Abdelrahman for editing a draft of this work.

Declaration of conflicting interests

The author(s) declared no potential conflicts of interest with respect to the research, authorship, and/or publication of this article.

Ethical approval

Our institution does not require ethical approval for reporting individual cases.

Funding

The author(s) received no financial support for the research, authorship, and/or publication of this article.

Informed consent

Written informed consent was obtained from the patient for his anonymized information to be published in this article.

ORCID iD

Emam M Kheder  <https://orcid.org/0000-0002-5326-6326>

References

1. Mens JMA, Vleeming A and Snijders CJ. Reliability and validity of the active straight leg raise test in posterior pelvic pain since pregnancy. *Spine* 2001; 26(10): 1167–1171.
2. Jedwab M, Ovadia S and Dan M. Pyogenic sacroiliitis in pregnancy. *Int J Gynecol Obstet* 1999; 65(3): 303–304.
3. Almoujahed MO, Khatib R and Baran J Jr. Pregnancy associated pyogenic sacroiliitis: case report and review. *Infect Dis Obstet Gynecol* 2003; 11(1): 53–57.
4. Egerman RS, Mabie WC, Eifrid M, et al. Sacroiliitis associated with pyelonephritis in pregnancy. *Obstet Gynecol* 1995; 85(5, Pt. 2): 834–835.
5. Cekmez Y, Göçmen A and Arslan O. A rare reason for pelvic pain in pregnancy: infectious sacroiliitis. *Case Rep Med* 2015; 2015: Article 690429.

6. Gordon G and Kabins SA. Pyogenic sacroiliitis. *Am J Med* 1980; 69(1): 50–56.
7. Millwala F, Chen S and Tsaltskan V. Acupuncture and postpartum pyogenic sacroiliitis: a case report. *J Med Case Rep* 2015; 9: 193.
8. Vyskocil J, Mellroy M and Brennan T. Pyogenic infection of the sacroiliac joint: case report and review of the literature. *Medicine* 1991; 70: 188–197.
9. Hermet M, Minichiello E and Flipo RM. Infectious sacroiliitis: a retrospective, multicentre study of 39 adults. *BMC Infect Dis* 2012; 12: 305.
10. Haq I and Morris V. Post-partum septic sacroiliitis. *Rheumatology* 2001; 40(10): 1191–1192.
11. Moros ML, Rodrigo C and Villacampa A. Septic shock in pregnancy due to pyogenic sacroiliitis: a case report. *J Med Case Rep* 2009; 23: 6505.
12. Kanakaris NK, Psarakis S and Chalidis B. Management of pelvic instability secondary to chronic pyogenic sacroiliitis: case report. *Surg Infect (Larchmt)* 2009; 10(4): 353–358.
13. Batson O. The function of the vertebral veins and their role in the spread of metastases. *Ann Surg* 1940; 112: 138–149.
14. Resnick D and Niwayama G. *Diagnosis of bone and joint disorders*. 1st ed. Philadelphia, PA: Saunders, 1981.
15. Butrimiene I, Ranceva J and Griskevicius A. Potential triggering infections of reactive arthritis. *Scand J Rheumatol* 2006; 35(6): 459–462.
16. Vleeming A, Albert HB and Ostgaard HC. European guidelines for the diagnosis and treatment of pelvic girdle pain. *Eur Spine J* 2008; 17(6): 794–819.
17. Kerr R. Pyogenic sacroiliitis. *Orthopedics* 1985; 8: 1028–1034.
18. Bindal M and Krabak B. Acute bacterial sacroiliitis in an adult: a case report and review of the literature. *Arch Phys Med Rehabil* 2007; 88(10): 1357–1359.
19. Murphey MD, Wetzel LH and Bramble JM. Sacroiliitis: MR imaging findings. *Radiology* 1991; 180(1): 239–244.
20. Dunn E, Bryan D and Nugent J. Pyogenic infections of the sacro-iliac joint. *Clin Orthop Relat Res* 1976; 118: 113–117.
21. Cohn S and Schoetz DJ Jr. Pyogenic sacroiliitis: another imitator of the acute abdomen. *Surgery* 1986; 100(1): 95–98.
22. Linnet KM, Gammelgaard L and Johansen M. Bilateral pyogenic sacroiliitis following uncomplicated pregnancy and labor. *Acta Obstet Gynecol Scand* 1996; 75(10): 950–951.
23. Braun J, Sieper J and Bollow M. Imaging of sacroiliitis. *Clin Rheumatol* 2000; 19: 51–57.
24. Stürzenbecher A, Braun J and Paris S. MR imaging of septic sacroiliitis. *Skeletal Radiol* 2000; 29: 439–446.
25. Shapiro S and Crispin E. Pyogenic sacroiliitis. *Minn Med* 1986; 69(4): 201–204.
26. Gupta DR, Herrera N and Chen C. Scintigraphic demonstration of pyogenic sacroiliitis. *Clin Nucl Med* 1982; 7(6): 295–296.
27. Kirchner P and Simon M. Current concepts review: radioisotopic evaluation of skeletal disease. *JBJS* 1981; 63-A: 673–681.
28. Braun J, Bollow M and Seyrekbasan F. Computed tomography guided corticosteroid injection of the sacroiliac joint in patients with spondyloarthropathy with sacroiliitis: clinical outcome and followup by dynamic magnetic resonance imaging. *J Rheumatol* 1996; 23(4): 659–664.
29. Roblot F, Besnier JM, Juhel L, et al. Optimal duration of antibiotic therapy in vertebral osteomyelitis. *Semin Arthritis Rheum* 2007; 36: 269–277.
30. Doita M, Yoshiya S, Nabeshima Y, et al. Acute pyogenic sacroiliitis without predisposing conditions. *Spine* 2003; 28: 384–389.
31. Wu M-S, Chang S-S, Lee S-H, et al. Pyogenic sacroiliitis—a comparison between paediatric and adult patients. *Rheumatology* 2007; 46: 1684–1687.
32. Moran GJ, Krishnadasan A, Gorwitz RJ, et al. Methicillin-resistant *S. aureus* infections among patients in the emergency department. *N Engl J Med* 2006; 355: 666–674.
33. Mancarella L, De Santis M, Magarelli N, et al. Septic sacroiliitis: an uncommon septic arthritis. *Clin Exp Rheumatol* 2009; 27(6): 1004–1008.