

CASE REPORT

Internal hernia after laparoscopic right hemicolectomy, report of a case

Hiroki Sugita*, Takahiko Akiyama, Naoya Daitoku, Rumiko Tashima, Hiroshi Tanaka, Shinobu Honda, Tetsumasa Arita, Yasushi Yagi, and Masahiko Hirota

Department of Surgery, Kumamoto Regional Medical Center, Kumamoto, Japan

*Correspondence address. Department of Surgery, Kumamoto Regional Medical Center, 5-16-10 Honjo, Kumamoto 860-0811, Japan. Tel: +81(96)-363-3311; Fax: +81(96)-362-0222; E-mail: sugitaf@ba2.so-net.ne.jp

Abstract

Mesenteric defects are often not closed in laparoscopic colectomy. We herein report a case of an internal hernia projecting through a mesenteric defect following laparoscopy-assisted right hemicolectomy. A 74-year-old woman was hospitalized for the surgical treatment of double colon cancer. Preoperative colonoscopy demonstrated the presence of ascending colon and transverse colon cancers. A laparoscopic-assisted right hemicolectomy was performed. The mesenteric defect resulting from the colectomy was not closed. Three months after the surgery, the patient developed a bowel obstruction. Under a diagnosis of strangulated bowel obstruction, we performed a laparotomy, and found a necrotic small bowel, which had passed into the bursa omentalis through the mesenteric defect. We removed the necrotic small bowel and closed the mesenteric defect by suturing. The patient's postoperative course was uneventful. An internal hernia projecting through a mesenteric defect following laparoscopy-assisted right hemicolectomy developed a severe strangulated bowel obstruction.

INTRODUCTION

Laparoscopic colectomy has been accepted for benign and malignant diseases of the colon for its quicker recovery time as well as from a cosmetic viewpoint [1, 2]. In addition, long-term oncological studies have indicated that laparoscopic colectomy was equivalent to open surgery in survival rates for colon cancer [1, 3]. Therefore, laparoscopic surgery is currently the standard colon cancer treatment.

Numerous reports indicate that mesenteric defects are often not closed in laparoscopic colectomy [4]. We herein report a case of an internal hernia projecting through a mesenteric defect following laparoscopy-assisted right hemicolectomy.

CASE REPORT

A 74-year-old woman was hospitalized for the surgical treatment of double colon cancer. Her medical history showed that she had been suffering from permanent damage from a cerebral hemorrhage for several years. A colonoscopic examination demonstrated the presence of an ascending colon tumor and a transverse colon tumor. Biopsies performed before surgery revealed that both lesions were well-differentiated adenocarcinomas. A laparoscopic-assisted right hemicolectomy was performed. We divided the sub-middle colic artery and the ileocecal artery that fed the tumors with surgical trunk dissection (D3 lymph node dissection). The right colon moved out

Received: October 7, 2016. Revised: November 23, 2016. Accepted: May 11, 2017

Published by Oxford University Press and JSCR Publishing Ltd. All rights reserved. © The Author 2017.

This is an Open Access article distributed under the terms of the Creative Commons Attribution Non-Commercial License (<http://creativecommons.org/licenses/by-nc/4.0/>), which permits noncommercial re-use, distribution, and reproduction in any medium, provided the original work is properly cited. For commercial re-use, please contact journals.permissions@oup.com

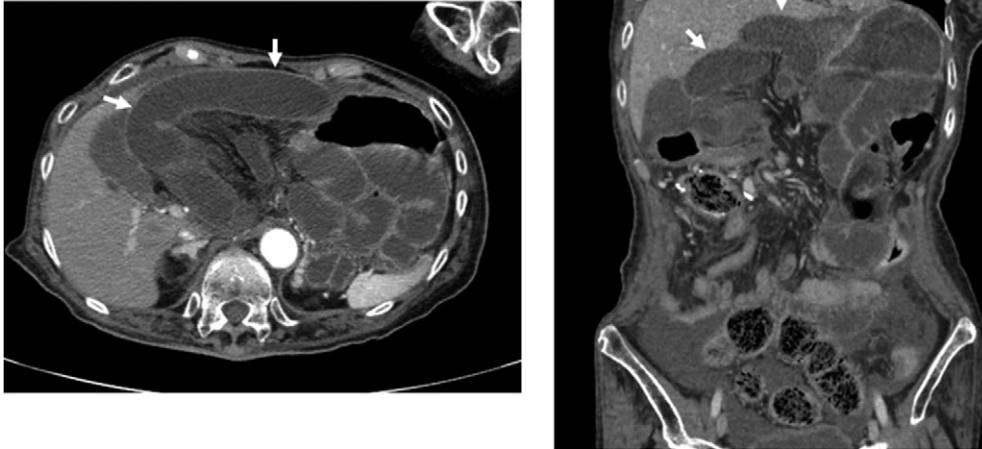


Figure 1: Preoperative CT scan revealed an internal hernia (arrow).

through a 5-cm midline incision. The marginal vessels were ligated, and functional end-to-end anastomosis was performed extracorporeally using linear staplers. The mesenteric defect resulting from the colectomy was not closed. No herniation of the small bowel through the mesenteric defect was observed laparoscopically. Operation time was 238 min. Blood loss was 10 ml.

The double cancers were diagnosed pathologically as pT4a, pN1b, M0, pStage IIIB in the ascending colon and pT4a, pN2a, M0, pStage IIIC in the transverse colon (TNM classification seventh Edition). Capecitabine was administered as an adjuvant chemotherapy, beginning 28 days after the surgery.

Three months after surgery, the patient developed a bowel obstruction. She had nausea, vomiting and abdominal distension. A plain abdominal X-ray revealed air-fluid levels in upper abdomen. A computed tomography (CT) scan revealed a closed loop of small bowel in the upper side of the transverse colon. This finding indicated a strangulated ileus (Fig. 1). Therefore, emergency surgery was performed. We performed a laparotomy finding the small bowel, which had passed into the bursa omentalis through the mesenteric defect (7–8 cm in diameter). We removed the necrotic small bowel 65 cm in length and closed the mesenteric defect by suturing (Fig. 2). Operation time was 102 min. Blood loss was 50 ml. The patient's postoperative course was uneventful. At the 2-year follow-up examination, no evidence of cancer recurrence or internal hernia was observed.

DISCUSSION

With the publication of several reports demonstrating that the outcomes of laparoscopic surgery for colon cancer were equivalent to those in open surgery, this approach has become widespread in recent years [1, 3]. Laparoscopic surgery also is beneficial because of its minimal invasiveness [2].

Closure of the mesenteric defect caused by anastomosis after colectomy is not performed routinely in laparoscopic surgery [4]. Laparoscopic closure of the mesenteric defect requires a longer operation time, and incomplete closure may produce internal hernia of the small bowel. There is no consensus concerning closure of the defect. Small bowel obstructions related to mesenteric defect are rare in laparoscopic colectomy. In the case reported here, the patient developed a strangulated ileus. A narrow defect caused by mesenteric adhesion may produce

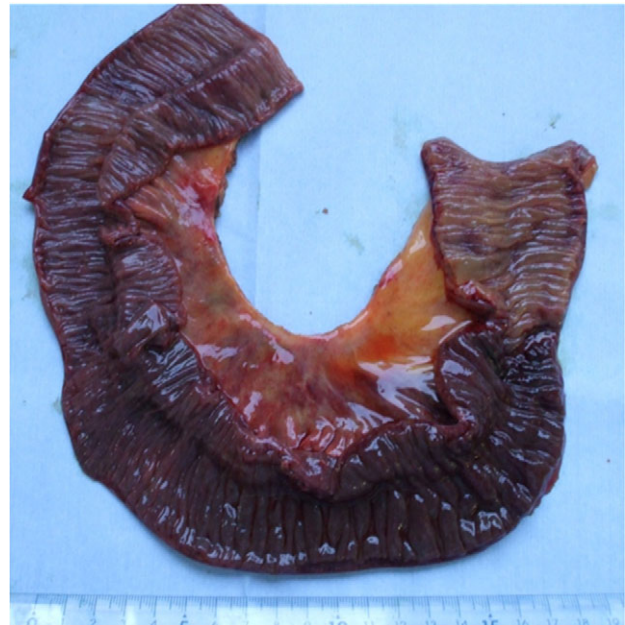

Figure 2: A picture of the resected strangulated small intestine.

the strangulation of the small bowel that passed through the mesenteric defect. The mesentery of the colon was conglutinated to the pancreas and surgical trunk that were dissected in the first operation, resulting in the formation of a small defect of the mesentery. Papers reported various types of internal hernias after laparoscopic colectomy [5–9]. In this case, the right hemicolectomy and the lymph nodes dissection in a wide area were necessary because of the double and advanced cancers (pT4a, pN1b, M0, pStage IIIB in ascending colon and pT4a, pN2a, M0, pStage IIIC in transverse colon). This might have allowed the tissues of the mesentery to conglutinate more easily. Internal hernia after laparoscopic colectomy is rare. However, patients with strangulated bowel obstructions may experience severe illness. An internal hernia projecting through a mesenteric defect following laparoscopy-assisted right hemicolectomy developed a severe strangulated bowel obstruction. Therefore, a closure of the mesenteric defect may be necessary after laparoscopic colectomy.

CONFLICTS OF INTEREST STATEMENT

None declared.

REFERENCES

1. Clinical Outcomes of Surgical Therapy Study Group. A comparison of laparoscopically assisted and open colectomy for colon cancer. *N Engl J Med* 2004;**350**:2050–9.
2. da Luz Moreira A, Kiran RP, Kirat HT, Remzi FH, Geisler DP, Church JM, et al. Laparoscopic versus open colectomy for patients with American Society of Anesthesiology (ASA) classifications 3 and 4: the minimally invasive approach is associated with significantly quicker recovery and reduced costs. *Surg Endosc* 24:1280–6.
3. Lacy AM, Garcia-Valdecasas JC, Delgado S, Castells A, Taura P, Pique JM. Laparoscopy-assisted colectomy versus open colectomy for treatment of non-metastatic colon cancer: a randomised trial. *Lancet* 2002;**359**:2224–9.
4. Cabot JC, Lee SA, Yoo J, Nasar A, Whelan RL, Feingold DL. Long-term consequences of not closing the mesenteric defect after laparoscopic right colectomy. *Dis Colon Rectum* 53:289–92.
5. Daskalaki A, Kaimasidis G, Xenaki S, Athanasakis E, Chalkiadakis G. Internal-mesocolic hernia after laparoscopic left colectomy report of case with late manifestation. *Int J Surg Case Rep* 6C:88–91.
6. Hosono S, Ohtani H, Arimoto Y, Kanamiya Y. Internal hernia with strangulation through a mesenteric defect after laparoscopy-assisted transverse colectomy: report of a case. *Surg Today* 2007;**37**:330–4.
7. Masubuchi S, Okuda J, Tanaka K, Kondo K, Asai K, Kayano H, et al. Internal hernia projecting through a mesenteric defect to the lesser omental cleft following laparoscopic-assisted partial resection of the transverse colon: report of a case. *Surg Today* 43:814–7.
8. Nagata K, Tanaka J, Endo S, Tatsukawa K, Hidaka E, Kudo SE. Internal hernia through the mesenteric opening after laparoscopy-assisted transverse colectomy. *Surg Laparosc Endosc Percutan Tech* 2005;**15**:177–9.
9. Saklani A, Naguib N, Tanner N, Moorhouse S, Davies CE, Masoud AG. Internal herniation following laparoscopic left hemicolectomy: an underreported event. *J Laparoendosc Adv Surg Tech A* 22:496–500.