

# Integra-based Reconstruction of Large Scalp Wounds: A Case Report and Systematic Review of the Literature

Maxwell B. Johnson, MS  
Alex K. Wong, MD, FACS

**Background:** Large complex scalp wounds that have traditionally required free vascularized tissue transfer have been successfully reconstructed with skin substitutes such as Integra. Although there are multiple reports of Integra-based reconstructions of scalp wounds, there has not been a comprehensive assessment of this body of literature that critically examines this method. Our goal was to conduct a systematic review to determine the effectiveness of Integra-based reconstructions of scalp wounds, with emphasis on large defects.

**Methods:** A comprehensive systematic review was completed using key search terms, including Integra, dermal regeneration template, bovine collagen, skin substitute, forehead, and scalp. Selected articles reported characteristics of patients and their reconstructions. The primary outcome measures were wound complications and percent graft take.

**Results:** Thirty-four articles were included in this systematic review. Wound sizes ranged from 5.7 to 610 cm<sup>2</sup>, with 35.3% of articles reporting a mean defect size >100 cm<sup>2</sup>. Thirty-two articles reported mean percent take of skin graft ≥90%. Sixteen articles reported a minor complication. There were no major complications associated with the reconstructions.

**Conclusions:** There is a substantial evidence base for the use of Integra to reconstruct scalp wounds. To date, the dermal regeneration template is generally reserved for salvage procedures or when the patient cannot tolerate free tissue transfer. Based on the findings of this systematic review and the authors' clinical experience, Integra can be used to achieve predictable results in large complex scalp defects. (*Plast Reconstr Surg Glob Open* 2016;4:e1074; doi: 10.1097/GOX.0000000000001074; Published online 24 October 2016.)

Reconstructive strategies for the management of scalp wounds are varied and determined by defect size, depth, and quality of regional tissue. Small wounds can be addressed with skin grafting and locoregional flaps or in some cases allowed to heal by secondary intention. Closure of larger defects may be facilitated by staged tissue expansion, whereas infected or previously irradiated wounds are best served by free vascularized tissue transfer.<sup>1</sup> These options, however, may not be suitable for all patients.<sup>2,3</sup>

Recently, there have been multiple reports documenting successful use of Integra (Integra LifeScience Corporation, Plainsboro, N.J.) dermal regeneration template in large scalp wounds. Integra is used widely in reconstructive procedures all over the body and is composed of a layer of bovine collagen crosslinked with glycosaminoglycan covered by a silastic membrane.<sup>4</sup> Infiltration of host cells into the collagen matrix forms a neodermis over the course of 3–6 weeks, at which point the silicone membrane is replaced with a split-thickness skin graft.<sup>5</sup> When applied properly, Integra can result in long-term engraftment with excellent cosmetic and functional results.<sup>6,7</sup> To date, there has not been a comprehensive analysis of the literature on the use of Integra for complex scalp wounds that would serve to guide practitioners toward best practices.

We present an illustrative case of Integra-based reconstruction for a large (>100 cm<sup>2</sup>) complex scalp wound. This is followed by a systematic review to evaluate and synthe-

From the Division of Plastic and Reconstructive Surgery, Department of Surgery, Keck School of Medicine of the University of Southern California, Los Angeles, Calif.

Received for publication August 4, 2016; accepted August 15, 2016.

Copyright © 2016 The Authors. Published by Wolters Kluwer Health, Inc. on behalf of The American Society of Plastic Surgeons. All rights reserved. This is an open-access article distributed under the terms of the Creative Commons Attribution-Non Commercial-No Derivatives License 4.0 (CCBY-NC-ND), where it is permissible to download and share the work provided it is properly cited. The work cannot be changed in any way or used commercially.

DOI: 10.1097/GOX.0000000000001074

**Disclosure:** The authors have no financial interest to declare in relation to the content of this article. The Article Processing Charge was paid for by the authors.

size the available literature on Integra-based reconstruction of scalp wounds. We wished to explore whether there was a critical defect size at which Integra was not reliable and thus paid particular attention to large defects, defined in this article as those defects that are  $\geq 100\text{ cm}^2$ . Furthermore, we sought to identify factors predisposing Integra-based reconstructions to complication and to identify best practices in the use of Integra for scalp wounds.

### CASE PRESENTATION

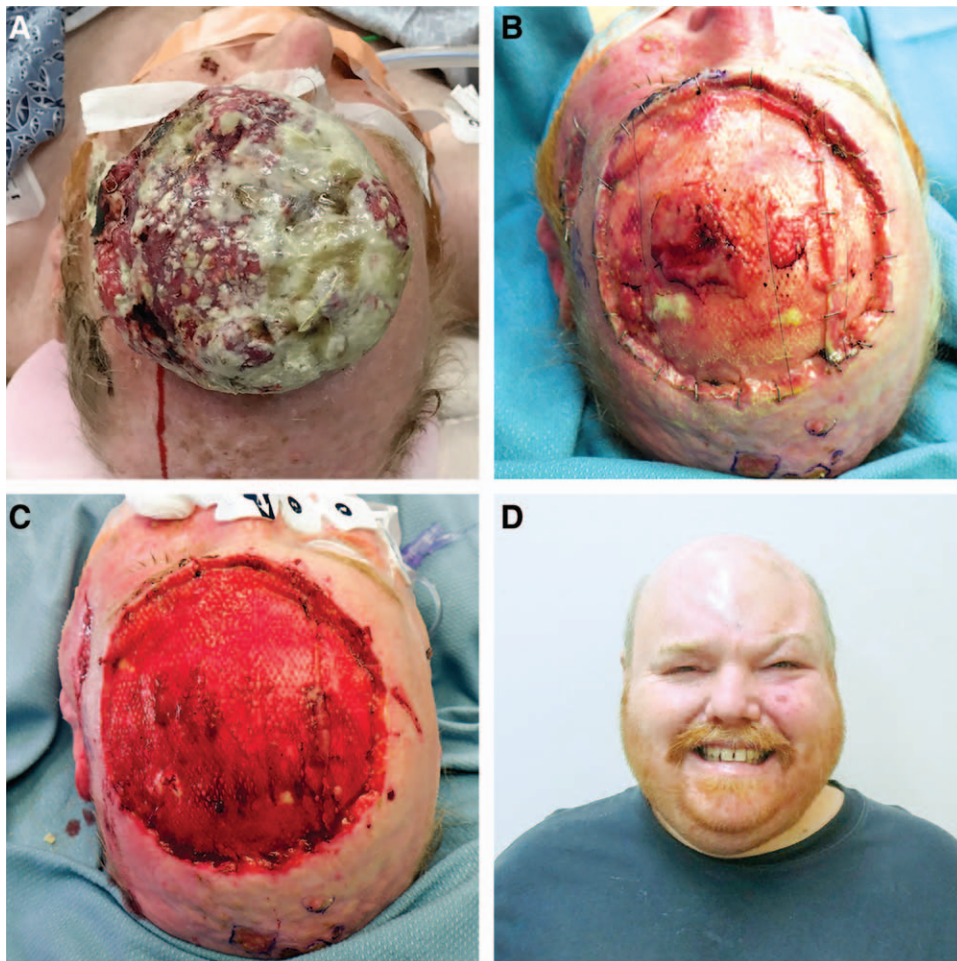
A 40-year-old man with history of intellectual disability and multiple preexisting medical conditions was referred to the plastic surgery service for definitive management and closure of a large scalp mass with bleeding and foul-smelling discharge (Fig. 1A). Per the patient's parents, the mass had been present for a year and a half and had grown over that period of time. On physical exam, a large  $64\text{ cm}^2$  ulcerated mass was noted over the patient's forehead and frontal scalp, with additional  $1\text{ cm}^2$  lesions on the left temporal region and dorsum of the left hand. A presumptive diagnosis of squamous cell carcinoma was made based on outside hospital

records, and the patient was taken to the operating room for definitive management. The scalp mass was excised down to calvaria, resulting in a  $144\text{ cm}^2$  scalp defect. The defect was reconstructed with fenestrated Integra after burring the calvaria. A wound vacuum-assisted closure (VAC) was used as the bolster dressing and removed on postoperative day 5. Pathology confirmed the diagnosis of squamous cell carcinoma. On readmission for second-stage reconstruction, the silastic membrane was removed and a healthy granulation bed was noted (Figs. 1B, C). A fenestrated split-thickness skin graft was applied and the patient was discharged home 6 days later. One hundred percent graft take was noted at subsequent clinic visits, with excellent cosmetic and functional results at follow-up at 244 days (Fig. 1D).

### MATERIALS AND METHODS

#### Literature Search and Study Selection

A systematic literature search was completed according to Preferred Reporting Items for Systematic Review and Meta-Analysis Protocols (PRISMA-P) guidelines (Fig. 1).<sup>8</sup>



**Fig. 1.** Photos of a patient undergoing Integra-based reconstruction of a large scalp defect. The patient is shown preoperatively (A), before removal of the silastic membrane (B), with a healthy granulation bed after removal of the silastic membrane before placement of skin graft (C), and on follow-up 244 days after initial reconstruction (D).

PubMed and Ovid were queried using the search terms “Integra AND (scalp OR forehead OR head)”, “bovine collagen AND (scalp OR forehead OR head)”, “skin substitute AND (scalp OR forehead OR head)”, and “dermal regeneration template AND (scalp OR forehead OR head)”. Additional references relevant to the review were retrieved from article reference lists. Inclusion and exclusion criteria are presented in Table 1. Two authors independently screened all articles for inclusion or exclusion.

**Table 1. Inclusion and Exclusion Criteria Utilized in This Systematic Review**

Inclusion criteria	
English	Studies where patients underwent Integra reconstruction of the forehead or scalp
Exclusion criteria	
Non-English	Studies that were review articles
Studies where patients underwent Integra reconstruction of sites other than the forehead or scalp	Studies where patients underwent reconstruction of the forehead or scalp with alternative skin substitutes
Studies with patients who had chronic illnesses predisposing them to reconstruction failure	Studies with insufficient information to abstract data
Animal studies	

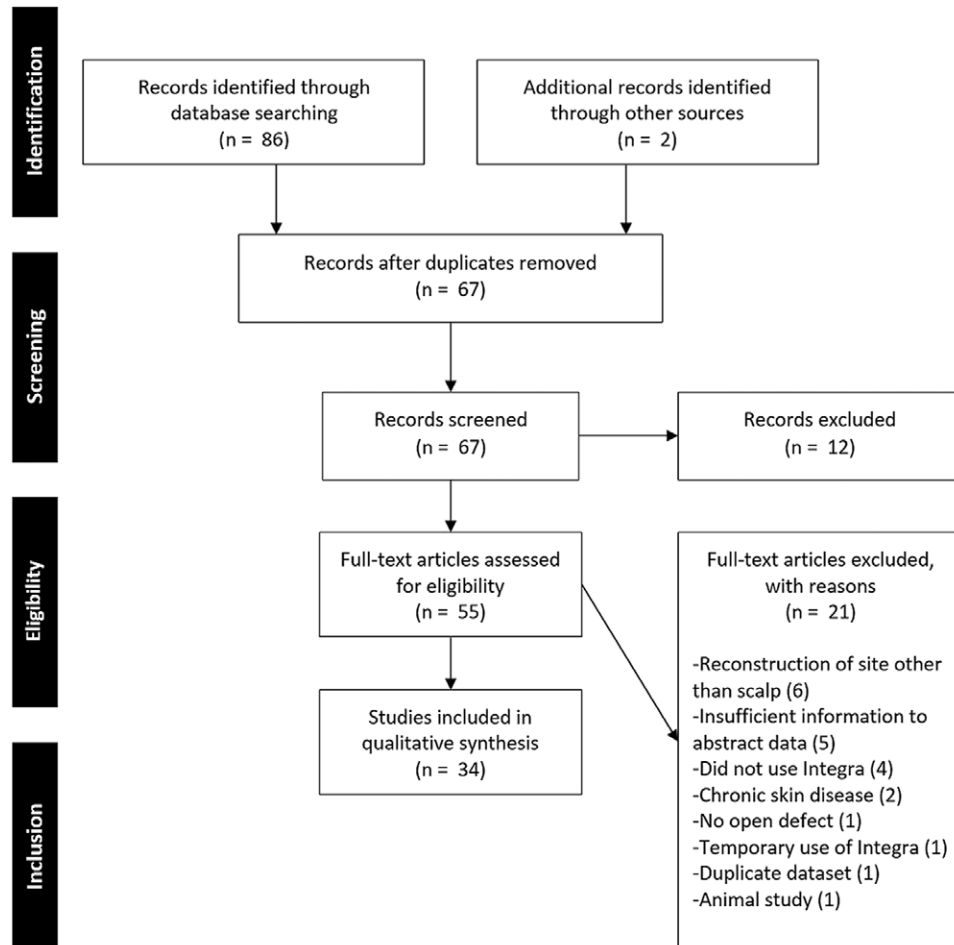
**Data Abstraction and Analysis**

Data were abstracted for a variety of preoperative, intraoperative, and postoperative details. Preoperative criteria included mean patient age, mean defect size, and indication for reconstruction. Intraoperative criteria included staging, bone burring, and Integra fenestration. Postoperative criteria included mean time to skin graft, adjuvant radiotherapy, complication, and mean percent graft take. In cases where mean percent take was not reported numerically, qualitative descriptors were used to estimate mean percent take. If graft take was described as “good” or “excellent,” it was converted to a mean percent take of 100%. Other descriptors were converted on a case-by-case basis. Studies not reporting specific patient or procedural details were removed from descriptive analysis for that detail. Given the limitations of the data, quantitative evaluation was not performed.

**RESULTS**

**Study Retrieval and Characteristics**

Eighty-six studies were identified through the initial database search, and 2 studies through article reference lists (Fig. 2). Abstracts for 67 studies were screened, and



**Fig. 2.** A PRISMA diagram detailing the method utilized to conduct this systematic review.

55 full-text articles were assessed for eligibility. Thirty-four studies met inclusion criteria for qualitative synthesis.<sup>9-43</sup>

**Preoperative Wound Characteristics**

The leading indication for reconstruction was resection of a malignant skin tumor (67.6%; Table 2). This was followed by trauma (17.6%), failed previous reconstruction (11.8%), burn (8.8%), radionecrosis (5.9%), infection (2.9%), and aplasia cutis congenita (2.9%). Patient age ranged from 0 to 93 years old, with 55.9% reporting a mean age over 65. In general, Integra was selected for reconstruction in elderly patients with multiple comorbidities.

Defects ranged in size from 5.7 to 610 cm<sup>2</sup>, with 12 studies reporting a mean defect size >100 cm<sup>2</sup> (Table 2). Percent take of Integra and/or skin graft ranged from 50% to 100%, with 94.1% reporting take ≥90%. Mean follow-up was 14 months.

**Outcomes of Integra-based Scalp Reconstruction**

The most common approach to Integra-based reconstruction is the staged approach, with initial application of the skin substitute followed by a split-thickness skin graft over the revascularized matrix at a later date. In this sys-

tematic review, 82.4% of studies utilized a staged approach (Table 3). Overall, staged reconstructions were successful, with 92.9% reporting average percent take ≥90%. Of the 11 staged studies with average defect size ≥100 cm<sup>2</sup>, all reported percent take >90%.

The timing of the second-stage of Integra reconstruction is largely dependent on the state of the granulation bed. If the matrix appears well-vascularized, the skin graft can be applied and expected to heal well. In this systematic review, 82.1% of studies reported a time to second stage ≤30 days (data not pictured). Five studies reported time to second stage >30 days.<sup>12,14,20,24,36,37</sup> All five reported a complication accounting for the delay.

Among staged reconstructions, 53.6% of studies reported complications in at least 1 patient (Table 3). Infection (17.9%) was the most common, followed by delayed healing (10.7%), incomplete adherence of the Integra (10.7%), radionecrosis after postoperative radiotherapy (10.7%), persistent contour defect (7.1%), hematoma (3.6%), seroma (3.6%), wound failure (3.6%), and ectropion (3.6%). Mean percent take for these studies ranged from 50% to 100%, with only 2 studies reporting mean percent take <90%.<sup>22,36</sup> Four studies with mean defect size ≥100 cm<sup>2</sup> reported complications.<sup>9,10,22,24</sup>

**Table 2. Preoperative Characteristics of Patients Undergoing Integra-based Reconstruction**

Reference	Defect Size (cm <sup>2</sup> )	No. of Patients	Age (y)	Follow-up (mo)	Indication	Percent Take (%)
Pannucci et al <sup>29</sup>	Unknown	23	66	23	Malignant skin tumor	97
Burd and Wong <sup>21</sup>	5.7	1	83	21	Malignant skin tumor	100
De Angelis et al <sup>41</sup>	20.2 ± 13.2	20	79.5 ± 5.1	3-6	Malignant skin tumor	100
Wain et al <sup>31</sup>	25	1	91	2	Malignant skin tumor	100
Gironi et al <sup>39</sup>	25.1	1	75	2	Malignant skin tumor	100
Fung et al <sup>37</sup>	32	1	69	14	Malignant skin tumor	90
Wrafter, <sup>43</sup>	32	1	79	Unknown	Trauma	100
Ahmed et al <sup>14</sup>	36	1	45	24	Malignant skin tumor	100
Singh et al <sup>30</sup>	36	1	Newborn	16	Aplasia cutis congenita	100
Singer et al <sup>40</sup>	50	1	7	5.7	Trauma	100
Wilensky et al <sup>13</sup>	51.4 ± 37.9	23	70.3 ± 14.9	Unknown	Malignant skin tumor	100
Momoh et al <sup>19</sup>	56	1	74	Unknown	Radionecrosis	100
Kosutic et al <sup>27</sup>	60.24	1	72	Unknown	Burn, failed reconstruction	100
Elledge et al <sup>36</sup>	61.9	8	Unknown	5.4 ± 3.3	Malignant skin tumor	70-100
Koenen et al <sup>18</sup>	62 ± 35	13	80 ± 10	6	Malignant skin tumor	100
Richardson et al <sup>42</sup>	63.2 ± 54	10	80 ± 9	16	Malignant skin tumor	99.8
Tufaro et al <sup>17</sup>	73 ± 47	7	53 ± 21.9	Unknown	Malignant skin tumor	97-100
Spector and Glat <sup>16</sup>	80	1	50	48	Trauma	100
McClain et al <sup>25</sup>	94.8 ± 61.4	5	67.2 ± 12.6	Unknown	Malignant skin tumor	95-100
Khan et al <sup>24</sup>	95	30	63	14	Malignant skin tumor	100
Komorowska-Timek et al <sup>12</sup>	97 ± 58	7	70 ± 14	14 ± 13	Malignant skin tumor, failed reconstruction	100
Orseck et al <sup>28</sup>	97.6 ± 83.1	13	61 ± 11.7	9	Malignant skin tumor, trauma, infection	100
Wang and To <sup>9</sup>	100	1	50	9	Failed reconstruction	90
Souéid and El-Tigani <sup>34</sup>	108.1 ± 116.5	4	85.5 ± 7.7	10.8 ± 6.3	Malignant skin tumor	90-100
Corradino et al <sup>23</sup>	143.3	8	81.5	24	Malignant skin tumor	100
Yeong et al <sup>15</sup>	150	2	16	12	Burn	100
	30		43			100
Ching and Gould <sup>26</sup>	150.8	1	70	Unknown	Malignant skin tumor	100
Chalmers et al <sup>22</sup>	164 ± 105	6	70 ± 13.9	16.8 ± 13	Malignant skin tumor	50-100
Navsaria et al <sup>11</sup>	180	1	26	12	Burn	100
Khan et al <sup>24</sup>	280	1	59	21	Trauma, failed reconstruction	100
Angelos et al <sup>33</sup>	300	1	50	12	Malignant skin tumor	100
Gonyon and Zenn <sup>10</sup>	400	2	20	15	Radionecrosis	100
	Unknown		67	9	Malignant skin tumor	100
Cunningham and Marks <sup>35</sup>	400	1	63	5	Malignant skin tumor	100
Konofaos et al <sup>38</sup>	610	1	0.2	12	Trauma	98

All values reported as mean ± SD where possible.

**Table 3. Postoperative Characteristics of Patients Undergoing Integra-based Reconstruction**

Reference	Defect Size (cm <sup>2</sup> )	No. Stages	Bone Burring	Integra Fenestration	Postoperative Radiotherapy	Complication	Percent Take (%)
Pannucci et al <sup>29</sup>	Unknown	2	No	Unknown	Unknown	Incomplete adherence	97
Burd and Wong <sup>21</sup>	5.7	1*	Unknown	Unknown	Unknown	None	100
De Angelis et al <sup>41</sup>	20.2±13.2	1*	No	Yes	Yes (1)	Hematoma (1), radionecrosis (1)	100
Wain et al <sup>31</sup>	25	2	Yes	No	No	None	100
Gironi et al <sup>39</sup>	25.1	1*	No	No	No	None	100
Wrafter, <sup>43</sup>	32	2	Yes	No	No	None	100
Fung et al <sup>37</sup>	32	2	Yes	No	No	Hematoma	90
Ahmed et al <sup>41</sup>	36	2	Yes	No	No	Delayed healing	100
Singh et al <sup>30</sup>	36	2	Yes	Yes	No	None	100
Singer et al <sup>40</sup>	50	1*	Yes	Unknown	No	None	100
Wilensky et al <sup>15</sup>	51.4±37.9	2	Unknown	Yes	No	Delayed healing (6), infection (5)	100
Momoh et al <sup>19</sup>	56	2	Yes	No	No	None	100
Kosutic et al <sup>27</sup>	60	1	Yes	No	No	None	100
	24						
Elledge et al <sup>36</sup>	61.9	2	Yes	Unknown	Unknown	Unknown	70–100
Koenen et al <sup>18</sup>	62±35	2	Yes	No	Yes (1)	Infection (1)	100
Richardson et al <sup>42</sup>	63.2±54	2	Unknown	Unknown	Yes (2)	Incomplete adherence (1), radionecrosis (1)	99.8
Tufaro et al <sup>17</sup>	73±47	2	Yes (4) No (3)	Yes	No	None	97–100
Spector and Glat <sup>16</sup>	80	2	No	No	No	None	100
McClain et al <sup>25</sup>	94.8±61.4	2	Unknown	No	Yes (1)	Radionecrosis (1), wound failure (1)	95–100
Khan et al <sup>24</sup>	95	2	Yes	No	Yes (3)	Infection (1), seroma (1)	100
Komorowska-Timek et al <sup>12</sup>	97±58	2	Yes (4) No (3)	Yes	Yes (1)	Contour defect (2)	100
Orseck et al <sup>28</sup>	97.6±83.1	2	Yes	Yes	No	Delayed healing (1)	100
Wang and To <sup>9</sup>	100	2	No	No	No	Infection, contour defect	90
Souéid and El-Tigani <sup>34</sup>	108.1±116.5	2	Yes	No	No	None	90–100
Corradino et al <sup>23</sup>	143.3	2	Yes	Yes (2) No (6)	No	None	100
Yeong et al <sup>15</sup>	150	2	Yes	No	No	None	100
	30						
Ching and Gould <sup>26</sup>	150.8	2	Unknown	Unknown	No	None	100
Chalmers et al <sup>22</sup>	164±105	2	Yes	No	Yes (1)	Radionecrosis (1)	50–100
Navsaria et al <sup>11</sup>	180	1*	No	No	No	Infection	100
Abbas Khan et al <sup>20</sup>	280	2	Yes	No	No	Incomplete adherence (1)	100
Angelos et al <sup>33</sup>	300	2	Yes	No	No	None	100
Gonyon and Zenn <sup>10</sup>	400	2	Yes	No	No	Ectropion (1)	100
	Unknown						
Cunningham and Marks <sup>35</sup>	400	2	No	No	No	None	100
Konofaos et al <sup>38</sup>	610	2	Yes	Yes	No	None	98

\*No split-thickness skin graft applied after Integra application.

All values reported as mean ± SD where possible. In cases where multiple patients are included in the study, the number of patients experiencing the descriptor is included in parentheses.

Seven studies included patients who underwent adjuvant radiotherapy after reconstruction.<sup>12,18,22,24,25,41,42</sup> Four reported subtotal radionecrosis, radiation-induced soft tissue breakdown, with eventual graft take of 100%.<sup>22,25,41,42</sup> In contrast, patients with preoperative radiotherapy of the wound bed had mixed results, with percent take as low as 50%.<sup>10,12,17,22,36</sup>

Six articles utilized a single-stage reconstructive approach.<sup>11,21,27,39–41</sup> Five of the 6 studies did not apply a skin graft,<sup>11,21,39–41</sup> while one applied both Integra and skin graft in the same procedure.<sup>27</sup> One case report performed one-stage reconstruction of a defect ≥100 cm<sup>2</sup>, reporting a minor infection in the postoperative period.<sup>11</sup> Percent take for one-stage studies was 100%.

**Effect of Bone Burring on Integra Scalp Reconstruction**

Bone burring of the calvaria before Integra placement encourages vascular ingrowth from the diploë into the

construct. Burring was employed in 74.2% of the studies included in this systematic review, with percent take ranging from 50% to 100% (Table 4).<sup>10,12,14,15,17–20,22–24,27,28,30–34,36–38,40</sup> Percent take was >90% in studies not employing bone burring.<sup>9,11,12,16,17,29,35,39,41</sup>

**Effect of Fenestration and Postoperative Bolster Technique on Integra Scalp Reconstruction**

Fenestrating Integra permits the egress of fluids, in theory reducing the risk of seroma or hematoma formation. Nine studies fenestrated the dermal regeneration template, with mean percent take ≥97% (Table 5).<sup>12,13,17,23,24,28,30,38,41</sup> Khan et al<sup>24</sup> and De Angelis et al<sup>41</sup> reported formation of small seroma and hematoma, respectively, not affecting final graft take. The remaining 22 articles using unfenestrated Integra reported percent take ranging from 50% to 100%.<sup>9–11,14–16,18–20,22–25,27,31–35,37,39,42</sup> Fung et al<sup>37</sup> reported hema-

**Table 4. The Effect of Bone Burring on Outcome of Integra-based Reconstruction**

Reference	Defect Size (cm <sup>2</sup> )	Percent Take (%)
Bone not burred before application of Integra		
Pannucci et al <sup>29</sup>	Unknown	97
De Angelis et al <sup>41</sup>	20.2 ± 13.2	100
Gironi et al <sup>39</sup>	25.1	100
Spector and Glat <sup>16</sup>	80	100
Tufaro et al <sup>17*</sup>	82.5 ± 40.9	100
Komorowska-Timek et al <sup>12*</sup>	97 ± 58	100
Wang and To <sup>9</sup>	100	90
Navsaria et al <sup>11</sup>	180	100
Cunningham and Marks <sup>35</sup>	400	100
Bone burred before application of Integra		
Wain et al <sup>31</sup>	25	100
Wrafter, <sup>43</sup>	32	100
Fung et al <sup>37</sup>	32	90
Ahmed et al <sup>14</sup>	36	100
Singh et al <sup>30</sup>	36	100
Singer et al <sup>40</sup>	50	100
Momoh et al <sup>19</sup>	56	100
Kosutic et al <sup>27</sup>	60	100
Tufaro et al <sup>17*</sup>	24	100
Elledge et al <sup>36</sup>	60 ± 60.6	100
Koenen et al <sup>18</sup>	61.9	70–100
Khan et al <sup>24</sup>	62 ± 35	100
Khan et al <sup>24</sup>	95	100
Komorowska-Timek et al <sup>12*</sup>	97 ± 58	100
Orseck et al <sup>28</sup>	97.6 ± 83.1	100
Souéid and El-Tigani <sup>34</sup>	108.1 ± 116.5	90–100
Corradino et al <sup>23</sup>	143.3	100
Yeong et al <sup>15</sup>	150	100
Chalmers et al <sup>22</sup>	30	50–100
Abbas Khan et al <sup>20</sup>	164 ± 105	100
Angelos et al <sup>33</sup>	280	100
Angelos et al <sup>33</sup>	300	100
Gonyon and Zenn <sup>10</sup>	400	100
Konofaos et al <sup>38</sup>	Unknown	100
Konofaos et al <sup>38</sup>	610	98

\*Study included patients with and without bone burring before application of Integra.  
All values reported as mean ± SD where possible. Defect size for subgroups calculated where possible.

toma formation under unfenestrated Integra resulting in 90% graft take.

Studies were divided on the basis of postoperative wound care method to evaluate its impact on outcome of Integra reconstruction (Table 6). VAC was the most common postoperative wound dressing (32%).<sup>19,22,24,27,28,33,35,38</sup> These studies reported percent take of 50–100%, with 87.5% of studies reporting percent take >98%. Bolstered dressings (28%) and silver-impregnated dressing materials (24%) were also popular, with percent take ≥90% in all cases. The remaining studies utilized a range of postoperative dressings. Notably, Gonyon and Zenn<sup>10</sup> were the only authors to report on the use of hyperbaric oxygen in the perioperative management of Integra-based reconstruction.

### DISCUSSION

There is a substantial body of literature supporting the use of Integra in a wide variety of reconstructive settings, including trauma, burns, and postoncologic resection.<sup>6,7</sup> Its popularity is largely due to its ability to provide effective and immediate closure to wounds without significant associated donor site morbidity and with low risk for scar

**Table 5. The Effect of Fenestration on Outcome of Integra-based Reconstruction**

Reference	Defect Size (cm <sup>2</sup> )	Percent Take (%)
Integra not fenestrated before application		
Wain et al <sup>31</sup>	25	100
Gironi et al <sup>39</sup>	25.1	100
Wrafter, <sup>43</sup>	32	100
Fung et al <sup>37</sup>	32	90
Ahmed et al <sup>14</sup>	36	100
Momoh et al <sup>19</sup>	56	100
Kosutic et al <sup>27</sup>	60	100
Koenen et al <sup>18</sup>	24	100
Koenen et al <sup>18</sup>	62 ± 35	100
Richardson et al <sup>42</sup>	63.2 ± 54	99.8
Spector and Glat <sup>16</sup>	80	100
McClain et al <sup>25</sup>	94.8 ± 61.4	95–100
Khan et al <sup>24</sup>	95	100
Wang and To <sup>9</sup>	100	90
Souéid and El-Tigani <sup>34</sup>	108.1 ± 116.5	90–100
Corradino et al <sup>23*</sup>	143.3	100
Yeong et al <sup>15</sup>	150	100
Yeong et al <sup>15</sup>	30	100
Chalmers et al <sup>22</sup>	164 ± 105	50–100
Navsaria et al <sup>11</sup>	180	100
Angelos et al <sup>33</sup>	300	100
Gonyon and Zenn <sup>10</sup>	400	100
Cunningham and Marks <sup>35</sup>	Unknown	100
Cunningham and Marks <sup>35</sup>	400	100
Integra fenestrated before application		
De Angelis et al <sup>41</sup>	20.2 ± 13.2	100
Singh et al <sup>30</sup>	36	100
Wilensky et al <sup>13</sup>	51.4 ± 37.9	100
Tufaro et al <sup>17</sup>	73 ± 47	97–100
Komorowska-Timek et al <sup>12</sup>	97 ± 58	100
Orseck et al <sup>28</sup>	97.6 ± 83.1	100
Corradino et al <sup>23*</sup>	143.3	100
Abbas Khan et al <sup>20</sup>	280	100
Konofaos et al <sup>38</sup>	610	98

\*Study included patients with and without Integra fenestration before placement, but insufficient data provided to perform subgroup calculations. All values reported as mean ± SD where possible.

contracture or hypertrophy.<sup>44</sup> Staging permits the use of Integra in poorly vascularized wounds, as the split-thickness skin graft is applied after neovascularization of the dermal regeneration template by host vessels.<sup>5</sup> Functional and cosmetic results are often excellent.<sup>6,7,45,46</sup> Of the 34 articles included in this review, 32 reported success rates ≥90%.

The initial impetus for reviewing the literature on scalp reconstruction using Integra was to determine if there was a maximal wound size where the dermal regeneration template could reliably be used. We found that relatively large scalp wounds can be successfully treated with Integra-based reconstruction as demonstrated by the presented case. Twelve studies reported mean defect size >100cm<sup>2</sup> across one- and two-stage reconstruction (Table 2). Eleven of these studies reported a mean percent take of ≥90%. We also found that large scalp wounds do not seem to have significantly more complications. Including both one- and two-stage reconstructions, approximately 41.7% of studies with large mean defect size reported at least one complication. This is comparable to the 45.5% of studies with smaller defects that reported complications. Thus, we believe that wound size alone should not prohibit the selection of Integra as a reconstructive option.

Although Integra can be effective in some types of poorly vascularized wound beds, our experience suggests

**Table 6. The Effect of Postoperative Wound Care Method on Outcome of Integra-based Reconstruction**

Reference	Defect Size (cm <sup>2</sup> )	Percent Take (%)
Bolstered dressing		
Burd and Wong <sup>31</sup>	5.7	100
De Angelis et al <sup>41</sup>	20.2 ± 13.2	100
Fung et al <sup>37</sup>	32	90
Ahmed et al <sup>14</sup>	36	100
Wilensky et al <sup>13</sup>	51.4 ± 37.9	100
Komorowska-Timek et al <sup>12</sup>	97 ± 58	100
Corradino et al <sup>23</sup>	143.3	100
Silver-impregnated dressing		
Singh et al <sup>30</sup>	36	100
Koenen et al <sup>18</sup>	62 ± 35	100
Tufaro et al <sup>17</sup>	73 ± 47	97–100
Spector and Glat <sup>16</sup>	80	100
Khan et al <sup>24</sup>	95	100
Wang and To <sup>9</sup>	100	90
Vacuum-assisted closure		
Momoh et al <sup>19</sup>	56	100
Kosutic et al <sup>27</sup>	60	100
	24	100
Orseck et al <sup>28</sup>	97.6 ± 83.1	100
Chalmers et al <sup>22</sup>	164 ± 105	50–100
Abbas Khan et al <sup>20</sup>	280	100
Angelos et al <sup>33</sup>	300	100
Cunningham and Marks <sup>35</sup>	400	100
Konofaos et al <sup>38</sup>	610	98
Other dressing material		
McClain et al <sup>25</sup>	94.8 ± 61.4	95–100
Richardson et al <sup>42</sup>	63.2 ± 54	99.8
Yeong et al <sup>15</sup>	150	100
	30	
	400	
Gonyon and Zenn <sup>10</sup>	Unknown	100

All values reported as mean ± SD where possible. Only studies reporting wound care methods are included.

that preoperative radiotherapy is a relative contraindication to its use. There is substantial evidence to suggest that irradiation reduces number and function of cells critically involved in wound healing.<sup>47–49</sup> Given that the revascularization of Integra is dependent on host cell migration and proliferation, we feel that preoperative radiotherapy's effect on the wound bed predisposes Integra reconstruction to failure. Although there are isolated reports of successful use of Integra in irradiated scalp wounds, the extent of radiation damage was variable.<sup>10,12,17,22</sup> Mean percent graft take for these patients ranged from 50% to 100%, and at least one patient experienced 30% breakdown by 22 months.<sup>12</sup> Although we do not recommend the use of Integra in irradiated wounds, it may be possible to achieve stable coverage in areas with limited damage. Hyperbaric oxygen may improve outcomes in selected cases, though we do not believe it can be applied in a predictable fashion.<sup>10,12</sup> In the senior author's practice, microsurgical free flap reconstruction in large previously irradiated scalp defects is preferred.

Interestingly, postoperative irradiation after Integra-based reconstruction appears to be well tolerated. Seven studies included patients who underwent adjuvant radiotherapy of the reconstruction site.<sup>12,18,22,24,25,41,42</sup> Although some patients experienced mild acute radiodermatitis and/or radionecrosis, outcomes were largely good with reported mean percent take of graft in excess of 95%. This

demonstrates the durability of Integra reconstruction and suggests that Integra is a viable reconstructive approach to wounds that may require future adjuvant radiotherapy.

The standard approach to Integra reconstruction requires 2 stages: the Integra forms a neodermis via ingrowth of host vessels, followed by the application of a thin split-thickness skin graft at a later date. The benefits of staging include the ability to use Integra in poorly vascularized wounds, where the direct application of a skin graft might otherwise fail. This staged approach was used by 82.4% of studies in this review, with the majority reporting time to second stage of <30 days (Table 3). Of these staged studies, 53.6% reported complications (Table 3). The need for multiple operations, however, can carry significant risk for some patients. Additionally, donor sites for skin grafts of appropriate size may be limited. Accordingly, 6 studies employed a single-stage reconstructive approach, ranging in publication date from 2004 to 2015.<sup>11,21,27,39–41</sup> Navsaria et al<sup>11</sup> were the first to describe single-stage Integra reconstruction in a patient with a full-thickness burn of the scalp, ear, face, and left arm. Foregoing a skin graft altogether, Navsaria et al<sup>11</sup> applied Integra followed by hair micrografting directly into the dermal regeneration template 12 days later. Despite a minor infection in the postoperative period, the patient achieved 100% graft take on follow-up. Although results of the one-stage procedures are positive, this is likely due to relatively small wound sizes. In general, it is the authors' opinion that a staged procedure should be used when possible, as it provides effective and durable results for all defect sizes.

Tissue overlying denuded bone without pericranium or fascia is unlikely to survive. Under these circumstances, the vessel-rich diploë is often exposed by burring the outer table of the calvaria. This has been shown to promote wound healing and is a relatively benign procedure.<sup>50</sup> It is particularly common when reconstructing defects postoncologic resection, when the thin subcutaneous tissues of the scalp are often removed to achieve adequate margins. Approximately 74.2% of studies in this systematic review burred the calvaria before Integra placement (Table 4). Of the studies employing bone burring, 90.9% reported graft take of ≥90%. Two studies—again Chalmers et al<sup>22</sup> and Elledge et al<sup>36</sup>—reported graft take of <90%. Interestingly, mean percent take of studies not burring bone was also >90%, though it is possible that wounds included in this calculation may have had residual pericranium or other sources of vascular ingrowth. De Angelis et al,<sup>41</sup> for example, covered denuded bone with locoregional pericranial flaps before application of the dermal regeneration template. Although it can have an impact on final contour, in cases where the calvaria is denuded or desiccated, bone burring is the optimal preparation for Integra placement.

Fenestration of Integra permits fluid egress, reducing the risk of hematoma or seroma formation and subsequent graft failure. Only 9 studies in this systematic review employed fenestration, all reporting percent take >97% (Table 5). Khan et al<sup>24</sup> and De Angelis et al<sup>41</sup> reported small seroma and hematoma formation, respectively, in 1 patient with fenestrated Integra that

was resolved by evacuation with a syringe, resulting in 100% graft take at follow-up. Studies utilizing unfenestrated Integra reported percent take ranging from 50% to 100%. Fung et al<sup>37</sup> did not fenestrate Integra before application and reported hematoma formation resulting in 10% graft failure. Although fenestration of skin grafts can result in unsatisfactory cosmetic results, Integra's staged approach permits fenestration without substantial impact on final site appearance. As a result, it is the authors' opinion that Integra should always be fenestrated before application.

Similar to fenestration, subatmospheric pressures generated by VAC also promotes fluid egress, reduces wound edema, enhances perfusion, and promotes the formation of a granulation bed.<sup>51</sup> Accordingly, it was the most popular bolster method used in this systematic review, including studies with the largest mean defect sizes (Table 6). Cunningham and Marks<sup>35</sup> reported 100% graft take in a patient with a 400 cm<sup>2</sup> wound who was treated postoperatively with VAC. Similarly, Kono-faos et al<sup>38</sup> reported 98% graft take in a pediatric patient with total scalp avulsion resulting in a 610 cm<sup>2</sup> defect. Although beneficial to wounds of all sizes, by assisting with drainage and promoting ingrowth of host vessels, VAC therapy was likely a crucial component of the positive outcomes in these large scalp defects. Given these findings, we believe VAC to be the best way to manage the wound postoperatively when practical.

As highlighted by this systematic review, there is a significant amount of outcomes data for Integra-based scalp reconstructions, the majority of which demonstrate clear and positive results. To date, however, there has been no systematic and critical evaluation of this body of literature. Although we put forth significant effort to extract objective and quantitative data from each of the articles, a limitation of this review is that there was no normalization of the wounds studied. If a consistent preoperative grading scale was available, a more quantitative analysis of outcomes (ie, meta-analysis) may have been possible. Based on our review, much of the existing published data are from salvage therapy cases or situations in which other options are not appropriate. A favorable results profile in these high-risk wounds supports continued use of Integra when the appropriate wound and patient are chosen. Under these circumstances, Integra-based reconstructions of the scalp can be safe, reliable, and esthetic. Although all reconstructive approaches must be chosen on a case-by-case basis, this systematic review and the authors' experience with Integra suggest that predictable results can be achieved with use of the dermal regeneration template in the scalp.

Alex K. Wong, MD

Division of Plastic and Reconstructive Surgery  
Department of Surgery  
Keck School of Medicine of the University of Southern California  
1510 San Pablo Street  
Suite 415  
Los Angeles, CA 90033  
E-mail: Alex.Wong@med.usc.edu

## PATIENT CONSENT

*The patient provided written consent for the use of his image.*

## REFERENCES

- Hussussian CJ, Reece GP. Microsurgical scalp reconstruction in the patient with cancer. *Plast Reconstr Surg.* 2002;109:1828–1834.
- Serletti JM, Higgins JP, Moran S, et al. Factors affecting outcome in free-tissue transfer in the elderly. *Plast Reconstr Surg.* 2000;106:66–70.
- Rudolph R. Complications of surgery for radiotherapy skin damage. *Plast Reconstr Surg.* 1982;70:179–185.
- Jones I, Currie L, Martin R. A guide to biological skin substitutes. *Br J Plast Surg.* 2002;55:185–193.
- Moiemen NS, Staiano JJ, Ojeh NO, et al. Reconstructive surgery with a dermal regeneration template: clinical and histologic study. *Plast Reconstr Surg.* 2001;108:93–103.
- Heimbach D, Luterma A, Burke J, et al. Artificial dermis for major burns. A multi-center randomized clinical trial. *Ann Surg.* 1988;208:313–320.
- Heimbach DM, Warden GD, Luterma A, et al. Multicenter postapproval clinical trial of Integra dermal regeneration template for burn treatment. *J Burn Care Rehabil.* 2003;24:42–48.
- Moher D, Shamseer L, Clarke M, et al; PRISMA-P Group. Preferred reporting items for systematic review and meta-analysis protocols (PRISMA-P) 2015 statement. *Syst Rev.* 2015;4:1.
- Wang JC, To EW. Application of dermal substitute (Integra) to donor site defect of forehead flap. *Br J Plast Surg.* 2000;53:70–72.
- Gonyon DL Jr, Zenn MR. Simple approach to the radiated scalp wound using INTEGRA skin substitute. *Ann Plast Surg.* 2003;50:315–320.
- Navsaria HA, Ojeh NO, Moiemen N, et al. Reepithelialization of a full-thickness burn from stem cells of hair follicles micrografted into a tissue-engineered dermal template (Integra). *Plast Reconstr Surg.* 2004;113:978–981.
- Komorowska-Timek E, Gabriel A, Bennett DC, et al. Artificial dermis as an alternative for coverage of complex scalp defects following excision of malignant tumors. *Plast Reconstr Surg.* 2005;115:1010–1017.
- Wilensky JS, Rosenthal AH, Bradford CR, et al. The use of a bovine collagen construct for reconstruction of full-thickness scalp defects in the elderly patient with cutaneous malignancy. *Ann Plast Surg.* 2005;54:297–301.
- Ahmed S, Hussein SS, Philp B, et al. Use of biologic dressing as a temporary wound dressing in reconstruction of a significant forehead Mohs defect. *Dermatol Surg.* 2006;32:765–767.
- Yeong EK, Huang HF, Chen YB, et al. The use of artificial dermis for reconstruction of full thickness scalp burn involving the calvaria. *Burns* 2006;32:375–379.
- Spector JA, Glat PM. Hair-bearing scalp reconstruction using a dermal regeneration template and micrograft hair transplantation. *Ann Plast Surg.* 2007;59:63–66.
- Tufaro AP, Buck DW 2nd, Fischer AC. The use of artificial dermis in the reconstruction of oncologic surgical defects. *Plast Reconstr Surg.* 2007;120:638–646.
- Koenen W, Goerdts S, Faulhaber J. Removal of the outer table of the skull for reconstruction of full-thickness scalp defects with a dermal regeneration template. *Dermatol Surg.* 2008;34:357–363.
- Momoh AO, Lypka MA, Echo A, et al. Reconstruction of full-thickness calvarial defect: a role for artificial dermis. *Ann Plast Surg.* 2009;62:656–659.
- Abbas Khan MA, Chipp E, Hardwicke J, et al. The use of dermal regeneration template (Integra®) for reconstruction of a large full-thickness scalp and calvarial defect with exposed dura. *J Plast Reconstr Aesthet Surg.* 2010;63:2168–2171.



21. Burd A, Wong PS. One-stage Integra reconstruction in head and neck defects. *J Plast Reconstr Aesthet Surg*. 2010;63:404–409.
22. Chalmers RL, Smock E, Geh JL. Experience of Integra® in cancer reconstructive surgery. *J Plast Reconstr Aesthet Surg*. 2010;63:2081–2090.
23. Corradino B, Di Lorenzo S, Leto Barone AA, et al. Reconstruction of full thickness scalp defects after tumour excision in elderly patients: our experience with Integra dermal regeneration template. *J Plast Reconstr Aesthet Surg*. 2010;63:e245–e247.
24. Khan MA, Ali SN, Farid M, et al. Use of dermal regeneration template (Integra) for reconstruction of full-thickness complex oncologic scalp defects. *J Craniofac Surg*. 2010;21:905–909.
25. McClain L, Barber H, Donnellan K, et al. Integra application for reconstruction of large scalp defects. *Laryngoscope* 2011;121:S353.
26. Ching JA, Gould L. Giant scalp melanoma: a case report and review of the literature. *Eplasty* 2012;12:e51.
27. Kosutic D, Beasung E, Dempsey M, et al. Single-layer Integra for one-stage reconstruction of scalp defects with exposed bone following full-thickness burn injury: a novel technique. *Burns* 2012;38:143–145.
28. Orseck MJ, Trujillo MG Jr, Ritter EF. Screw fixation of dermal regeneration template for scalp reconstruction. *Ann Plast Surg*. 2012;68:457–460.
29. Pannucci CJ, Collar RM, Johnson TM, et al. The role of full-thickness scalp resection for management of primary scalp melanoma. *Ann Plast Surg*. 2012;69:165–168.
30. Singh M, Bui CJ, St-Hilaire H. Reconstruction of complex aplasia cutis congenita. *J Craniofac Surg*. 2012;23:e88–e90.
31. Wain RA, Shah SH, Senarath-Yapa K, et al. Dermal substitutes do well on dura: comparison of split skin grafting +/- artificial dermis for reconstruction of full-thickness calvarial defects. *Clin Plast Surg*. 2012;39:65–67.
32. Abstracts of the RAMI (Royal Academy of Medicine in Ireland) Section of Interns Study Day of the Royal College of Physicians of Ireland. January 26, 2013. *Ir J Med Sci*. 2013;182(Suppl 5):S144–S178.
33. Angelos TM, Larsen MT, Janz BA. Nodular basal cell carcinoma arising in a split-thickness skin graft of the scalp. *Ann Plast Surg*. 2013;71:372–374.
34. Souéid A, El-Tigani E. The role of dermal regeneration template “Integra®” in reconstructive skin cancer surgery. *Eur J Plast Surg*. 2013;36:247–250.
35. Cunningham T, Marks M. Vacuum-assisted closure device and skin substitutes for complex Mohs defects. *Dermatol Surg*. 2014;40(Suppl 9):S120–S126.
36. Elledge R, Lloyd-Rogers J, Barnard NA. Integra® dermal regeneration template in the reconstruction of complex scalp defects: initial experiences at Worcestershire Royal Hospital. *Br J Oral Maxillofac Surg*. 2014;52:e105.
37. Fung V, Chalmers RL, Geh JL. Scalp reconstruction using Integra, an alternative to free tissue transfer—case report. *OALibj*. 2014;1:1–5.
38. Konofaos P, Kashyap A, Wallace RD. Total scalp reconstruction following a dog bite in a pediatric patient. *J Craniofac Surg*. 2014;25:1362–1364.
39. Gironi LC, Boggio P, Colombo E. Reconstruction of scalp defects with exposed bone after surgical treatment of basal cell carcinoma: the use of a bilayer matrix wound dressing. *Dermatol Ther*. 2015;28:114–117.
40. Singer M, Korsh J, Predun W, et al. A novel use of Integra™ bilayer matrix wound dressing on a pediatric scalp avulsion: a case report. *Eplasty* 2015;15:e8.
41. De Angelis B, Gentile P, Tati E, et al. One-stage reconstruction of scalp after full-thickness oncologic defects using a dermal regeneration template (Integra). *Biomed Res Int*. 2015;2015:698385.
42. Richardson MA, Lange JP, Jordan JR. Reconstruction of full-thickness scalp defects using a dermal regeneration template. *JAMA Facial Plast Surg*. 2016;18:62–67.
43. Wrafter, PF. Management of Traumatic Full Thickness Scalp Wound With Dermal Regeneration Template (Integra) Application to Exposed Pericranium in a Patient with Brooke-Spiegler Syndrome. *Ir J Med Sci*. 2013;182:173.
44. Frame JD, Still J, Lakhel-LeCoadou A, et al. Use of dermal regeneration template in contracture release procedures: a multicenter evaluation. *Plast Reconstr Surg*. 2004;113:1330–1338.
45. Dantzer E, Braye FM. Reconstructive surgery using an artificial dermis (Integra): results with 39 grafts. *Br J Plast Surg*. 2001;54:659–664.
46. Faulhaber J, Felcht M, Teerling G, et al. Long-term results after reconstruction of full thickness scalp defects with a dermal regeneration template. *J Eur Acad Dermatol Venereol*. 2010;24:572–577.
47. Illsley MC, Peacock JH, McAnulty RJ, et al. Increased collagen production in fibroblasts cultured from irradiated skin and effect of TGF beta(1)- clinical study. *Br J Cancer*. 2000;83:650–654.
48. Liu X, Liu JZ, Zhang E, et al. Impaired wound healing after local soft x-ray irradiation in rat skin: time course study of pathology, proliferation, cell cycle, and apoptosis. *J Trauma*. 2005;59:682–690.
49. Miller SH, Rudolph R. Healing in the irradiated wound. *Clin Plast Surg*. 1990;17:503–508.
50. Latenser J, Snow SN, Mohs FE, et al. Power drills to fenestrate exposed bone to stimulate wound healing. *J Dermatol Surg Oncol*. 1991;17:265–270.
51. Argenta LC, Morykwas MJ. Vacuum-assisted closure: a new method for wound control and treatment: clinical experience. *Ann Plast Surg*. 1997;38:563–76; discussion 577.