

## Functional Medicine

## Laparoscopic Management of Pelvic Organ Prolapse in a Kidney Transplant Recipient

Jean Rouffilange<sup>a,\*</sup>, Maxime Deslandes<sup>a</sup>, Laurent Lopez<sup>b</sup><sup>a</sup> Urology Department, CHU Pellegrin, Place Amélie Raba-léon, Bordeaux, France<sup>b</sup> Urology Department, Clinique St Augustin, 114 Avenue d'Arès, Bordeaux, France

## ARTICLE INFO

Article history:  
Received 12 March 2017  
Accepted 20 April 2017

Keywords:  
Laparoscopy  
Kidney transplant  
Prolapse

## ABSTRACT

This is a report of a laparoscopic double mesh sacrocolpopexy performed in the setting of a 73-year-old woman carrying a grafted kidney. The patient had a vaginal prolapse of the anterior and posterior floor without urinary incontinence. Despite immunosuppression due to anti-rejection treatments and the presence of kidney transplant in left iliac fossa, laparoscopic intervention with the introduction of prosthetic material was conducted. The intervention showed no major difficulty in its implementation and the postoperative course was uneventful. The long-term follow-up will confirm the tolerance of a prosthetic material.

© 2017 The Authors. Published by Elsevier Inc. This is an open access article under the CC BY-NC-ND license (<http://creativecommons.org/licenses/by-nc-nd/4.0/>).

## Introduction

The prevalence of pelvic organ prolapse (POP) is high. Patients interested in undergoing parallel renal transplantation are increasingly older. How do we manage this particular situation? Here, we propose laparoscopic management of POP in a kidney transplant.

## Case presentation

The patient is 73 year old with a history of renal transplantation with disabling POP. Kidney transplantation in the left iliac fossa was performed 3 years ago due to kidney failure of undetermined origin.

The patient's response to questionnaire revealed debilitating symptoms with pain and pelvic heaviness without urinary incontinence. The only potential POP risk factor in this patient was a history of two natural deliveries, without instrumented labor. There were no digestive symptoms. No smear or mammography was collected during follow-up. The subject was postmenopausal since age 55 and received an immunosuppressant as her exclusive treatment, which included a calcineurin inhibitor, an inhibitor of inosine 5'-monophosphate dehydrogenase, and steroids.

Clinical examination showed a POP with Grade 4 cystocele, Grade 3 hysterocoele, and Grade 2 rectocele, according to the Baden–Walker classification. The tone of the levator muscle was

estimated at 3/5. In the abdominal region, a Mc Burney scar on the right side and transplant procedure scar on the left side were identified. There were no transit disorders (no constipation), and sexual relations were reported as rare.

No urinary incontinence before and after reduction of the POP was reported, and the urethral sphincter closing pressure was low (39 cm/H<sub>2</sub>O).

Renal function was a stable state with preoperative creatinine at 70 μmol/L and a urea to 10 mmol/L (clearance 64.7 mL/min).

Because of the patient's persistence of a rare sexual activity and her preference, a laparoscopic rather than vaginal surgical approach was preferred.

Sacrocolpopexy associated with the treatment of the posterior floor was performed under general anesthesia. Prophylactic

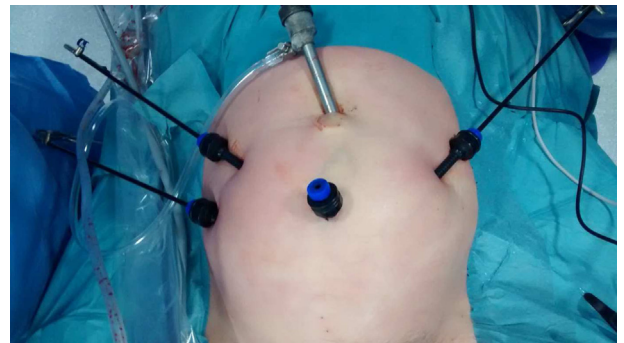
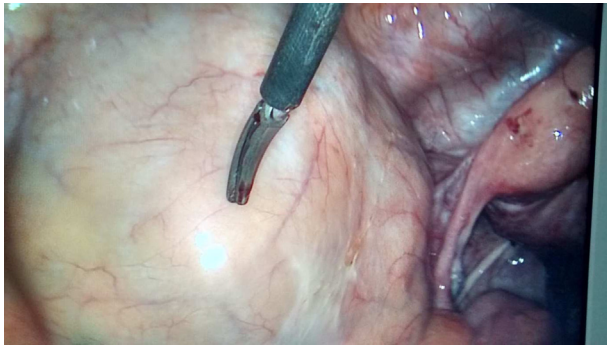


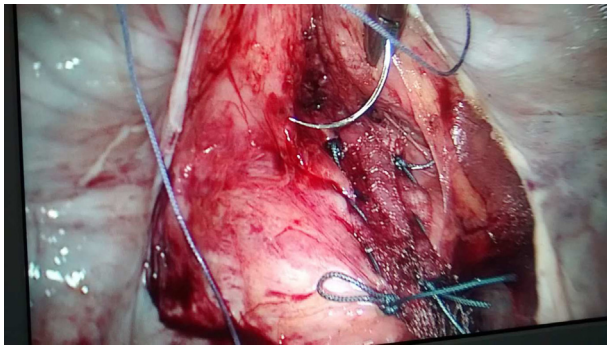
Figure 1. Positioning of the abdominal trocar.

\* Corresponding author.

E-mail address: [jean22rouffilange@hotmail.com](mailto:jean22rouffilange@hotmail.com) (J. Rouffilange).



**Figure 2.** Kidney transplant in the left iliac fossa.



**Figure 3.** Bladder dissection.

antibiotics were administered, as recommended by the French Association of Urology in this indication (first-generation cephalosporin [Cephazolin]).

We established a rear plate fixed without tension on the lifters and a front plate attached to the cervix and the anterior vaginal wall by using a nonbraided absorbable wire. The purpose of the intervention was to identify the graft to avoid injury when inserting the left trocar. Therefore, the graft was spotted after the careful positioning of the camera trocar and the cranial portion of the graft, with the vessels and ureter being left positioned at the lateral and lower portion of the graft, respectively (Figs. 1 and 2). A careful dissection of the bladder was then conducted to avoid injury to the neo-located ureter (Fig. 3). We did not insert a ureteral stent before the surgery.

The procedure took 90 min to complete, and 50 cc of blood loss was collected.

The postoperative course was uneventful; the probe was removed after 2 days and the patient was discharged the day after.

The first follow-up was conducted at 3 months postoperatively, and the clinical assessment was strictly normal. The gynecologic examination did not reveal prolapse, and the patient's sexual activity had resumed.

From a renal standpoint, clearance was stable without change from the preoperative state. Indeed, postoperative creatinine was 74  $\mu\text{mol/L}$  and urea was 12  $\text{mmol/L}$  (clearance 61.2  $\text{mL/min}$ ). We have not performed ultrasound to measure postvoid residual.

## Discussion

This is the first report of a pelvic reconstructive surgery using a laparoscopic approach performed on a renal transplanted patient.

Genital prolapse could lead to a decrease in quality of life. The prevalence of POP varies between 2.9% and 11.4% in questionnaire-based studies and from 31.8% to 97.7% according to the International Continence Society Pelvic Organ Prolapse Classification anatomic classifications.<sup>1</sup> Moreover, the cumulative incidence of surgery for POP is as high as 70% in women over the age of 70.<sup>2</sup>

Heit et al estimated the prevalence and severity of urinary incontinence and its impact on daily living activity in kidney transplant recipients.<sup>3</sup> A total of 123 patients were interviewed, 28% of whom reported urinary incontinence. Therefore, urinary incontinence alone might have less impact on daily living activity in renal transplant recipients than in nontransplanted incontinent women with similar severe incontinence. Unfortunately, POP data were not compiled in past medical histories. Two other studies evaluated POP treatment on renal transplant recipients. Hoda et al and Shveiky et al reported 21 transplanted patients who underwent pelvic reconstructive surgery for POP<sup>4,5</sup>; a vaginal approach was used in all patients. No operative complications were recorded, and the follow-up showed excellent clinical outcomes.

POP may complicate the mid-term and long-term course of renal transplantation, because it may be associated with postvoid residual urine, urgency, recurrent urinary tract infections, and pad use. Prolapse surgery in renal transplanted women is technically possible with apparently good outcomes, although limited data exist on the subject. The choice of vaginal prolapse as a repair technique remains controversial. Laparoscopy has established its use in functional vaginal surgery, with results comparable to those of the lower tract. Nevertheless, two major advantages to not open the vagina in this indication are the persistence of sexual activity and the risk of infection. Indeed, even if the rate of erosion is similar in the literature between the two techniques, the presence of immunosuppressive treatments impairs wound healing, and the contact of the prosthesis with the vaginal scar area is something that we have considered in favor of a laparoscopy.

The limitation of this technique in this specific indication was the development of prosthetic material in an immunocompromised patient. The prosthesis infection risk remains to be assessed in this case. Moreover, no publications on the technique and its pitfalls are available to our knowledge.

## Conclusion

Laparoscopic management of prolapse in this renal transplant patient, as well as the use of mesh, was achieved without complications in the short and medium term. A case series and long-term data are required.

## Conflict of interest

No conflict.

## References

1. Nygaard I, Barber MD, Burgio KL, et al. Prevalence of symptomatic pelvic floor disorders in US women. *JAMA*. 2008;300(11):1311–1316.
2. Lousquy R, Costa P, Delmas V, Haab F. [Update on the epidemiology of genital prolapse]. *Prog En Urol J Assoc Fr Urol Société Fr Urol*. 2009;19(13):907–915.
3. Heit M, Blackwell L, Thomas S, Ouseph R. Prevalence and severity of urinary incontinence in kidney transplant recipients. *Obstet Gynecol*. 2004;103(2):352–358.
4. Hoda MR, Wagner S, Greco F, et al. Pelvic organ prolapse management in female kidney transplant recipients. *J Urol*. 2010;184(3):1064–1068.
5. Shveiky D, Blatt A, Sokol AI, et al. Pelvic reconstructive surgery in renal transplant recipients. *Int Urogynecol J Pelvic Floor Dysfunct*. 2009;20(5):551–555.