



# Isolated paediatric orbital fractures: a case series and review of management at a major trauma centre in the UK

Patrick Harrison<sup>1</sup> · Safiya Hafeji<sup>1</sup> · Alexandra O. Green<sup>1</sup> · Anthony D. Chellappah<sup>1</sup> · Kathleen Fan<sup>1,2</sup>

Received: 20 January 2022 / Accepted: 6 March 2022

© The Author(s), under exclusive licence to Springer-Verlag GmbH Germany, part of Springer Nature 2022

## Abstract

**Purpose** Paediatric orbital fractures are rare. Existing literature demonstrates wide variation in estimates of incidence, aetiology, management protocols and outcomes. Despite this, it is generally acknowledged that orbital fractures with entrapment of the extraocular muscles constitute a surgical emergency due to the potential for persistent diplopia secondary to muscle ischaemia and necrosis.

**Methods** This retrospective study was conducted to determine the characteristics and outcomes of management of orbital fractures amongst the paediatric population. It involved patients presenting to a major trauma unit in London between 2010 and 2020.

**Results** Thirteen patients with isolated orbital fractures presented to our unit in this period. The average age was 13 years. Surprisingly the predominant aetiology was interpersonal violence. The most common fracture pattern involved the orbital floor and medial wall. One medial wall fracture case was missed in the emergency department.

Eight patients required surgical intervention due to diplopia caused by muscular entrapment of extraocular muscles; the final patient had a large defect resulting in enophthalmos requiring a large titanium plate. A transconjunctival approach was preferred for surgical access and resorbable sheet was used in the remaining cases. Five patients had nausea, vomiting or bradycardia associated with the oculocardiac reflex. Surgical intervention occurred within 24–48 h of injury in 6 cases. Resolution of diplopia occurred in 7 patients within 6 months.

**Conclusion** Paediatric patients with orbital fractures should be assessed on the day of injury by a maxillofacial surgeon. Due to the risk of persistent diplopia, urgent surgical intervention in patients with entrapment of extraocular muscles should occur as soon as possible.

**Keywords** Trauma · Orbit · Fracture · Paediatric · Facial injury

## Introduction

Facial fractures are uncommon amongst the paediatric population. This is particularly true when compared to orthopaedic injuries sustained by children and to the incidence of facial fractures amongst adults. The reported incidence of

paediatric facial fractures ranges between 1 and 15% [1]. The most common facial fractures amongst children involve the dental alveolus and nasal bone [2].

Reasons for this include protection afforded by the relative prominence of the calvarium in early childhood, which results in a high skull to face ratio with paediatric patients more susceptible to skull fractures than facial fractures. Furthermore, it has been suggested that the elasticity of the juvenile bones, flexible suture lines, lack of maxillary and ethmoidal sinus pneumatization, the presence of the developing tooth buds and a thicker layer of adipose tissue contribute to the lower incidence of facial fractures occurring in childhood [3, 4]. The influence of increased parental supervision during childhood may also contribute to the low incidence of these injuries. The majority of paediatric facial fractures occur

✉ Patrick Harrison  
patrick.harrison6@gmail.com

✉ Kathleen Fan  
kfan@nhs.net

<sup>1</sup> Oral and Maxillofacial Surgery Department, King's College Hospital NHS Foundation Trust, Denmark Hill, London SE1 9RT, UK

<sup>2</sup> Faculty of Dentistry, Oral & Craniofacial Sciences, King's College London, London, UK

secondary to slips and falls, sporting mishaps and road traffic accidents rather than interpersonal violence [5].

Amongst the adult population, there remains controversy regarding indications, approaches and choice of implant for the treatment of orbital fracture [6–8]. Due to the sparsity of these injuries amongst the paediatric population there are fewer studies describing the management of these injuries. There is no definitive consensus, national or international guidelines regarding the management of paediatric orbital fractures.

Adult patients commonly experience orbital ‘blow out’ fractures. This term describes a fracture of the orbital floor or medial wall with an intact rim and herniation of orbital contents into the adjacent sinuses. Paediatric patients, however, are at risk of ‘trapdoor’ fractures. The elastic orbital walls fracture and flex with displacement of periorbital fat and extraocular muscles into the sinus cavities before spontaneously reducing to their pre-injury position. This entraps the herniated orbital contents within the fracture line and results in characteristic sign of diplopia secondary to mechanical restriction of extraocular muscle function. Whilst the thin nature of the orbital floor makes it the most frequently fractured orbital wall amongst children, trapdoor fractures are not restricted to the orbital floor and can also occur in the adult population [9].

Features of orbital fractures can include pain and restriction of ocular movement. Commonly, this presents as a limitation in superior gaze and occurs due to involvement of the inferior rectus muscle and or periorbital tissue within an orbital floor fracture line. Often, in trapdoor-type fracture patterns, there are limited clinical findings on initial examination, minimal oedema or ecchymosis, and thus where the name “white-eyed” orbital fracture comes from. Open or comminuted orbital fractures may present with oedema, ecchymosis and with soft tissue displacement even hypoglobus or enophthalmos [9].

The aims of this retrospective study were to review isolated orbital fractures in the paediatric population at King’s College Hospital London, a level 1 trauma unit, over a 10-year period and evaluate the outcome of those patients who underwent surgical exploration, to compare results with previous international studies and aid in the future development of guidelines and recommendations for the management of these injuries locally and nationally.

## Materials and methods

The Oral and Maxillofacial Surgery Unit at King’s College Hospital is the sole referral centre for all maxillofacial injuries in South East London and its surrounds. King’s College

Hospital is also a major trauma centre serving an inner-city population of around 700,000. The department receives around 3000 referrals from the emergency department per year. There are 9 consultant oral and maxillofacial surgeons within the department and 8 are involved in the management of facial trauma.

The departmental database was reviewed and all patients who sustained orbital fractures between 2010 and 2020 were identified. The Accident and Emergency (A&E) Department database was also reviewed to identify any other patients who may have been assessed within the A&E setting and discharged without any outpatient follow-up scheduled. There were also cases included that were a direct referral to the unit.

The medical records of patients with isolated orbital fractures who were 16 years of age or younger at the time of presentation were then assessed. All patients with orbital fractures presenting to King’s College Hospital are additionally assessed by an ophthalmologist pre-operatively and post-operatively. These electronic records were also sought and reviewed.

Isolated orbital fractures were considered to be those that include the orbital floor and/or medial wall. Patients with lateral wall, roof or associated facial fractures such as zygomaticomaxillary complex or incorporated cranial vault fractures were excluded.

The patient’s age at the time of presentation, gender and mechanism of the injury were recorded along with pre-operative visual acuity, diplopia, restriction of extraocular movements, enophthalmos, hypoglobus and sensory disturbances. The presence of associated symptoms such as nausea, vomiting and bradycardia was also noted. Radiographic evidence of orbital fracture was evaluated by review computed tomography (CT) images.

Operative intervention was performed under general anaesthesia. The time to surgery from the time of injury to the commencement of anaesthesia was recorded. The surgical approach to the orbital cavity and material used for orbital reconstruction were documented.

Post-operative visual acuity, HESS charts, time until resolution of diplopia, need for further intervention and duration of follow-up were also noted.

## Results

Over a 10-year period there were 13 patients with isolated orbital wall fractures who attended King’s College Hospital. The age range of these patients was 5–16 (mean 12.5). Of these, 9 patients had surgical management of their fractures.

The mean age for surgical patients ( $n=9$ ) was 12.1 years (range 5–16) with 78% being male. An orbital floor fracture was found in 78% of injuries. The most common fracture

**Table 1** Mechanism of injury ( $n=13$ )

Mechanism of injury	Number	Percentage (%)
Sport	2	15%
Assault	5	38%
RTC	3	23%
Fall	2	15%
Accidental injury	1	8%

pattern was medial wall and floor with 4 patients (44%), 3 patients had isolated floor fractures (33%) and 2 patients had isolated medial wall (22%).

In the non-operative group ( $n=4$ ) two patients had isolated orbital floor fractures. Two patients had isolated medial wall fractures.

The aetiology of patients who presented with fractures, both surgical and non-surgical managed, are outlined in Table 1 ( $n=13$ ). Accidental injury included 1 patient who had a collision in the playground.

### Clinical findings

In the surgical group, diplopia was present in initial assessment in 9 cases (100%). Visual acuity was documented within normal range in 7 cases (78%) and reduced in 2 cases (22%). Globe injury was found in 2 cases (22%). Restriction in ocular movement was present in all but one patient whom underwent surgery and detailed in Table 2. The one that did not had a large defect with enophthalmos, associated diplopia on upward gaze. A large, preformed titanium plate was used in this patient.

On presentation, 7 patients presented with no obvious signs of ocular injury and thus “white eye” fracture pattern. Five patients (56%) had extraocular signs such as nausea and vomiting, 3 of those patients (33%) exhibited the oculocardiac reflex with documented bradycardia.

Pre-operative CT imaging in surgical patients ( $n=9$ ) revealed linear fractures present in 78% ( $n=7$ ) with remainder being open fractures ( $n=2$ ). Rectus muscle was entrapped on 4 (45%) patients. Three patients (33%) were reported having of possible entrapment. Seven patients had radiographic reports of fat entrapment.

**Table 2** Restricted ocular movements ( $n=9$ )

Reduced ocular movement	Number	Percentage (%)
Superiorly	5	56%
Medial	2	22%
Lateral	1	11%
Normal ocular movement	1	11%

In the non-surgical group ( $n=4$ ), none of the patients had diplopia, restricted ocular movement or vomiting.

### Procedure

Regarding the time from injury to surgery, 5 of the 9 cases were operated on within 24 h. One case was operated on within 48 h. Three cases were delayed; two were operated on day 17 post-injury following an outpatient maxillofacial review. The final case was operated 51 days after initial injury, again after outpatient review. The basic demographics, presentation, imaging and follow-up of patients undergoing surgical exploration are shown in Table 3.

All surgical cases were managed via transconjunctival approach ( $n=9$ ). Eight of these cases were repaired with resorbable 0.25- or 0.5-mm-thick polydioxanone implant (PDS sheet). In 1 case (11%), performed at day 51, a large, preformed orbital titanium Synthes plate was used.

### Follow-up

In the operative group, length of follow-up ranged from 1 to 18 months and is still ongoing in 1 case. No follow-up documentation was seen for 1 patient.

Five of the surgical patients (56%) had complete resolution of diplopia by 6 weeks. Two patients (22%) had resolution by 6 months. Unfortunately for 1 patient, no follow-up documentation was found. One patient had mild diplopia at 5-month follow-up and is still currently under review as an outpatient.

### Discussion

Two peaks have been identified for the incidence of paediatric facial fractures in the literature: ages 6–7 and 12–14 [10–12]. Our data revealed a similar age variation within the operative group with two peaks at ages 5–8 and 13–16 years. The first peak is thought to be due to starting primary school, and second associated with an increase in participation in organised sport according to Hink et al. [10]. However, we found that the causality of the second peak in our study was due to interpersonal violence. This is in contrast to what Zimmermann et al. found, with interpersonal violence being a rare cause of facial fractures in children [11]. In our study, 67% of those aged 13 or over who required surgery due to orbital fracture (4 patients) sustained their injury through interpersonal violence. The reasons for this are not clear but given the inner-city location of King’s College Hospital and referring centres, it may reflect the crime rate, living standards and deprivation of the surrounding boroughs [13]. Child abuse and assault are rare causes of orbital fracture in children; however, Sidpra et al. found that cases of abusive

**Table 3** Outline demographics, presentation, imaging and follow-up of patients undergoing surgical exploration

Patient	Age	Sex	Side	Fracture location	Fracture type	Evidence rectus entrapment on CT	Diplopia	Limitation of gaze	N+V	Bradycardia	Time from injury to surgery	Post-operative resolution of diplopia
1	13	M	L	Floor	Trapdoor	Yes	Yes	Restricted upward gaze	Yes	Yes	< 24 h	< 6 months
2	5	M	L	Floor	Trapdoor	Yes	Yes	Restricted upward gaze	Yes	Yes	< 24 h	< 6 weeks
3	15	F	L	Floor and medial wall	Trapdoor	No	Yes	Restricted upward gaze	Yes	Yes	< 24 h	Minor diplopia at 5 months
4	16	M	L	Floor and medial wall	Trapdoor	Yes	Yes	Restricted upward gaze	Yes	No	< 24 h	< 6 months
5	8	M	R	Medial wall	Open	Yes	Yes	Restricted abduction	Yes	No	< 48 h	< 6 weeks
6	14	F	L	Floor	Trapdoor	Yes	Yes	Restricted upward gaze	No	No	< 24 h	< 6 weeks
7	16	M	R	Medial wall	Trapdoor	Yes	Yes	Restricted adduction	No	No	17 days	< 6 weeks
8	16	M	R	Floor and medial wall	Trapdoor	Yes	Yes	Restricted adduction	No	No	17 days	Presumed. No follow-up seen
9	6	M	L	Floor and medial wall	Open	Yes	Yes	No restriction	No	No	51 days	< 6 weeks

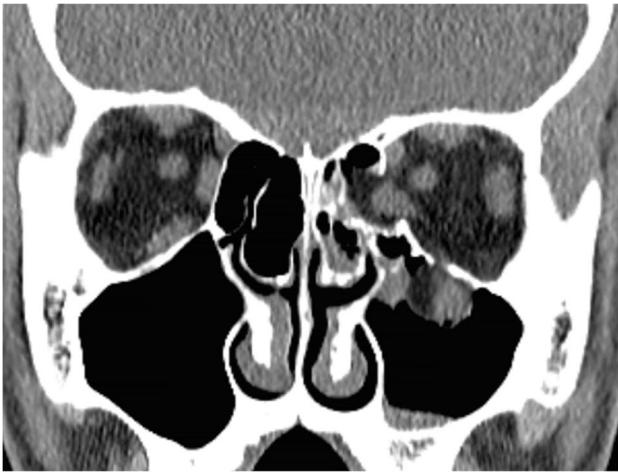
head trauma in children secondary to domestic violence have increased by 1493% during the coronavirus (SARS-CoV-2) pandemic [14]. The assessing clinician should have a high level of suspicion if the history or explanation does not reflect the injuries sustained. Violence in children aged 16 or below in our study is evident. It is therefore vital to continue education on the impact and potential consequences of interpersonal violence.

Entrapment of orbital muscles has been found to be more common in paediatric patients than adults [15]. Entrapment can lead to ischaemia of the ocular muscles and this can lead to permanent damage of due to Volkmann’s contracture [16]. Contracture of the entrapped muscle may lead to a long-term visual impairment, hence the reason that orbital floor fractures in paediatric patients are considered a surgical emergency.

Radiographically there is much variation in patients with orbital fractures. In this paper we have divided fractures into trapdoor (linear type) or open. Within trapdoor-type, patients can be broadly divided into two groups: those with tissue incarceration in the fracture line and those without [9]. In non-displaced fractures there is very little radiographic evidence. Air in the orbit or blood in the adjacent maxillary sinus may be indicators. In orbital floor fractures, there may be a small amount of tissue that appears below the floor of the orbit, this is termed the “tear drop” sign. This can be seen in Fig. 1. Depending on the resolution of the images, it can be identified as periorbital tissue which may include rectus muscle, but often it can be difficult to distinguish [9]. The same can also be seen in medial wall fractures.

In our series seven patients had linear trapdoor fractures. Two others had open fractures, one of the medial wall (patient 5) and one of the floor and medial wall (patient 9). One patient had an isolated medial wall trapdoor fracture (patient 7). Isolated medial wall fractures are not well documented in the literature, but the most common pattern described is a blowout fracture. The lamina papyracea of the ethmoidal bone on the medial orbital wall is thin and is in a similar arrangement to the adult skull by the age of 4; thus, fractures occurring in this region tend to be of blow-out pattern in a similar fashion to fractures occurring in adult patients [17]. However, paediatric trapdoor fractures of the medial wall do occur but are very rare [18]. Just like trapdoor fracture of the orbital floor, entrapped muscle can lead to ischaemia; thus, these patients should be managed in the same fashion as trapdoor fractures of the orbital floor. In both patients with isolated medial wall fractures in this series (patients 5 and 7), resolution of diplopia occurred within 6 weeks.

In relation to entrapment, the oculocardiac reflex can result from orbital trapdoor fractures. This was first described by Sires et al. Bradycardia, nausea and vomiting were seen in a small series of patients [19]. Given the



**Fig. 1** Coronal CT image of a patient with left medial wall and orbital floor trapdoor fracture with inferior rectus muscle entrapment

dangers of bradycardia and other fatal arrhythmias, it must be identified early [9]. Three cases in our series were found to have bradycardia on assessment; none required intensive care support or inotropic support pre-surgery and all were operated on within 24 h.

Bradycardia has been shown by Cohen et al. to be useful in identification of entrapment. He also identified that those patients who present with nausea and vomiting are at high risk of inferior rectus entrapment and had poorer outcomes [20]. Nausea and vomiting were a common feature of our operative group (56%) as also noted in other series, leading to operative management of the fracture [21–23]. None of the non-operative group suffered from nausea or vomiting, giving the overall the incidence at 38.5%, similar to that of Heggie et al., although other previous series report marginally lower ranging between 21 and 27.6% [20, 21, 23, 24]. Regarding the non-operative group, none of the patients had diplopia or ocular restriction.

Diplopia was present in all operative cases with gaze restriction present in 89% before their surgery. Seven out of the nine operative patients had full resolution of resolution of diplopia at 6 months. One patient who sustained an orbital floor and medial wall fracture whilst playing netball exhibited vertical and horizontal diplopia on primary gaze and additional torsional affect on upward gaze. She still had mild diplopia at extreme gaze 5 months post-operative and is still being followed by the department. One patient unfortunately, no follow-up documentation was found, and he was not contactable.

There were two cases with ocular trauma; one case punctate epithelial erosions secondary to a foreign body in eye which was removed by an ophthalmologist. The second revealed traumatic mydriasis with probable vitreous prolapse

around the inferior lens. Classically, like other series, our data has shown that paediatric orbital wall fractures present few associated ocular features, hence fit with the term called white-eyed blowout fracture [23]. Nevertheless, ocular injuries may occur alongside orbital wall fractures and complete ophthalmic review is recommended if fracture present [22, 25].

During surgery implants were used in all cases. Eight of these were resorbable PDS sheets. The main indication for these resorbable implants is the additional layer of protection it provides, to prevent any further restriction of periorbital tissue. The final implant was a large titanium Synthes plate; this was required to reconstruct the anatomy of the orbital floor due to the open-fracture pattern. Clinical findings during surgery often were not specific when describing what tissue, muscle or fat, was included within the fracture line. Simply it was described most as “entrapped contents released”.

Timing of surgery for paediatric orbital floor is crucial for a number of reasons. Oculocardiac reflex can cause a potentially unstable patient who is at risk of arrhythmia and haemodynamic compromise. Necrosis of ocular muscles leading to diplopia is a devastating and potentially lifelong sequela of this type of injury if not managed promptly. Timing of repair remains controversial; Wei and Durairaj recommended that surgery is performed within 48 h of injury in paediatric orbital floor fractures [26]. Others have found that outcomes such as resolution of diplopia and gaze restriction were significantly improved in patients who were treated with surgery within 24 h [27]. Our series is too small to extrapolate and claim that early intervention has improved outcomes. Five patients were operated on within 24 h of injury. Patient 2 was operated approximately 9 h from time of injury and patient 6 was operated on approximately 18 h after injury. Both had resolution of diplopia within 6 weeks of injury. Patient 1 and patient 4 were operated on approximately 20.5 and 24 h after injury respectfully and both had resolution of diplopia at 6 months. Patient 3 was operated at approximately 22.75 and still had some mild diplopia at 5 months on upward gaze and has ongoing review. Of these 5 cases, the cases that were performed sooner did have better outcomes with regards to resolution of diplopia.

One case was operated on within 48 h of injury and had resolution of diplopia within 6 weeks. Of the delayed cases ( $n = 3$ ), patient 7 was initially discharged from the emergency department (ED), as there was no fracture reported on imaging. They represented 2 days later to ED and were referred to ophthalmology due to partial ophthalmoplegia. Ophthalmology then referred the patient to our oral and maxillofacial surgery team. The patient was found to have a medial wall fracture with rectus entrapment. This patient had resolution of diplopia within 6 weeks post-surgery. Medial wall fractures are not as common as orbital floor fractures,



but appropriate assessment in ED can help to avoid cases being missed.

The second delayed case, patient 8, was initially admitted at a referring hospital for head injury observation. The patient was then seen in clinic and then listed for surgery. In this case, initial transfer to the maxillofacial surgery unit may have expedited his surgery. His diplopia is assumed to have improved; however, this patient did not attend his follow-up appointments. Dunphy et al. report a case where a patient was admitted and initially diagnosed with a head injury due to nausea and vomiting following trauma to his orbit [28]. Unfortunately, this led to a delay in the surgery to release the entrapped ocular muscle. This highlights the importance of performing an ophthalmic assessment in the emergency department and prompt maxillofacial review.

Finally, the last delayed case, patient 9, operated on at day 51 was an open fracture, with associated diplopia and enophthalmos. In this case there was a more ‘adult’ fracture pattern; diplopia had improved by 6 weeks after the procedure.

The limitations of this study are clear. Despite a large volume of trauma patients seen, with around 3000 referrals per annum, isolated paediatric orbital injuries are rare. Nevertheless, the suspicion and prompt identification of orbital fracture in children, including medial orbital injury, is essential, particularly with trapdoor-type injuries and may be less vital with the ‘open’-type fracture pattern. This paper nevertheless adds to the current literature with further cases of paediatric orbital trauma requiring surgical intervention and hopefully will add to available data to enable in the development of guidelines and recommendations for the management of these injuries.

## Conclusion

Paediatric orbital wall fractures are a rare injury that may involve orbital floor and or medial wall. They can have potential life-changing complications associated with them. Unusually interpersonal violence was the most common cause of injury in our series. Patients should be assessed by a maxillofacial surgeon on the day on injury, with appropriate imaging. Extraocular signs such as nausea and vomiting and bradycardia help identify patient with orbital fractures and may be a useful indicator for those who require surgery. Medial wall fractures should not be missed and thorough assessment and imaging can help to avoid this. Surgical intervention for paediatric trapdoor-type injury should be as soon as possible and ideally within 24 h. Full ophthalmic review should be performed pre- and post-surgical intervention.

**Author contribution** Conception and design of study/case series: A. C., K. F., P. H.; acquisition of data: laboratory or clinical/literature search: P. H., S. H., A. G., A. C.; analysis and interpretation of data collected: P. H., A. C., K. F.; initial draft: P. H. and A. C.; manuscript revision: P. H., A. C., K. F., A. G., S. H.; final approval and guarantor of manuscript: P. H., S. H., A. G., A. C., K. F.

**Funding** Patrick Harrison received a personal grant for work on this project by British Association of Oral and Maxillofacial Surgery. This was part of their Student Bursary Award for second degree medical and dental students. The other authors declare that no funds, grants, or other support were received during the preparation of this manuscript.

## Declarations

**Ethics approval** This is an observational study. The local audit office has confirmed that no ethical approval is required.

**Consent to participate** No patient identifiable information is included in this article. Therefore, this does not apply in this article.

**Consent for publication** No patient identifiable information is included in this article. Therefore, this does not apply in this article.

**Competing interests** The authors declare no competing interests.

## References

- Gassner R, Tarkan T, Hachl O et al (2004) Craniomaxillofacial trauma. In children: A review of 3, 385 cases with 6, 6060 injuries in 10 years. *J Oral Maxillofac Surg* 62:399–407 n.d
- Kidd A, Beattie T, Campbell-Hewson G (2010) Facial injury patterns in a UK paediatric population aged under 13 years. *Emerg Med J* 27:603–6 n.d
- Kaban LB (1993) Diagnosis and treatment of fractures of the facial bones in children 1943–1993. *J Oral Maxillofac Surg* 51:722–9 n.d
- Anderson PJ (1995) Fractures of the facial skeleton in children. *Injury* 26:47–5 n.d
- Vujcich N, Gebauer D (2018) Current and evolving trends in the management of facial fractures. *Aust Dent J* 63:S35–S47 n.d
- Dubois L, Steenan S, Gooris P et al (2015) Controversies in orbital reconstruction. I—Defect driven orbital reconstruction: a systematic review. *Int J Oral Maxillofac Surg* 44:308–15 n.d
- Dubois L, Steenan S, Gooris P et al (2015) Controversies in orbital reconstruction. II—Timing of post-traumatic orbital reconstruction: a systematic review. *Int J Oral Maxillofac Surg* 44:433–40 n.d
- Dubois L, Steenan S, Gooris P et al (2016) Controversies in orbital reconstruction. III—Biomaterials for orbital reconstruction: a review with clinical recommendations. *Int J Oral Maxillofac Surg* 45:41–50 n.d
- Phan LT, Jordan Piluek W, McCulley TJ (2012) Orbital trapdoor fractures. *Saudi J Ophthalmol* 26:277–282. <https://doi.org/10.1016/j.sjopt.2012.05.008>
- Hink EM, Wei LA, Durairaj VD (2014) Clinical features and treatment of pediatric orbit fractures. *Ophthal Plast Reconstr Surg* 30:124–131. <https://doi.org/10.1097/IOP.000000000000026>

11. Zimmermann CE, Troulis MJ, Kaban LB (2005) Pediatric facial fractures: recent advances in prevention, diagnosis and management. *Int J Oral Maxillofac Surg* 34:823–833. <https://doi.org/10.1016/j.ijom.2005.06.015>
12. Alcalá-Galiano A, Arribas-García JJ, Martín-Pérez MA, Romance A, Montalvo-Moreno JJ, Juncos JMM (2008) Pediatric facial fractures: children are not just small adults. *Radiographics* 28:441–461. <https://doi.org/10.1148/rg.282075060>
13. Office for national statistics (2019) English indices of deprivation 2019. London, n.d
14. Sidpra J, Abomeli D, Hameed B, Baker J, Mankad K (2021) Rise in the incidence of abusive head trauma during the COVID-19 pandemic. *Arch Dis Child* 106:e14–e14. <https://doi.org/10.1136/archdischild-2020-319872>
15. Kwon JH, Moon JH, Kwon MS, Cho JH (2005) The differences of blowout fracture of the inferior orbital wall between children and adults. *Arch Otolaryngol Neck Surg* 131:723. <https://doi.org/10.1001/archotol.131.8.723>
16. Smith B, Lisman RD, Simonton J, Rocca RD (1984) Volkmann's contracture of the extraocular muscles following blowout fracture. *Plast Reconstr Surg* 74:200–209. <https://doi.org/10.1097/00006534-198408000-00004>
17. Anderson PJ, Chellappah AD, David DJ (2010) Medial wall blow out fractures in children. *Asian J Oral Maxillofac Surg* 22:202–204. <https://doi.org/10.1016/j.ajoms.2010.02.004>
18. McCulley TJ, Yip CC, Kersten RC, Kulwin DR (2004) Medial rectus muscle incarceration in pediatric medial orbital wall trapdoor fractures. *Eur J Ophthalmol* 14:330–333. <https://doi.org/10.1177/112067210401400409>
19. Sires BS, Stanley RB, Levine LM (1960) Oculocardiac reflex caused by orbital floor trapdoor fracture: an indication for urgent repair. *Arch Ophthalmol Chic Ill* 1998(116):955–956
20. Cohen S (2003) Pediatric orbital floor fractures: nausea/vomiting as signs of entrapment. *Otolaryngol Head Neck Surg* 129:43–47. [https://doi.org/10.1016/S0194-5998\(03\)00487-X](https://doi.org/10.1016/S0194-5998(03)00487-X)
21. Egbert JE, May K, Kersten RC, Kulwin DR (2000) Pediatric orbital floor fracture. *Ophthalmology* 107:1875–1879. [https://doi.org/10.1016/S0161-6420\(00\)00334-1](https://doi.org/10.1016/S0161-6420(00)00334-1)
22. Carroll SC, Ng SGJ (2010) Outcomes of orbital blowout fracture surgery in children and adolescents. *Br J Ophthalmol* 94:736–739. <https://doi.org/10.1136/bjo.2008.155143>
23. Heggie AA, Vujcich NJ, Shand JM, Bordbar P (2015) Isolated orbital floor fractures in the paediatric patient: case series and review of management. *Int J Oral Maxillofac Surg* 44:1250–1254. <https://doi.org/10.1016/j.ijom.2015.02.019>
24. Bansagi ZC, Meyer DR (2000) Internal orbital fractures in the pediatric age group. *Ophthalmology* 107:829–836. [https://doi.org/10.1016/S0161-6420\(00\)00015-4](https://doi.org/10.1016/S0161-6420(00)00015-4)
25. Hatton MP, Watkins LM, Rubin PAD (2001) Orbital fractures in children. *Ophthal Plast Reconstr Surg* 17
26. Wei LA, Durairaj VD (2011) Pediatric orbital floor fractures. *J Am Assoc Pediatr Ophthalmol Strabismus* 15:173–180. <https://doi.org/10.1016/j.jaapos.2011.02.005>
27. Gerbino G, Roccia F, Bianchi FA, Zavattero E (2010) Surgical management of orbital trapdoor fracture in a pediatric population. *J Oral Maxillofac Surg* 68:1310–1316. <https://doi.org/10.1016/j.joms.2009.12.037>
28. Dunphy L, Anand P (2019) Paediatric orbital trapdoor fracture misdiagnosed as a head injury: a cautionary tale! *BMJ Case Rep* 12:e228739. <https://doi.org/10.1136/bcr-2018-228739>

**Publisher's note** Springer Nature remains neutral with regard to jurisdictional claims in published maps and institutional affiliations.