

Massive Necrotizing Fasciitis of the Chest Wall: A Very Rare Case Report of a Closed Thoracostomy Complication

Sangwook Chun, M.D., Gyeongho Lee, M.D., Kyoung Min Ryu, M.D., Ph.D.

Department of Thoracic and Cardiovascular Surgery, Dankook University Hospital, Cheonan, Korea

ARTICLE INFO

Received September 25, 2020

Revised October 18, 2020

Accepted October 20, 2020

Corresponding author

Kyoung Min Ryu

Tel 82-41-550-7640

Fax 82-41-550-7060

E-mail cskmin@naver.com

ORCID

https://orcid.org/0000-0001-8461-6010

We present a case study of necrotizing fasciitis (NF), a very rare but dangerous complication of chest tube management. A 69-year-old man with shortness of breath underwent thoracostomy for chest tube placement and drainage with antibiotic treatment, followed by a computed tomography scan. He was diagnosed with thoracic empyema. Initially, a non-cardiovascular and thoracic surgeon managed the drainage, but the management was inappropriate. The patient developed NF at the tube site on the chest wall, requiring emergency fasciotomy and extensive surgical debridement. He was discharged without any complications after successful control of NF. A thoracic surgeon can perform both tube thoracostomy and tube management directly to avoid complications, as delayed drainage might result in severe complications.

Keywords: Empyema, Chest tubes, Necrotizing fasciitis, Case report

Case report

A 69-year-old man was brought to the emergency room due to shortness of breath. The patient had diabetes and a history of cerebral infarction 10 years ago. The sequelae of cerebral infarction included slight motor weakness of the left leg that did not interfere with activities of daily life. He had received conservative treatment for symptoms such as myalgia, fever, and chills at a nearby hospital 2 weeks prior. He was transferred to Dankook University Hospital for shortness of breath that had started 1 day before admission. Left-sided hydrothorax was observed on an initial chest X-ray conducted in the emergency room. Conse-

quently, thoracostomy was performed for chest tube placement. The drainage was also very turbid. Subsequent chest computed tomography (CT) revealed left thoracic empyema (Fig. 1). Laboratory tests revealed an initial C-reactive protein level of 30.76 mg/dL, a white blood cell count of $15.71 \times 10^3/\mu\text{L}$, and a negative tuberculosis test result. A pleural fluid culture study, the results of which came back on the sixth hospital day, showed the growth of *Streptococcus constellatus* and an anaerobe. The patient was admitted with the chest tube, and ceftriaxone and clindamycin were used as empirical antibiotics. When the total amount of drainage reached 1 L on the day of admission, tube clamping was performed considering re-expansion

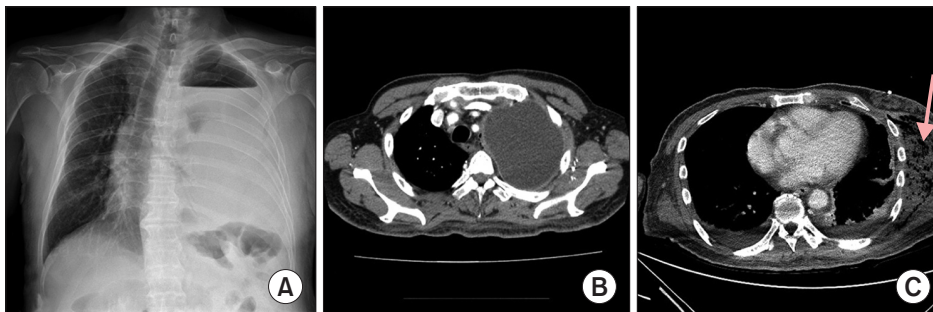


Fig. 1. (A) Initial chest X-ray. (B) Computed tomography (CT) revealing left thoracic empyema. (C) Preoperative chest CT; the arrow indicates necrotized muscle.

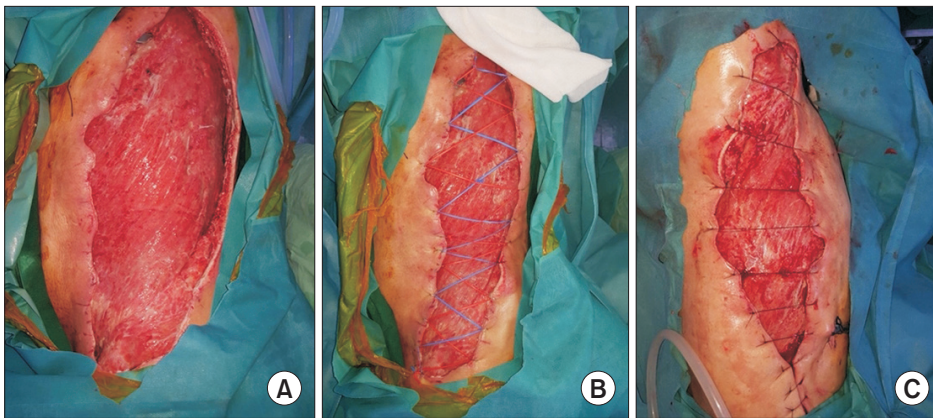


Fig. 2. Wound pictures. (A) Immediately postoperative. (B) Shoelace-sutured wound. (C) Before delayed wound repair.

edema. The next day, natural draining resumed. From that day onward, redness, warmth, swelling, and tenderness were observed in the left flank. On the following day, symptoms worsened, and another CT scan was performed. On chest CT, signs of infection, including gas formation, were found in the soft tissue and the muscle layer of the left chest wall (Fig. 1). At this point, an internal medicine doctor contacted cardiovascular and thoracic surgery department, and we performed surgery immediately, after making a diagnosis of necrotizing fasciitis (NF). Surgery was performed under general anesthesia, with the patient in the right lateral position. Wide sterilization and draping were performed from the axilla to the buttock. An approximately 60-cm horizontal incision was made along the left flank from the scapula tip to the anterior superior iliac spine. There was a large amount of pus, and the anatomy of the muscle was indistinguishable due to severe infective necrosis. Necrotic tissues were removed, including those at the subcutaneous tissue, latissimus dorsi, teres muscle, serratus anterior muscle, and gluteus muscle, using a scalpel and electrocautery (Fig. 2). The surgery was completed with an open-dressing using betadine wet gauze. NF was confirmed by pathology (Fig. 3). The antibiotics were switched to meropenem and vancomycin as empirical therapy. *Acinetobacter baumannii* complex growth was noted in cultures of samples collected during surgery; therefore, we changed vancomycin to tigecycline based on antibiotic sensitivity. Wound irrigation and open dressing were performed daily under consultation with the orthopedic surgery department. On postoperative day 6, we applied negative-pressure wound therapy. Extubation was performed on postoperative day 12, and the patient was transferred to the general ward. On postoperative day 35, delayed wound closure was performed. C-reactive protein levels decreased gradually after surgery and reached 0.31

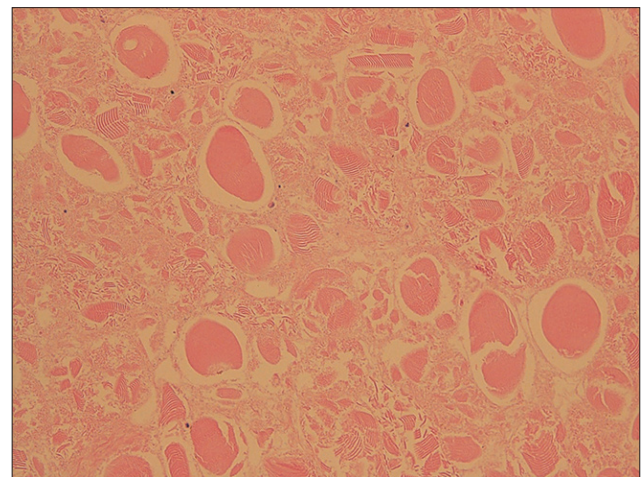


Fig. 3. Microscopic image of removed tissue reveals necrotic tissues without nuclei (H&E, $\times 200$).

mg/dL at discharge. The patient was discharged from the hospital on day 98 and currently continues to be monitored via follow-up through outpatient visits.

The study was approved by the Institutional Review Board of Dankook University Hospital (IRB approval no., 2020-09-018). The requirement for informed consent was waived.

Discussion

NF refers to extensive necrosis of the superficial fascia, resulting in widespread damage to the surrounding tissues and extreme systemic toxicity regardless of the specific bacterial etiology. NF was first described by Hippocrates in approximately 500 BC. Despite advances in understanding this disease and improvements in medical treatment, NF-related mortality remains high (at 25%–30%) and has

not improved significantly [1]. NF is caused not only by β -hemolytic streptococci, but also by a number of different organisms [2]. Therefore, in recent years, NF has been regarded a clinical entity, not a specific bacterial infection. The incidence of NF is nearly 1,000 cases per year in the United States. NF incidence has increased from 1980 to 2000, but the exact reason remains unclear. Although it is extremely rare, NF is a life-threatening condition requiring early aggressive intervention in the form of salvage.

The initial injuries are minor in 80% of NF patients. Recently, NF has been reported to occur predominantly at the extremities and on the trunk. Infection involves the subcutaneous tissue, but may extend downward to the fascia or muscle. The depth of the primary infection site is important and related to mortality [1]. The risk factors for polymicrobial NF include obesity, chronic renal failure, alcoholism, trauma, surgical incision, and indwelling catheters. The reason for NF in our case seems have been indwelling catheter-tube thoracostomy.

The signs and symptoms vary, including subcutaneous and fascial necrosis, cellulitis, edema, disorientation or apathy, and skin discoloration, with only 10%–40% of patients presenting these classic signs. Local erythema and swelling, along with pain, are the most common signs of NF [1].

Radiographic modalities are sometimes needed to confirm the diagnosis of NF. CT is the most sensitive diagnostic modality because it can show inflammatory changes such as fascial edema, thickening, abscesses, and gas formation. In our case, CT showed necrotized muscle with gas formation. Although radiologic modalities are advanced and conventionally used, surgery remains the gold standard modality for the diagnosis of NF.

The basic treatment for NF is surgical debridement. Some studies have reported that the most important determinant of mortality is the timing and adequacy of initial debridement. Wong et al. [3] reported a 9-fold increase in mortality if the procedure was delayed for over 24 hours from the time of hospital admission. Some studies also showed remarkable increases in mortality with delays and inadequate operative interventions.

Antibiotics also play an important role in improving systemic sepsis and bacterial spread. Traditionally, an empirical regimen including penicillin and clindamycin was recommended to target Gram-positive and anaerobic organisms. However, the recommended initial antibiotic regimen has recently changed because of the emergence of resistant microorganisms [1].

The successful treatment of NF requires coordination

between surgical management and medical care. No factors other than rapid widespread operative debridement and appropriate antibiotics have an effect on mortality.

Although uncommon, complications associated with tube thoracostomy do occur and include subcutaneous emphysema, chest wall hematoma, hemothorax, lung laceration, chylothorax, and injury to mediastinal structures, the diaphragm, or intra-abdominal viscera [4]. NF of the chest wall was first reported by Pingleton and Jeter [5] in 1983, and its incidence is extremely rare worldwide.

Adequate drainage of early parapneumonic effusions is usually achieved with simple tube thoracostomy. However, the success rate deteriorates to 35%–39% in cases of true empyema [4]. The suction drainage technique is safe, quick, and relatively painless. It can also clear large amounts of pus, resulting in rapid clinical improvement [6]. As mentioned above, if pleural infection is confirmed, then immediate and complete drainage is necessary.

It would be best for a thoracic surgeon to perform tube thoracostomy and tube management directly, but there are cases where other departments have to provide assistance due to the shortage of thoracic surgeons. In such cases, improper drainage of empyema and complications resulting from this are rare, but sufficient care is required. Likewise, it is necessary to be wary of re-expansion edema, a complication that may occur due to rapid drainage of effusion; however, in cases of infective effusion, it is necessary to be aware that drainage may be delayed, resulting in serious complications, and to always closely monitor the proper drainage of the chest tube. As there may be a lack of understanding of this condition in other departments, thorough education and immediate inter-department consultations are required.

Conflict of interest

No potential conflict of interest relevant to this article was reported.

ORCID

Sangwook Chun: <https://orcid.org/0000-0003-1561-442X>

Gyeongho Lee: <https://orcid.org/0000-0001-5928-3939>

Kyoung Min Ryu: <https://orcid.org/0000-0001-8461-6010>

References

1. Sarani B, Strong M, Pascual J, Schwab CW. *Necrotizing fasciitis: current concepts and review of the literature*. J Am Coll Surg

- 2009;208:279-88.
2. Rea WJ, Wyrick WJ Jr. *Necrotizing fasciitis*. *Ann Surg* 1970;172:957-64.
3. Wong CH, Chang HC, Pasupathy S, Khin LW, Tan JL, Low CO. *Necrotizing fasciitis: clinical presentation, microbiology, and determinants of mortality*. *J Bone Joint Surg Am* 2003;85:1454-60.
4. de Hoyos A, Sundaresan S. *Thoracic empyema*. *Surg Clin North Am* 2002;82:643-71.
5. Pingleton SK, Jeter J. *Necrotizing fasciitis as a complication of tube thoracostomy*. *Chest* 1983;83:925-6.
6. Cummin AR, Wright NL, Joseph AE. *Suction drainage: a new approach to the treatment of empyema*. *Thorax* 1991;46:259-60.