

Timing of Endovascular Interventions for Iliac Vein Compression Syndrome With Thrombus

Clinical and Applied
Thrombosis/Hemostasis
Volume 27: 1-7
© The Author(s) 2021
Article reuse guidelines:
sagepub.com/journals-permissions
DOI: 10.1177/10760296211026974
journals.sagepub.com/home/cat



Wenxu Jin, MS¹, Guanfeng Yu, MS¹, Jingyong Huang, MD¹, Kangkang Lu, BS², and Chongqing Huang, MD¹

Abstract

The aim of this study is to explore the timing and method of endovascular intervention for iliac vein compression syndrome (IVCS) with thrombus. Data from 111 patients with IVCS, complicated acute deep vein thrombosis (DVT), or post-thrombotic syndrome (PTS) who underwent endovascular interventions were analyzed retrospectively. Patients were divided into Group A (DVT group), including 56 patients with IVCS and iliofemoral DVT, with or without femoropopliteal DVT, with sudden lower limb swelling, and Group B (PTS group) included 55 patients with IVCS and PTS, including 18 with lower extremity wet ulcers and 32 with lower limb infections. Interventional therapies were used to treat the thrombus and eliminate stenosis and occlusion of the iliac vein. In both groups, clinical symptoms in the lower limbs after surgery were reduced significantly, and PTS incidence was low during long-term follow-up. The cumulative patency rate was 75.2% in the DVT group and 88.6% in the PTS group. Comprehensive interventional therapies are safe and effective in patients with IVCS and thrombi. Long-term efficacy in the PTS group tended to be better than that in the DVT group.

Keywords

iliac vein compression syndrome, deep vein thrombosis, stent, post-thrombotic syndrome

Date received: 07 March 2021; revised: 23 May 2021; accepted: 02 June 2021.

Introduction

Iliac vein compression syndrome (IVCS), also known as May-Thurner syndrome¹ or Cockett syndrome,² which occurs mostly in the left leg, is an important predisposing factor for deep vein thrombosis (DVT). Post-thrombotic syndrome (PTS) is a complication that develops in up to 50% of patients with DVT. The risk of PTS can be markedly reduced by preventing DVT and providing appropriate anticoagulation once it develops.³ However, there has been no agreement on the treatment of IVCS with thrombus. We reviewed the data from cases of IVCS with thrombus with 5 years of follow-up treated at the Vascular Surgery Department at the First Affiliated Hospital of Wenzhou Medical University and discuss the timing and method of endovascular interventional treatments.

mean, 56.9 ± 13.5 years; 106 cases on the left and 5 cases on the right) with an average weight of 64.1 ± 10.6 kg, average height of 162.9 ± 7.2 cm, and average body mass index (BMI) of 23.8 ± 3.0 kg/m². The exclusion criteria were as follows: contraindications for anticoagulant therapy or thrombolytic drugs, recent major surgery or cerebrovascular accident, and anticipated long-term bed rest. Eighteen patients had obvious causes, including 2 patients with tumorigenicity, 8 patients with related surgery history, 1 patient with pregnancy, and 7 cases had related trauma history. All patients had more swelling in the affected limb than in the contralateral limb and underwent in vitro duplex ultrasonography and anterograde venography of their lower limbs before endovascular

Materials and Methods

Materials

From September 2013 through September 2020, a total of 111 patients with IVCS and thrombosis were treated by vascular surgery, including 54 men and 57 women (age, 13-83 years;

¹ Department of Vascular Surgery, The First Affiliated Hospital of Wenzhou Medical University, Wenzhou, China

² Department of Breast and Thyroid Surgery, The First Affiliated Hospital of Wenzhou Medical University, Wenzhou, China

Corresponding Author:

Chongqing Huang, Department of Vascular Surgery, The First Affiliated Hospital of Wenzhou Medical University, Wenzhou 325015, China.
Email: christopherhuang@qq.com



Creative Commons Non Commercial CC BY-NC: This article is distributed under the terms of the Creative Commons

Attribution-NonCommercial 4.0 License (<https://creativecommons.org/licenses/by-nc/4.0/>) which permits non-commercial use,

reproduction and distribution of the work without further permission provided the original work is attributed as specified on the SAGE and Open Access pages (<https://us.sagepub.com/en-us/nam/open-access-at-sage>).

Table 1. General Data and Comparison Between the 2 Groups of Patients With IVCS ($\bar{x} \pm s$).

Item	All patients (N = 111)	Group A (n = 56)	Group B (n = 55)	t	P
Number and proportion of male patients (%)	54 (48.6)	27 (48.2)	27 (49.1)	0.009	0.926
Age (years)	56.9 \pm 13.5	52.6 \pm 13.9	61.3 \pm 11.5	-3.61	0
Weight (kg)	64.1 \pm 10.6	62.4 \pm 8.5	65.8 \pm 12.2	-1.68	0.096
Height (cm)	162.9 \pm 7.2	163.1 \pm 7.3	162.6 \pm 7.1	0.35	0.729
BMI	23.8 \pm 3.0	22.1 \pm 5.9	23.3 \pm 6.6	-1.05	0.298
The incidence rate of left lower limb (%)	106 (95.5)	55 (98.2)	51 (92.7)	1.942	0.163
Number and proportion of related causes (%)	18 (33.3)	8 (14.3)	10 (37.0)	0.31	0.587
Iliac vein stenosis rate (%)	96.8% \pm 5.9%	97.7% \pm 4.0%	95.8% \pm 7.4%	1.51	0.14

interventions. Confirmed using 3-dimensional angiography, the stenosis rate of the iliac vein was 70.0%-100.0% (mean 96.8% \pm 5.9%). The disease duration ranged from 5 hours to 40 years (average, 4.0 \pm 9.0 years). A total of 111 patients were divided into 2 groups. Group A (DVT group) included 56 patients with IVCS and iliofemoral DVT, with or without femoropopliteal DVT, with sudden lower limb swelling. Group B (PTS group) included 55 patients with IVCS and PTS. Among these 55 patients, 18 had lower extremity wet ulcers and 32 had lower limb infections (Table 1).

In Group A, there were 56 patients with IVCS and DVT, including 27 men and 29 women (age, 13-77 years old; mean age, 52.6 \pm 13.9 years; mean weight, 62.4 \pm 8.5 kg; mean height, 163.1 \pm 7.3 cm; mean BMI, 22.1 \pm 5.9 kg/m²). Among all patients in Group A, 55 were affected on the left side, and 1 was affected on the right side. Eight patients had obvious causes, including 3 patients with acute DVT in the perioperative period after surgery, 4 patients with a related trauma history, and 1 pregnant patient. Before endovascular interventions, all patients underwent in vitro duplex ultrasonography and anterograde venography of their lower limbs. The stenosis rate of the iliac vein was 80.0%-100.0% (mean, 97.7% \pm 4.0%). The acute onset of the disease lasted from 5 to 15 d (mean, 5.1 \pm 3.8 d).

In Group B, 55 patients with IVCS and PTS were treated, including 27 men and 28 women (age, 23-83 years old; mean age, 61.3 \pm 11.5 years; mean weight, 65.8 \pm 12.2 kg; mean height, 162.6 \pm 7.1 cm; BMI, mean 23.3 \pm 6.6 kg/m²; 51 cases of left-sided disease and 4 cases of right-sided disease). Three patients had a tumorigenic cause, 4 patients had a history of trauma, and 3 patients had a history of surgery. All patients underwent in vitro duplex ultrasonography and anterograde venography of the lower limbs before surgery, and the stenosis rate ranged from 70.0% to 100.0% (mean, 95.8% \pm 7.4%). The duration of disease ranged from 2 months to 40 years (mean, 8.4 \pm 11.6 years). The clinical CEAP classification was 3 in 8 patients, 4 in 29 patients, 5 in 3 patients, and 6 in 15 patients.

Treatment Method

Combined with acute DVT (n = 56). An inferior vena cava (IVC) filter was implanted below the level of the renal vein through

the contralateral femoral vein. After successful puncture of the popliteal vein or femoral vein, a small balloon was used to dilate the vein. The corresponding length of the thrombolytic catheter was implanted into the thrombus for thrombolysis. In 51 patients, CDT was performed with urokinase (0.6 million to 8.4 million U; mean, 3.674 million \pm 1.851 million U) for 1-16 d (mean, 7.2 \pm 3.2 d). In another case, catheter thrombolysis along with a total dose of 30 mg alteplase was performed for 3 d. After 3 d, alteplase was replaced by urokinase at a dose of 1.2 million U for 3 d. Three patients were treated with urokinase first that was then replaced with alteplase. One patient was treated with 0.4 million U urokinase every day for 7 d; after a total dose of 2.8 million U, it was replaced with alteplase, 60 mg over 4 d. One patient was treated with urokinase (0.4 million U/d) for 6 d, which was then replaced by 20 mg/d of alteplase for 1 d. In 1 patient, urokinase, after 0.6 million U over 3 d, was replaced by alteplase. In addition, 24 patients underwent AngioJet rheolytic thrombectomy (ART) with urokinase/alteplase, and urokinase/alteplase continued to be used. Among them, 3 patients underwent ART with 0.3 million U urokinase. One patient was treated with 0.6 million U/d urokinase for 6 d; another patient was treated with 0.4 million U urokinase for 3 d; and the other was treated with nothing after surgery. One patient treated with ART combined with 250,000 U urokinase, continued with CDT with alteplase for 4 d, and the total amount of alteplase administered was 60 mg. Urokinase was used for thrombolysis for another 7 d, and the total amount of urokinase administered was 2.8 million U. Two patients underwent ART with alteplase 10 mg, followed by CDT with alteplase (10 mg for 1 d); 1 of these patients was then given urokinase 0.6 million U/d for 3 d. Angiography was performed after ART and CDT. Subsequently, we decided to perform stent implantation and/or balloon angioplasty, and the filter was retrieved. Low-molecular-weight heparin was administered according to body weight, and rivaroxaban was administered in special cases, such as in patients with heparin-induced thrombocytopenia. Ordinary heparin micropump anticoagulation was administered during CDT, and low molecular weight heparin was administered postoperatively, followed by a transition to oral warfarin (target international normalized ratio 2.0-3.0) or rivaroxaban. Warfarin or rivaroxaban was taken for at least 3 months. If the significant risk factors for coagulation were not resolved, patients continued anticoagulant therapy. If

Table 2. Perioperative Status of Patients and Comparison Between the 2 Groups ($\bar{x} \pm s$).

Item	All patients (N = 111)	Group A (n = 56)	Group B (n = 55)	t	P
Number and proportion of patients undergoing stent implantation (%)	105 (94.6)	52 (92.9)	53 (96.4)	0.667	0.414
Number of stents implanted >1 (%)	61 (55)	24 (42.9)	37 (67.3)	6.682	0.01
Diameter of stent (mm)	12.8 \pm 1.2	13.0 \pm 1.1	12.5 \pm 1.2	2.233	0.028
Length of stent (mm)	145.2 \pm 65.2	131.7 \pm 61.6	158.5 \pm 66.5	-2.138	0.035
The number and proportion of patients with simple balloon angioplasty (%)	6 (5.4)	4 (7.1)	2 (3.6)	0.667	0.414
Diameter of balloon for simple balloon angioplasty (mm)	6.3 \pm 2.1	5.75 \pm 1.3	7.5 \pm 3.5	-0.679	0.609
Length of balloon for simple balloon angioplasty (mm)	116.7 \pm 67.4	130.0 \pm 82.5	90.0 \pm 14.1	0.943	0.409

the significant risk factors for coagulation were resolved, patients were treated with aspirin after 3 months.

Combined with PTS (n = 55). After puncturing the dorsal vein of the foot, antegrade venography was performed on the lower limb vein of the affected side to confirm the diagnosis of IVCS. By puncturing the ipsilateral common femoral vein with pelvic venography, the pelvic venous blood flow and stenosis rate of the iliac vein were assessed. After a guide wire was inserted into the inferior vena cava successfully, a small balloon was used to dilate the iliac vein. The opening of the blood vessels and lateral branches was then observed, the rate of iliac vein stenosis was measured, and the reflux and collateral blood flow were evaluated again. If the majority of blood flowed through the ipsilateral iliac vein into the inferior vena cava and the venous stenosis rate was no more than 70%, further intervention was stopped. Otherwise, if the iliac vein stenosis rate was more than 70%, and the majority of blood flow was through the collateral into the inferior vena cava, balloon angioplasty was performed again with a larger balloon, and the stent was implanted. All patients received the same routine physical and drug anticoagulant treatments as those in the DVT group.

Evaluation of Efficacy

The rate of stenosis was measured before and after the operation using venography and ultrasonography. The circumferences of the ipsilateral and contralateral limbs were measured and compared before and after the operation (before discharge). The patients were followed up at 1, 3, and 6 months; and 1, 2, and 5 years, and venous duplex ultrasonography was performed. Evaluation at follow-up included venous and stent blood flow, complications related to the stent, and patency rate (Kaplan-Meier method).

Statistical Methods

The initial data were entered into Excel (2016 version) for logical proofreading and analysis. SPSS 22.0 software was used for the statistical analysis of the aforementioned data. The general data of patients are expressed as $\bar{x} \pm s$ and were compared using the *t*-test; statistical significance was set at $P < 0.05$.

Results

Perioperative Status of 111 Patients

In total, 105 patients underwent stent implantation, with a total of 184 stents, 8-14 mm in diameter (mean, 12.8 \pm 1.2 mm) and 40-280 mm in length (mean, 138.4 \pm 61.2 mm). Six patients underwent simple balloon angioplasty, with a balloon diameter of 5-10 mm (mean, 6.3 \pm 2.1 mm) and a length of 40-200 mm (mean, 116.7 \pm 67.4 mm). No symptomatic pulmonary embolism was found in any of the patients. In 6 patients (7.3%), puncture point bleeding occurred during catheter thrombolysis, and hemostasis was stopped after compression bandaging. No systemic bleeding, stent fracture, or other complications were observed (Table 2).

The rate of iliac vein stenosis decreased from 96.8% \pm 5.9% (70.0%-100.0%) before treatment to 5.1% \pm 15.6% (0%-70.0%) after surgery. The difference between the 2 groups was statistically significant ($P < 0.01$). The preoperative thigh circumference difference was 8.7 \pm 3.1 cm, and postoperative difference was 2.2 \pm 1.7 cm. The preoperative calf circumference difference was 7.0 \pm 2.3 cm and the postoperative difference was 1.3 \pm 1.6 cm. The difference was statistically significant ($P < 0.01$) (Table 3).

Perioperative Status of 56 Patients in the Group With Acute DVT (Group A)

In total, 52 patients underwent stent implantation, with a total of 105 stents, 12-14 mm in diameter (mean, 12.8 \pm 1.2 mm) and 60-260 mm in length (mean, 138.4 \pm 61.2 mm). Four patients underwent simple balloon angioplasty. The diameter of the balloons was 6 mm, 6 mm, 7 mm, and 4 mm, and their lengths were 40 mm, 80 mm, 200 mm, and 200 mm, respectively. Forty-nine of the 52 acute cases of DVT were treated with CDT after implantation of the inferior vena cava filter, and 24 patients were treated with ART followed by CDT. No symptomatic pulmonary embolism recurrence was found in any of the cases. In 6 patients (11.5%), puncture point bleeding occurred during catheter thrombolysis and resolved after compression bandaging. No systemic bleeding, stent fracture, or other complications were observed (Table 2).

Table 3. Comparison of the Rate of Iliac Vein Stenosis and Circumference Difference Before and After Stent Implantation ($\bar{x} \pm s$).

Item	Patients with IVCS associated with thrombosis	Preoperative	Postoperative	t	P
Iliac vein stenosis rate (%)	All patients (N = 111)	96.8 ± 5.9	5.1 ± 15.6	49.03	<0.01
	Group A (n = 56)	97.7 ± 4.0	6.7 ± 18.1	33.29	<0.01
	Group B (n = 55)	95.8 ± 7.4	3.3 ± 12.4	37.86	<0.01
	t	1.47	0.99		
	P	0.15	0.33		
Difference of circumference of thigh (cm)	All patients (N = 111)	8.7 ± 3.1	2.2 ± 1.7	12.34	<0.01
	Group A (n = 56)	11.5 ± 2.8	2.5 ± 2.4	15.00	<0.01
	Group B (n = 55)	6.6 ± 0.8	2.0 ± 0.9	20.64	<0.01
	t	-5.61	-0.66		
	P	<0.01	0.52		
Difference of circumference of calf (cm)	All patients (N = 111)	7.0 ± 2.3	1.3 ± 1.6	14.93	<0.01
	Group A (n = 56)	8.9 ± 2.3	1.7 ± 2.2	12.36	<0.01
	Group B (n = 55)	5.6 ± 0.8	1.0 ± 0.9	20.64	<0.01
	t	-4.54	-1.03		
	P	<0.01	0.32		

The rate of iliac vein stenosis decreased from $97.7\% \pm 4.0\%$ (90.0%-100.0%) before treatment to $6.7\% \pm 18.1\%$ (0%-70.0%) after surgery. The difference between the 2 groups was statistically significant ($P < 0.01$). The preoperative thigh circumference difference was 11.5 ± 2.8 cm, and the postoperative difference was 2.5 ± 2.4 cm. The preoperative crus circumference difference was 8.9 ± 2.3 cm, and the postoperative difference was 1.7 ± 2.2 cm. The difference was statistically significant ($P < 0.01$) (Table 3).

Perioperative Status of 55 Patients in the Group With PTS (Group B)

In total, 53 of the 55 patients underwent stent implantation, with a total of 100 stents implanted, 8-14 mm in diameter (mean, 12.5 ± 1.2 mm) and 40-280 mm in length (mean, 158.5 ± 66.5 mm). Two patients underwent simple balloon angioplasty. The diameters of the balloons were 5 mm and 10 mm and their lengths were 80 mm and 100 mm, respectively. All patients with PTS had no complications such as symptomatic pulmonary embolism, local or systemic bleeding, or stent fracture (Table 2).

The rate of iliac vein stenosis decreased from $95.8\% \pm 7.4\%$ (70.0%-100.0%) before treatment to $3.3\% \pm 12.4\%$ (0%-70%) after surgery. The difference between the 2 groups was statistically significant ($P < 0.01$). The preoperative thigh circumference difference was 6.6 ± 0.8 cm, and the postoperative difference was 2.0 ± 0.9 cm. The preoperative crus circumference difference was 5.6 ± 0.8 cm, and the postoperative difference was 1.0 ± 0.9 cm. The difference was statistically significant ($P < 0.01$) (Table 3).

Five-Year Follow-Up of 111 Patients

The cumulative patency rates were 96.3%, 95.3%, 92.4%, 90.3%, 89.1%, and 83.6% at 1, 3, and 6 months; and 1, 2, and 5 years after surgery (Figure 1). In 11 patients, the lower limb

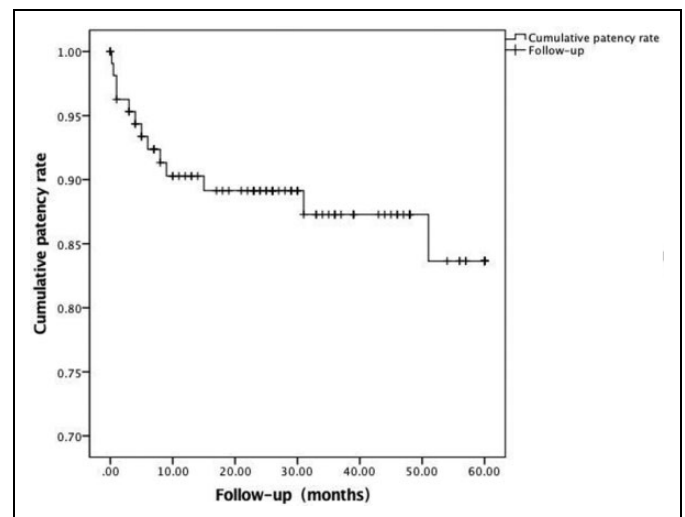


Figure 1. Patency rate of the iliac vein in 111 patients with thrombosis associated with IVCS (5-year follow-up, Kaplan-Meier Method).

was slightly swollen, and in 2 patients, there was a sense of heaviness. The incidence of PTS was 11.7% (13/111). Eighteen patients had wet ulcers, and 32 patients had lower limb infections. Both ulcers and infections healed within 1-3 months of treatment. Furthermore, there were 13 patients with recurrent iliac vein occlusion, 2 in the acute phase, 2 in the subacute phase, and 9 in the chronic phase. All patients with reocclusion of the iliac vein refused to undergo surgery again.

Five-Year Follow-Up of 56 Patients With Acute DVT

Simple balloon angioplasty of the iliac vein was performed in 3 patients with DVT. Ultrasonography in 3 patients showed complete patency of the previously affected veins. However, in 1 patient, even when treated with standardized anticoagulant therapy after surgery, iliac thrombosis occurred again in the first month. Seven more patients had venous occlusion after

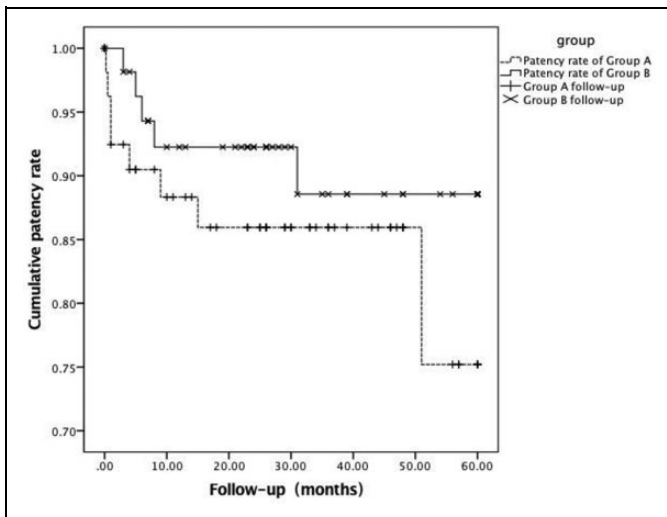


Figure 2. Cumulative patency rate of iliac vein after stent implantation in 2 groups of IVCS patients with thrombosis (5-year follow-up, Kaplan-Meier method).

stent implantation. One patient experienced re-occlusion of the stent in the 9th month after stent implantation due to self-discontinuation of warfarin anticoagulation. The other patient, refractory to CDT, was found to have occlusion of the stent within 1 week after ART and implantation of the stent in the iliac vein, as confirmed by ultrasound. In the 3rd month of follow-up, the patient still felt heaviness in the lower limbs. In the remaining 5 cases, thrombosis occurred 15 d, 6 months, 9 months, 15 months, and 55 months after surgery, leading to re-occlusion. These 8 patients with reocclusion of the iliac vein refused to undergo surgery again, and the PTS incidence was 14.3% (8/56). In addition, the cumulative patency rates of patients in this group were 96.2%, 92.5%, 90.5%, 88.3%, 85.9%, and 75.2% at 1, 3, and 6 months; and 1, 2, and 5 years after surgery, respectively (Figure 2).

Five-Year Follow-Up of 55 Patients With PTS

Five patients experienced re-occlusion of the stent after the suspension of anticoagulant drugs in the 3rd, 5th, 6th, 8th, and 26th month, respectively. All complained that the lower limb still felt heavy, including the patient who underwent simple balloon expansion of the iliac vein. These 5 patients refused to undergo surgery again, and the incidence of PTS was 9.1% (5/55). The cumulative patency rates of patients in this group were 100%, 98.1%, 94.3%, 92.2%, 92.2%, and 88.6% at 1, 3, and 6 months; and 1, 2, and 5 years after surgery, respectively (Figure 2).

Discussion

IVCS is a common disease in clinical practice. Typically, IVCS lesions mainly manifest as left iliac vein compression. It has been reported that 84% of the general population has different degrees of iliac vein pressure and at least 25% stenosis is

present in over 2/3 of the population,⁴ which is an important cause of DVT in the left lower limb. Moreover, cancer patients have a higher incidence of DVT than non-cancer patients.⁵ The majority of patients with IVCS are asymptomatic, while symptomatic ILVC can present with a variety of symptoms, including lower extremity swelling, claudication, hyperpigmentation, varicose veins, and/or venous ulceration.⁶ Surgical treatments for IVCS patients with thrombosis include open surgery and minimally invasive surgery. Open surgery mainly includes thoracotomy of the deep vein, venoplasty, transposition of the right common iliac artery, and venous bypass. Minimally invasive surgery mainly includes CDT, ART, balloon angioplasty, and stent implantation. As suggested, interventional therapy for patients with IVCS with thrombi is safe and effective.⁷⁻¹² Therefore, in this study, we performed comprehensive interventional surgery in all patients in the 2 groups and discussed the time of surgical intervention between the 2 groups.

Until now, no dedicated venous stents have been available, and stent-related issues have accounted for the decrease in patency scores.¹³ Endovascular ultrasound has not been popularized in most parts of China, and we evaluated the vascular condition of patients using preoperative extracorporeal ultrasound and enhanced computed tomography. We suggest the use of an 8-12-mm-diameter balloon to dilate the iliac vein as much as possible. The diameter of the stent should also range from 12 to 14 mm, and the length of the stent should cover the narrow segment too, with the 2 ends slightly exceeding 0.5 cm. For the majority of cases, we implanted iliac vein stents, and there was a significant difference in the proportion of patients who underwent stenting between the 2 groups. The PTS group required stents with a greater diameter and length, and more stents were implanted in individual patients than in patients in the DVT group. The main reasons for this are as follows. In patients with PTS, the iliac vein is totally occluded, and even the femoral vein after iliofemoral venous thrombosis is mechanized. However, there is currently no commercially available ultra-long venous stent; therefore, 2 or even 3 stents need to be implanted in the occluded lesion.

In general, 6/111 patients (5.4%) had postoperative puncture point bleeding, which was resolved using a pressure bandage. This is similar to the results reported in the literature.¹⁴ No complications, such as symptomatic pulmonary embolism, systemic hemorrhage, stent fracture, or other complications, occurred in any patient. A number of specialists have reported the short-term and medium-term efficacy of endovascular interventional treatment. Catheter-directed thrombolysis, with or without stenting, has been reported to be an effective treatment for DVT induced by IVCS, with primary patency rates of 79%-100% after 2 years.^{9,15,16} Neglén et al⁹ reported that the cumulative rate of severe in-stent restenosis (>50%) occurred in 5% of limbs after 72 months following stent placement for chronic nonmalignant obstructions. Hartung et al¹⁶ reported a 13% restenosis rate after 27 months of follow-up. The main risk factors associated with stent occlusion were the presence of thrombotic disease, positive thrombophilia test results, and formation of neointimal hyperplasia in stented vessels.

In our study, the clinical symptoms in the lower limbs after surgery were reduced significantly, regardless of group, and the incidence of PTS was low in the long-term results. Our study showed that the long-term patency rates in the PTS group tended to be higher than those in the DVT group (88.6% vs. 75.2%). Although there was no significant difference between the 2 groups, we would require a larger sample size and longer study period to further validate this conclusion. Previous studies have shown that age <40 years was a determinant of decreased primary patency in patients after interventional treatment of symptomatic IVCS.¹⁷ The PTS group was significantly older than the DVT group; however, there was no significant difference in BMI between the 2 groups. Interestingly, the incidence of recurrent occlusion in the DVT group was mainly concentrated in the acute phase and that in the PTS group was mainly in the chronic phase. The occurrence of this phenomenon is mainly related to the following points. First, the occurrence of vein occlusion after interventional treatment, whether in the DVT or PTS group, mainly manifests as the formation of a thrombus in the stent. Second, for patients in the DVT group, the reasons for stent occlusion were not only thrombus in the inflow duct that was not cleared completely, but also the sufficient time for oral anticoagulants (such as warfarin and rivaroxaban) to become fully effective, which may require more than 2 years. Third, compared with DVT, the inflow duct in the PTS group was better. In the acute phase, the inflow vein is mostly accompanied by a thrombus. Therefore, the blood flow rate is still relatively slow, and it is easy for DVT to reoccur. Fourth, the diameter of the stent in the PTS group were larger than those in the DVT group because the proximal vein is compressed and blocked for a long time, which causes the distal vein to expand, ultimately leading to an increase in the diameter of the stent to be implanted. Fifth, the length of the stent in the DVT group were shorter than those in the PTS group because of the reduction of lesions caused by CDT and ART.

Nevertheless, our study had several limitations. First, our sample was comparatively small and from a single center. Second, how patients with IVCS after interventional surgery will be affected by factors such as the presence of hyperhomocysteinemia, lack of protein C or S thrombophilia, and further development of new drugs (such as ATPase and galectins¹⁸) for DVT needs to be studied further.

Conclusion

In conclusion, comprehensive interventional therapies, such as CDT, ART, balloon angioplasty, and stent implantation, are safe and effective in patients with IVCS and thrombi. There was a significant difference in the diameter and total length of the implanted stents. As far as the current results were concerned, the long-term efficacy in the PTS group tends to be better than that in DVT group. However, this result may change in the future with the development of novel anticoagulants, thrombolytic drugs, surgical instruments, and operation methods.

Authors' Note

Patient consent was obtained. The study was approved by the institutional review board of the First Affiliated Hospital of Wenzhou Medical University.

Declaration of Conflicting Interests

The author(s) declared no potential conflicts of interest with respect to the research, authorship, and/or publication of this article.

Funding

The author(s) disclosed receipt of the following financial support for the research, authorship, and/or publication of this article: This work was supported by a grant from Wenzhou Science and Technology Planning Project (NO. Y20190150), and Scientific Research Incubator Project of the First Affiliated Hospital of Wenzhou Medical University (NO. FHY2019030).

ORCID iD

Wenxu Jin  <https://orcid.org/0000-0002-1617-5011>

References

1. May R. The cause of predominantly sinistral occurrence of thrombosis of the pelvic veins. *Minerva Cardioangiol Eur.* 1957;3(4):346-349.
2. Cockett FB, Thomas ML. The iliac compression syndrome. *Br J Surg.* 1965;52(10):816-821.
3. Henke P. Prevention and treatment of the postthrombotic syndrome. *J Vasc Surg.* 2010;52(5 suppl):21S-28S.
4. Kib Be MR, Ujiki M, Goodwin AL. Iliac vein compression in an asymptomatic patient population. *J Vasc Surg.* 2004;39(5):937-943.
5. Faiz AS, Khan I, Beckman MG, et al. Characteristics and risk factors of cancer associated venous thromboembolism. *Thromb Res.* 2015;136(3):535-541.
6. Radaideh Q, Patel NM, Shammas NW. Iliac vein compression: epidemiology, diagnosis and treatment. *Vasc Health Risk Manag.* 2019;15:115-122. doi:10.2147/vhrm.s203349
7. Huang C, Yu G, Huang J. Midterm results of endovascular treatment for iliac vein compression syndrome from a single center. *Ann Vasc Surg.* 2018;49:57-63.
8. Bi Y, Yu Z, Chen H. Long-term outcome and quality of life in patients with iliac vein compression syndrome after endovascular treatment. *Phlebology.* 2019;34(8):536-542.
9. Neglén P, Hollis KC, Olivier J. Stenting of the venous outflow in chronic venous disease: long-term stent-related outcome, clinical, and hemodynamic result. *J Vasc Surg.* 2007;46(5):979-990.e1.
10. Ignatyev IM, Pokrovsky A, Gradusov E. Long-term results of endovascular treatment of chronic iliofemoral venous obstructive lesions. *Vasc Endovascular Surg.* 2019;53(5):373-378.
11. Kim JY, Choi D, Ko YG. Percutaneous treatment of deep vein thrombosis in May-Thurner syndrome. *Cardiovasc Intervent Radiol.* 2006;29(4):571-575.
12. Titus JM, Moise MA, Bena J. Iliofemoral stenting for venous occlusive disease. *J Vasc Surg.* 2011;53(3):706-712.
13. van Vuuren TMAJ, Doganci S, Wittens CHA. Patency rates and clinical outcomes in a cohort of 200 patients treated with a

- dedicated venous stent. *J Vasc Surg Venous Lymphat Disord.* 2018;6(3):321-329.
14. Enden T, Haig Y, Kløw NE, et al. Long-term outcome after additional catheter-directed thrombolysis versus standard treatment for acute iliofemoral deep vein thrombosis (the CaVenT study): a randomised controlled trial. *Lancet (London, England).* 2012; 379(9810):31-38. doi:10.1016/s0140-6736(11)61753-4
 15. Patel NH, Stookey KR, Ketcham D. Endovascular management of acute extensive iliofemoral deep venous thrombosis caused by May-Thurner syndrome. *J Vasc Interv Radiol.* 2000;11(10):1297-1302.
 16. Hartung O, Otero A, Boufi M, et al. Mid-term results of endovascular treatment for symptomatic chronic nonmalignant ilio caval venous occlusive disease. *J Vasc Surg.* 2005;42(6):1138-1143.
 17. Knipp BS, Ferguson E, Williams DM, et al. Factors associated with outcome after interventional treatment of symptomatic iliac vein compression syndrome. *J Vasc Surg.* 2007;46(4): 743-749.e1.
 18. Diaz JA, Ramacciotti E, Wakefield TW. Do galectins play a role in venous thrombosis? A review. *Thromb Res.* 2010;125(5): 373-376.