

ORIGINAL ARTICLE

Successful management of pyriform sinus cyst and fistula using endoscopic electrocauterization

Naonori Kawakubo¹  | Satoshi Obata¹ | Koichiro Yoshimaru¹ | Kina Miyoshi^{1,2} | Tomoko Izaki^{1,3} | Tatsuro Tajiri¹

¹Department of Pediatric Surgery, Faculty of Medical Sciences, Kyushu University, Fukuoka, Japan

²Department of Pediatric Surgery, Miyazaki Prefectural Hospital, Miyazaki, Japan

³Department of Pediatric Surgery, Oita Prefectural Hospital, Oita, Japan

Correspondence

Kawakubo Naonori, Department of Pediatric Surgery, Faculty of Medical Sciences, Kyushu University, 3-1-1, Maidashi, Higashiku, Fukuoka, Japan.

Email:

kawakubo.naonori.061@m.kyushu-u.ac.jp

Abstract

Objectives: Pyriform sinus cyst (PSC) and pyriform sinus fistula (PSF) is a rare congenital malformation that arises from the third or fourth branchial structure. In our study, we describe the safety and the utility of endoscopic electrocauterization against PSC/PSF.

Methods: We retrospectively reviewed the records of patients who underwent endoscopic electrocauterization for PSC/PSF at our hospital. The internal opening of the fistula was identified under general anesthesia using a flexible endoscope (XQ-260 or H-290; Olympus, Tokyo, Japan), and the DualKnifeJ (KD-655L; Olympus) was used to ablate the internal opening.

Results: We experienced three PSF and three PSC patients. The postoperative course was uneventful in all cases. The patients declared no pain in the neck, and there were no cases showing recurrent nerve paralysis. Five in six cases (83%), the closure of fistula was archived in the first cauterization. One case (16.6%) required repeated cauterization. No recurrence was found during the follow-up period (median: 1 year) in any cases.

Conclusions: Owing to its rarity in neonates, the diagnosis and treatment of PSC remains complicated and not clearly described. Complete removal of the fistula and the cyst with or without affected thyroid tissue was previously the most commonly used treatment. From our experience, we believe that endoscopic electrocauterization can be the first choice not only for PSF but also for neonatal PSC. In conclusion, endoscopic electrocauterization is feasible even for neonatal PSC. Further investigations including multicenter analyses are needed.

KEYWORDS

electrocauterization, endoscopic cauterization, pediatric, pyriform sinus cyst, pyriform sinus fistula

INTRODUCTION

Pyriform sinus cyst (PSC) and pyriform sinus fistula (PSF) are rare congenital malformations that arise from the third or fourth branchial structure.¹ Complete removal of the fistula and cyst with or without affected thyroid tissue was previously the most commonly used

and most thorough treatment.² However, severe scarring due to recurrent abscesses or repetitive incisions and drainage can increase the risk of developing postoperative complications.¹

An alternative procedure for finding an opening in PSC/PSF and performing endoscopic chemical cauterization with trichloroacetic acid (TCA) as the first-line

This is an open access article under the terms of the [Creative Commons Attribution](https://creativecommons.org/licenses/by/4.0/) License, which permits use, distribution and reproduction in any medium, provided the original work is properly cited.

© 2022 The Authors. *DEN Open* published by John Wiley & Sons Australia, Ltd on behalf of Japan Gastroenterological Endoscopy Society.

treatment for PSF with a combination of endoscopy and treatment using rigid laryngoscopy was recently reported.^{3,4} This approach can reduce the incidence of postoperative complications and has a higher cure rate than open surgery. However, transient paralysis of the vocal cords after TCA chemical cauterization has been reported.⁵ The most popular endoscopic electrocautery technique was first described in 1998,⁶ and laser ablation has also been reported as a minimally invasive treatment for PSF.⁷ The basic principles of chemical ablation and electrocauterization are aimed at circumferential ablation of internal openings. Lachance et al. reported the systematic review of the endoscopic obliteration technique for managing PSF, and the endoscopic management appeared to be safe and effective.⁸ In Japan, the reports about the endoscopic obliteration technique for PSF are few. Moreover, in past, there was only one report that focused on endoscopic treatment for neonatal PSC.⁹ In the present study, we describe the safety and utility of endoscopic electrocauterization for pediatric PSC/PSF. We actively treated neonatal PSC using endoscopic electrocauterization with a focus on treatment for neonatal PSC.

PATIENTS AND METHODS

We retrospectively reviewed the records of patients who underwent endoscopic electrocauterization of PSC/PSF at Kyushu University Hospital from January 2017 to January 2022.

Since 2017, we have actively treated PSC/PSF by endoscopic electrocauterization. The internal opening of the fistula was identified under general anesthesia using a flexible endoscope (GIF-XQ260 or GIF-H290; Olympus, Tokyo, Japan), and the DualKnifeJ (KD-655L; Olympus) was used to ablate the internal opening of the pyriform sinus; the modes of electrocauterization were FORCED COAG mode (Effect 2, 10–20 W), and the electrocautery unit was VIO 300D (ERBE). When the patients underwent Sclerotherapy using OK-432, the surgeon performed an ultrasound-guided puncture to the cyst and injected 5 ml of OK-432 (0.1 KE/ml). And, almost 1 h after the sclerotherapy, the injected OK-432 was collected from the cyst through the inserted needle. During this procedure, the patient was in the supine position, and no laryngeal elevation was required.

The institutional review board of our hospital approved this study. This retrospective study was performed according to the Ethical Guidelines for Clinical Research, published by the Ministry of Health, Labour and Welfare, Japan, on July 30, 2003 (revised in 2008). The study complied with the 1964 Declaration of Helsinki (revised in 2008). The Institutional Review Board exempted this study from the need for informed consent.

RESULTS

During the above period, we experienced three PSF and three PSC patients. In all of the patients, the PSF and PSC were located on the left side. There was no other patient who underwent other treatment (e.g., surgery) for PSF/PSC during the same period.

The details of the six patients are summarized in Table 1. There were no intraoperative complications. The endoscopic findings are listed in Figure 1 (Case 6). For two of the three PSC patients, sclerotherapy using OK-432 was performed after endoscopic electrocauterization, and the other patient underwent only endoscopic electrocauterization. Regarding the three PSF patients, one (Case 5) who had an acute inflammatory neck tumor underwent an external incision and drainage of the neck abscess.

The postoperative course was uneventful in all cases. The patients declared no pain in the neck, and there were no cases of recurrent nerve paralysis. Five in six cases (83%), the closure of fistula was archived in the first cauterization. Case 2 required repeated cauterization (three times), but the fistula was ultimately closed after repeated cauterization. The cyst of the neck shrank but still remained in two patients (Cases 1 and 2), and we have continued follow-up of these patients. In one patient (Case 6), the cyst shrank remarkably, and we were able to detect a tiny cyst (3 mm) on ultrasonography (Figure 2). No cases of recurrence were found during the follow-up period (median: 1 year).

DISCUSSION

PSF and PSC are rare congenital branchial arch anomalies in children.¹ PSC is commonly identified during the newborn period and causes respiratory failure, neck abscess, or thyroiditis.^{1,2,10} It originates from the failure of obliteration of the third or fourth pharyngeal pouches, which are connected to the pharynx by the pharyngo-branchial duct.^{1,2} Owing to its rarity in neonates, the diagnosis and treatment of PSC remains complicated and not clearly described. Complete removal of the fistula and cyst with or without affected thyroid tissue was previously the most commonly used and most thorough treatment.^{1,2,10}

Recently, however, studies involving ablation of the internal opening for treatment of PSF have been reported.^{11,12} Various ablation techniques have been described, including TCA^{3,4}, electrocauterization,^{6,13,14} radiofrequency ablation,¹⁵ laser cauterization,⁷ and others.¹⁶ Chen et al. reported the utility of endoscopic radiofrequency ablation compared to endoscopic-assisted surgery.¹⁵ In their report, the patients treated with radiofrequency ablation had a significantly shorter hospital stay than those treated with

TABLE 1 Results of six patients

Case	Age	Sex	Number of procedures	Operative time (min)	Combination therapy	Left or Right	Cyst	Follow-up period
1	1 month	Male	1	94	Sclerotherapy	Left	Yes	4 years
2	18 days	Female	3	34/44/63	Sclerotherapy	Left	Yes	4 years
3	12 years	Female	1	15	-	Left	No	3 years
4	2 years	Male	1	11	-	Left	No	1 year
5	4 years	Male	1	29	Drainage of abscess	Left	No	1 year
6	1 month	Male	1	10	-	Left	Yes	3 months

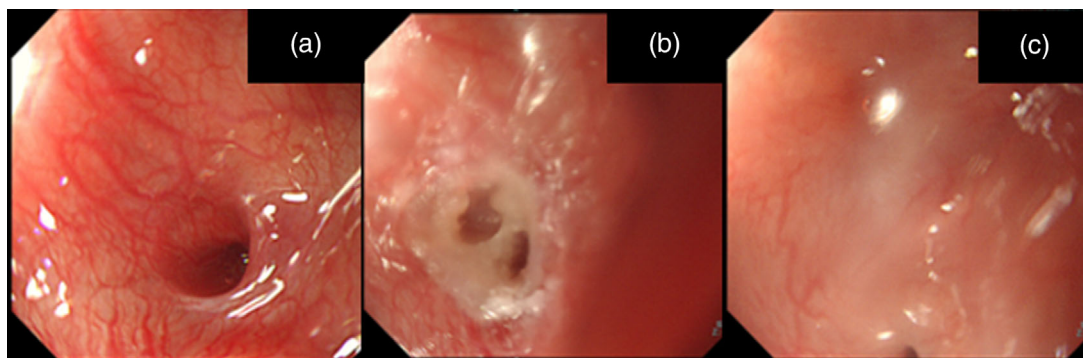


FIGURE 1 Endoscopic findings of pyriform sinus cyst. Case 6 (a–c). (a) The internal opening of the pyriform sinus (Case 6). (b) The internal opening after ablation. (c) The finding of endoscopy 2 weeks after ablation. Closure of the fistula was observed

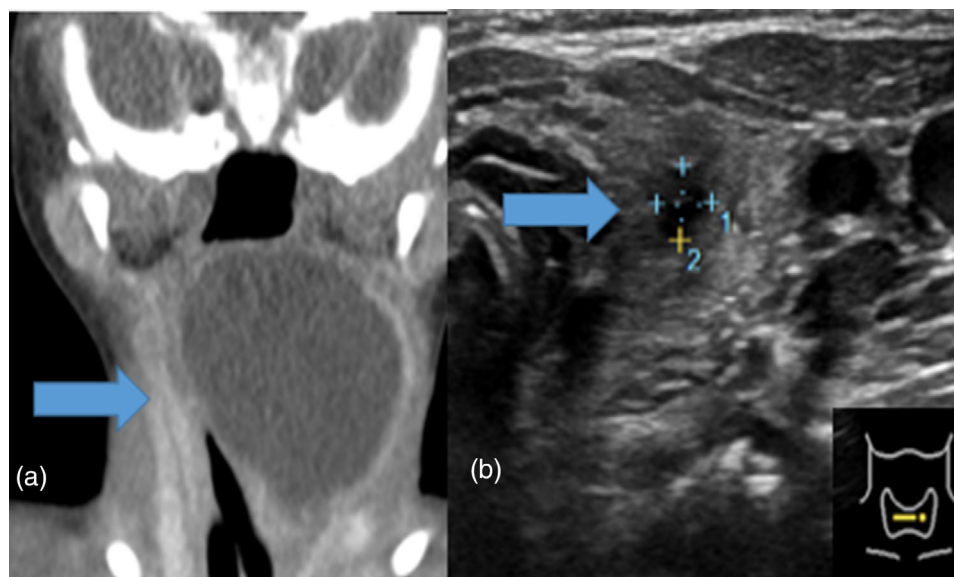


FIGURE 2 Computed tomography and ultrasonography findings of pyriform sinus cyst before and after ablation. Case 6 (a, b). (a) Computed tomography findings before ablation. A large cystic mass occupies the left side of the neck. (b) Ultrasonography findings one month after ablation. The cystic mass has remarkably shrunk

endoscopic-assisted surgery. Hwang et al. reported a retrospective analysis comparing excision versus TCA.³ In their report, TCA chemocauterization was performed for 13 patients, and the recurrence rate was 46.1%. All of

the patients with recurrence were successfully treated with repeated chemocauterization or re-excision. A large cohort of endoscopic electrocauterization was initially reported by Chen et al.¹³ They used the Bugbee

TABLE 2 The summary of obliteration technique for pyriform sinus fistula/pyriform sinus cyst

Author	Patient number	Obliteration technique	Success rate(%)	Complication rate(%)	Age. (range mo)
Kim ¹⁷	11	TCA	81.8	0	24–144
Stenquist ¹⁸	1	TCA	100	0	166
Cigliano ¹⁹	1	Fibrin glue	100	0	108
Sayadi ²⁰	2	CERALAS laser	100	0	36–144
Ahmed ²¹	3	Electrocautery	100	0	12–84
Pereira ²²	2	Silver nitrate	100	0	24–204
Chen ¹³	9	Electrocautery	78	0	49–193
Leboulanger ⁹	19	CO ₂ laser, thulium laser, electrocautery	84.2	0	0–204
Park ⁵	2	TCA	100	100	13–60
Watson ²³	5	Electrocautery, CO ₂ laser plus silver nitrate, silver nitrate	100	0	36–144
Sun ²⁴	22	Electrocautery	95.5	0	6–124
Cha ²⁵	44	TCA	77.3	0	24–648
Wong ²⁶	2	Electrocautery	100	0	132–168
Hwang ³	13	TCA	54	0	18–180
Yanagisawa ⁴	4	TCA	100	50	60–96
Wang ⁷	101	CO ₂ laser,	97	0	13–197
Masuoka ¹²	74	TCA, diode laser	83 (TCA) 100 (laser)	5.4	60–552
Ishinaga ¹⁴	8	Electrocautery	75%	0	36–636
Chen ¹⁵	48	Radioablation	100	13.2	33–97
Xia ¹⁶	10	Hypothermia plasma	100	0	NA
Hod ²⁷	10	Electrocautery plus voicegel	100	0	12–84
Present cases	6	Electrocautery, electrocautery plus sclerotherapy	100	0	0–170

TCA, trichloroacetic acid

flexible cautery electrode and inserted the electrode into the sinus tract and ablate the tract. They advocated this procedure as a first-line treatment in conjunction with incision and drainage. In another report that emphasized the utility of electrocauterization,¹⁴ authors considered that cauterization was a proper first-line treatment for PSF.

Electrocauterization of PSC for neonatal patients is a more challenging procedure than electrocauterization for older patients. Two of our three patients underwent sclerotherapy using OK-432 to ablate the internal epithelium of the cyst, but the cysts remained in both cases. We considered sclerotherapy for PSC not to be very effective or necessary. Thus, in Case 6, the patient underwent only electrocauterization. The internal openings were closed in all cases, and the cysts remained in two cases, but in one case (treated with only electrocauterization), the cyst shrank remarkably. In our experience, closure of the internal opening of the fistula is the most important factor for managing PSC as well as PSF.

We should consider the risk for each obliteration technique. In chemical ablation such as TCA, there is a risk

of oral inflammation for the spillage of chemical agents to another oral cavity. In radiofrequency ablation or laser ablation, postoperative temporary hoarseness occurred in 11.1% of patients.¹⁵ The postoperative hoarseness is often observed even after the open surgery to PSF/PSC, and we should pay attention to the overcauterization of the internal opening. As Ishinaga et al. reported,¹⁴ the Bugbee cautery electrode can be inserted 1–2 cm deep into a fistula, but we feel that blind cauterization is dangerous, considering the risk of damaging the recurrent laryngeal nerve. We ablated the internal opening using Dualknife J. Because the internal opening of the pediatric (especially neonatal) pyriform sinus is very small, a fine operation is needed, and we think Dualknife J is a suitable device to ablate in such a small area. We think the advantage of this procedure is targeted electrocauterization under direct endoscopic observation, which allows for effective cauterization minimizing the cautery effect on surrounding organs.

In Table 2, we summarized the reports about the obliteration technique for managing PSF/PSC. As mentioned above, when TCA was used, a postoperative

complication such as temporary vocal fold immobility occasionally occurred. There was only one report about endoscopic electrocauterization for neonatal PSC.⁸ In that report, the high rate of failure of endoscopic treatment (40% 2/5) was reported. Further investigation is needed if endoscopic treatment is truly effective for neonatal PSC, but we think the electrocauterization of the internal opening of the fistula is effective not only for PSF but neonatal PSC.

In the present study, we cauterized only the mucous membrane of the internal opening endoscopically. Careful consideration should be given to the effects of residual cysts. Based on our experience, we believe that this procedure can be the first choice for not only PSF but also newborn PSC.

In conclusion, endoscopic electrocauterization is a viable procedure, even for neonatal PSC. However, our study was associated with some limitations, including its retrospective design, and further investigations that include multicenter analyses are needed.

CONFLICT OF INTEREST

The authors declare no conflict of interest.

FUNDING INFORMATION

None.

ORCID

Naonori Kawakubo 

<https://orcid.org/0000-0003-0010-4902>

REFERENCES

- Nicoucar K, Giger R, Pope HG, Jaecklin T, Dulguerov P. Management of congenital fourth branchial arch anomalies: A review and analysis of published cases. *J Pediatr Surg* 2009; **44**: 1432–9.
- Zhu H, Xiao X, Zheng S, Shen C. Diagnosis and management of pyriform sinus cyst in neonates: 16-years experience at a single center. *J Pediatr Surg* 2017; **52**: 1989–93.
- Hwang J, Kim SC, Kim DY, Namgoong JM, Nam SY, Roh JL. Excision versus trichloroacetic acid (TCA) chemocauterization for branchial sinus of the pyriform fossa. *J Pediatr Surg* 2015; **50**: 1949–53.
- Yanagisawa S, Oshio T, Kano M, Kano M, Tsuji Y, Morikawa Y. Endoscopic chemocauterization for pyriform sinus fistula in children. *Pediatr Int* 2017; **59**: 807–11.
- Park JH, Jung YH, Sung MW, Kim KH. Temporary vocal fold immobility after chemocauterization of the pyriform sinus fistula opening with trichloroacetic acid. *Laryngoscope* 2012; **123**: 410–3.
- Jordan JA, Graves JE, Manning S, Mcclay JE, Biavati MJ. Endoscopic cauterization for treatment of fourth branchial cleft sinuses. *Arch Otolaryngol Head Neck Surg* 1998; **124**: 1021–4.
- Wang S, He Y, Zhang J *et al.* CO₂ laser cauterization approach to congenital pyriform sinus fistula. *J Pediatr Surg* 2018; **53**: 1313–7.
- Lachance S, Chadha NK. Systematic review of endoscopic obliteration techniques for managing congenital pyriform fossa sinus tracts in children. *Otolaryngol Head Neck Surg* 2016; **154**: 241–6.
- Leboulanger N, Ruellan K, Nevoux J *et al.* Neonatal vs delayed-onset fourth branchial pouch anomalies. *Arch Otolaryngol Head Neck Surg* 2010; **136**: 885–90.
- Li WX, Dong Y, Zhang A *et al.* Surgical treatment of fourth branchial apparatus anomalies: A case series study. *J Otolaryngol Head Neck Surg* 2020; **49**: 79.
- Sheng Q, Lv Z, Xu W, Liu J. Reoperation for pyriform sinus fistula in pediatric patients. *Front Pediatr* 2020; **8**: 116.
- Masuoka H, Miyachi A, Sasaki T, Sano T, Miya A. Outcomes of endoscopic chemo-and laser-cauterizations and open fistulectomy for pyriform sinus fistula. *J Otolaryngol Head Neck Surg* 2021; **50**: 49.
- Chen EY, Inglis AF, Ou H *et al.* Endoscopic electrocauterization of pyriform fossa sinus tracts as definitive treatment. *Int J Pediatr Otorhinolaryngol* 2009; **73**: 1151–6.
- Ishinaga H, Kobayashi M, Otsu K *et al.* Endoscopic electrocauterization of pyriform sinus fistula. *Eur Arch Otorhinolaryngol*. 2017; **274**: 3927–31.
- Chen T, Chen J, Sheng Q *et al.* Pyriform sinus fistula in children: A comparison of endoscopic-assisted surgery and endoscopic radiofrequency ablation. *J Pediatr Surg* 2021; **56**: 800–4.
- Xia L, Lin Z, Lin X *et al.* The treatment of congenital pyriform sinus fistula: A single-center experience. *Pediatr Surg Int* 2020; **36**: 779–88.
- Kim KH, Sung M-W, Koh T-Y, Oh SH, Kim IS. Pyriform sinus fistula: Management with chemocauterization of internal opening. *Ann Otol Rhinol Laryngol* 2000; **109**: 452–6.
- Stenquist M, Juhlin C, Astrom G, Friberg U. Fourth branchial pouch sinus with recurrent deep cervical abscesses successfully treated with trichloroacetic acid cauterization. *Acta Otolaryngol*. 2003; **123**: 879–82.
- Cigliano B, Cipolletta L, Baltogiannis N, Esposito C, Settini A. Endoscopic fibrin sealing of congenital pyriform sinus fistula. *Surg Endosc* 2004; **18**: 554–6.
- Sayadi SJ, Gassab I, Dellai M *et al.* Endoscopic treatment with laser of fourth endobranchial pouch. *Ann Otolaryngol Chir Cervicofac* 2006; **123**: 138–42.
- Ahmed J, De S, Hore ID, Bailey CM, Hartley BEJ. Treatment of piriform fossa sinuses with monopolar diathermy. *J Laryngol Otol* 2008; **122**: 840–4.
- Pereira KD, Smith SL. Endoscopic chemical cautery of pyriform sinus tracts: A safe new technique. *Int J Pediatr Otorhinolaryngol* 2008; **72**: 185–8.
- Watson GJ, Nichani JR, Rothera MP, Bruce IA. Case series: Endoscopic management of fourth branchial arch anomalies. *Int J Pediatr Otorhinolaryngol* 2013; **77**: 766–9.
- Sun JY, Berg EE, McClay JE. Endoscopic cauterization of congenital pyriform fossa sinus tracts: an 18 year experience. *JAMA Otolaryngol Head Neck Surg* 2004; **140**: 112–7.
- Cha W, Cho SW, Hah JH, Kwon T-K, Sung M-W, Kim KH. Chemocauterization of the internal opening with trichloroacetic acid as first-line treatment for pyriform sinus fistula. *Head Neck* 2013; **35**: 431–5.
- Wong PY, Moore A, Daya H. Management of third branchial pouch anomalies: An evolution of a minimally invasive technique. *Int J Pediatr Otorhinolaryngol* 2014; **78**: 493–8.
- Hod R, Lachance S, Chadha NK. Endoscopic cauterization and injection of Voicegel for treatment of congenital pyriform fossa sinus tracts. *Acta Otorhinolaryngol Ital* 2021; **41**: 432–5.