

## Does a lateral tibial plateau fracture (Takeuchi type III) occurring during opening wedge high tibial osteotomy induce a higher revision rate to total knee arthroplasty?

Piero Giardini<sup>1</sup>, Lapo De Luca<sup>2</sup>, Beatrice Crespan<sup>3</sup>, Avraam Christodoulidis<sup>1</sup>, Marco Molinari<sup>1</sup>

<sup>1</sup>Department of Orthopaedics and Traumatology, Cavalese Hospital, Provincia Autonoma di Trento, Italy; <sup>2</sup>Department of Orthopaedics and Traumatology, S. Chiara Hospital, Provincia Autonoma di Trento, Italy <sup>3</sup>Department of Orthopedics and Trauma Surgery, University of Verona, Italy

**Abstract.** *Background and aim:* High tibial osteotomies (HTO) are effective procedures to treat younger patients affected by moderate but symptomatic arthritis. Open-wedge HTO (OW-HTO) is more often performed compared to a closing wedge osteotomy to treat varus arthritis of the knee due to a lower incidence of complications and better results: lateral hinge fracture (LHF) is the most common complication of OW-HTO. Intra articular fractures of the lateral tibial plateau (Takeuchi type III) appear as a particularly serious complication due to its extension to the subchondral bone of the compartment towards which the load is shifted. Aim of our study, is to assess if an intra articular fracture of the lateral tibial plateau occurring during an OW-HTO leads to an higher risk of failure and to an early conversion to a total knee arthroplasty. *Methods:* Between January 2013 and December 2018 114 patients underwent OW-HTO at our Orthopaedic Department. All the patients underwent the same surgical procedure performed by a skilled knee surgeon: a subcutaneous-medial locked plate (Tomofix®, Synthes, Solothurn, Switzerland) has been used in all the procedures to stabilize the osteotomy. Clinical and radiographic follow up has been performed at one, three, six and twelve months postoperatively afterwards annually. We retrospectively reviewed all the intra operative fluoroscopy of patients to detect those affected by an intra articular fracture of the lateral tibial plateau occurred intra operatively. *Results:* A LHF occurred in 11 out of 114 patients (9.65%) who underwent an OW-HTO; in particular nine patients (7.9%) had a Type III LHF. In all cases such complication has been detected intra operatively. In the subgroup of patients who experienced an intra articular fracture of the tibial plateau at the last follow up only one patients underwent to a revision with a total knee arthroplasty; in other words, the survivorship of an OW-HTO complicated by a LHF type III resulted 89% at a mean follow-up of 5 years. In 103 patients without an intraoperative fracture, the percentage of patients free from revision at the last follow up resulted of 92%. *Conclusions:* Takeuchi type III fracture is an uncommon but serious complication to manage: in our case series we found that an early recognition and a correct treatment of this occurrence don't lead to a premature conversion to a knee arthroplasty if compared with an uncomplicated osteotomy. Further studies are necessary to establish specific subjective outcomes after OW-HTO burdened by an intra articular fracture of the lateral plateau. ([www.actabiomedica.it](http://www.actabiomedica.it))

**Key words:** Open-Wedge High Tibial Osteotomy, Lateral-Hinge Fracture, Lateral Tibial Plateau Fracture, Knee revision

## Introduction

Total knee arthroplasty is the primary treatment for late stage arthritis of the knee; however unicompartmental knee arthroplasty (UKA) and high tibial osteotomy (HTO) are effective procedure to treat younger patients affected by moderate but symptomatic arthritis.

UKA and HTO share some well-known clinical indications such as age, activity level, body weight, mild varus malalignment, absence of joint instability, good ROM and moderate-unicompartmental knee arthritis; although UKA lead to a better control of the pain, HTO guarantee a higher post operative range of motion and a better post operative activity level compared to UKA (1). For these reasons, several studies conclude that HTO is a suitable option for patients with high activity requirements (1-10).

Opening wedge-high tibial osteotomy (OW-HTO) and closing wedge high tibial osteotomy (CW-HTO) are well defined surgical procedure with specific indication (2,4,11); nonetheless OW-HTO is more often performed compared to a closing wedge osteotomy to treat varus arthritis of the knee due to a lower incidence of complications and better results (2,4, 12).

A detrimental topic related to tibial osteotomy is the survivorship of the surgical procedure without a revision that is a conversion in a total knee arthroplasty.

Recently Yoon et al reported that the risk of revision is higher in the patients treated with HTO compared to patients treated with UKA, respectively an eight years survivorship of 91.5% and 97.8% (5).

Female sex and elderly age are the most cited risk factors for failure of HTO (5-8): comorbidities (5), grade of osteoarthritis (7) or previous meniscectomy (8) are other risk factors involved on the survivorship of the HTO.

OW-HTO are burdened of an overall complication rate around 30% (9), including both minor complication (undisplaced lateral hinge fracture, hardware irritation, displaced lateral hinge fracture, delayed wound healing, undisplaced lateral tibial plateau fracture, superficial wound infection) and major complications (symptomatic hardware which requires removal, infections, hardware failures, loss of correction, non union and early conversion to arthroplasty).

Lateral hinge fracture (LHF) is the most common complication of OW-HTO occurring between 15 and 25% of the surgical procedures (10-12).

Takeuchi et al in 2012 classified lateral hinge fracture in type I (within the tibio fibular (TF) joint), type II (at the distal portion of the TF joint) and type III (intra articular, lateral plateau fracture) (10).

Recently, different authors (13,14) demonstrated favourable clinical and radiographic outcome after a LHF type I or II during an OW-HTO.

Although Type I and Type II fracture resulted more common than type III fracture (10-12), intra articular fractures of the lateral tibial plateau appear as a particularly serious complication due to its extension to the subchondral bone and the cartilage of the compartment towards which the load is shifted after an OW-HTO (20).

Aim of our study, is to assess if an intra articular fracture of the lateral tibial plateau occurring during an OW-HTO leads to an higher risk of failure and to an early conversion to a total knee arthroplasty.

To the best of our knowledge, no other studies in the literature report the outcomes of OW-HTO complicated by an intra articular fracture of the lateral tibial plateau, namely a Takeuchi type III fracture.

## Material and Methods

Between January 2013 and December 2018 114 patients underwent OW-HTO to treat mild varus arthritis at our Orthopaedic Department. All the surgical procedure were performed by the same operator (MM), a skilled knee surgeon, using the same technique.

In brief, the surgical procedure consisted in a biplanar opening wedge high tibial osteotomy performed with intra operative fluoroscopy. The first oblique osteotomy is performed with a saw starting at the upper margin of the pes anserinus and ended at the lateral cortical margin: this osteotomy is guided by a couple of previously placed K wire in a medial to lateral direction to the fibula head. The second osteotomy is performed proximally to the insertion of the patellar tendon on a frontal plane to cross the first osteotomy line.

Progressive chisels are used to complete the osteotomies and a graduated wedge is inserted to open the

HTO according to the preoperative planning.

Intra operative fluoroscopy is fundamental to check the direction of the osteotomies and the correct opening of the wedge; furthermore, an accurate amplioscopic check of each step of the procedure is fundamental for an early diagnosis of an intraoperative fracture.

Independently from the grade of correction required, nor a synthetic or heterologous bone substitute has been used to fill the osteotomy site as previously described by other authors (13).

A subcutaneous-medial locked plate (Tomofix®, Synthes, Solothurn, Switzerland) positioned in a mini invasive manner has been used in all the procedures to stabilize the osteotomy.

All the patients underwent the same post operative rehabilitation protocol with partial weight bearing and full range of motion from the immediate post operative period; patients affected by an intra operative LHF type III underwent a less aggressive rehabilitation protocol comprising not weight for one month and thereafter partial weight bearing was allowed with a brace.

Clinical and radiographic follow up has been performed at one, three, six and twelve months postoperatively afterwards annually.

We retrospectively reviewed all the intra operative fluoroscopy of patients to detect those affected by an intra articular fracture of the lateral tibial plateau occurred intra operatively. We conducted a follow up of the patients either clinically when possible or by a telephonic interview to calculate the survivorship of the OW-HTO free from a conversion to a TKA.

Our hypothesis was that a careful management of a Takanagy Type III fracture would not affect the outcome of the surgery compared to those free from this complication.

## Results

114 patients (74 male; 40 female), mean age 57 years old (y.o) (min 48, max 63y.o.) that underwent OW-HTO to treat mild varus arthritis (average  $10^{\circ} \pm 3^{\circ}$ ) at our Orthopaedic Department met eligibility criteria for the present study. All the surgical procedure were performed by the same operator (MM), a skilled knee surgeon, using the same technique.

A LHF occurred in 11 out of 114 patients (9.65%) who underwent an OW-HTO; in particular nine patients (7.9%) had a Type III LHF. In all cases such complication has been detected intra operatively. The mean follow up time was 5 years.

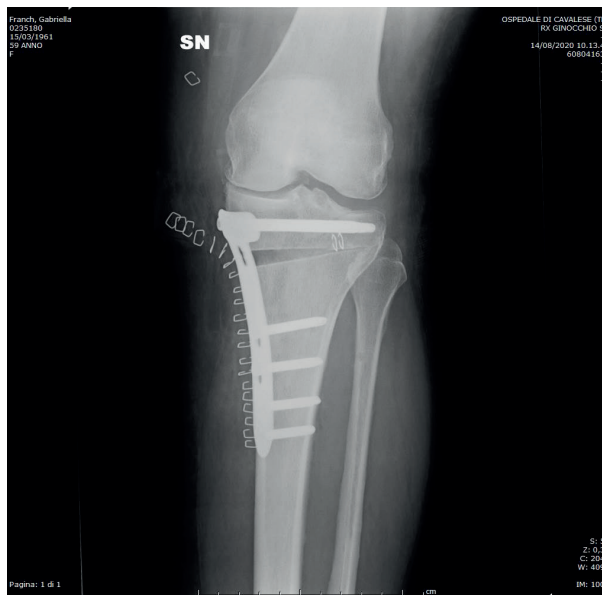
In the subgroup of patients who experienced an intra articular fracture of the tibial plateau (9 of 114), at the last follow up only one patients underwent to a revision with a total knee arthroplasty; in other words, the survivorship of an OW-HTO complicated by a LHF type III resulted 89% at a mean follow-up of 5 years.

In 103 patients without an intraoperative fracture (90.35%), the percentage of patients free from revision at the last follow up resulted of 92%.

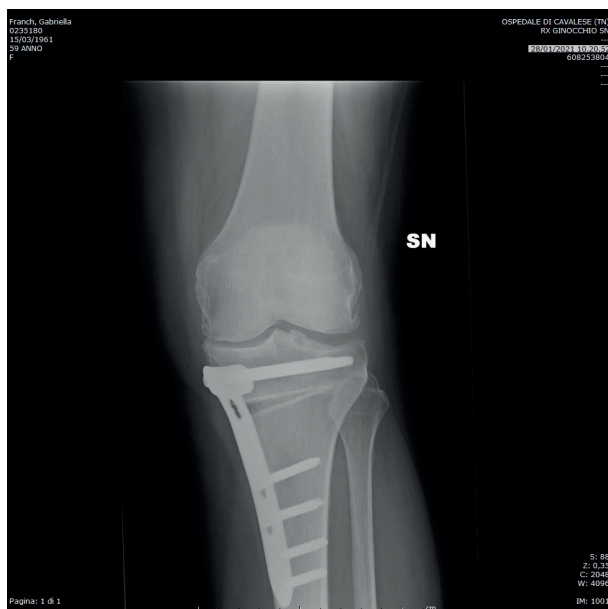In patients affected by a Type III LHF we haven't recorded any major complication such as non union/mal union or infections and any revision surgery was required to address this complication (Figure 1 and 2).

## Discussion

In our mountain environment many active patients are affected by arthritis of the medial compartment associated with varus alignment in a relatively young age (younger than 60 years old (6)).



**Figure 1.** Post operative X-Rays showing a well reduced fracture of the lateral tibial plateau occurred during an OW-HTO



**Figure 2.** The radiographic follow up after six months shows the healing of the osteotomy site and the absence of any sign of displacement or mal union of the fracture of the lateral plateau

At the present time, although knee arthroplasty is gaining more popularity, high tibial osteotomy appears popular again and worthy of attention (1); advantages of HTO is the preservation of the knee joint as long as possible, a large corrective effect of the mechanical axis and the avoidance or postponement of knee replacement (4). Not at least, HTO in young patients (50–60 y.o.) may be more cost effective than arthroplasty (7).

Selection of the ideal candidate is an important factor in achieving good results with HTO (1,4) and for the above mentioned reasons many of our patients perfectly fit the indications to perform an HTO instead of a UKA: mean age (57 years old) of our cohort and double male population than female (M:F=74:40) in the study appear in line with previous literature.

The aim of HTO is to shift the weight bearing line from the medial-arthritic tibio-femoral compartment to the opposite healthy compartment: for this reason, an intra operative fracture of the lateral tibial plateau involving the joint appears as a particularly alarming situation that could potentially lead to an early failure of the osteotomy, a non union or a delayed union or a loss of correction.

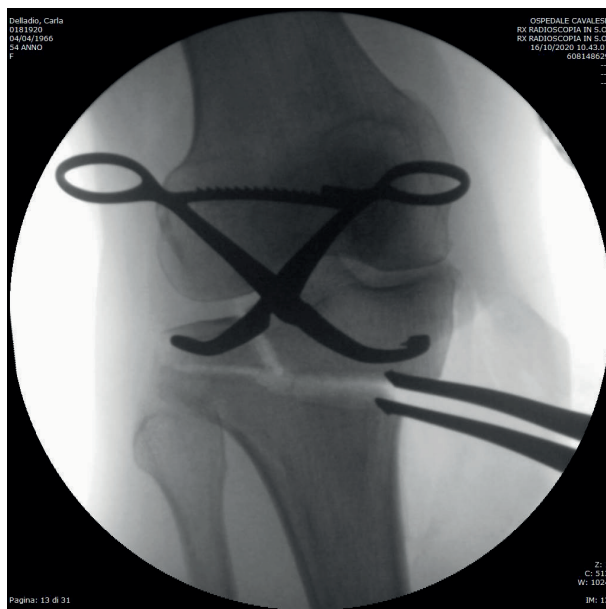
We found a 5 years survival rate of 92% for an uncomplicated OW-HTO and of 89% for an osteot-

omy complicated with a lateral tibial plateau fracture (Takeuchi Type III): these results appears very comforting and in line with previous studies that report a five years survival rate of OW-HTO between 73 and 99% (15). Keenan and the Finnish Registry reported a 5 years survivorship respectively of 84 and 89% (6); likewise Pannell described a survival rate of 80% at 5 years (7).

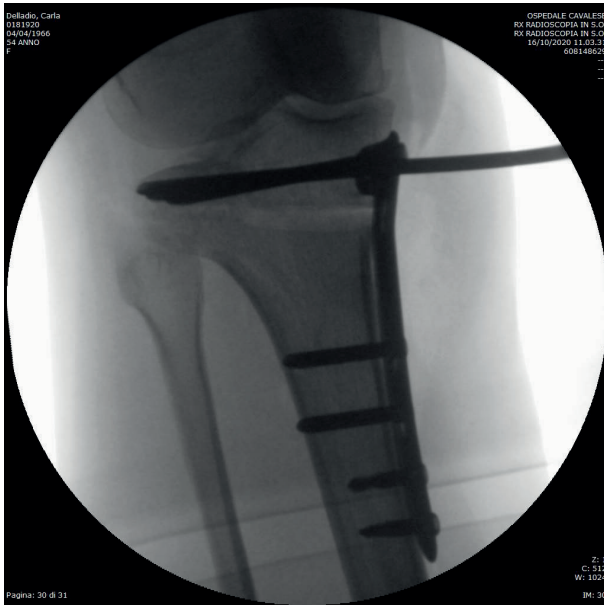Furthermore, patients who underwent OW-HTO burdened by a fracture of the lateral tibial plateau did not suffer from delayed union or non union of the osteotomy site. We hypothesized that this good result could depend both on the accurate reduction and stabilization of the fracture and on a more cautious rehabilitation protocol.

In our cases, a good reduction of the fracture of the lateral plateau was obtained with a large bone fragment clamp and the routine use of a long support plate (Figure 3). Stoffel et al previously described that, from a biomechanical point of view, the Tomofix plate does not need an additional lateral fixation in case of a fracture of the lateral hinge compared with a short Puddu plate (14) (Figure 4).

All the patients affected by a fracture of the lateral plateau extended to the joint underwent a more cau-



**Figure 3.** Intraoperative fluoroscopy shows the use of a large bone fragment clamp to reduce the intraoperative fracture of the tibial plateau



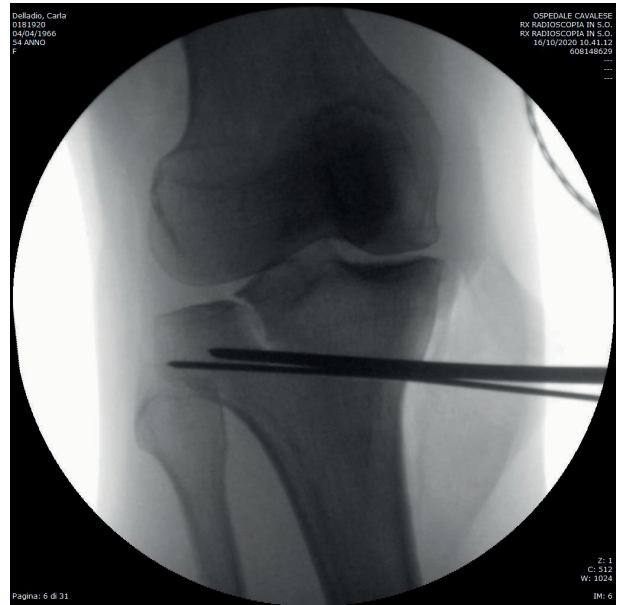
**Figure 4.** The routine use of a TomoFix plate permit to stabilize the fracture without the need of a lateral support plate.

tious post operative protocol, the same used in patients affected by a traumatic fracture of the tibial plateau; such program comprehends not weight bearing for one month and the use of an articulated brace.

Although Lee described an early viewable sign to detect an intra operative fracture of the lateral plateau (16), in all the patients of our series the diagnosis was made intra operatively with fluoroscopy. Differently with other studies, we had no cases in which the fracture was diagnosed after surgery or during the follow up (9).

In the present study, Takeuchi Type III fractures occurred in 7.9% of OW-HTO performed: although this percentage is not negligible, it appears in line with previous studies that report this complication between 5.6 and 11% (10, 11).

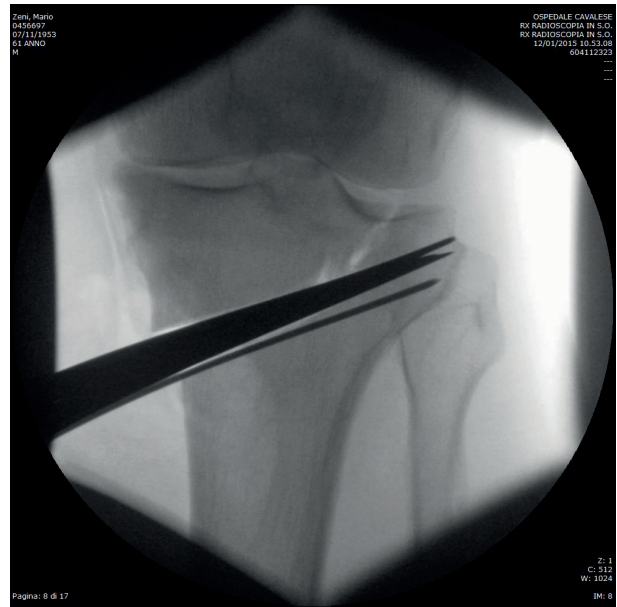We found in our series an overall fracture rate including Takeuchi type I and II fractures of 9.65%: such percentage is small if compared with most of the studies reporting this eventuality around 25% (9-12, 17). We believe that this data is the counterpart of a small rate of intra-articular fractures. Indeed, to avoid a lateral hinge fracture, the risk is to perform an insufficient osteotomy both at the anterior or the posterior lateral tibial cortices (10, 16, 20) (Figure 5): for this reason, some authors propose to intentionally cause a type I fracture in cases in which a high resistance



**Figure 5.** Intraoperative fluoroscopy demonstrates a Takeuchi Type III fracture occurring with incomplete osteotomy.

against the opening of the osteotomy is found thus not to create a fracture of the lateral plateau (18).

Another well known risk factor to produce an unintentional fracture of the tibial plateau that extend into the joint is an high endpoint level of the osteotomy in relation to the head of the fibula (11, 14) (Figure 6).



**Figure 6.** Intraoperative fluoroscopy demonstrates a Takeuchi Type III fracture occurring with high end osteotomy.

Although our results derive from a rather numerous series (114 surgical procedures) also compared with others present in the literature (6, 9, 11), the present study certainly has some limitations: a retrospective design of the study, the absence of statistical significance, the lack of a scoring system to test patient's satisfaction after an OW-HTO complicated by a fracture and the neglect of other complications that certainly occurred in the study (e.g. implant removal due to hardware intolerance) (17). Lastly, we haven't considered to perform weight bearing X-Rays at follow up and this did not allow us to evaluate any post operative loss of correction at the osteotomy site, especially when an intra operative fracture of the lateral plateau occurred. Although these limitations certainly have an impact on results, the mentioned aspects have not been deliberately taken into consideration as they do not represent the theme of the study.

## Conclusion

A major risk of an accidentally-incomplete osteotomy during an OW-HTO with the purpose to avoid a breakage of the lateral hinge is to create a fracture of the lateral tibial plateau.

Takeuchi type III fracture is an uncommon but serious complication to manage: in our case series we found that an early recognition and a correct treatment of this occurrence don't lead to a premature conversion to a knee arthroplasty if compared with an uncomplicated osteotomy.

Further studies are necessary to establish specific subjective outcomes after OW-HTO burdened by an intra articular fracture of the lateral plateau: lower outcomes have already been described in patients affected by a complication after OW-HTO (9).

**Acknowledgements:** Piero Giardini would like to thank Dr Molinari for the daily teachings, his colleagues for the affection of every day ... and Bea for the patience.

**Conflict of Interest:** Each author declares that he or she has no commercial associations (e.g. consultancies, stock ownership, equity interest, patent/licensing arrangement etc.) that might pose a conflict of interest in connection with the submitted article. Ethics approval was not required for this retrospective study.

## References

1. Cao Z, Mai X, Wang J, Feng E, Huang Y. Unicompartmental Knee Arthroplasty vs High Tibial Osteotomy for Knee Osteoarthritis: A Systematic Review and Meta-Analysis. *J Arthroplasty* 2018;33(3):952-959.
2. Wang Z, Zeng Y, She W, Luo X, Cai L. Is opening-wedge high tibial osteotomy superior to closing-wedge high tibial osteotomy in treatment of unicompartmental osteoarthritis? A meta-analysis of randomized controlled trials. *Int J Surg* 2018;60:153-163.
3. Sun H, Zhou L, Li F, Duan J. Comparison between Closing-Wedge and Opening-Wedge High Tibial Osteotomy in Patients with Medial Knee Osteoarthritis: A Systematic Review and Meta-analysis. *J Knee Surg* 2017;30(2):158-165.
4. Liu X, Chen Z, Gao Y, Zhang J, Jin Z. High Tibial Osteotomy: Review of Techniques and Biomechanics. *J Healthc Eng* 2019;2019:8363128.
5. Yoon JR, Ko SN, Jung KY, Lee Y, Park JO, Shin YS. Risk of Revision Following Total Knee Arthroplasty or High Tibial Osteotomy: A Nationwide Propensity-Score-Matched Study. *J Bone Joint Surg Am* 2019;101(9):771-778.
6. Keenan OJF, Clement ND, Nutton R, Keating JF. Older age and female gender are independent predictors of early conversion to total knee arthroplasty after high tibial osteotomy. *Knee* 2019;26(1):207-212.
7. Pannell WC, Heidari KS, Mayer EN, et al. High Tibial Osteotomy Survivorship: A Population-Based Study. *Orthop J Sports Med* 2019;7(12):2325967119890693.
8. Khoshbin A, Sheth U, Ogilvie-Harris D, et al. The effect of patient, provider and surgical factors on survivorship of high tibial osteotomy to total knee arthroplasty: a population-based study. *Knee Surg Sports Traumatol Arthrosc* 2017;25(3):887-894.
9. Han SB, In Y, Oh KJ, Song KY, Yun ST, Jang KM. Complications Associated With Medial Opening-Wedge High Tibial Osteotomy Using a Locking Plate: A Multicenter Study. *J Arthroplasty* 2019;34(3):439-445.
10. Takeuchi R, Ishikawa H, Kumagai K, et al. Fractures around the lateral cortical hinge after a medial opening-wedge high tibial osteotomy: a new classification of lateral hinge fracture. *Arthroscopy* 2012;28(1):85-94.
11. Dorofeev A, Tylla A, Benco M, Drescher W, Stangl R. Opposite hinge fractures in high tibial osteotomy: a displacement subtype is more critical than a fracture type. *Eur J Orthop Surg Traumatol* 2020;30(2):297-305.
12. Ogawa H, Matsumoto K, Akiyama H. The prevention of a lateral hinge fracture as a complication of a medial opening wedge high tibial osteotomy: a case control study. *Bone Joint J* 2017;99-B(7):887-893.
13. Song KY, Koh IJ, Kim MS, Choi NY, Jeong JH, In Y. Early experience of lateral hinge fracture during medial opening-wedge high tibial osteotomy: incidence and clinical outcomes. *Arch Orthop Trauma Surg* 2020;140(2):161-169.

14. Kim KI, Kim GB, Kim HJ, Lee SH, Yoon WK. Extra-articular Lateral Hinge Fracture Does Not Affect the Outcomes in Medial Open-Wedge High Tibial Osteotomy Using a Locked Plate System. *Arthroscopy* 2018;34(12):3246-3255.
15. Ekeland A, Nerhus TK. Editorial Commentary: High Tibial Osteotomy for Varus Knees With Medial Osteoarthritis May Prevent Total Knee Arthroplasty. *Arthroscopy* 2020;36(2):544-545.
16. Lee SC, Kim SJ, Jung KA, Choi DH, Hwang BY. An early sign of intraarticular fracture of the lateral tibial plateau during opening wedge high tibial osteotomy. *Knee* 2013;20(1):66-8.
17. Sidhu R, Moatshe G, Firth A, Litchfield R, Getgood A. Low rates of serious complications but high rates of hardware removal after high tibial osteotomy with Tomo-fix locking plate. *Knee Surg Sports Traumatol Arthrosc* 2021;29(10):3361-3367.
18. Yokoyama M, Nakamura Y, Doi H, Onishi T, Hirano K, Doi M. Stress fractures of the lateral tibial plateau after open wedge high tibial osteotomy could be delayed type III lateral hinge fractures. *Asia Pac J Sports Med Arthrosc Rehabil Technol* 2019;18:23-27.

Received: 1 November 2021

Accepted: 20 December 2021

Correspondence:

Piero Giardini, MD

Department of Orthopaedics and Traumatology,

Cavalese Hospital,

Via dei Dossi 17

38033 Trento - Italy

Phone: +39 3405566971

E-mail: piero.giard@gmail.com