

Case Report

Diabetic Ketoacidosis as the Initial Presenting Symptom of Pancreatic Adenocarcinoma: A Discussion about Screening Utilizing ENDPAC Scoring Coupled with CT Scans and Endoscopic Ultrasound

Sasmith R. Menakuru Adelina Priscu Vijaypal Singh Dhillon
Ahmed Salih

Internal medicine, Indiana University Health, Ball Memorial Hospital, Muncie, IN, USA

Keywords

Diabetic ketoacidosis · Pancreatic adenocarcinoma · Computed tomography scan · Enriching new-onset diabetes for pancreatic cancer score

Abstract

Pancreatic adenocarcinoma is often discovered at an advanced stage due to a lack of early symptomology, resulting in this being the fourth leading cause of cancer-related death in the USA. The relationship between diabetes mellitus and pancreatic cancer has been known for many years; however, it is not well understood. Studies have suggested that long-standing type 2 diabetes mellitus can increase the risk of pancreatic cancer by 1.5–2.0-fold. However, patients with new-onset diabetes over 50 years of age have an 8-fold higher risk of pancreatic cancer. Evidence has shown that pancreatic cancer causes diabetes, with the majority being new onset. Diabetic ketoacidosis, which occurs in long-term hyperglycemia, as an initial presentation of pancreatic adenocarcinoma is rare, and only a few cases have been reported. It is postulated that pancreatic cancer prevents insulin-producing cells of the pancreas from responding to insulin resistance. The enriching new-onset diabetes for pancreatic cancer (ENDPAC) score may be utilized as a screening tool for pancreatic carcinomas as an early diagnosis may lead to cure by surgery instead of the grave prognosis associated with it. In this case report, we discuss a 52-year-old female presenting with symptoms of diabetic ketoacidosis who was then subsequently found to

have stage-4 pancreatic adenocarcinoma. We concluded that if a patient presents with new-onset diabetes, abdominal imaging with CT scans and endoscopic ultrasound may be warranted to rule out pancreatic carcinoma.

© 2022 The Author(s).
Published by S. Karger AG, Basel

Introduction

More than 60,000 new cases of pancreatic exocrine cancer occur in the USA each year, and adenocarcinoma of the pancreas makes up 90% of the cases. It is currently the fourth leading cause of cancer-related deaths in the USA, and almost all are expected to die from the disease [1]. This is due to the late diagnosis of most patients with pancreatic cancer, as there is a lack of established guidelines for screening. Symptoms typically include abdominal pain, weight loss, anorexia, asthenia, and obstructive jaundice. The link between pancreatic cancer and diabetes is not clearly defined; however, 1 in 100 cases of newly diagnosed diabetes mellitus is reported to be attributed to pancreatic cancer [2]. Surgical resection is currently the only chance of cure and would only be possible if pancreatic cancer is detected early using screening methods. Resection of pancreatic adenocarcinoma has also been shown to improve diabetes mellitus and insulin resistance, further establishing a relationship between diabetes and pancreatic adenocarcinoma [3]. Patients with diabetes mellitus diagnosed less than 4 years ago had a 50% higher risk of pancreatic cancer than individuals who had diabetes for more than 4 years [4]. Adrenomedullin, a pluripotent hormone, is overexpressed in pancreatic adenocarcinoma and has been shown to be a potential mediator of beta-cell dysfunction [3]. Eight-five percent of patients with pancreatic adenocarcinoma presented with new-onset hyperglycemia at diagnosis [5]. Diabetic ketoacidosis (DKA) on presentation, however, is rare and is typically seen only in pancreatic endocrine tumors. The enriching new-onset diabetes for pancreatic cancer (ENDPAC) score coupled with computed tomography (CT) and endoscopic ultrasound may be the best option for screening pancreatic cancer and may lead to better outcomes.

Case Presentation

A 52-year-old woman, without significant medical history, was brought to the hospital due to episodes of confusion. Her husband stated that she had lost weight, was increasingly lethargic, and complained of extreme thirst and polyuria. She had a remote history of mild alcohol use but had not been drinking for over 20 years and does not smoke. She has never traveled abroad and had no family history of diabetes or cancer. During her last two primary care visits the year prior, it was noted that the patient had developed new-onset hyperglycemia. The patient's hemoglobin A1C was taken during her second visit, which came back at 8.9%. All other laboratory investigations at that time were within normal limits, and she had no complaints at each of the previous visits. She was contacted over the phone to inform her of her results, but she thought it was not anything to worry about, despite informing her about the need for intervention for her new-onset diabetes. She declined to come in for a follow-up appointment and opted to make lifestyle changes as she was a healthy individual. She was lost to follow-up after that visit and was next seen in the inpatient setting.

The patient was not alert or oriented to time, place, or person. Examination revealed a female in mild distress, with a heart rate of 122 beats/min, blood pressure of 100/80 mm Hg,

respiratory rate of 22 breaths/min, oxygen saturation of 97% on room air, and a temperature of 37.1°C. She had fruity-smelling breath, skin tenting, a dry tongue, and decreased tonus. Cardiovascular, respiratory, and abdominal examinations on auscultation, and palpation were normal. Laboratory studies were consistent with DKA, and the patient was subsequently admitted to the intensive care unit. Pertinent serum chemistry values were as follows: pH 7.18 (7.36–7.44), bicarbonate 14 mmol/L (22–29), lactate 2.4 mmol/L (0.5–2.2), calcium 10.7 mg/dL (8.5–10.5), glucose 344 mmol/L (70–99), ketones 7.8 mmol/L (<3), amylase 721 IU/L (40–140), lipase 1,234 IU/L (7–59), bilirubin 3.8 mg/dL (0–1.0), AST 98 IU/L (13–39), ALT 103 IU/L (7–52), alkaline phosphatase 167 IU/L (25–125), blood urea nitrogen 34 mg/dL (5–20), and a WBC count 24.0 k/mm³ (3.6–10.6). Chest radiograph, EKG, urine drug screen, and CT head were within normal limits. Urine and blood cultures returned negative 2 days later. HbA1C was 13.9% (4–6%), the C-peptide level was low at 1.0 ng/dL (1.1–4.4 ng/dL), and the insulin level was also low at 1.2 µIU/mL (2.6–24.9 µIU/mL). Anti-glutamate decarboxylase and anti-islet cell antibodies were negative as well. On day three, her overall function improved, and only then did she give a history of mid-epigastric abdominal pain for the past month, which was something she did not consider important enough to seek medical attention.

Workup was started for a possible pancreatic etiology due to her elevated bilirubin, alkaline phosphatase, and lipase. The abdomen-pelvis CT with IV contrast showed an ill-defined hypodense mass in the body of the pancreas with surrounding necrotic-appearing lymphadenopathy. The findings were suspicious of pancreatic adenocarcinoma. A positron emission tomography scan showed hypermetabolic pancreatic body mass with numerous metastatic lymph nodes throughout the mediastinum, left hilum, and within the retroperitoneum (Fig. 1). There are also a few hypermetabolic foci within the liver suspicious for

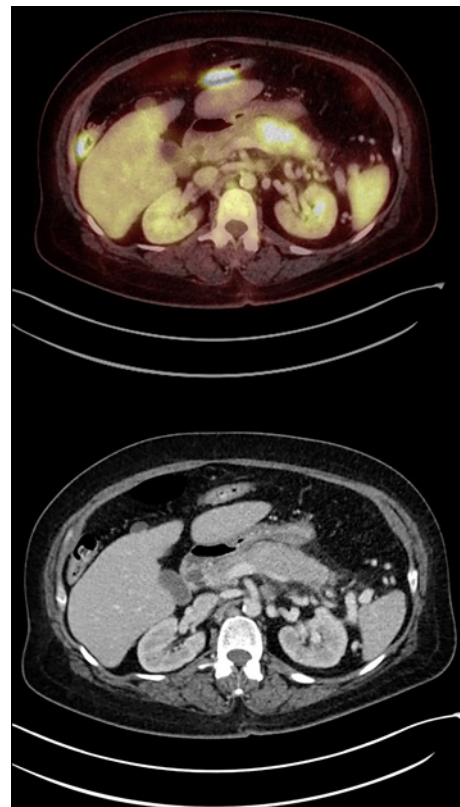


Fig. 1. CT and positron emission tomography scan showing pancreatic adenocarcinoma.

metastatic disease. The pancreatic mass encased and occluded the splenic vein, with numerous venous collaterals present in the left upper quadrant. Levels of carbohydrate antigen 19-9 and carcinoembryonic antigen were elevated at 251 U/mL (0–37 U/mL) and 5.5 ng/mL (0–2.5 ng/mL), respectively. A biopsy of the pancreas and a mediastinal lymph node was performed, revealing pancreatic adenocarcinoma. She was treated with intravenous insulin and fluids. By day 3, her symptomatology resolved, and by day 4, laboratory values related to her DKA normalized. She was transitioned to basal-bolus subcutaneous insulin. Palliative care and hematology-oncology were consulted, and due to the patient being diagnosed with stage-4 pancreatic cancer, the ultimate decision was to pursue hospice. Palliative chemotherapy was offered, but she refused. The patient passed away 2 months later.

At the time of new-onset diabetes, the patient would have had an ENDPAC score of 7, which would have prompted a workup (Table 1; Fig. 2) [6]. Her new-onset diabetes in a patient without any significant medical history should have given rise to a clinical suspicion of pancreatic adenocarcinoma. The authors suspect that if she had been told about the seriousness of new-onset diabetes, she may have followed up in the clinic setting and would have gotten the necessary screening measures after her ENDPAC score was calculated.

Discussion

DKA may be precipitated by infections, stress, myocardial infarction, poor compliance with medications, and exocrine pancreatic tumors, such as glucagon-secreting islet cell neoplasms, but presentation with pancreatic adenocarcinoma is exceedingly rare. Our patient presented with DKA, weight loss, and mild abdominal pain. Her sudden DKA, labs, and abdominal pain prompted abdominal imaging. CT imaging showed signs of pancreatic adenocarcinoma that was proven by biopsy. Insulin and C-peptide levels were both decreased, suggesting that insulin deficiency was present. The patient was diagnosed as having DKA on presentation due to pancreatic adenocarcinoma stage 4, with previously diagnosed but untreated diabetes mellitus.

DKA is a severe complication of diabetes mellitus characterized by severe hyperglycemia and metabolic acidosis caused by absolute or relative insulin deficiency. Pancreatic adenocarcinoma is not known to be a presentation, complication, or cause of DKA [7]. Multiple theories have been postulated in an effort to investigate whether diabetes is a cause or a result of pancreatic cancer or if they simply coexist without causality. Long-term diabetes increases the risk of pancreatic cancer, and up to 80% of patients with pancreatic cancer have diabetes or impaired glucose tolerance at the time of diagnosis [3, 4]. A study by Yalniz and Pour [8] showed that long-standing type 2 diabetes mellitus could predispose to pancreatic cancer by altering islet cells either by direct carcinogenesis or by a diabetogenic substance released by cancer cells. Cersosimo et al. [9] proved that peripheral insulin resistance leading to hyperinsulinemia and the concurrent impairment of beta-cell response to glucose are the primary mechanisms of the development of diabetes in pancreatic cancer. According to a meta-analysis performed by Ben et al. [10], findings suggested that there was a two-fold increase in pancreatic cancer rates in new-onset diabetes, and patients diagnosed with diabetes less than 4 years earlier have a 50% higher risk of developing pancreatic adenocarcinoma compared to patients with long-term diabetes (those who have had diabetes for more than 5 years). Batabyal et al. [11] stated that the association between the diagnoses of diabetes less than 1 year before pancreatic adenocarcinoma was much more significant, showing that new-onset diabetes or worsening glycemic control could be used as an indicator. These findings are further supported as patients who undergo resection for pancreatic adenocarcinoma have improvements in their blood sugar levels [12]. The authors thereby conclude that more

Table 1. ENDPAC scoring system parameters [6]

Blood glucose categories		Change in blood glucose category score
		new-onset diabetes minus blood glucose at 1 year (A)
blood glucose range, mg/dL	score	score range
Blood glucose category at 1 year prior to the onset		1–4
<100	1	
100–109	2	
110–125	3	
Blood glucose category at glycemically defined new-onset diabetes		
126–160	4	
>160	5	
Change in weight categories		Change in weight score (B)
Change in weight, kg	Score	Score range
≤−6.0	+6	−6 to +6
−5.9 to −4.0	+4	
−3.9 to −2.0	+2	
−1.9 to +1.9	0	
+2.0 to +3.9	−2	
+4.0 to 5.9	−4	
≥+6.0	−6	
Age, years at glycemically defined new-onset diabetes		Age score (C)
Age range	Score	Score range
≤59	−1	−1 to +1
60–69	0	
≥70	+1	
Total score		A + B + C

In the case presented, the patient had a blood glucose of 101 mg/dL from her yearly PCP appointment the year prior to new-onset glycemically defined diabetes which would give her a score of 1 in that category. Her blood glucose the year afterward was found to be 161 mg/dL and 210 mg/dL, which would be a score of 5. At that time, her A1C was also found to be 8.9%, indicating new-onset diabetes. The total score for category A was 4. The year prior, her weight was 85 kg prior to new-onset diabetes, and her weight afterward was 79.2 kg, which would be a 5.8 kg change. Therefore, the score in category B would be +4. Given that her age was 52 years at glycemically defined new onset of diabetes, her score in category C would be −1. Her total score was 4+4−1, resulting in a total of 7.

research has to be done on the relationship between new-onset diabetes mellitus, DKA, and its relationship with the carcinogenesis of pancreatic adenocarcinomas.

Currently, there are inconclusive data on the connection between diabetes mellitus and pancreatic cancer. Pancreatic cancer is usually diagnosed in advanced stages and has a bleak prognosis, with a 5-year survival rate of less than 5% [7]. No screening test sensitive and specific enough is available for the detection of early pancreatic cancer in the general population. As stated above, more data are needed to determine if patients with new-onset hyperglycemia should be screened for pancreatic cancer. Gangi et al. [13] suggested that the usage

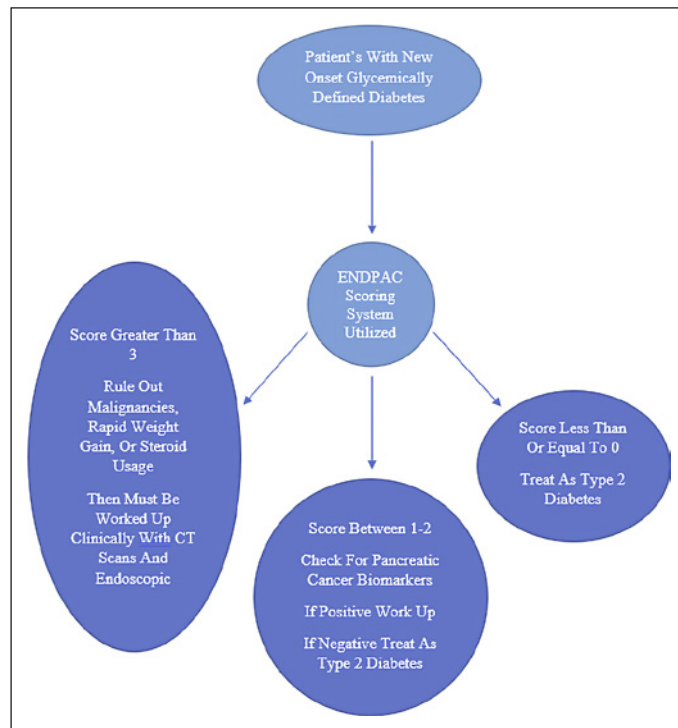


Fig. 2. Approach to utilizing the ENDPAC scoring system [6].

of CT scans can detect a significant proportion of asymptomatic pancreatic cancers before the clinical diagnosis and that CT scans could be utilized as a screening measure in at-risk patients. An ENDPAC score has been proposed as a way to identify subgroups of new-onset diabetes subjects at high risk for pancreatic cancer based on age, amount of weight loss, and rise in blood sugar before new-onset diabetes [6]. A high ENDPAC score is able to identify a subset of patients that have a 30- to 40-fold risk of developing pancreatic cancer in a study proven by Khan et al. [14]. Schwartz et al. [15] found that the cost associated with the detection of pancreatic adenocarcinoma by CT scan in patients with new-onset diabetes is cost-effective in the USA, even if only a few patients with detected pancreatic adenocarcinoma are resectable. The NIH has been enrolling subjects with high ENDPAC scores to perform CT scans to establish new screening guidelines.

DKA as presentation is not the norm in pancreatic adenocarcinoma, and recognition of new-onset diabetes or hyperglycemia as a potential early sign of pancreatic cancer could help in the diagnosis of the early-stage, asymptomatic pancreatic carcinomas [5]. If the clinical situation of DKA is unusual with no precipitating factors, the authors believe that physicians should consider pancreatic cancer as a possible cause. Our patient had developed new-onset hyperglycemia and had an elevated A1C within 1 year of diagnosis, indicating that she had new-onset diabetes mellitus most likely caused by her pancreatic adenocarcinoma. We believe that if a strong proven relationship between new-onset diabetes or hyperglycemia and pancreatic adenocarcinoma can be established, then screening tests first with an ENDPAC score and then either a CT scan or endoscopic ultrasound of the abdomen may be warranted, as early detection may be able to establish an early diagnosis which could be cured by resection. Pancreatic cancer is fatal due to late diagnosis and lack of targeted therapy, as only 15–20% of patients can receive a pancreatectomy after presentation. There must be more research on the treatment of pancreatic carcinoma, and we hope there are new developments with the possibility of cure in the future, but for now, the best

method we have for cure is surgical resection by early diagnosis. Our patient had a high ENDPAC score as she had weight loss, was over 50 years of age, and had new-onset hyperglycemia. If she had been screened by a CT scan or endoscopic ultrasound, the outcome may have been different. We believe that if a patient presents with new-onset hyperglycemia or newly diagnosed type 2 diabetes mellitus without a history of previous diabetes, an ENDPAC score should be performed, and if high, abdominal imaging may be warranted to check for pancreatic cancer, as early diagnosis may lead to cure with resection instead of the fatal outcomes typically associated with it.

Statement of Ethics

Written informed consent was obtained from the patient's next of kin for publication of the details of their medical case and any accompanying images. This retrospective review of patient data did not require ethical approval in accordance with local/national guidelines.

Conflict of Interest Statement

The authors have no conflicts of interest to declare.

Funding Sources

No funding was required for the case report.

Author Contributions

Sasmith Menakuru saw the case, wrote the case, and did research on the topic. Adelina Priscu, Vijaypal Singh Dhillon, and Ahmed Salih helped with the research and in editing the case.

Data Availability Statement

All data generated or analyzed during this study are included in this article. Further inquiries can be directed to the corresponding author Sasmith R. Menakuru.

References

- 1 Saad AM, Turk T, Al-Husseini MJ, Abdel-Rahman O. Trends in pancreatic adenocarcinoma incidence and mortality in the United States in the last four decades: a SEER-based study. *BMC Cancer*. 2018 Jun 25;18(1):688.
- 2 Li D. Diabetes and pancreatic cancer. *Mol Carcinog*. 2012;51(1):64–74.
- 3 Chari ST. Mechanism(s) of pancreatic cancer-induced diabetes. *J Pancreas*. 2014;15(5):2777.
- 4 De Souza A, Irfan K, Masud F, Saif MW. Diabetes type 2 and pancreatic cancer: a history unfolding. *JOP*. 2016;17(2):144–8.
- 5 Pannala R, Basu A, Petersen GM, Chari ST. New-onset diabetes: a potential clue to the early diagnosis of pancreatic cancer. *Lancet Oncol*. 2009;10(1):88–95.
- 6 Sharma A, Kandlakunta H, Nagpal SJS, Feng Z, Hoos W, Petersen GM, et al. Model to determine risk of pancreatic cancer in patients with new-onset diabetes. *Gastroenterology*. 2018;155(3):730–9.e3.

- 7 Lee KA, Park KT, Kim WJ, Park TS, Baek HS, Jin HY. Diabetic ketoacidosis as a presenting symptom of complicated pancreatic cancer. *Korean J Intern Med*. 2014;29(1):116–9.
- 8 Yalniz M, Pour PM. Diabetes mellitus: a risk factor for pancreatic cancer? *Langenbeck's Arch Surg*. 2005;390(1):66–72.
- 9 Cersosimo E, Pisters PW, Pesola G, McDermott K, Bajorunas D, Brennan MF. Insulin secretion and action in patients with pancreatic cancer. *Cancer*. 1991 Jan 15;67(2):486–93.
- 10 Ben Q, Xu M, Ning X, Liu J, Hong S, Huang W, et al. Diabetes mellitus and risk of pancreatic cancer: a meta-analysis of cohort studies. *Eur J Cancer*. 2011;47(13):1928–37.
- 11 Batabyal P, Vander Hoorn S, Christophi C, Nikfarjam M. Association of diabetes mellitus and pancreatic adenocarcinoma: a meta-analysis of 88 studies. *Ann Surg Oncol*. 2014;21(7):2453–62.
- 12 Permert J, Ihse I, Jorfeldt L, von Schenck H, Arnquist HJ, Larsson J. Improved glucose metabolism after subtotal pancreatectomy for pancreatic cancer. *Br J Surg*. 1993;80(8):1047–50.
- 13 Gangi S, Fletcher JG, Nathan MA, Christensen JA, Harmsen WS, Crownhart BS, et al. Time interval between abnormalities seen on CT and the clinical diagnosis of pancreatic cancer: retrospective review of CT scans obtained before diagnosis. *AJR Am J Roentgenol*. 2004;182(4):897–903.
- 14 Khan S, Safarudin RF, Kupec JT. Validation of the ENDPAC model: identifying new-onset diabetics at risk of pancreatic cancer. *Pancreatol*. 2021;21(3):550–5.
- 15 Schwartz NRM, Matrisian LM, Shrader EE, Feng Z, Chari S, Roth JA. Potential cost-effectiveness of risk-based pancreatic cancer screening in patients with new-onset diabetes. *J Natl Compr Canc Netw*. 2021 Jun 21;20(5):451–9.