

CLINICO-PATHOLOGIC REVIEW OF BIOPSIED TONGUE LESIONS IN A NIGERIAN TERTIARY HOSPITAL

T.J. Lasisi^{1,2} and T.A. Abimbola²

1. Department of Physiology and Oral Pathology, College of Medicine, University of Ibadan, Ibadan, Nigeria
2. Department of Oral Pathology, University College Hospital, Ibadan, Nigeria.

Correspondence:

Dr. T.J. Lasisi

Dept. of Oral Pathology,
University College Hospital,
Ibadan, Nigeria
E-mail: jameelahlasisi@yahoo.com

ABSTRACT

Background: Varying pathologic conditions can affect the tongue for which the pattern of occurrence may differ. The aim of this study was to review the clinico-pathologic features of histologically diagnosed cases of tongue lesions that presented in our hospital over a 21 years period.

Materials and Methods: Data on habits, class of lesion, histological diagnosis, age, gender, and site distributions were analyzed using descriptive frequencies, ranges and means \pm SD. Variables were compared using Chi square and ANOVA tests as appropriate. Sites of lesions were coded using the WHO ICD-O code on topography.

Results: Tongue lesions were seen in 43 males and 31 females. There was a bimodal peak age of occurrence at 40-49 and 60-69 years of age. Smoking and alcohol intake habits were recorded in 8 cases only. Neoplastic lesions constituted 78.4% of the cases. Using the WHO ICD-O code for topography of lesions, the tongue dorsum (ICD-O-2.0) was the most commonly affected site. Malignant lesions constituted 47.3% of the cases seen. Also, 8.6% of the malignant lesions were seen in younger patients (< 40 years).

Conclusions: Tongue lesions showed a bimodal age of occurrence with neoplastic lesions as the most histologically diagnosed lesions in our study.

Keywords: Tongue, Clinico-pathology, Squamous cell carcinoma, Non-neoplastic lesions

INTRODUCTION

The tongue is an important muscular structure in the oral cavity involved in the critical functions of taste, speaking, chewing and swallowing.¹ The condition of the tongue has been considered a good reflection of many systemic diseases^{2,3}. However, varying pathologic conditions may affect the tongue of which chronic lesions often necessitate biopsy and histological diagnosis.⁴ Most studies that reviewed tongue lesions were based on clinical assessment only. However, the pattern of occurrence of histologically diagnosed tongue lesions may vary across the globe. Generally, few studies⁵⁻⁷ have reported clinico-pathologic review of histologically diagnosed tongue lesions which are mostly case specific. More importantly, none of these studies were from our environment. Thus, the aim of this study was to review the clinic-pathologic features of histologically diagnosed cases of tongue lesions that was presented in our hospital within the last 21 years (1995-2015) and also provide a reference data base from the region.

MATERIALS AND METHODS

This is a retrospective cross-sectional study of cases of tongue lesions seen between January 1995 and December 2015. Biopsy records of all histologically diagnosed cases seen in the Oral Pathology department

of the University College Hospital Ibadan, Nigeria within the period were retrieved and included. Data on habit, class of the lesion, histological diagnosis, age, gender and site of lesions were analyzed descriptively using frequencies, ranges and means \pm SD. Variables were compared using Chi square and ANOVA tests as appropriate. Patients were also grouped into either young (<40 years) or old (>40 years) age groups based on previous report of different clinicopathologic behavior of tongue lesions in the two age groups.^{8,9} Sites of lesions were coded using the WHO ICD-O code on topography.

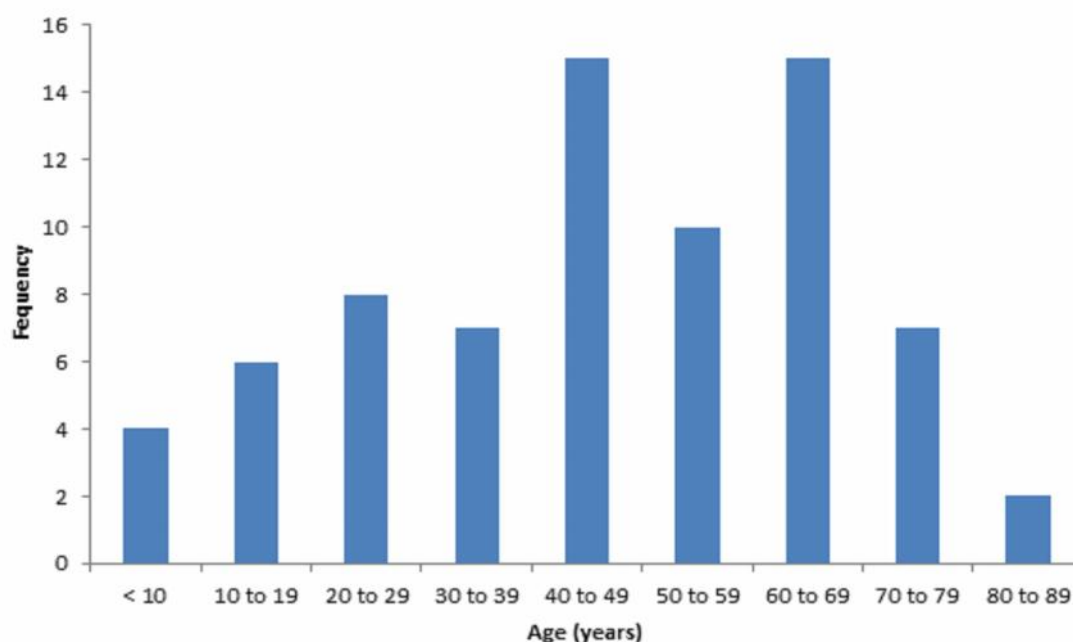
RESULTS

A total of 1807 biopsy cases were diagnosed during the period of which 74 cases (4%) were tongue lesions. The histological diagnoses of the lesions are shown in Table 1. The lesions were seen in 43 males and 31 females with a male to female ratio of 1.4:1. The mean age of occurrence was 46.41 ± 21.13 years (range = 1 to 92 years). The distribution of the lesions based on age group is shown in figure 1. There was a bimodal peak age of occurrence at 40-49 and 60-69 years. Gender distribution of the various classes of tongue lesions are shown in Table 2.

Table 1: Histological diagnoses of tongue lesions

Histological Diagnosis	Number of cases	Percentage
Neoplastic lesions		
Squamous cell carcinoma	30	40.5
Fibroma	6	8.1
Fibroepithelial polyp	3	4.0
Papilloma	4	5.4
Hemangioma	3	4.0
Lymphangioma	3	4.0
Adenoid cystic carcinoma	1	1.4
Fibrolipoma	1	1.4
Leiomyoma	1	1.4
Peripheral giant cell tumor	1	1.4
Alveolar soft part sarcoma	1	1.4
Kaposi sarcoma	1	1.4
Non Hodgkin lymphoma	2	1.4
Granular cell tumor	1	2.7
Non-neoplastic lesions		
Pyogenic granuloma	9	12.1
Amyloidosis	1	1.4
Papillary hyperplasia	1	1.4
Harmatoma	1	1.4
Leukoplakia	1	1.4
Reactive lesion	3	4.0
Total	74	100

History of both smoking and alcohol intake was positive in only 8 cases (10.8%) out of which 7 cases (87.5%) were squamous cell carcinoma. In addition, habit of alcohol intake only was recorded in 3 cases (4.1%) while the remaining 63 cases (85.1%) did not indicate either of the habits.

**Figure 1:** Age group distribution of tongue lesions**Table 2:** Gender distribution of classes of tongue lesions

Type of lesion	Male	Female	Total
Neoplastic			
Benign	11 (47.8%)	12 (52.2%)	23 (31.1%)
Malignant	21 (60%)	14 (40%)	35 (47.3%)
Non-neoplastic			
Inflammatory	9 (69.2%)	4 (30.8%)	13 (17.6%)
Non-inflammatory	2 (66.7%)	1 (33.3%)	3 (4%)
Total	43 (58.1%)	31 (41.9%)	74 (100%)

Table 3: ICD-O site distribution of cases based on type of neoplastic lesion

ICD-O Site	Benign	Malignant	Total
Base of tongue	0	9 (100%)	9 (15.5%)
Dorsum of tongue	16 (59.3%)	11 (40.7%)	27 (46.6%)
Border of tongue	4 (28.6%)	10 (71.4%)	14 (24.1)
Ventral Surface	2 (40%)	3 (60%)	5 (8.6%)
Overlapping tumor	1 (33.3%)	2 (66.7%)	3 (5.2%)
Total	23 (39.7%)	35 (60.3%)	58 (100%)

Distribution of the lesions into locations (anterior two-third and posterior one-third) showed that lesions involving the anterior two-third were most commonly seen (Figure 2). Using the WHO ICD-O code for topography of lesions, the tongue dorsum (ICD-O-2.0) constituted 48.6%, border of the tongue (ICD-O-2.1) constituted 24.3%, base of the tongue (ICD-O-1.9) constituted 12.2%, ventral surface of the tongue (ICD-O-2.2) constituted 9.5% and overlapping sites (ICD-O-2.8) constituted 5.4%. The ICD-O site

Table 4: ICD-O site distribution of lesions based on side of the tongue

ICD-O Site	Right	Left	Bilateral	Midline	Total
Base of tongue	2 (22.2%)	2 (22.2%)	4 (44.4%)	1 (11.1%)	9 (12.2%)
Dorsum of tongue	5 (13.9%)	7 (19.4%)	14(38.9%)	10 (27.8%)	36 (48.6%)
Border of tongue	12 (66.7%)	5 (27.8%)	1 (5.5%)	0	18 (24.3%)
Ventral Surface	1 (14.3%)	2 (28.6%)	3 (42.8%)	1 (14.3%)	7 (9.5%)
Overlapping tumor	0	3 (75%)	1 (25%)	0	4 (5.4%)
Total	20 (27%)	19 (25.7%)	23 (31.1%)	12 (16.2%)	74 (100%)

distributions of lesions based on class of lesion (neoplastic or non-neoplastic), type of neoplastic lesion (benign or malignant) and side of the tongue involved are shown in figure 1 as well as Tables 3 and 4.

Neoplastic lesions constituted 78.4% with bimodal peak of age group of occurrence (40 to 49 years and 60 to 69 years while non-neoplastic lesions constituted 21.6% with peak of occurrence in the age group 10 to 19 years. Forty-one cases (70.8%) out of the neoplastic lesions were seen in the older age group (> 40 years), while 17 cases (29.2%) were seen in younger age patients (< 40 years). Out of the neoplastic lesions, malignant lesions constituted 60.3% of the cases seen with peak age group of occurrence of 60 to 69 years, while benign lesions constituted 39.7% with a peak

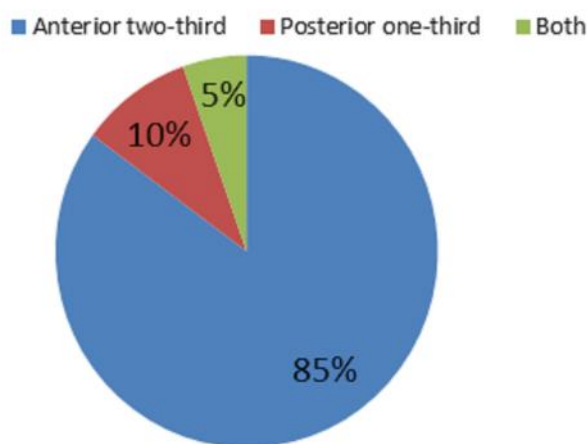


Figure 2: Distribution of lesions based on part of the tongue involved

age group of occurrence of 20 to 29 years. Out of the 16 non-neoplastic lesions, 12 cases were inflammatory or reactive lesions while 3 cases were non-inflammatory lesions. The malignant lesions constituted 91.4% of the lesions seen in the older patients (> 40 years) and 8.6% of those in the younger patients (< 40 years). Out of the 35 cases of malignant lesions, 31 (88.6%) were carcinomas while 2 cases (5.7%) each were sarcomas and lymphomas.

DISCUSSION

In this study, tongue lesions constituted an appreciable percentage (4%) of all histologically diagnosed cases of oral pathologic conditions in our institution. Our finding is almost similar to a recent report in a retrospective analysis of oral biopsies in Iran that documented 3.7% cases of tongue lesions.¹⁰ However, our finding is contrary to the previous reports by Alaeddini *et al.*¹¹, which indicated that tongue lesions constituted 6.3% of all the histo-pathologic cases seen at their center. The lower percentage from our results may be due the study population and the differences in the duration of the studies. The duration of our study was shorter when compared with that of Alaeddini *et al.*¹¹ Also, higher prevalence of oral lesions has been reported in their population, due to habits of tobacco use.

Neoplastic lesions were the most commonly diagnosed tongue lesions in this review. This finding may be explained by the design of the study which included only histologically diagnosed tongue lesions. While studies that reviewed tongue lesions based mostly on clinical presentations of patients reported higher prevalence of benign lesions,¹²⁻¹⁴ those that involved histologically diagnosed cases,^{11,15} reported higher prevalence of neoplastic lesions similar to our finding. However, contrary to our finding, a study that reviewed histologically diagnosed cases of tongue lesions from Brazilian population documented higher prevalence of non-neoplastic lesions. In their study, non-neoplastic lesions of the tongue constituted 53.5%.¹⁶

The age groups mostly affected by tongue lesions with specific consideration to neoplastic tongue lesion were the 40 to 49 years and the 60 to 69 years age groups which are similar to previous studies.^{11,16} According to Kantola *et al.*¹⁷, 91% of patients with tongue cancer were older than 40 years. However, the peak age group of non-neoplastic tongue lesions was 10 to 19 years. These findings indicate that neoplastic tongue lesions affected older age groups whereas non-neoplastic tongue lesions affected younger age groups. Advancing age is the most significant risk factor for cancer overall, and for several discrete cancer types. According to a

recent statistical data from National Cancer Institute's Surveillance, Epidemiology, and End Results program, the median age of a cancer diagnosis is 66 years. It has been known for years that age is a leading risk factor for the development of many types of cancer, but why aging increases cancer risk remains unclear. A study suggested that the accumulation of age-related changes in a biochemical process involved in genes control may be responsible for some of the increased risk of cancer seen in older people.¹⁸ It was proposed that DNA methylation, or the binding of chemical tags, called methyl groups, onto DNA, may be involved. Methyl groups activate or silence genes, by affecting interactions between DNA and the cell's protein-making machinery. It was reported that 70-90 percent of the sites associated with age showed significantly increased methylation in all cancer types studied. Thus age-related methylation may incapacitate the expression of certain genes, making it easier for cells to transform to cancer.¹⁸

The anterior two-thirds of the tongue was the most commonly involved location for benign malignant lesions. The tongues' dorsum was the most commonly affected site. All the lesions that involved the base of the tongue were malignant neoplastic lesions. The percentage of lesions at the base of the tongue was much less than what obtained in some other regions.^{19,20} This may be related to the fact that habits like placement of carcinogenic substances in the base of the tongue as well as the floor of the mouth which has been implicated in the etiology of oral cancer are not widely practiced in our environment.^{21,22} Tobacco smoking and chewing, betel chewing and alcohol consumption are all more commonly consumed where tongue malignancies are highly prevalent.^{23,24} Positive history of smoking and alcohol intake (the most implicated etiological factor in oral neoplastic lesions) was recorded in a very few cases of lesions studied. This finding is similar to a previous report²¹ suggestive of other etiological causes of oral lesions in our environment. The differential diagnosis for lesions of the tongue vary from non-neoplastic to neoplastic and those involving the base of the tongue may include normal lymphatic tissue, ectopic thyroid tissue, lymphoma, lipoma, hemangioma, schwannoma, granular cell tumors, benign and malignant tumors of minor salivary gland origin, rhabdomyosarcoma, and metastatic disease.

Of the neoplastic tongue lesions reviewed, majority were histologically diagnosed as malignant lesions similar to previous reports.^{11,16} Malignancies were commoner in the older age group compared with the younger age group in keeping with the trend worldwide. This age group had lesions in the base of

the tongue, a trend completely not noticed in the younger age group in this study.

Tongue cancers constitute a significant proportion of oral cancers majority of which are SCC.²⁵⁻²⁷ Studies in Nigeria have documented lower prevalence of tongue SCC compared to studies from non-Nigerian populations. Oji and Chukwunke²⁸ and Effiom *et al.*²⁵ reported that tongue cancer constituted 30% and 17.4% respectively of all oral cancer cases seen in their studies. Also, Lasisi *et al.*²² reported 21 cases (13.5%) of tongue SCC of which 79.2% constituted well differentiated histological type. However, higher prevalence of tongue SCC has been reported in other populations. Hernandez-Guerrero *et al.*²⁹, in an epidemiological study showed that the tongue is the predominant anatomic site for SCC (44.7%).

CONCLUSIONS

Findings from this review indicate that tongue lesions are relatively common in our environment with bimodal peak ages of occurrence, a predominance of neoplastic lesions and predilection for the dorsum and the anterior two-thirds of the tongue. Also all lesions presenting in the base of the tongue were malignant lesions with squamous cell carcinoma as the most common histological diagnosis.

REFERENCES

1. **du Toit DF.** The tongue: structure and function relevant to disease and oral health. *SADJ*. 2003; 58(9):375-376, 380-383.
2. **Bhattacharya PT,** Sinha R, Pal S. Prevalence and subjective knowledge of tongue lesions in an Indian population. *J Oral Biol Craniofac Res*. 2016; 6(2): 124-128.
3. **Mangold AR,** Torgerson RR. Diseases of the tongue. *Clin Dermatol*. 2016; 34(4):458-469.
4. Logan RM, Goss AN. Biopsy of the oral mucosa and use of histopathology services; *Aust Dent J*. 2010; 55(1 Suppl):9-13.
5. **Lau SK,** Bishop JA, Thompson LD. Spindle cell lipoma of the tongue: a clinicopathologic study of 8 cases and review of the literature. *Head Neck Pathol*. 2015; 9(2):253-259.
6. **Koutlas IG,** Scheithauer BW. Palisaded encapsulated ("solitary circumscribed") neuroma of the oral cavity: a review of 55 cases. *Head Neck Pathol*. 2010; 4(1):15-26.
7. **Diapera MJ,** Lozon CL, Thompson LD. Malacoplakia of the tongue: a case report and clinicopathologic review of 6 cases. *Am J Otolaryngol*. 2009; 30(2):101-105.
8. **Sarkaria JN,** Harari PM. Oral tongue cancer in young adults less than 40 years of age: rationale

- for aggressive therapy. *Head Neck*. 1994;16(2):107-11.
9. **Li R**, Koch WM, Fakhry C, Gourin CG. Distinct epidemiologic characteristics of oral tongue cancer patients. *Otolaryngol Head Neck Surg*. 2013; 148(5): 792-796.
 10. **Shamloo N**, Lotfi A, Motazadian HR, *et al*. Squamous Cell Carcinoma as the Most Common Lesion of the Tongue in Iranians: a 22-Year Retrospective Study. *Asian Pac J Cancer Prev*. 2016; 17(3):1415-1419.
 11. **Alaeddini M**, Barghammadi R, Eshghyar N, Etemad-Moghadam S. An analysis of biopsy-proven tongue lesions among 8,105 dental outpatients. *J Contemp Dent Pract*. 2014; 15(1):1-7.
 12. **Patil S**, Kaswan S, Rahman F, Doni B; Prevalence of tongue lesions in the Indian population. *J Clin Exp Dent*. 2013; 5(3):e128-132.
 13. **Bánóczy J**, Rigó O, Albrecht M. Prevalence study of tongue lesions in a Hungarian population. *Community Dent Oral Epidemiol*. 1993; 21:224-226.
 14. **Darwazah AM**, Almelaiah AA. Tongue lesions in a Jordanian population. Prevalence, symptoms, subject's knowledge and treatment provided. *Med Oral Patol Oral Cir Bucal*. 2011;16:e745-749.
 15. **Gambino A**, Carbone M, Arduino PG, *et al*. Clinical features and histological description of tongue lesions in a large Northern Italian population. *Med Oral Patol Oral Cir Bucal*. 2015; 20(5):e560-565.
 16. **Costa FW**, Osterne RL, Mota MR, *et al*. Tongue lesions. *J Craniofac Surg*. 2012; 23(6):e548-551.
 17. **Kantola S**, Jokinen K, Hyryn Kangas K, *et al*. Detection of tongue cancer in primary care. *Br J Gen Pract*, 2001; 51: 106-111.
 18. **Xu Z**, Taylor JA. Genome-wide age-related DNA methylation changes in blood and other tissues relate to histone modification, expression, and cancer. *Carcinogenesis*. 2014; 35(2):356-364.
 19. **Gorsky M**, Epstein JB, Oakley C, *et al*. Carcinoma of the tongue: a case series analysis of clinical presentation, risk factors, staging, and outcome. *Oral Surg Oral Med Oral Pathol Oral Radiol Endod*. 2004; 98(5):546-552.
 20. **Najeeb T**. Clinicopathological presentation of tongue cancers and early cancer treatment. *J Coll Physicians Surg Pak*. 2006; 16(3):179-182.
 21. **Adeyemi BF**, Olusanya AA, Lawoyin JO. Oral squamous cell carcinoma, socioeconomic status and history of exposure to alcohol and tobacco. *J Natl Med Assoc*. 2011; 103(6):498-502.
 22. **Lasisi TJ**, Adeyemi BF, Oluwasola AO, *et al*. Oro-facial squamous cell carcinoma - a twenty-year retrospective clinicopathological study. *Afr J Med Med Sci*. 2012; 41(3):265-270.
 23. **Yeh CY**, Lin CL, Chang MC, *et al*. Differences in oral habit and lymphocyte subpopulation affect malignant transformation of patients with oral precancer. *J Formos Med Assoc*. 2016; 115(4):263-268.
 24. **Kumar M**, Nanavati R, Modi TG, Dobariya C. Oral cancer: Etiology and risk factors: A review. *J Cancer Res Ther*. 2016; 12(2):458-463.
 25. **Effiom OA**, Adeyemo WL, Omitola OG, *et al*. Oral squamous cell carcinoma: a clinicopathologic review of 233 cases in Lagos, Nigeria. *J Oral Maxillofac Surg*. 2008; 66(8):1595-1599.
 26. **Chi AC**, Day TA, Neville BW. Oral cavity and oropharyngeal squamous cell carcinoma—an update. *CA Cancer J Clin*. 2015; 65(5):401-421
 27. **Bello IO**, Soini Y, Salo T. Prognostic evaluation of oral tongue cancer: means, markers and perspectives (I). *Oral Oncol*. 2010;46(9):630-635.
 28. **Oji C**, Chukwunke FN. Oral cancer in Enugu, Nigeria, 1998-2003. *Br J Oral Maxillofac Surg*. 2007; 45(4):298-301.
 29. **Hernandez-Guerrero JC**, Jacinto-Aleman LF, Jimenez-Farfan MD, *et al*. Prevalence trends of oral squamous cell carcinoma. Mexico City's General Hospital experience. *Med Oral Patol Oral Cir Bucal*; 2013; 18: 306-311.