



ELSEVIER

Contents lists available at [ScienceDirect](http://www.sciencedirect.com)

JSES Open Access

journal homepage: www.elsevier.com/locate/jses

Irreducible Monteggia fracture: interposed radial nerve and capsule

Cary Tanner, MD ^{a,b,*}, Toby Johnson, MD ^{a,b}, Kouros Kolahi, MD ^b, Lisa Husak, MPH ^b, Nathan Hoekzema, MD ^b^a Sierra Pacific Orthopaedic Center, Fresno, CA, USA^b Department of Orthopaedic Surgery, University of California, San Francisco, Fresno, CA, USA

ARTICLE INFO

Keywords:

Monteggia fracture
 Unreducible radial head dislocation
 Unreducible proximal radioulnar joint dislocation
 Partial PIN palsy
 Radial nerve entrapment
 Ulnar osteotomy

Persistent radial head subluxation following open reduction and internal fixation of the ulna in a Monteggia fracture dislocation is typically ascribed to inadequate reduction of the ulna. In this case, a revision of the ulna fixation failed to achieve radiocapitellar reduction, and further exploration revealed the interposition of the anterior elbow capsule and the radial nerve in the radiocapitellar joint, as well as soft tissue interposed in the proximal radioulnar joint.

Case report

Case history

A 35-year-old right-hand-dominant cyclist collided with another cyclist, sending him over the handlebars onto the outstretched arm, so sustaining a segmental Monteggia fracture-dislocation (Figs. 1 and 2).

An orthopedic surgeon performed an open reduction and internal fixation of the ulna using two plates (Figs. 3 and 4). The patient was referred because of the persistent subluxation of the radial head. We evaluated the patient within 48 hours of the original procedure. He stated that he had no history of a prior injury to the elbow on either side and before the injury had enjoyed full range of motion.

Physical examination revealed that he was stiff and moderately swollen from the elbows to the fingers. No sensory loss was noted.

On careful bilateral comparison of the ulnar anatomy under fluoroscopy, it appeared to us that the injured side was internally fixed in a position of slight apex anterior angulation at the proximal

internal fixation site. We assumed that restoring the ulnar anatomy would result in a reduction of the radial head.

The patient was taken back to the operating room 1 week after the initial procedure. On removal of the hardware, it was noted under intraoperative fluoroscopy that the radial head was resistant to reduction. The ulna was then repaired, matching the contralateral anatomy (slight apex posterior bow), but the radial head remained subluxed anteriorly. Passively at this point, the patient's elbow range of motion was full in both flexion and extension and in pronosupination. As it was unclear what was preventing the reduction of the radial head, a radiocapitellar arthroscopy was made through a 3-cm longitudinal incision in the fascia centered over the radiocapitellar joint in line with the midaxis of the radius and supracondylar ridge of the distal humerus. Interposed tissue was present between the radial head and the capitellum. At this point, it was simply unclear if this represented an old nursemaid's elbow with annular ligament interposed or some other distant injury because the range of motion appeared to be unrestricted. It was elected to conclude the procedure at that point and to see how the patient rehabilitated.

The video demonstrates the patient's intraoperative range of motion, the subluxed radial head, and the resistance of the radial head to reduction (Video S1).

Postoperatively, it was noted during the next 4 weeks that the patient remained quite stiff, and it was also noted after his wrist and finger range of motion improved that a partial radial nerve palsy was present. Nerve conduction velocities were normal for the radial sensory component, but positive sharp waves were present in the extensor carpi radialis, the extensor digitorum communis, and the extensor index proprius; 1 or 2 voluntary motor unit action potentials were present, indicating partial conduction.

Because of the proximity of the radial nerve to the anterolateral capsule of the elbow and because of the interposed tissue found

* Corresponding author: Cary Tanner, MD, Sierra Pacific Orthopaedic Center, 1630 E Herndon Ave, Fresno, CA 93720, USA.

E-mail address: ctanner@spoc-ortho.com (C. Tanner).

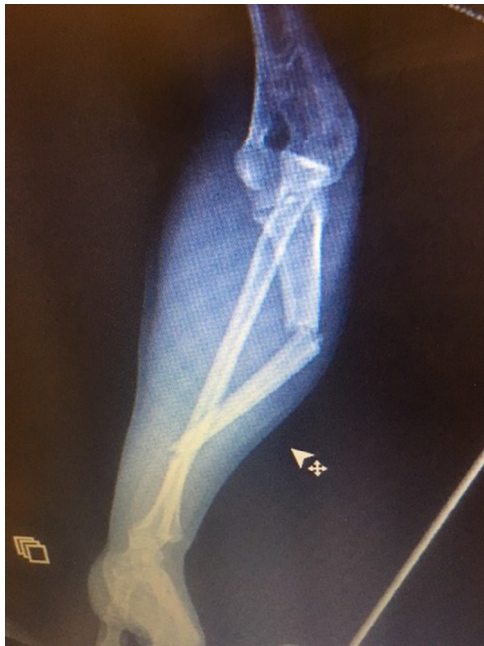

Figure 1 Segmental Monteggia fracture-dislocation.

at the previous procedure, the findings were discussed with the patient. He elected to proceed with an exploration.

On more extensive exploration, the radial nerve was isolated between the extensor digitorum communis and the extensor carpi radialis brevis proximal to the radiocapitellar joint and in the supinator muscle distal to the radiocapitellar joint. Once localized in normal tissue, the nerve was followed to the site of entrapment in the radiocapitellar joint. The anterior elbow capsule and the radial nerve were seen to be infolded into the joint (Fig. 5). Once the radial nerve and capsule were dissected free, it became evident that interposed tissue in the proximal radioulnar joint was blocking

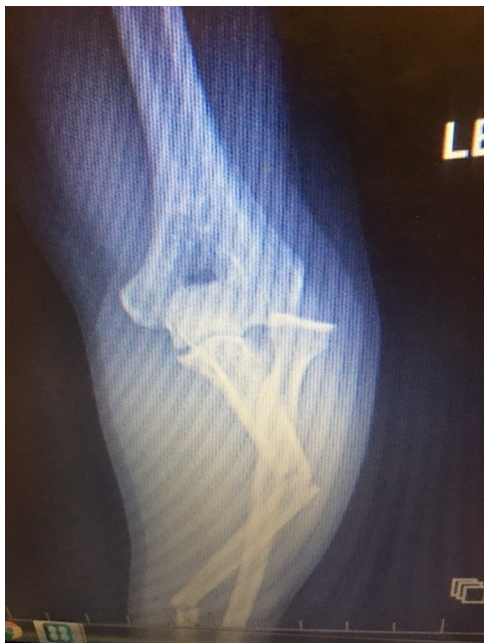

Figure 2 Anteroposterior radiograph of elbow, segmental Monteggia fracture-dislocation.

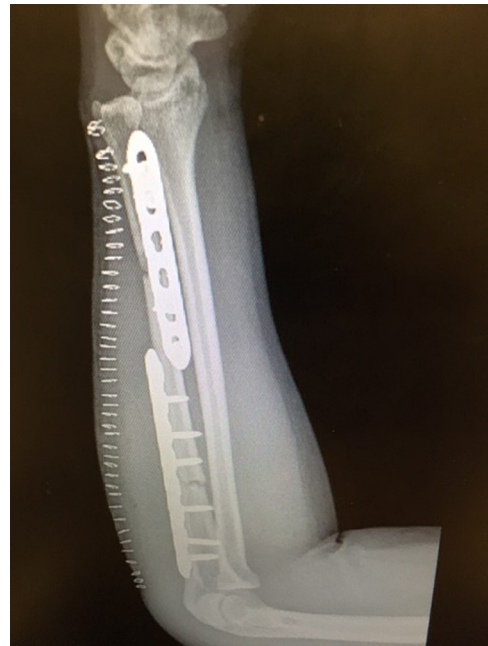

Figure 3 Initial open reduction and internal fixation present on referral.

reduction (Fig. 6). Once this tissue was excised, the radial head snapped back into place, with no alteration in the ulnar fixation (Figs. 7 and 8).

A K-wire was placed across the radiocapitellar joint, and the patient was placed in a long arm splint. The K-wire was removed at 4 weeks and range of motion begun.

Six months after the procedure, the patient was pain free; the ulna had fully healed, the radiocapitellar joint remained reduced, and range of motion was improved (28° - 118° , with pronosupination of 42° and 30°) (Figs. 7 and 8). The patient believed that he had fully recovered radial nerve function, but resisted extension revealed slight

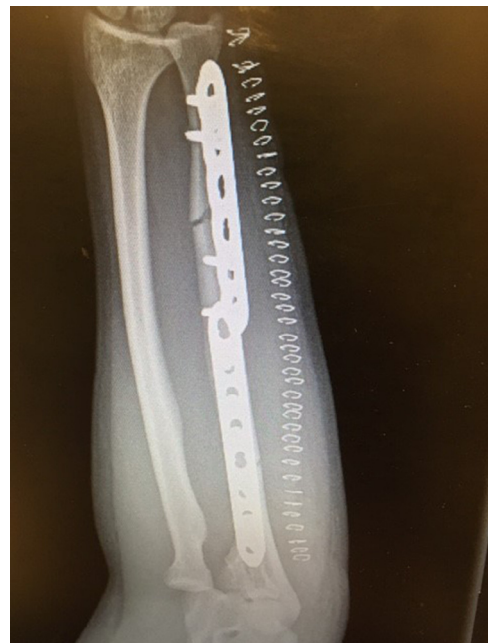

Figure 4 Initial open reduction and internal fixation present on referral, with radiocapitellar joint subluxated.

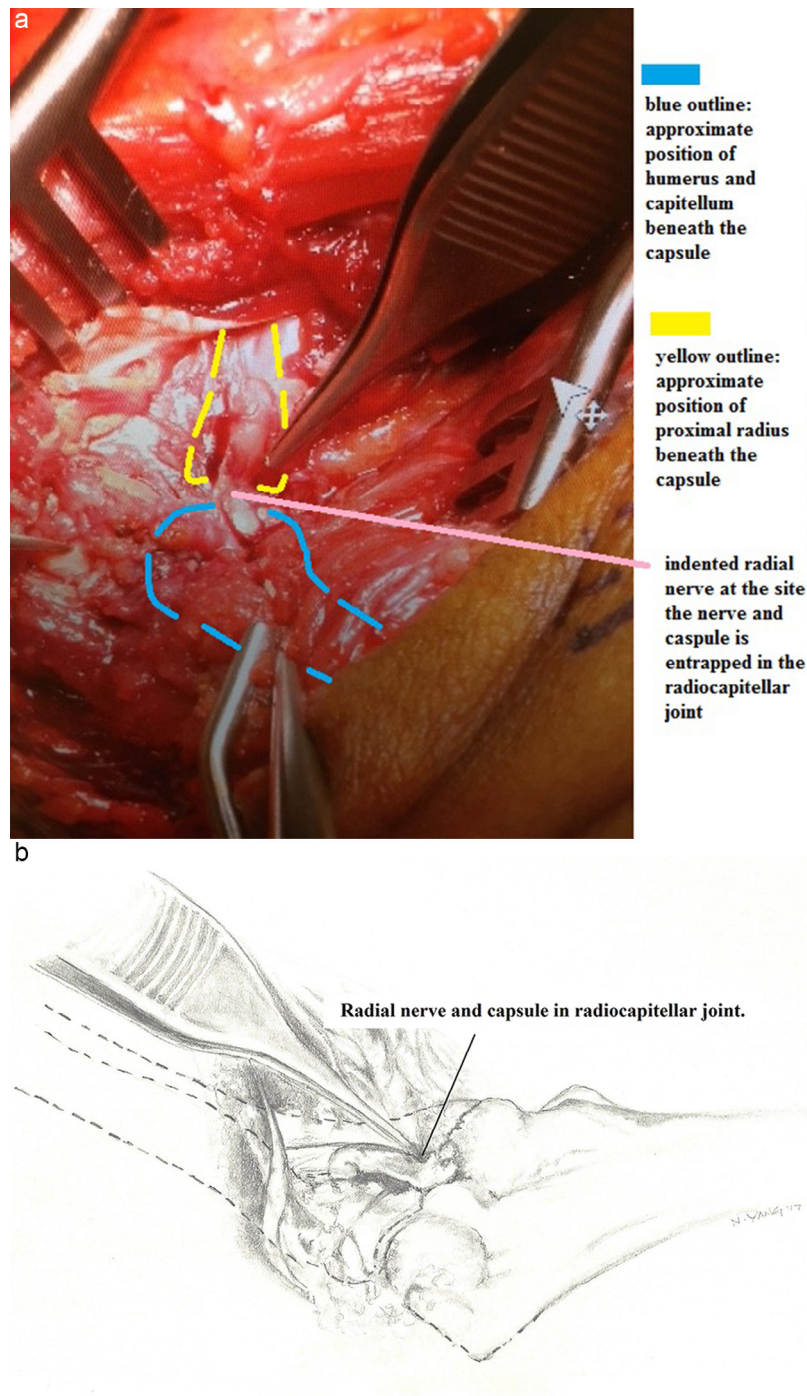


Figure 5 Photograph (a) and illustration (b) of the radial nerve and the elbow capsule infolded into the radiocapitellar joint. The pickup points to the indented nerve at the site of the infolded capsule into the radiocapitellar interval.

weakness in the long and ring fingers, although full range of motion was present.

Discussion

Irreducible radial head dislocation seems to occur in the context of a spectrum of injuries in children and adults. The pathogenesis of a pulled or nursemaid's elbow remains uncertain; it may be a partial tear in the annular ligament, with the ligament partially slipping over the radial head as the radius travels distally with traction,¹⁰ or the thicker proximal portion of the annular ligament separates from the

distal thinner portion through a naturally occurring fissure, allowing the proximal portion to slip into the radial capitellar joint.¹¹ Whereas this injury is usually easily reduced, there are reports of the annular ligament being entrapped in the radiocapitellar joint, requiring open reduction in children^{5,10,15} and adults.^{6,7,13}

The biceps tendon has also been found to be a factor preventing the reduction of a dislocated radial head. In these injuries, the biceps tendon becomes displaced lateral to the neck of the radius. The anterior subluxed radial head appears to be medially displaced on the anteroposterior radiograph under the influence of the biceps tendon wrapped around the lateral aspect of the radial neck.

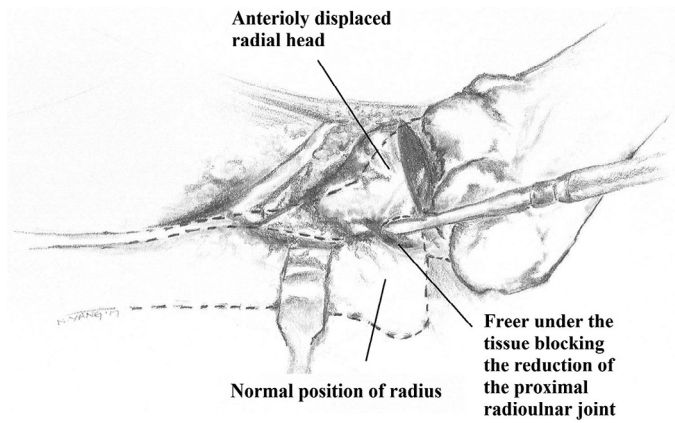


Figure 6 Illustration of the capsule and radial nerve released from the joint. The Freer points to the soft tissue interposed in the proximal radioulnar joint.

This has been reported in children with and without an associated Monteggia fracture-dislocation^{1,2,12,17,18} and in adults without an ulna fracture.¹⁶ In the latter case, the authors performed a cadaver re-creation of the injury. This revealed that the injury could be reproduced only with an accompanying ulnar collateral ligament tear at the elbow.

The radial head has also been found to be buttonholed through the brachialis tendon, preventing radial head reduction in children.^{3,4}

Capsular interposition blocking reduction has also been reported.^{8,14}

We are aware of 1 report of the posterior interosseus nerve (PIN) being entrapped in the radiocapitellar joint in a child, preventing

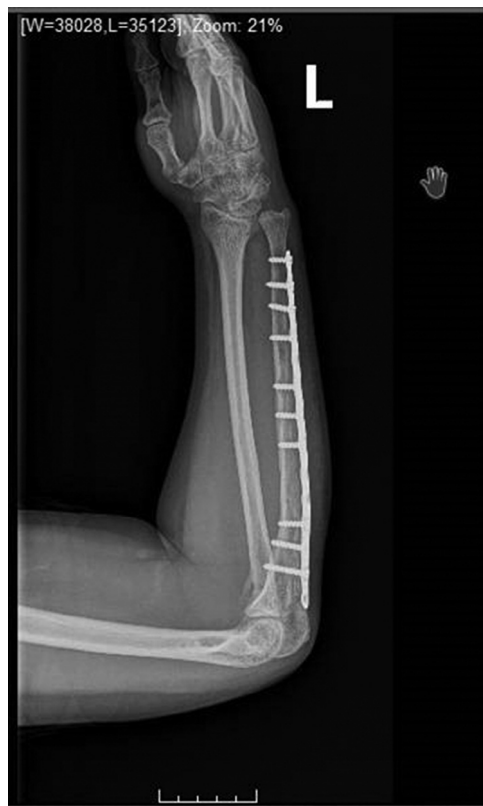

Figure 7 Lateral radiograph demonstrating reduction of the radiocapitellar joint and union of the ulna segmental fracture at 6 months postoperatively.

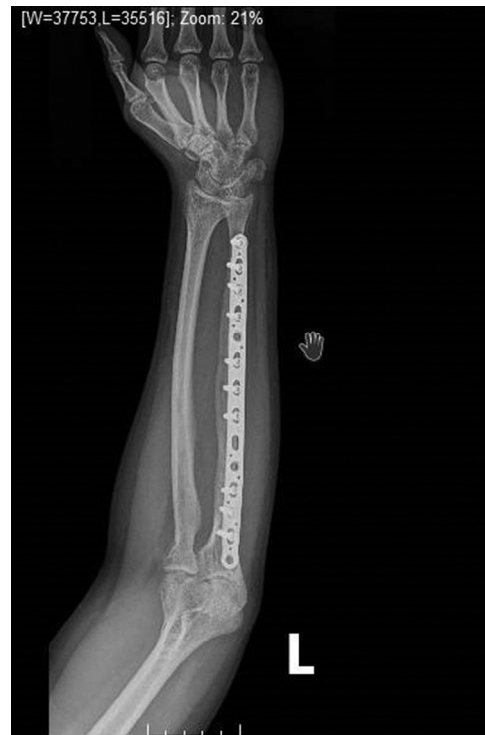

Figure 8 Anteroposterior radiograph demonstrating reduction of the radiocapitellar joint and union of the ulna segmental fracture at 6 months postoperatively.

reduction of the radial head.⁹ In that case, the patient had a pre-operative PIN palsy. The PIN was lacerated on exposure of the radiocapitellar joint and was repaired.

Another reasonable question would be whether there is a radiographic pattern to the radiocapitellar dislocation that would be predictive of interposed tissue blocking reduction. In this case, the dislocation of the radius was widely displaced (Figs. 1 and 2). On review of the radiographs shown in the cases reported and referenced here that also had interposed tissue blocking reduction, 70% were associated with 100% displacement of the radiocapitellar joint, but not a great deal more in any of them. Thus, it is not clear that radiographs will help alert treating surgeons of the possibility of interposed soft tissue blocking reduction of the radiocapitellar or proximal radioulnar joint.

Conclusion

When confronted with persistent subluxation of the radial head after open reduction and internal fixation of a Monteggia fracture-dislocation, consider first the adequacy of the ulnar anatomy, but second, consider the possibility of soft tissue interposition. If radial nerve dysfunction is present, wide exposure of the radial nerve is recommended because of the marked distortion of the anatomy in the region of the radiocapitellar joint.

Disclaimer

The authors, their immediate families, and any research foundations with which they are affiliated have not received any financial payments or other benefits from any commercial entity related to the subject of this article.

Appendix: Supplementary material

Supplementary data to this article can be found online at [doi:10.1016/j.jses.2017.06.003](https://doi.org/10.1016/j.jses.2017.06.003).

References

1. Armstrong RD, McLaren AC. Biceps tendon blocks reduction of isolated radial head dislocation. *Orthop Rev* 1987;16:104-8.
2. Aversano F, Kepler CK, Blanco JS, Green DW. Rare cause of block to reduction after radial head dislocation in children. *J Orthop Trauma* 2011;25:e38-41. <http://dx.doi.org/10.1097/BOT.0b013e3181dc245d>
3. Camp CL, O'Driscoll SW. Transbrachialis buttonholing of the radial head as a cause for irreducible radiocapitellar dislocation: a case report. *J Pediatr Orthop* 2015;35:e67-71. <http://dx.doi.org/10.1097/BPO.0000000000000516>
4. Cates RA, Steinmann SP, Adams JE. Irreducible anteromedial radial head dislocation caused by the brachialis tendon: a case report. *J Shoulder Elbow Surg* 2016;25:e232-5. <http://dx.doi.org/10.1016/j.jse.2016.04.017>
5. Corella F, Horna L, Villa A, Gonzalez JL, Soleto J. Irreducible "pulled elbow": report of two cases and review of the literature. *J Pediatr Orthop B* 2010;19:304-6. <http://dx.doi.org/10.1097/BPB.0b013e3283339a1b>
6. Kajiwara R, Sunagawa T, Ishida O, Ochi M. Irreducible pulled elbow in an adult: a case report. *J Shoulder Elbow Surg* 2007;16:e1-4. <http://dx.doi.org/10.1016/j.jse.2006.03.007>
7. Kong KC. Irreducible isolated dislocation of the radial head in a skeletally mature teenager. A case report. *Arch Orthop Trauma Surg* 1993;112:304-5.
8. Neviasser RJ, LeFevre GW. Irreducible isolated dislocation of the radial head. A case report. *Clin Orthop Relat Res* 1971;80:72-4.
9. Rodgers WB, Waters PM, Hall JE. Chronic Monteggia lesions in children. Complications and results of reconstruction. *J Bone Joint Surg Am* 1996;78:1322-9.
10. Salter RB, Zaltz C. Anatomic investigations of the mechanism of injury and pathologic anatomy of "pulled elbow" in young children. *Clin Orthop Relat Res* 1971;77:134-43.
11. Sanal HT, Chen L, Haghighi P, Trudell DJ, Resnick DL. Annular ligament of the elbow: MR arthrography appearance with anatomic and histologic correlation. *AJR Am J Roentgenol* 2009;193:W122-6. <http://dx.doi.org/10.2214/AJR.08.1887>
12. Sasaki K, Miura H, Iwamoto Y. Unusual anterior radial head dislocation associated with transposed biceps tendon: a case report. *J Shoulder Elbow Surg* 2006;15:e15-9. <http://dx.doi.org/10.1016/j.jse.2005.08.021>
13. Takami H, Takahashi S, Ando M. Irreducible isolated dislocation of the radial head. *Clin Orthop Relat Res* 1997;345:168-70.
14. Takase K, Mizuochi J. Irreducible dislocation of the radial head with undisplaced olecranon fracture in a child: a case report. *J Pediatr Orthop B* 2011;20:345-8. <http://dx.doi.org/10.1097/BPB.0b013e32834534cb>
15. Triantafyllou SJ, Wilson SC, Rychak JS. Irreducible "pulled elbow" in a child. A case report. *Clin Orthop Relat Res* 1992;284:153-5.
16. Upasani V V, Hentzen ER, Meunier MJ, Abrams RA. Anteromedial radial head fracture-dislocation associated with a transposed biceps tendon: a case report. *J Shoulder Elbow Surg* 2011;20:e14-8. <http://dx.doi.org/10.1016/j.jse.2010.11.025>
17. Veenstra KM, van der Eyken JW. Irreducible antero-medial dislocation of the radius. A case of biceps tendon interposition. *Acta Orthop Scand* 1993;64:224-5.
18. Yoshihara Y, Shiraishi K, Imamura K. Irreducible anteromedial dislocation of the radial head caused by biceps tendon clinging around the radial neck. *J Trauma* 2002;53:984-6.