



Case report

Treatment of grade III knee osteoarthritis with bone marrow stimulation and intraarticular injection of triamcinolone and hyaluronic acid combination; three case report and literature review

Ariyanto Arief^{a,b,*}, Budu^c, Muhammad Andry Usman^{c,d}, Muhammad Sakti^{c,d},
Andri Maruli Tua Lubis^e, Agussalim Bukhari^c

^a Medical and Health Science Faculty of State Islamic Alauddin University Makassar, Indonesia

^b Department of Orthopedic and Traumatology, Hasri Ainun Habibie Hospital Parepare, Indonesia

^c Medical Faculty of Hasanuddin University Makassar, Indonesia

^d Department of Orthopedic and Traumatology, Wahidin Sudirohusodo Hospital, Makassar, Indonesia

^e Department of Orthopedic and Traumatology, Faculty of Medicine, Universitas Indonesia/Cipto Mangunkusumo Hospital Jakarta, Indonesia

ARTICLE INFO

Keywords:

Osteoarthritis
Bone marrow stimulation
Hyaluronic acid
Womac score
Case report
Interleukin 15

ABSTRACT

Introduction and importance: Osteoarthritis is a severe joint disease that affects more than 60% of the elderly and more common an idiopathic disease or unknown cause although there is also a secondary cause such as trauma, infection, neurological or metabolic disorders. The usual complaints that perceived by osteoarthritis patients is pain in the affected joint. Many patients and providers think of arthroplasty as the only surgical option for the treatment of osteoarthritis of the knee. However, there are several other surgical options for osteoarthritis which can be therapeutic alternatives. The role of bone marrow stimulation and intraarticular injection with triamcinolone and Hyaluronic acid combination on grade III knee osteoarthritis patient has not been reported.

Case presentation: Three patients who presented to orthopedic department with complaints of bilateral knee pain were identified with grade III osteoarthritis (Kellgren and Lawrence) receiving some kind of analgetic treatment for more than 1 year which provided pain relief for some time but not permanent. They underwent arthroscopic procedure (bone marrow stimulation) and then injected with triamcinolone and hyaluronic acid combination. Pre and post operation outcome scores (WOMAC score, Interleukin 15 and MRI) were assessed. At six-month follow-up, all patients reported improvement in pain and stiffness. WOMAC score and Interleukin 15 serum level decreases, MRI with Amadeus score showed improvement of cartilage defect.

Clinical discussion: This case report showed that our three patients were successfully treated with bone marrow stimulation and intraarticular injection with triamcinolone and hyaluronic acid combination. All three patients have improved in their functional outcome, IL 15 and cartilage defect.

Conclusion: Bone marrow stimulation and intraarticular injection with triamcinolone and hyaluronic acid combination can be a valuable treatment option for moderate active patients with grade III knee osteoarthritis.

1. Introduction

Osteoarthritis (OA) is a severe joint disease that affects more than 60% of the elderly. Primary OA pathogenesis is an intrinsic cartilage disorder in which biomechanical and metabolic changes contribute to its breakdown. Although OA is a phase of multifactorial disease, early cartilage damage, and ultimate loss of articular cartilage are considered essential for OA progression. Other essential pathophysiology of OA is bone or joint deterioration, in addition to cartilage degeneration.

Although multiple accounts of joint deformity such as osteophytes, subchondral osteosclerosis and bone cysts have been found to be important pathological hallmarks for OA [1].

Osteoarthritis is a degenerative joint disease in which the affected joint is usually the large joint and unilateral. Prevalence of osteoarthritis in Indonesia, 15.5% in men and 12.7% in women, where the incidence is increasing with age. Osteoarthritis is more common an

idiopathic disease or unknown cause although there is also a secondary cause such as

* Corresponding author at: Medical and Health Science Faculty of State Islamic Alauddin University Makassar, Indonesia.

E-mail address: ariyanto_ar@yahoo.com (A. Arief).

<https://doi.org/10.1016/j.ijscr.2022.107177>

Received 1 April 2022; Received in revised form 7 May 2022; Accepted 7 May 2022

Available online 10 May 2022

2210-2612/© 2022 The Authors. Published by Elsevier Ltd on behalf of IJS Publishing Group Ltd. This is an open access article under the CC BY-NC-ND license (<http://creativecommons.org/licenses/by-nc-nd/4.0/>).

trauma, infection, neurological or metabolic disorders. The usual complaints that perceived by osteoarthritis patients is pain in the affected joint, especially after the load on the joint.

Therapy in osteoarthritis is usually symptomatic, which include the control of risk factors,

physiotherapy and pharmacological [2].

Knee osteoarthritis is a degenerative disease often encountered in clinical practice, and the majority of the patients with this disease are middle-aged. If it is not treated quickly and effectively, it can cause joint deformity and disability and lead to a series of complications. Severe cases can even limit patient's activities, which will have a greater impact on patients' quality of life. According to published studies, the occurrence of osteoarthritis in knee joints is usually caused by long-term labor, excessive weight, trauma, and cold. With the continuous development of clinical research on knee osteoarthritis, the treatment plan for this condition has been effectively developed and applied, which has effectively promoted the further development of clinical work [3].

Many patients and providers think of arthroplasty as the only surgical option for the treatment of osteoarthritis of the knee. However, there are several other surgical options for osteoarthritis which can be therapeutic alternatives. Contemporary options include (i) arthroscopic debridement or lavage, (ii) marrow-stimulation techniques, such as microfracture, (iii) periosteal or perichondral grafting, (iv) autologous chondrocyte implantation, (v) osteochondral autograft transplantation, and (vi) osteochondral allograft transplantation. Each technique offers its own advantages and disadvantages, but there are very few controlled comparative clinical or basic science studies. In the setting of osteoarthritis with full-thickness chondral lesions, there is still debate concerning optimal treatment options [4].

As life expectancy increases and the age at which patients are diagnosed with knee OA decreases, exploring alternative therapies for treating knee OA becomes necessary. The aim of this case study is to evaluate the effect of bone marrow stimulation and intraarticular injection of hyaluronic acid-triamcinolone combination on functional outcome (WOMAC score), cartilage repair (MRI-AMADEUS score), and interleukin 15 serum level. This case report has been reported in line with the SCARE 2020 Criteria [5].

2. Case report

In 2021, three consecutive patients who self-presentation at the orthopedic department were identified with grade III osteoarthritis, they were receiving some kind of analgetic treatment for more than 1 year which provided pain relief for some time but not permanent.

The first patient was a 55 years old male, who presented to orthopedic department with complaints of bilateral knee pain since 3 years ago. He reported that he had knee pain and stiffness when wake up in the morning. Pain increased on climbing up and down the stairs. Patient expressed the main concern of bilateral pain in the knee. The pain was intermittent throbbing and dull present around both the knees. Pain in left knee was more than pain in right knee. No history of smoking, alcohol and recreational drug use. No family history with the same complaint. Tests and assessments were performed during the patient's examination to determine the knee joint range of motion. Total score of Western Ontario and Mc Master University (WOMAC) score is 34 and from blood test show Interleukin 15 is 100,5 pg/ml (Table 1). Plain X ray Showed Kellgren and Lawrence (KL) grading 3 in left knee joint and

grading 3 in right knee joint (Fig. 1.A). MRI showed Area Measurement and Depth Underlying Structure (AMADEUS) score grade 3 (Fig. 1B).

The second patient was 62 years old female who presented to orthopedic department with wheelchair. She complaints pain and stiffness on her both knee from 5 years till now. Pain and stiffness especially in the morning. She has been taking pain medication for more than 2 year without improvement in her pain. No history of smoking, alcohol and recreational drug use. No family history with the same complaint. Tests and assessments were also performed during the patient's examination to determine the knee joint range of motion. Total score of Western Ontario and Mc Master University (WOMAC) score is 29 and from blood test show Interleukin 15 is 88,3 pg/ml (Table 1). Plain X ray Showed Kellgren and Lawrence (KL) grading 3 in left knee joint and grading 3 in right knee joint (Fig. 2A). MRI showed AMADEUS score grade 3 (Fig. 2B).

Third Patient was a 58 years old female, who also presented to orthopedic department with wheelchair with complaints of bilateral knee pain and stiffness since 2 years ago. Stiffness usually in the morning. She also been taking pain medication for more than 1 year without no pain relief. No history of smoking, alcohol and recreational drug use. No family history with the same complaint. Total score of Western Ontario and Mc Master University (WOMAC) score is 35 and from blood test show Interleukin 15: 67,5 pg/ml (Table 1). Plain X ray Showed Kellgren and Lawrence (KL) grading 3 in left knee joint and grading 3 in right knee joint (Fig. 3A). MRI showed AMADEUS score grade 3 (Fig. 3B).

All surgeries were performed by first author (AA) as a 10 years orthopedic surgeon and 4 years consultant of arthroscopy and sport injury in the general hospital. All patients gave consent for this treatment. All three patients underwent a bone marrow stimulation procedure, conducted under regional anesthesia with patient in supine position, the knee in 90 degrees. A thigh tourniquet was used with 250 mmHg pressure. Two incision were made at anterolateral and anteromedial aspect of the knee for arthroscopic portal. After assessing the full thickness articular cartilage lesion, the exposed bone is debrided of all remaining unstable cartilage. To debride the cartilage, the author used a shaver. All loose or marginally attached cartilage from the surrounding rim of articular cartilage is also debrided to form a stable perpendicular edge of healthy vital cartilage around the defect. This prepared lesion provides a pool that helps to hold the bone marrow clot as it forms. To avoid excessive damage to the subchondral bone, an arthroscopic awl then is used to make multiple perforations, or microfractures, into the exposed subchondral bone plate. The holes should be placed 3–4 mm apart without breaking the subchondral bone plate between them. Fat emerging from the marrow cavity indicates the appropriate depth (2–4 mm). The arthroscope portal was closed with ethylene suture and dressings were applied. After the microfracture procedure, then all patients were injected intraarticularly with combination of hyaluronic acid HA 2,5 ml (10 mg/ml) and triamcinolone 5 ml (10 mg/ml) (Fig. 7).

Post-operatively, patients were allowed to weight bear as tolerated with the use of crutches if necessary.

Pre- and postoperative outcome were assessed, including WOMAC score, Interleukin 15 serum level, and MRI with AMADEUS score. All three patient show uneventful recovery after the operation and show improvement of outcome at 6 months follow-up. There was improvement in WOMAC score, Interleukin 15 serum level and AMADEUS score (Table 2, Fig. 4–6). Postoperative WOMAC score showed decreased of WOMAC score more than 20%, postoperative Interleukin 15 serum level was also decreased at all patient. Although AMADEUS score in 2 patients showed the same grade with preoperative but total scores were increased (Table 2). All patient reported improved in knee pain and stiffness.

3. Discussion

All three arthroscopy procedures were performed without any intra-operative complication. No complications were documented within six

Table 1

Patient characteristic.

	Patient 1	Patient 2	Patient 3
Age	55	62	56
Gender (M/F)	M	F	F
Womac score	34	29	35
Interleukin 15	100,5 pg/ml	88,3 pg/ml	67,5 pg/ml

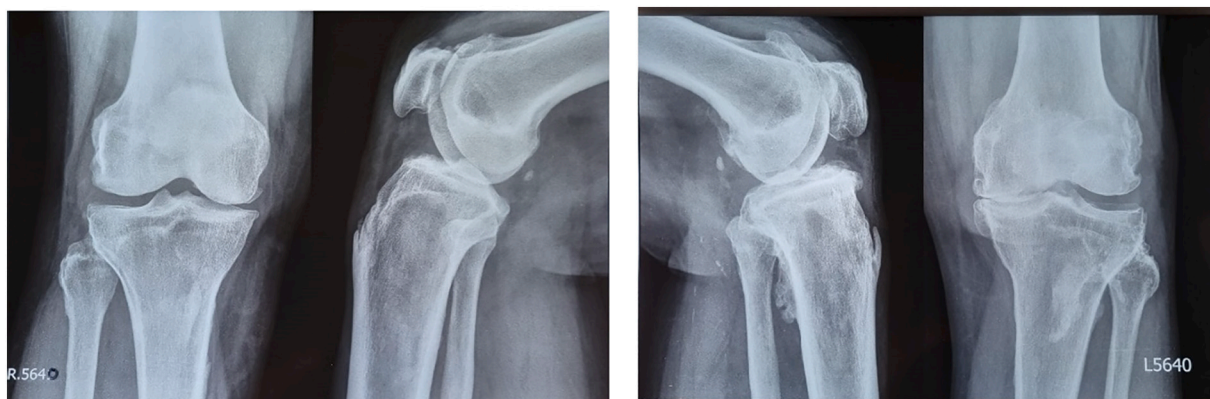


Fig. 1. Plain X ray of patient 1 knee showed grade III Osteoarthritis on both knee (Kellgen and Lawrence).

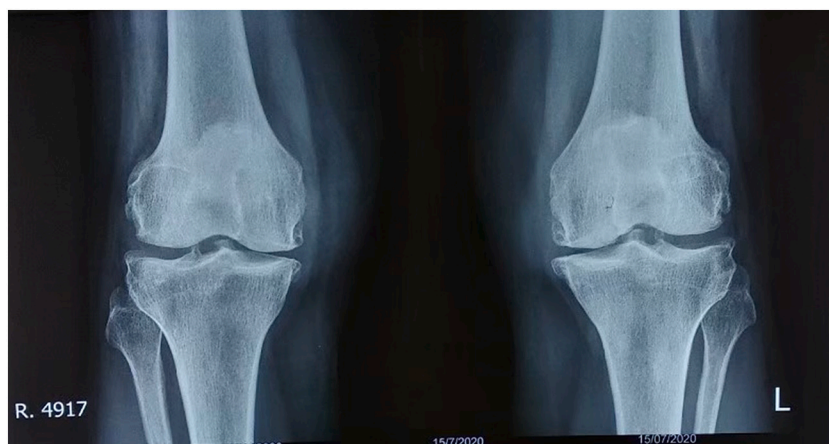

Fig. 2. Plain X ray of patient 2 knee showed grade III Osteoarthritis on both knee (Kellgen and Lawrence).

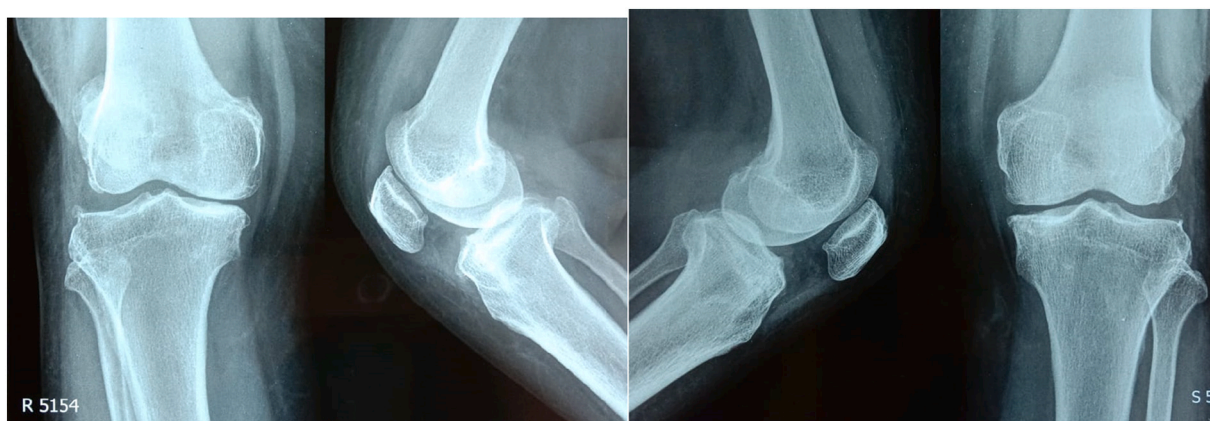


Fig. 3. Plain X ray of patient 3 knee showed grade III Osteoarthritis on both knee (Kellgen and Lawrence).

months follow up include infection, bleeding, nerve damage, deep venous thrombosis, pulmonary embolus, allergic reaction and Hyaluronic acid-triamcinolone delivery site pain.

All three cases presented demonstrate that bone marrow stimulation and intraarticular injection of hyaluronic acid and triamcinolone combination can be a feasible treatment option for grade III knee osteoarthritis patients. The microfracture technique often considered as the golden standard therapy for the treatment of cartilage defect. The first result and the technique were published in 1994. Microfracture is a technique in which the subchondral bone is penetrated to stimulate

formation of a new articular surface. This began with the idea that augmentation of healing could be enhanced by recruiting marrow elements. Penetration of the subchondral bone disrupts blood vessels and promotes the formation of a fibrin clot. Undifferentiated mesenchymal cells migrate into the clot, proliferate and form a fibrocartilaginous surface. Pridie in the 1950s penetrated the subchondral bone with a drill while Johnson performed superficial abrasion of the chondral surface to promote tissue repair. The concept of microfracture has been refined and popularized by Steadman and colleagues [4,6,7].

There have been numerous clinical studies that support the use of

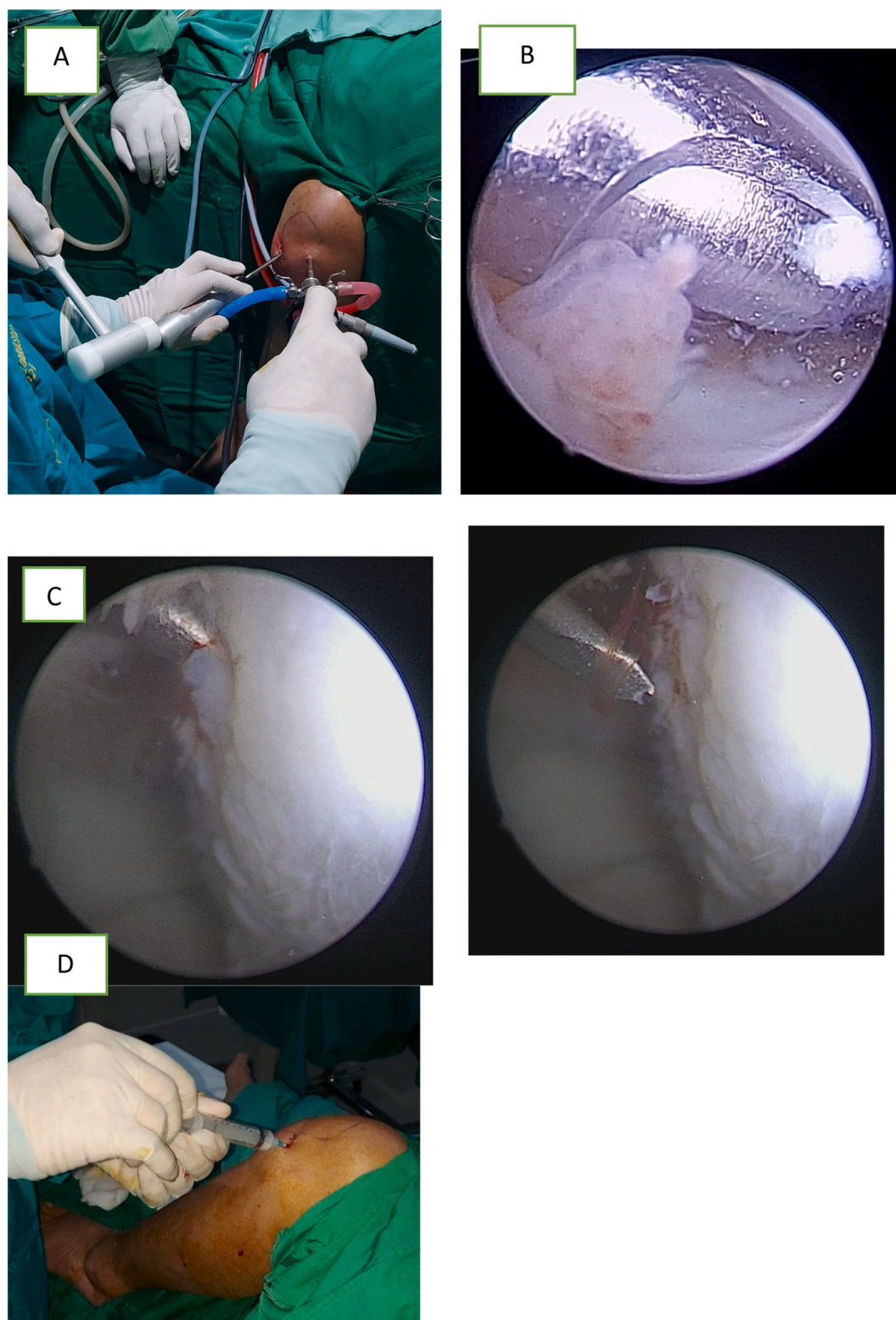


Fig. 7. A. Arthroscopy procedure; B. Debridement perarthrosy with a shaver; C. Microfracture drilling using an awl; D. Intraarticular Injection.

marrow-stimulation techniques. In 1994, Rodrigo and colleagues reported on “second-look” arthroscopy in 77 patients who had been treated with microfracture. The appearance of the defects was graded on a scale of 1 to 5, where 1 is normal and 5 indicates exposed subchondral bone. Among the 46 patients who were able to comply with the post-operative CPM regime, the mean improvement in defect was 2.6, whereas improvement was less dramatic at 1.6 for patients unable to

comply with the postoperative therapy [4].

All our three patients showed improvement of WOMAC score especially in pain score in 6 months follow up. A case series by Xinning Li et al., thirty consecutive patients who underwent arthroscopic debridement and concomitant delivery of 6 ml/90 mg Hyaluronic Acid. These patients were evaluated preoperatively, at 6 weeks, 3 and 6 months post-operatively. They found that WOMAC pain score improved

Table 2

Pre- and post-operative outcome score.

Patient	Womac score pre-operative	Womac score (6 months post-operative)	IL15 pre-operative (pg/ml)	IL15 (6 months post-operative) (pg/ml)	MRI AMADEUS score pre-operative	MRI AMADEUS score (6 months post-operative)
1	34	5	100,5	57,3	40 (grade 3)	50 (grade 3)
2	29	4	88,3	32,8	45 (grade 3)	65 (grade 2)
3	35	0	67,5	50,5	65 (grade 2)	65 (grade 2)

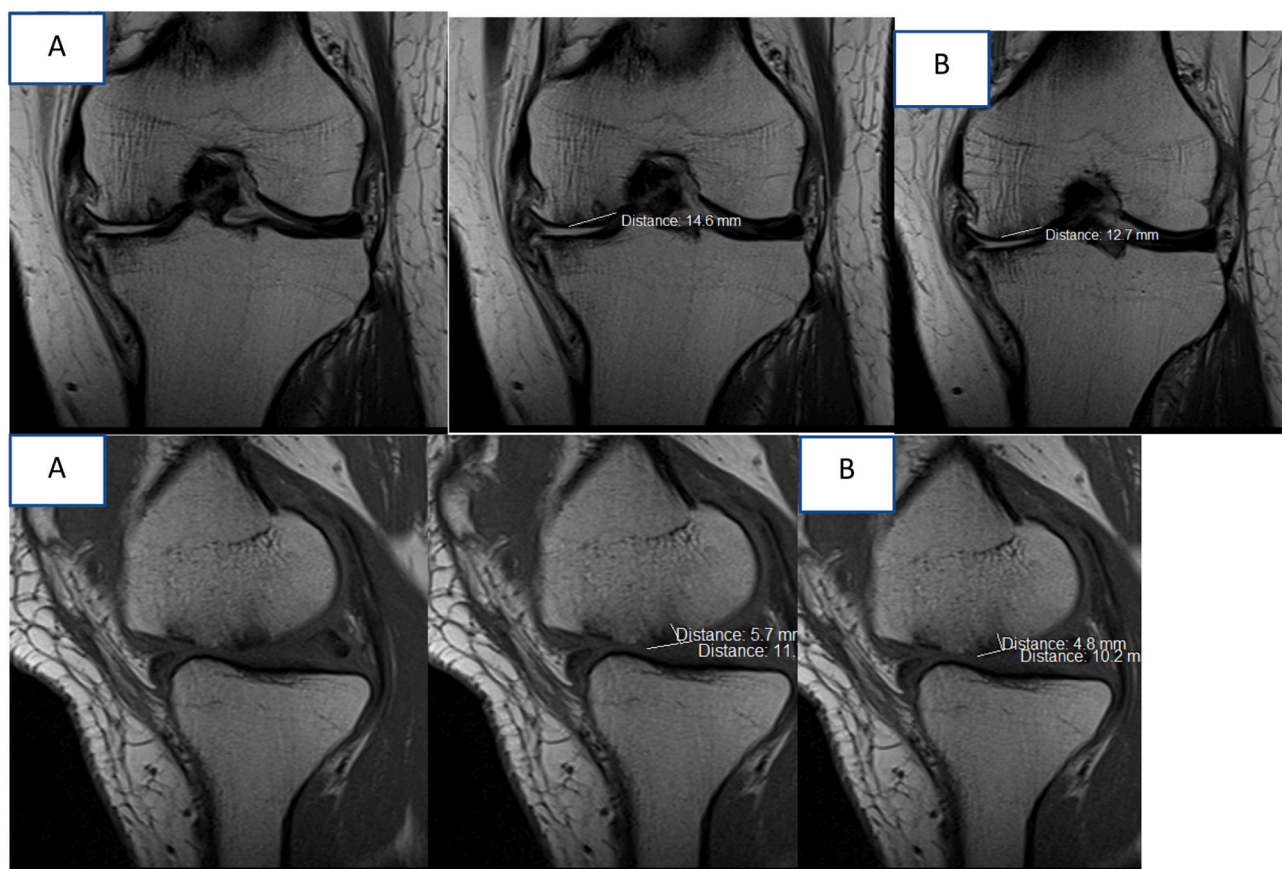


Fig. 4. Patient 1 A. MRI pre-operative and 6 month post-operative showed improvement of cartilage (preoperative 14,6 mm, postoperative 12,7 mm), AMADEUS score 40 (grade 3) and postoperative AMADEUS score 50 (grade 3).

in 6 months follow up. Brandt et al. in a randomized control trial of 226 patients found that HA injection improved WOMAC pain score for the duration of the study of 30 weeks. Study by Mathies et al. HA injection was performed after arthroscopy for meniscal tears. He found that patients had less pain at rest and during exercise when compared to a control group. Patients in the HA group were also noted to have less joint swelling and better Lysholm scores. Hempfling et al. in a recent study compared arthroscopic knee debridement and lavage for knee OA versus the same procedure with immediate injection of 10 ml of HA post arthroscopy. A total of 80 patients were followed prospectively for two years with 40 patients in each group. At the one year follow up time frame, patients in the debridement/lavage and HA group were found to have statistically longer lasting improvement in walking pain, night pain, and ability to walk 100 m with no complications observed. It was concluded that the post-arthroscopic instillation of a HA-based synovial fluid substitute into the joint is a suitable way of achieving long-term stabilization of the treatment outcome. However, their study did not utilize WOMAC and SF-36 questionnaires to evaluate functional efficacy [8].

Our three patients received intraarticular injection of HA combination with triamcinolone after bone marrow stimulation, at 6 months

follow up, all patients show improvement in WOMAC score. The prospective, randomized, double blind trial with parallel groups study by Wang et al., 120 patients who received co-treatment with HA and CS experienced pain relief and improved knee function faster than those who received HA alone. However, the combined use of HA and CS was not overall superior to HA in terms of pain control, knee function and range of motion at month 6 post-injection. By adhering to the joint cartilage, HA may protect the cartilage from CS erosion, improving the safety of CS application [9].

In our patient postoperative Interleukin 15 serum level was decreased at all patient it corresponds to study of Jian-Min Sun et al., 226 patient with primary knee OA were evaluate their WOMAC pain Score, Radiologic examination (Kellgren and Lawrence) and Interleukin 15 serum. They showed that serum IL-15 levels were positively associated with WOMAC-pain scores in OA patients. This association remained significant after the adjustment of potential confounders such as age, gender, and BMI, indicating that OA patients with high serum IL-15 levels may suffer a more severe self-reported pain. Increasing evidence indicated that chronic inflammation played an important pathophysiological role in the generation and maintenance of pain in OA patients. A previous study by Penninx et al. demonstrated that high concentrations

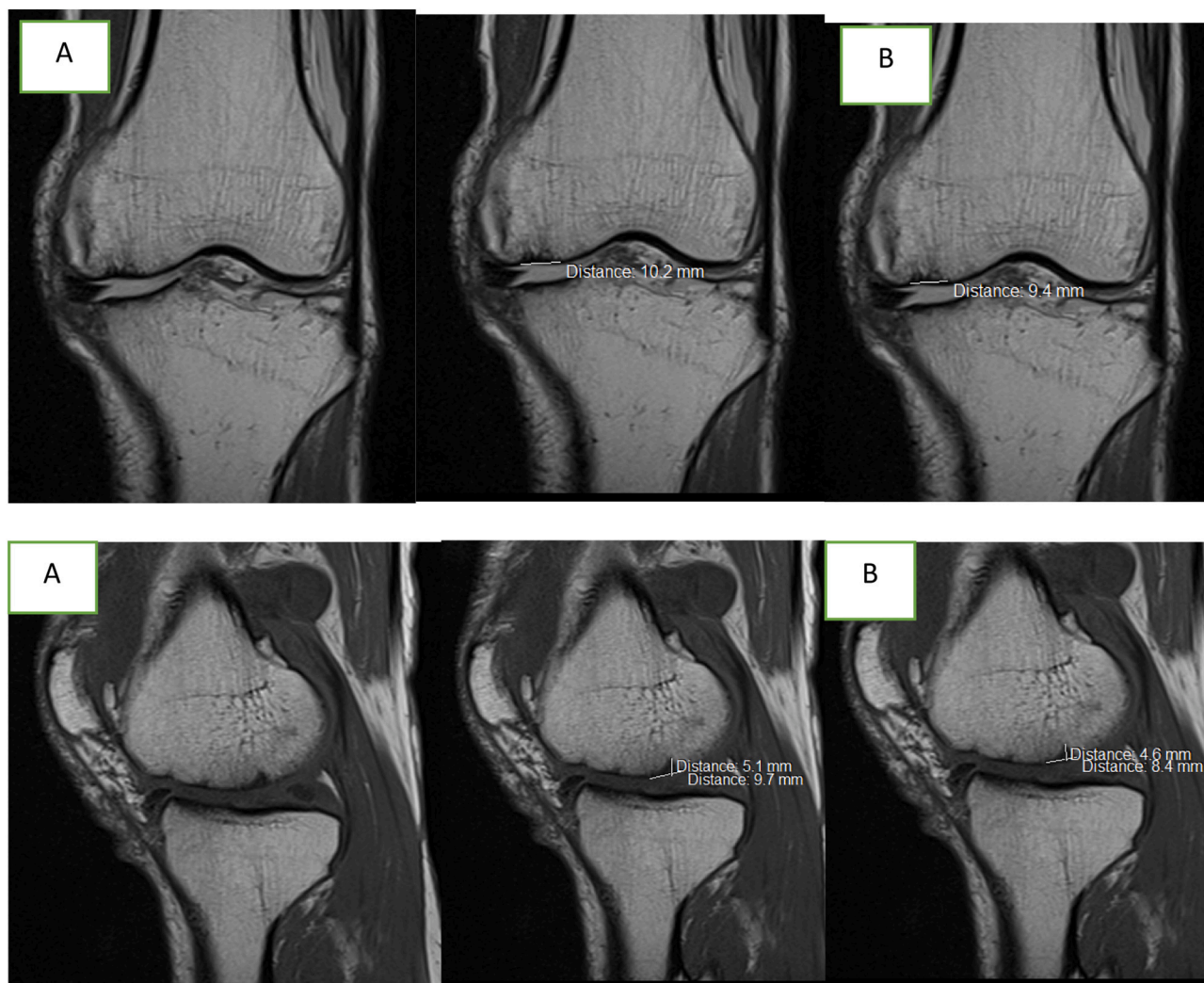


Fig. 5. Patient 2. MRI pre-operative and 6 months post-operative showed improvement of cartilage (preoperative 10,2 mm, postoperative 9,4 mm), AMADEUS score 45 (grade 3) and postoperative AMADEUS score 65 (grade 2).

of inflammatory markers in the serum were associated with increased pain of OA. IL-15 is a potent proinflammatory cytokine that plays a major role in the development of inflammatory and protective immune responses by modulating immune cells of both the innate and adaptive immune systems. IL-15 promotes the production of inflammatory cytokines such as tumor necrosis factor- α (TNF- α) and interleukin- (IL-) 6 in the synovial membrane via effects on synovial T cells. These inflammatory cytokines have been reported to contribute to OA pain by increasing cartilage degradation and inducing hyperalgesia via a number of direct and indirect actions. Therefore, the proinflammatory role of IL-15 might explain the relationship between serum IL-15 level and severity of OA pain observed in their study [10].

In a recent review of evidence base factors influencing arthroscopy for knee OA by Darling et al., the authors recommended arthroscopy for OA only in patients with short duration of symptoms, medial sided knee pain with localized tenderness, preservation of the joint space on radiograph, and mechanical symptoms. Patients with mechanical malalignment, flexion contracture, and obesity are not likely to have long term improvement after arthroscopy for knee OA. The above statements were also supported by several other studies [8].

4. Conclusions

Bone marrow stimulation and intraarticular injection with

triamcinolone and hyaluronic acid combination can be a valuable treatment option for moderate active patients with grade III knee osteoarthritis because bone marrow stimulation and intraarticular injection of hyaluronic acid and triamcinolone combination can improve functional outcome (WOMAC score) and cartilage repair of grade III knee osteoarthritis patient.

Sources of funding

This research did not receive any specific grant from funding agencies in the public, commercial, or not-for-profit sectors.

Ethical approval

The study was conducted in accordance with the Good Clinical Practice guidelines and in compliance with the principles of the Declaration of Helsinki. The study protocol was approved by the local Ethics Review Board from Hasanuddin University, Makassar, South Sulawesi, Indonesia.

Consent

Written informed consent was obtained from the patient for publication of this case report and accompanying images. A copy of the

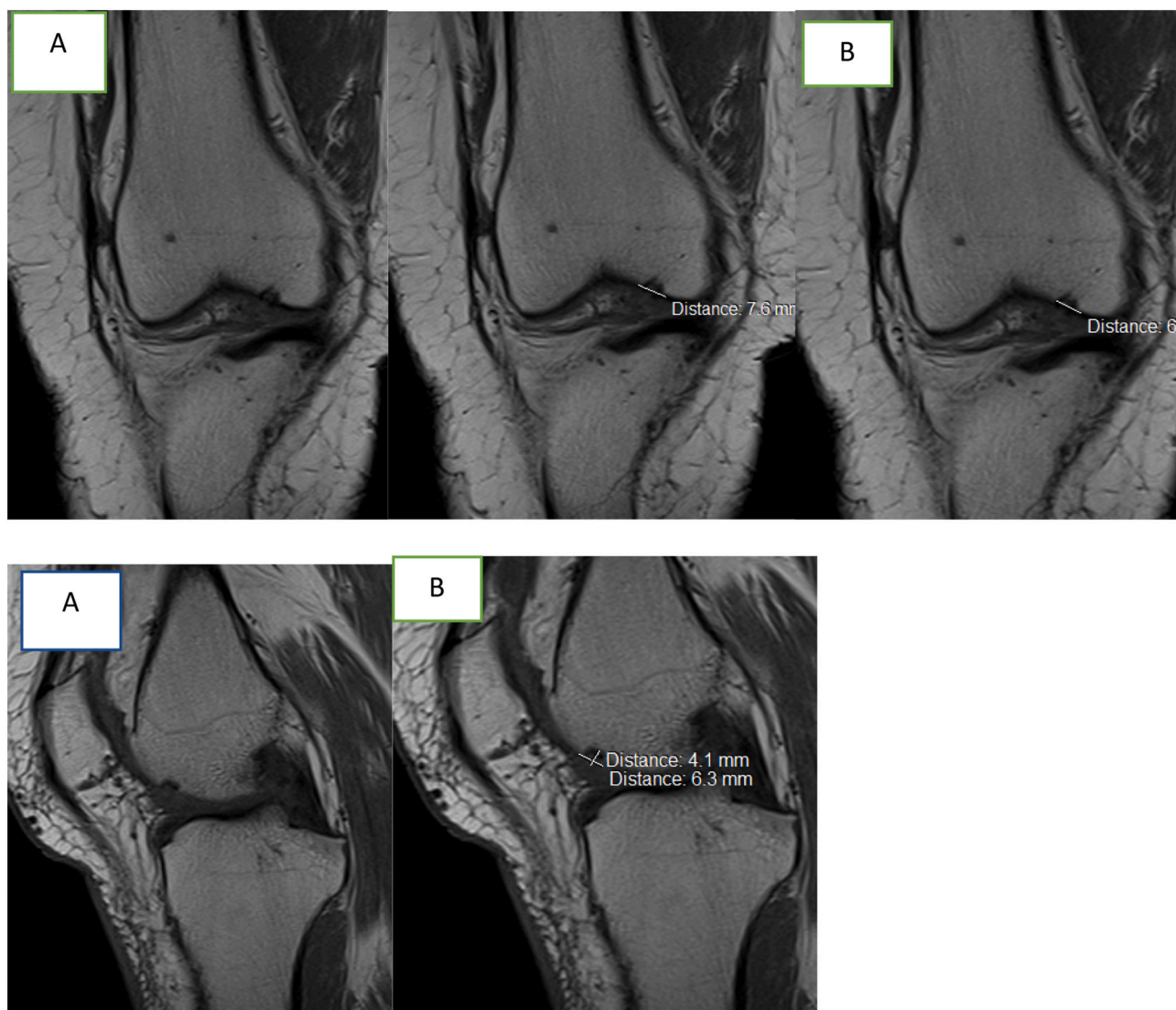


Fig. 6. Patient 3. MRI pre-operative (A) and postoperative (B) showed improvement of Cartilage (preoperative 7,5 mm postoperative 6,0 mm) with AMADEUS score 65 (grade 2) preoperative and 65 (grade 2) postoperative.

written consent is available for review by the Editor-in-Chief of this journal on request.

Author contribution

AA contributed in this concept or design, data analysis or interpretation, and writing the paper. BD, MAU, MS, AMTL, AB contributed in study concept or design, data collection, data analysis or interpretation, revising the paper. AA performed the surgical procedure.

Research registration

N/a.

Guarantor

BD, MAU, MS, AMTL, AB are guarantors of this study.

Provenance and peer review

Not commissioned, externally peer reviewed

Declaration of competing interest

None declared.

Acknowledgment

None.

References

- [1] R.F. Loeser, Age-related changes in the musculoskeletal system and the development of osteoarthritis, *Clin. Geriatr. Med.* 26 (3) (2010) 371–386, <https://doi.org/10.1016/j.cger.2010.03.002>. Available from:
- [2] P. Imayati, G. Kambayana, Case report: osteoarthritis, Available from, *E-Jurnal Medika Udayana* (2013) 1233–1234, <https://ojs.unud.ac.id/index.php/eum/article/view/5815>.
- [3] Haifei Xu, Z. Gaiping, X. Feiyi, L. Xiaojie, G. Li, W. Xueping, The diagnosis and treatment of knee osteoarthritis: literatur review, *Int J Clin Exp Med* (2019) 4589–4599.
- [4] Y. Yi-Meng, C. Brett, O.B. Luke, S. Steve, J.M. Peter, J. Richard S., Treatment of osteoarthritis of the knee with microfracture and rehabilitation, *Medicine & Science In Sports & Exercise* (2008) 200–205.
- [5] Riaz A. Agha, Thomas Franchi, Catrin Sohrabi, Ginimol Mathew, Ahmed Kerwan, the SCARE Group, The SCARE 2020 guideline: updating consensus Surgical Case REport (SCARE) guidelines, *International Journal of Surgery* 84 (2020) 226–230.

- [6] E. Christoph, P. Vavken, Microfracture for the treatment of cartilage defects in the knee joint – a golden standard? *Journal of Clinical Orthopaedics and Trauma* (2016) 145–152. Elsevier.
- [7] T.F. David, Arthroscopy as a treatment for knee osteoarthritis, *Best Pract. Res. Clin. Rheumatol.* 24 (1) (2010 February) 47.
- [8] L. Xinning, S. Agam, F. Patricia, M. Renee, B. Jill, B. Brian, Arthroscopic debridement of the osteoarthritic knee combined with hyaluronic acid (Orthovisc®) treatment: a case series and review of the literature, *J. Orthop. Surg. Res.* 1–8 (2008).
- [9] W. Shang-Zheng, W. Dong-Yi, C. Qing, G. Yu-Dong, W. Cheng, Wei-Min F. Intra-Articular, Single-shot co-injection of hyaluronic acid and corticosteroids in knee osteoarthritisA Randomized Controlled Trial, *Experimental And Therapeutic Medicine* (2018 May) 1928–1934.
- [10] S. Jian-Min, S. Liang-Zhi, L. Jun, S. Bao-Hui, S. Lin, in: *Serum Interleukin-15 Levels are Associated With Severity of Pain in Patients With Knee Osteoarthritis*, Disease Marker, Hindawi Publishing Corporation, 2013, pp. 203–206.