

Molluscum contagiosum effectively treated with a topical acidified nitrite, nitric oxide liberating cream

A.D.ORMEROD, M.I.WHITE, S.A.A.SHAH AND N.BENJAMIN*

Department of Dermatology, Aberdeen Royal Infirmary, Foresterhill, Aberdeen AB25 2ZN, U.K.

*Department of Clinical Pharmacology, St Bartholomew's Hospital, London EC1A 7BE, U.K.

Accepted for publication 16 July 1999

Summary

A double-blind, group-sequential clinical trial of acidified nitrite was performed to demonstrate the efficacy of this nitric oxide donor in treating molluscum contagiosum. Subjects received either 5% sodium nitrite co-applied with 5% salicylic acid under occlusion, or identical cream with 5% salicylic acid, omitting sodium nitrite. Active and control treatment groups were well matched for the number and duration of lesions and made a similar number of applications. We found a 75% cure rate in the active treatment group and 21% cure with control treatment ($P = 0.01$). The mean time to cure was 1.83 months. Staining of the skin and irritation were frequent side-effects but did not prevent successful treatment.

Key words: acidified nitrite, antiviral, molluscum contagiosum, nitric oxide

Molluscum contagiosum 1 and 2 are related to orthopox and parapox viruses and share some homology with vaccinia.^{1,2} Nitric oxide (NO) has been shown to have antiviral effects in DNA, RNA, enveloped and encapsidated viruses.^{3,4} It reduces replication of herpes simplex type 1,⁵ vaccinia and the orthopox ectromelia virus,⁶ murine coronavirus⁷ and *in vitro*, but not *in vivo*, has antiviral properties for avian reovirus infection.⁸ Not all viruses are inhibited by NO, e.g. tick-borne encephalitis virus is resistant to its effects.⁹ We have previously described the use of acidified nitrite cream as an NO donor to treat dermatophyte infections¹⁰ and now show the effectiveness of this topical treatment in molluscum contagiosum.

Within keratinocytes, the molluscum virion colonies are isolated in a unique sac¹¹ which provides an immunologically privileged environment for replication. Lesions lack a T-cell and killer cell infiltrate, reflecting absence of a host response. This may result from the expression of epitopes on the molluscum bodies¹² mimicking those normally found on the surface of macrophages. Current therapies include physical destruction, manual extrusion, liquid nitrogen therapy¹³ and curettage,¹⁴ all of which are painful, although pain can be reduced by lidocaine/prilocaine

Correspondence: Dr A.D.Ormerod.

E-mail: a.d.ormerod@abdn.ac.uk

This study was presented at the 1998 Annual Meeting of the British Association of Dermatologists, Brighton, U.K.

(Emla) cream.^{13,14} The pain of these therapies is important, as most patients are under 10 years old. There are few well conducted clinical trials of therapy for molluscum, although povidone iodine and 50% salicylic acid was effective in one such trial¹⁵ and 5% podophyllotoxin in another.¹⁶ Interestingly, the latter trial showed only a 16% response rate over 3 months with placebo therapy, demonstrating the slow rate of spontaneous resolution. The infection can be severe in patients with human immunodeficiency virus (HIV)-induced immunosuppression, where disfiguring facial lesions are a therapeutic problem.¹⁷ In some such patients, resolution with the antiviral cidofovir has been noted when coincidentally given for cytomegalovirus infection.¹⁸

Subjects and methods

As we could not estimate the size of the effect of this therapy, we chose a double-blind, group-sequential design¹⁹ in which subjects were randomized to receive either 5% sodium nitrite co-applied with 5% salicylic acid under occlusion, or identical cream with 5% salicylic acid but omitting sodium nitrite, as a control. Children under 1 year of age, pregnant or lactating women, an unco-operative child or mother, and those on immunosuppressive drugs or known to have HIV infection, were excluded. Lesions on the face were

Table 1. In the active and control groups, the mean values were similar for duration and number of lesions

	Active		Control	
	Cleared	Not cleared	Cleared	Not cleared
Duration (months)	8.5	5.2	8.6	7.9
Number of lesions	38	30	13	38

excluded because of potential stinging or staining of the skin. Subjects were asked to apply the treatment to each individual lesion every night and record the treatment in a diary. Wherever possible, occlusion with cling film or light adhesive tape was suggested, but certain body sites and widely distributed lesions often precluded occlusion. Statistical analysis was on an intention-to-treat basis. Repeated χ^2 analyses (Pearson's, SPSS statistical package) were scheduled after 15, 20, 25, 30 and 35 patients completed, with a prospective stopping rule for $P < 0.003$, 0.011, 0.016, 0.019 and 0.031 on successive analyses. Completion was defined as 3 months, or when the patient was cured or dropped out, if sooner. At least 1 month of treatment was necessary to be valid for efficacy. The log rank test was used to assess differences in cure rate over time, with the last evaluable status carried forward for drop-outs.

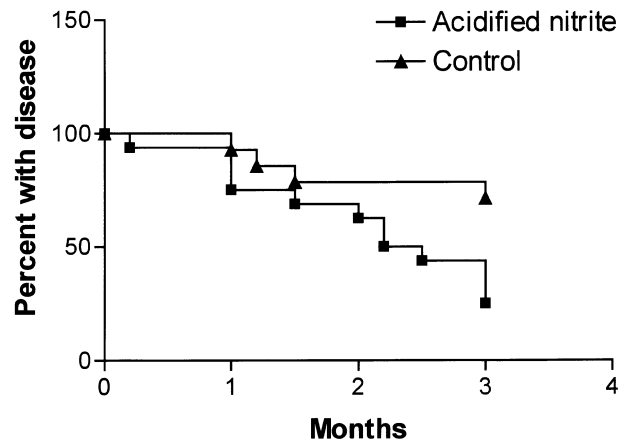
Results

The median age of subjects was 6 years and interquartile range 4 years. Twenty-two were girls and eight boys. The infection had a mean \pm SD duration of 8.23 ± 3.959 months. No significant difference was found between the active treatment and control groups in the number of lesions per patient or duration of these lesions (Table 1). Cure was significantly greater with NO treatment after 30 patients completed therapy, with 75% cure in the active treatment group and 21% cure with control treatment (Table 2) (χ^2 with Yates' correction $P = 0.01$, Fisher's exact test $P < 0.01$), and the mean time to cure \pm SD was 1.83 ± 0.91 months.

A Kaplan–Meier plot (Fig. 1) demonstrates the rate of cure over time and was analysed by the log rank test.

Table 2. Numbers of subject cured or not in the active and control groups

	Cured	Not cured
Acidified nitrite	12 (75%)	4 (25%)
Control	3 (21%)	11 (79%)

**Figure 1.** A Kaplan–Meier plot demonstrates the rate of cure over time.

This showed a significant difference in the survival curves, with cure being greater in the active group ($P < 0.01$). Four of 16 patients stopped the active treatment because of irritation and lack of efficacy, and two further patients who cleared complained of significant irritation. Similar irritation occurred in four of the controls. Lack of efficacy was the primary reason for stopping treatment in 10 of 14 controls. Brown staining was recorded in six subjects with active treatment but not in controls. Patients were not disturbed by this, as there was improvement in the lesions.

Subjects dropped out of the study evenly in both active and control groups, including subjects that were cured. Five active and four control subjects dropped out after 1 month, six in each group dropped out after 2 months, and five active and four control subjects completed 3 months. The mean \pm SD number of treatments in the active treatment group was 38 ± 20 compared with 49 ± 25 in the control group. This confirms that the control group did not fail to clear because of early withdrawal. Although instructed to apply the treatment nightly, on average it was only applied every second night. This was because treatment was fiddly and time-consuming or, where there was irritation, treatment was omitted for a few days. No other systemic or other adverse events were noted.

Discussion

Acidified nitrite cream is an effective therapy for this distressing condition and, unlike physical treatments, is

painless. Irritation was the main reason for stopping the therapy in the four non-responders to active therapy. Although staining of the skin was common in the active treatment group, it only occurred in six of 16. It is unlikely to have led to bias, as the end-point of cure of all lesions is an objective and specific end-point. Staining did not put patients off continuing the treatment, which was done by motivated parents, and could be overcome by reformulating the acidified nitrite, substituting a reducing acid for the salicylic acid. Molluscum is more common in subjects with eczema, and tends to induce eczematization of the surrounding skin.^{20,21} Some such patients tolerate this poorly, but the addition of topical steroids or use of an alternate day schedule has helped other patients. Applying creams under occlusion leads to displacement on to perilesional skin. A more viscous and occlusive formulation with applicators may be more successful. Adhesive tape can also be used and left in place to protect perilesional skin.

NO has specific antiviral effects at levels below those toxic to host cells,⁶ by inhibiting viral replication. It probably acts on several targets by inhibiting RNA synthesis, DNA replication, early and late viral protein synthesis and by nitrosylating viral structural proteins.⁴ We have shown that higher concentrations of NO from nitrite and ascorbic acid are immunopotentiating. We showed that NO caused lymphocyte, macrophage and neutrophil infiltration, expression of the adhesion molecules intercellular adhesion molecule-1 and vascular cell adhesion molecule-1 and migration of antigen-presenting cells.²² We also showed an increase in p53. It is therefore possible that NO acts through DNA toxicity to infected cells, promoting apoptotic cell death. We have successfully treated genital lesions of molluscum contagiosum and extensive lesions in two subjects with HIV infection. The immunosuppressed patients took longer to clear, suggesting that immunopotentialization contributes to the successful clearance of the virus.

References

- Martin-Gallardo A, Moratilla M, Funes JM *et al.* Sequence analysis of a molluscum contagiosum virus DNA region which includes the gene encoding protein kinase 2 and other genes with unique organization. *Virus Genes* 1996; **13**: 19–29.
- Douglass NJ, Blake NW, Cream JJ *et al.* Similarity in genome organization between molluscum contagiosum virus (MCV) and vaccinia virus (VV): identification of MCV homologues of the VV genes for protein kinase 2, structural protein VP8, RNA polymerase 35 kDa subunit and 3beta-hydroxysteroid dehydrogenase. *J Gen Virol* 1996; **77**: 3113–20.
- Mannick JB. The antiviral role of nitric oxide. *Res Immunol* 1995; **146**: 693–7.
- Reiss CS, Komatsu T. Does nitric oxide play a critical role in viral infections? *J Virol* 1998; **72**: 4547–51.
- Croen KD. Evidence for an antiviral effect of nitric oxide, inhibition of herpes simplex type 1 replication. *J Clin Invest* 1993; **91**: 2446–52.
- Karupiah G, Xie Q, Buller ML *et al.* Inhibition of viral replication by interferon gamma induced nitric oxide synthase. *Science* 1993; **261**: 1445–8.
- Lane TE, Paoletti AD, Buchmeier MJ. Disassociation between the *in vitro* and *in vivo* effects of nitric oxide on a neurotropic murine coronavirus. *J Virol* 1997; **71**: 2202–10.
- Pertile TL, Karaca K, Sharma JM, Walser MM. An antiviral effect of nitric oxide: inhibition of reovirus replication. *Avian Dis* 1996; **40**: 342–8.
- Kreil TR, Eibl MM. Nitric oxide and viral infection: NO antiviral activity against a flavivirus *in vitro*, and evidence for contribution to pathogenesis in experimental infection *in vivo*. *Virology* 1996; **219**: 304–6.
- Weller R, Ormerod AD, Hobson R, Benjamin N. A randomised trial of acidified nitrite cream in the treatment of tinea pedis. *J Am Acad Dermatol* 1998; **38**: 559–63.
- Shelley WB, Burmeister V. Demonstration of a unique viral structure: the molluscum viral colony sac. *Br J Dermatol* 1986; **115**: 557–62.
- Heng MC, Steuer ME, Levy A *et al.* Lack of host cellular immune response in eruptive molluscum contagiosum. *Am J Dermatopathol* 1989; **11**: 248–54.
- White MI, Weller R, Diack P. Molluscum contagiosum in children—evidence based treatment. *Clin Exp Dermatol* 1997; **22**: 51.
- Rosdahl I, Edmar B, Gisslen H *et al.* Curettage of molluscum contagiosum in children: analgesia by topical application of a lidocaine/prilocaine cream (Emla). *Acta Derm Venereol (Stockh)* 1988; **68**: 149–53.
- Ohkuma M. Molluscum contagiosum treated with iodine solution and salicylic acid plaster. *Int J Dermatol* 1990; **29**: 443–5.
- Syed TA, Lundin S, Ahmad M. Topical 0.3% and 0.5% podophyllotoxin cream for self-treatment of molluscum contagiosum in males. A placebo-controlled, double-blind study. *Dermatology* 1994; **189**: 65–8.
- Ficarra G, Cortes S, Rubino I, Romagnoli P. Facial and perioral molluscum contagiosum in patients with HIV infection. A report of eight cases. *Oral Surg Oral Med Oral Pathol* 1994; **78**: 621–6.
- Meadows KP, Tyring SK, Pavia AT, Rallis TM. Resolution of recalcitrant molluscum contagiosum virus lesions in human immunodeficiency virus-infected patients treated with cidofovir. *Arch Dermatol* 1997; **133**: 987–90.
- Pocock SJ. Monitoring trial progress. In: *Clinical Trials: A Practical Approach*. Chichester: Wiley, 1983: 147–51.
- Block SH. The association of molluscum contagiosum and infantile eczema. *Med J Aust* 1972; **2**: 626–7.
- Block SH. Eczema and molluscum contagiosum. *JAMA* 1973; **223**: 195.
- Ormerod AD, Copeland P, Hay I *et al.* The inflammatory and cytotoxic effects of nitric oxide releasing cream on normal skin. *J Invest Dermatol* 1999; **113**: 392–7.