

Native Coronary Artery and Grafted Artery Spasm Just after Coronary Artery Bypass Grafting: A Case Report

Native coronary artery spasm after coronary artery bypass grafting (CABG) is scarce. It frequently causes disastrous circulatory collapse. We report a 72-yr-old male, who experienced native coronary artery spasm and grafted artery spasm following CABG, which was successfully treated with coronary angiography and intracoronary injection of nitroglycerine.

Key Words : *Coronary Artery Bypass; Coronary Vasospasm*

© 2010 The Korean Academy of Medical Sciences.

This is an Open Access article distributed under the terms of the Creative Commons Attribution Non-Commercial License (<http://creativecommons.org/licenses/by-nc/3.0>) which permits unrestricted non-commercial use, distribution, and reproduction in any medium, provided the original work is properly cited.

**Jong Hyun Baek, Sung Sae Han,
and Dong Hyup Lee**

Department of Thoracic & Cardiovascular Surgery,
Yeungnam University College of Medicine, Daegu,
Korea

Received : 8 October 2008
Accepted : 3 December 2008

Address for Correspondence

Dong Hyup Lee, M.D.
Department of Thoracic & Cardiovascular Surgery,
Yeungnam University Medical Center, 317-1
Daemyeong 5-dong, Nam-gu, Daegu 705-717, Korea
Tel : +82.53-620-3880, Fax : +82.53-626-8660
E-mail : dhlee@med.yu.ac.kr

INTRODUCTION

Native coronary artery spasm after coronary artery bypass grafting (CABG) is scarce. But it frequently causes disastrous result. Here we report an untouched native coronary artery spasm and grafted coronary artery spasm following CABG, which was successfully treated with coronary angiography and intracoronary injection of nitroglycerin with review of associated literatures.

CASE REPORT

A 72-yr-old man had been taking medication for chronic stable angina pectoris since 1 yr before, and for hypertension since 4 months before. He was referred to the department of thoracic and cardiovascular surgery due to increasing intensity of chest pain as time goes by. The patient was a current smoker, who had undergone pulmonary tuberculosis with administration of beta blocking agent, calcium channel blocker (CCB), and acetyl salicylic acid (ASA) on admission. Pre-operative coronary angiogram (CAG) showed a 90% stenosis on the distal left main coronary artery, which bifurcating to left anterior descending branch and left circumflex branch (Fig. 1). Operation was conducted under general endotracheal anesthesia, and the left internal thoracic artery (ITA) was harvested (in situ) through median sternotomy. The left ITA was

anastomosed with the radial artery to form a composite Y-graft and then cardiopulmonary bypass (CPB) was started. Bypass grafting to the left anterior descending artery and to the obtuse marginal branch was done by using composite Y-graft. The patient was transferred to intensive care unit after uneventful weaning from the CPB following a satisfactory operation. Blood pressure and pulse rate were stable as 100/60 mmHg and 90 beats/min for initial 2 hr after the operation. After for a while, the electrocardiogram (EKG) showed depression of ST-segment on all over the leads, the blood pressure fell to 80/30 mmHg, and the pulse rate reached to 100 beat/min. The persistent ischemic signs, including ST-segment depression, hypotension, LVEF of 30% and severe global hypokinesia on echocardiogram, despite of intravenous dopamine infusion of 10 μ g/kg/min, made us to get an emergent CAG to confirm the patency of anastomosis. This CAG revealed severe spastic narrowing at the grafted coronary arteries (Fig. 1). Repetitive intracoronary infusion of nitroglycerin resolved the coronary artery spasm, but ongoing depression of ST-segment was observed on EKG. So, CAG about non-grafted, innocent right coronary artery (RCA) had to be done. CAG demonstrated severe vasospasm of RCA (Fig. 1), and also it was resolved with intracoronary infusion of nitroglycerin resulting in normalized ST-segment. Thereafter, he took oral medication of nicorandil as a vasodilator and CCB. He was discharged on the 15th postoperative day without re-attack of coronary spasm.

DISCUSSION

Coronary artery spasm before CPB during cardiac surgery was reported by MacAlpin et al. in 1973, and the first case of coronary artery spasm developed in the postoperative period CABG was reported in 1980 by Pichard et al. (1, 2). Since so many parameters are involved (1-4), the accurate incidence of postoperative coronary artery spasm is not clearly known. Buxton et al. reported the incidence is about 0.8% of whom underwent CABG (3, 5), Skarvan et al. 2.5%, and Lockerman et al. about 8% (1, 4). The etiology of coronary artery spasm after CABG is not clear, but several factors are thought to induce vasospasm, including transient high-release of norepinephrine and epinephrine in the immediate post-CPB period, administration of catecholamine such as dopamine, preoperative use of beta blocking agents or CCB, high dosage of nitroglycerin in the preoperative period, vascular injury by manipulation during surgery, platelet activation at the vascular endothelial injury site, high level of potassium exist-

ing in the focal area, respiratory alkalosis due to hyperventilation, hypomagnesemia, hypothermia, stimulation with a chest tube, and so forth (1-3, 5). But, Lockerman et al. (4) suggested that there is no relation between withdrawal of CCB, nitrate, nitroglycerin and the occurrence of postoperative coronary artery spasm. Also, many authors reported patients with normal dominant RCA without stenosis, and with history of resting angina before surgery as a high risk group to develop coronary artery spasm (1-3, 5, 6). Postoperative coronary artery spasm is most commonly manifested by ST-segment elevation and circulatory collapse without specific cause (1-3, 5). Lemmer and Kirsh reported that the most common manifestations are ST-segment elevation and life threatening severe hypotension, and that the coronary artery spasm commonly develops just after weaning from the CPB, within 2 hr after completion of operation, in the normal RCA without stenosis (1). We should aim the resolution of vasospasm as a target of therapy in the circulatory collapse due to coronary artery spasm. Most reports suggest to infuse nitroglycerin or CCB

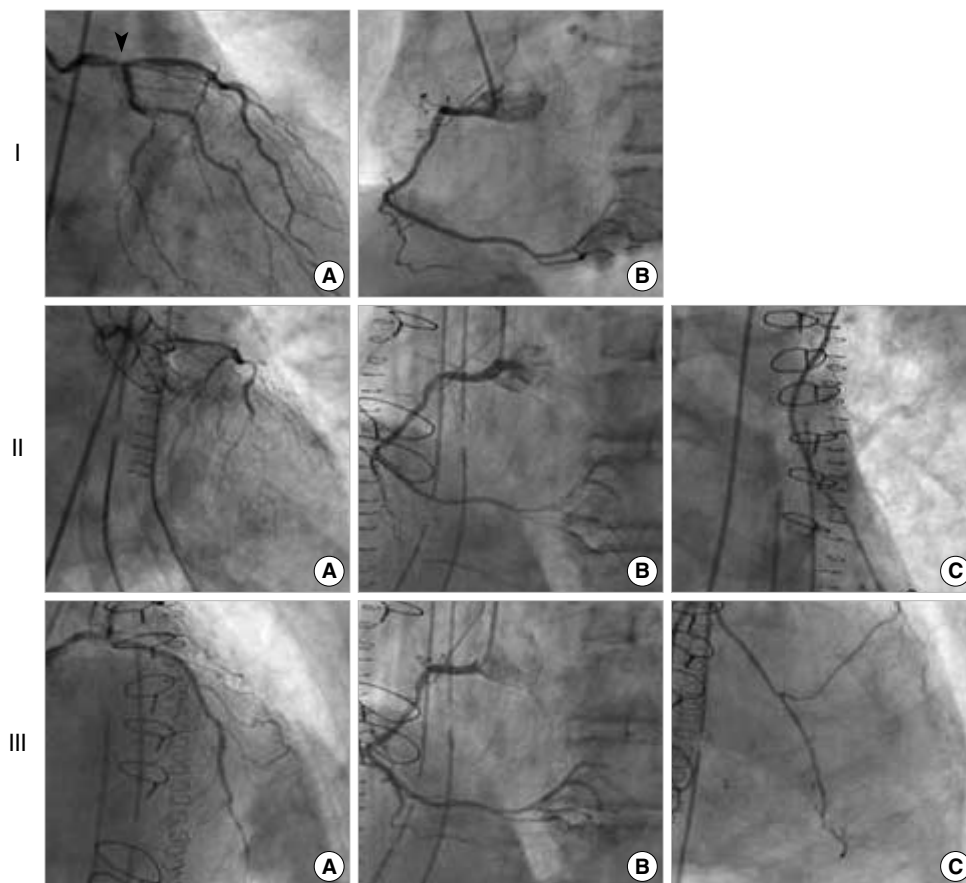


Fig. 1. Preoperative & postoperative coronary angiography. I. Preoperative coronary angiogram shows significant stenosis at distal left main coronary artery (A, arrowhead). Also shows normal right coronary artery (B). II. Postoperative coronary angiogram (about 2 hr after operation) shows severe spastic narrowing at grafted native coronary arteries (A, left anterior descending and left circumflex arteries), untouched native coronary artery (B, right coronary artery) and composite Y-graft (C, internal thoracic artery-radial artery). III. After intracoronary nitroglycerine injection, coronary angiography shows relief of spastic narrowing at grafted, non-grafted native coronary arteries (A, left anterior descending artery and B, right coronary artery), and composite Y-graft (C).

alone or in combination, which is more effective with intracoronary route than intravenous (1-4, 6). Schena et al. (5) reported a case of the nongrafted right coronary artery spasm treated with decisive balloon dilatation and stent insertion, which was intractable with intracoronary infusion of nitroglycerin and CCB. As observed in the Tarhan and colleagues' study, to prevent spasm of grafting artery, donor vessel should be manipulated carefully to minimize surgical trauma during harvest, endothelial injury must be avoided by maintaining the blood flow until just before distal anastomosis, body temperature and temperature of harvested vessel have to be strictly controlled as normothermia, and medication such as nitroglycerin and/or CCB also should be applied systemically or topically (7).

Although the incidence of coronary artery spasm after CABG is not high, we should get close observation of the patient who is in high risk group, because it can cause disastrous result without prompt adequate management. When unexplainable, sudden circulatory collapse after CABG accompanying ST-segment change comes up, we must keep in mind the spasm of untouched native coronary artery, grafted coronary artery, and grafting artery with high suspicion. In this scenario, we need to observe regional hypokinesia of myocardium on echocardiogram and to confirm vasospasm by CAG. When coronary artery spasm and/or grafting artery spasm are certified by the means mentioned above, intracoronary infusion of nitroglycerin or CCB only or in combination should be performed without reluctance, even in the hypotension status. Also, in case of highly suspicious vasospasm with diffi-

culty of CAG, immediate intravenous administration of nitroglycerin or CCB makes good results. We believe that correcting the hypothermic state aggressively, one of the etiologies of vasospasm, and applying IABP decisively may be helpful, too.

REFERENCES

1. Lemmer JH Jr, Kirsh MM. *Coronary artery spasm following coronary artery surgery. Ann Thorac Surg* 1988; 46: 108-15.
2. Kim YH, Kim H, Chung YS, Kang JH, Chung WS, Shinn SH. *Low cardiac output syndrome caused by a coronary artery spasm following CABG. Korean J Thorac Cardiovasc Surg* 2007; 40: 633-6.
3. Buxton AE, Goldberg S, Harken A, Hirshfield J Jr, Kastor JA. *Coronary-artery spasm immediately after myocardial revascularization: recognition and management. N Engl J Med* 1981; 304: 1249-53.
4. Lockerman ZS, Rose DM, Cunningham JN Jr, Lichstein E. *Postoperative ST-segment elevation in coronary artery bypass surgery. Chest* 1986; 89: 647-51.
5. Schena S, Wildes T, Beardslee MA, Lasala JM, Damiano RJ Jr, Lawton JS. *Successful management of unremitting spasm of the nongrafted right coronary artery after off-pump coronary artery bypass grafting. J Thorac Cardiovasc Surg* 2007; 133: 1649-50.
6. Paterson HS, Jones MW, Baird DK, Hughes CF. *Lethal postoperative coronary artery spasm. Ann Thorac Surg* 1998; 65: 1571-3.
7. Tarhan IA, Kehlibar T, Arslan Y, Yilmaz M, Dumantepe M, Berkoz K, Pancaroglu C, Ozler A. *Effects of normothermic organ bath and verapamil-nitroglycerin solution alone or in combination on the blood flow of radial artery. Eur J Cardiothorac Surg* 2007; 32: 617-22.