

Outcome of radial head preserving operations in missed Monteggia fracture in children

Parag Garg, Prashant Baid, Shivam Sinha, Rajeev Ranjan, Utpal Bandyopadhyay, SR Mitra

ABSTRACT

Background: The dislocated radial head in missed Monteggia fracture loses its concave articular surface and displays hypertrophic changes and flattened humeral capitellum configuration, thereby limiting the range of motion. We evaluated the results of open reduction in missed Monteggia fractures by various techniques.

Materials and Methods: Sixty-three missed Monteggia fractures were included in the analysis. We performed four combinations of operation: Group I: 22 patients treated with modified Hiramaya ulnar osteotomy plus annular ligament reconstruction with free Palmaris longus grafting; Group II: 18 patients treated with modified Hiramaya ulnar osteotomy plus annular ligament reconstruction by the Bell Tawse's procedure; Group III-9: patients treated with only modified Hiramaya's osteotomy; and Group IV: 14 patients treated with transverse osteotomy of ulna and annular ligament reconstruction by the Bell Tawse's procedure. During followup these cases were assessed for the following parameters: 1) range of motion and 2) mayo elbow performance index (MEPI). Results were noted on follow ups at 3, 6, 12 months and then on yearly basis. Sixty-three patients were followed up for an average duration of 5.6 years (range 3-8 years).

Results: The mean range of motion was increased by 45°, 30°, 45°, 20° for Group I, II, III and IV respectively. The average increase in MEPI scores was also almost on the same lines. There was one case of frank dislocation in group III and six cases of subluxation, two each in Groups II, III, and IV. For Annular ligament reconstruction, amongst two procedures, Groups II and IV (Bell Tawse group), had a significant extension lag contributing to the lower increase in the range of motion as compared to the Palmaris longus reconstruction group (group I).

Conclusion: Hiramaya's osteotomy is inherently more stable than the simple transverse osteotomy and it should be combined with annular ligament reconstruction. Palmaris longus graft for ligament reconstruction provides more stability as compare to Bell Towse's procedure.

Key words: Hiramaya's osteotomy, missed Monteggia, palmaris longus

INTRODUCTION

A missed Monteggia fracture leading to a persistent radial head dislocation is a widely known entity.^{1,2,5,7} The ignorance, lack of awareness and medical facilities lead to inadequate treatment of such fractures. The neglected radial head dislocation is diagnosed several months after the injury when the patient complains of elbow pain, decreased elbow flexion, valgus deformity, or

neurologic problems.^{1,4} If left untreated, the dislocated radial head loses its concave articular surface thereby limiting the range of motion.² It also hampers the normal growth of the radius and give rise to distal radio ulnar instability.² Open reduction of the radial head is of clinical significance. But such late cases have various problems such as stiffness of joint, excessive fibrosis, and radial head distortion. In this study, we evaluate the results of open reduction by various techniques to assess the advantages and disadvantages of each.

MATERIALS AND METHODS

This retrospective study includes sixty-three missed Monteggia fractures between June 2000 and June 2007. All the cases were operated by same surgeon (PG) who switched to different types of surgeries in the course of 7 years as newer techniques evolved. The inclusion criterias were all missed Monteggia fractures (diagnosed clinicoradiologically) with a persistent radial head dislocation in patients less than 18 years and demanding

Department of Orthopaedics, IPGMER, Kolkata, India

Address for correspondence: Dr. Parag Garg,
Department of Orthopaedics, IPGMER, Kolkata, India. E-mail: pgiluvu@gmail.com

Access this article online	
Quick Response Code:	Website: www.ijoonline.com
	DOI: 10.4103/0019-5413.83946

surgery for better functional or cosmetic results.

A missed Monteggia fracture was defined as any Monteggia fracture not treated adequately for more than 4 weeks.^{1,5-7} The usual complaint was pain, swelling and loss of function at the elbow joint and a clicking sound on elbow motion. All 63 patients were counseled about the missed fracture, the treatment to be offered, its effectiveness, and complications. The average age of the patient was 15.5 years (range 10-18 years) while most (n=50) of them had nondominant hand fractures.

The patients were clinically evaluated for elbow movements, deformity and stability. The following parameters were recorded 1) range of motion 2) mayo elbow performance index (MEPI). Radiological examination included anterior posterior and lateral views of both forearms with elbow. The ulnar bow was determined in a united fracture to determine the angle of the bent plate while performing modified Hirayama's osteotomy. Since the fractures were all old missed fractures it was difficult to exactly classify them according to paediatric classification. Instead we classified them according to Bado's classification. Most common type was anterior (Type I: n=42, 66%) and antero lateral (Type III: n=20, 30%) dislocations. This pattern was constant for all four groups. There was only one case of posterior dislocation (Type II: n=2, 3%) in Group I. We performed four combinations of operations.

1. Group I (n=22) – modified Hirayama ulnar osteotomy with annular ligament reconstruction with free Palmaris longus graft.
2. Group II (n=18) – modified Hirayama ulnar osteotomy with annular ligament reconstruction by Bell Tawse's procedure.
3. Group III (n=9) – only modified Hirayama's osteotomy.
4. Group IV (n=14) – transverse osteotomy of ulna, with annular ligament reconstruction by Bell Tawse's procedure.

The results were assessed by a different set of doctors. They were assessed on basis of time of surgery, complications, range of motion achieved, and MEPI. Anova F-test was used for tabulation of data. The condition of the radial head was also noted in all cases by radiographs and peroperative visualization (Group III had only radiographs). They were quantified radiologically according to the method of Kim et al.^{8,9}

Operative procedure

Skin incision was made beginning at the lateral epicondyle of the humerus continuing distally on the proximal metaphysis of the ulna, and extending to the middle

part of the posterior aspect of the ulna. The radial head was approached between the extensor carpi ulnaris, and anconeus. The ulna was then approached between the flexor carpi ulnaris and anconeus or the extensor carpi ulnaris. In all cases, an ulnar osteotomy was performed first, and then the radial head was reduced. A transverse osteotomy of ulna and fixation with a plate or rush nail was done in the first 15 cases which comprised our Group IV patients. Rest of them had a modified Hirayama's osteotomy done which is described below:

*Modified Hirayama's osteotomy*¹⁰ [Figure 1]: it is a bending osteotomy of the ulnar shaft using a prebent plate with the degree and site determined by preoperative drawings from the lateral radiographs. After the osteotomy at the proposed site, the prebent plate was placed over the posterior surface of ulna and a corticocancellous wedge shaped graft from the iliac crest was inserted in the gap thus created and the plate fixed *in situ*. This creates a posterior or lateral (depending on the original deformity) bend of around 15° (10°–25°) and an elongation of around 1 cm (8 to 14 mm). We used a seven-hole DCP or reconstruction plate in all cases. This correction usually replaces the radial head in its original position and also lends an inherent stability.

Annular ligament reconstruction: Annular ligament reconstruction was performed for all groups except for Group II. We used two methods of reconstruction. first one is the well-known Bell Tawse's procedure where a new annular ligament is reconstructed from a strip of the triceps fascia^{11,12} [Figure 2]. The second procedure is the reconstruction of the remnant of the annular ligament with free Palmaris longus graft. It requires identification of the remains of the torn annular ligament, clearance, and then reconstruction with a small free Palmaris longus graft harvested from the same hand¹ [Figure 3]. Only in the cases of an absence of Palmaris longus (two cases) we had to procure the graft from the opposite hand.

Wound was closed in layers over a drain and immobilized for 2 weeks in a plaster cast at 90° flexion in supination. We fixed the radius with a transcapitular k wire in all cases. The back slab and the wire were removed after 2 weeks and active elbow flexion and extension exercises were started. Pronation and supination were added after 4 weeks postoperatively. The patients were followed up at 3, 6, 12 months and then on yearly basis.

RESULTS

Sixty-three patients were followed up for an average duration of 5 years and 6 months (range 3-8 years) through clinical examination, radiographs, questionnaires, and

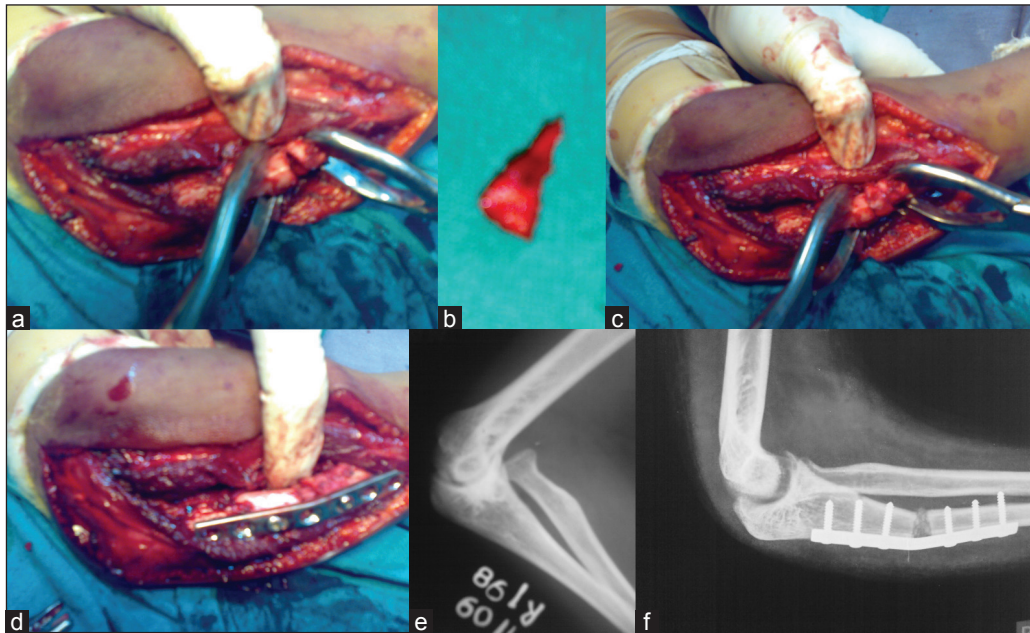


Figure 1: Peroperative clinical photographs (a,b,c,d) and X-rays (e,f) of modified Hirayama's osteotomy with the wedge graft showing (a) Osteotomy followed by bend creating an open wedge. (b) Wedge shaped graft from iliac crest. (c) Graft placed in the open wedge. (d) Osteotomy fixed with a pre bent plate. (e) Pre op X-ray. (f) Post op X-ray

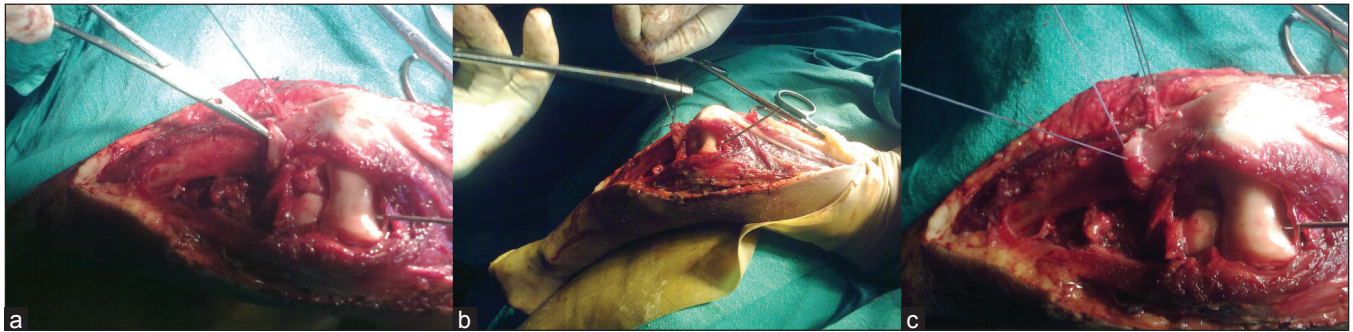


Figure 2: Peroperative clinical photographs of Bell Tawse's procedure: (left to right) – (a) Harvesting the triceps sling. (b) Encircling the radial head with the sling. (c) Suturing the sling

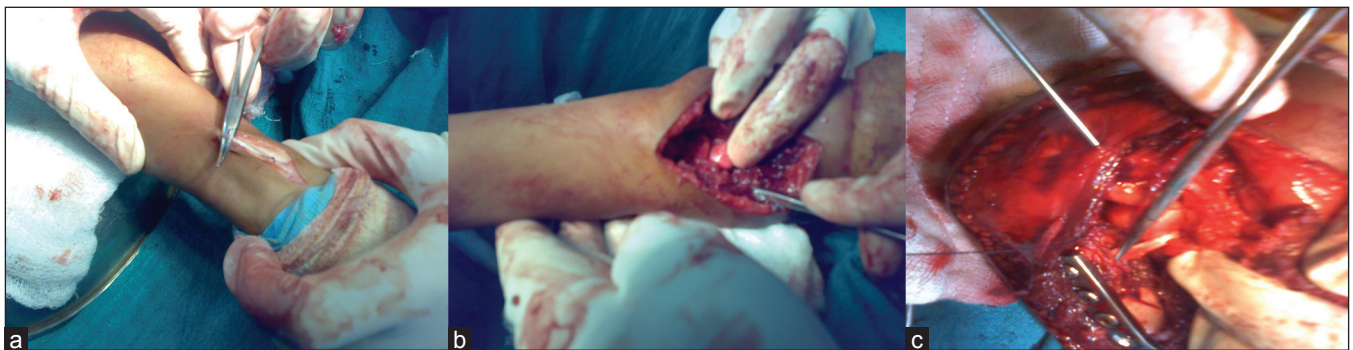

Figure 3: Peroperative clinical photographs of annular ligament reconstruction with Palmaris longus graft: (left to right) – (a) Harvesting Palmaris longus. (b) Identification of the remnants of the annular ligament. (c) Reconstruction with Palmaris longus

telephonic conversations. The average lapse to time from trauma to surgery was 1.6 years (ranging between 6 months to 3 years) for all four groups.

Fifty seven cases (85%) had no distortion of the radial head while 6 cases (15%) had a mild distortion of the radial

head. Four cases had flattening of the radial head while two had radial head hypertrophy. Of these six cases, two cases were each in Groups I and IV while the other two groups had one each. There was radiological union of all the osteotomies after 6 months of followup. The mean duration of radiological union for Hirayama's osteotomy (Groups I,

II, and III) was slightly less (8.5 weeks) as compared to the mean duration of the transverse osteotomy of 9 weeks, but the difference was not significant (P value > 0.1). Average time of surgery was the most for Group II, 90 mins (range 60–110 mins), 80 mins (range 60–90 mins) for Group I, 70 mins (range 50–80 mins) for Group IV, and was the least for Group III being only 40 mins (range 35–50 mins) [Table 1].

We observed five superficial infections, two each in Groups II and IV and one in Group I, which recovered after appropriate antibiotics and removal of K wire. There was a case of tourniquet palsy in a Group I patient that recovered fully in 3 months duration but had marginal loss of range of motion, but it led to some loss of range of motion. We believe it was due to the faulty application of the esmarch bandage tourniquet as other factors remained same during other surgeries.

The mean range of motion increased by 45° in both Groups I and III (45° to 90° for Group I and 35° to 80° for Group III). It increased only by 30° in Group II (45° to 65°) while even less, 20° in Group IV (40° to 60°). The average increase in the MEPI scores were also almost on the same lines, being the maximum for Group I (33 points, range 28–39) then Group III (32 points, range 25–35) followed by Group II (27 points, range 20–33) and the least for Group IV (18 points, range 15–22). We also compared the duration between the initial trauma and the surgery, and the condition of radial head at the time of surgery (visually and radiologically), with the MEPI scores. There were five cases that presented after more than 5 years of trauma. The average increase of MEPI score for these five cases was only 23 but none of them dislocated. Similarly the six cases with radial head distortion had a lower increase of the MEPI score (24) than the average of 28. Both increased lapse of time from initial trauma to surgery, and distortion of the radial head, had a negative impact on the MEPI scores but not on the dislocation rate.

There was one case of frank dislocation in Group III and six cases of subluxation, two in Groups II, III, and IV each. The frank dislocation in Group III took place 8 weeks postoperatively and decreased the range of motion considerably. There was also a fair incidence of subluxation of radial head in all other groups (11%, 22%, 14% for group

II, III and IV respectively) except Group I (0%), though none of them was significant enough to cause restriction of movement or require a reoperation.

For annular ligament reconstruction, amongst the two procedures, Groups II and IV (Bell Tawse group) had a significant extension lag contributing to the lower increase in range of motion (30° and 20°) as compared to the Palmaris longus reconstruction group (45°). The length of the scar and dissection required for annular ligament reconstruction using triceps fascia is much more than of that with Palmaris longus. Bell Tawse groups also had a longer average duration of surgery (90 mins) and infection rate (11.1%) than the Palmaris longus group (80 mins, 4.8%) (comparing Groups I and II to exclude the osteotomy factor).

DISCUSSION

Chronic radial head dislocation due to a missed Monteggia fracture is a vexing problem. It results primarily due to inadequate or no primary treatment at the time of injury.² The principle cause for the dislocation is the closed ring-like anatomy of the radius and ulna along with the interosseous membrane and the annular ligament.¹³ Disruption and malunion of the ulna leads to shortening and angulation of one arm of the ring. This is compensated on the other side by the dislocation of the radial head from its position. This gives us insight to the necessity of correction the length and angular deformity of the ulna and how it acts as the primary stabilizer for the reduction of the radial head.¹

World literature is filled with a plethora of osteotomies for correcting this deformity. They range between ulnar corrective osteotomy,^{6,14,15} ulnar bending osteotomy,^{16,22} radial rotation osteotomy,¹⁷ combined procedures of ulnar bending plus lengthening,^{1,10} and ulnar lengthening plus radial shortening.¹⁸ Our study proves that an ulnar bending plus lengthening osteotomy like Hirayama's osteotomy provides for a more stable reduction of the radial head than a simple transverse osteotomy with better long-term results. This osteotomy takes up a little more operative time than the transverse one, but we found that preoperative planning with line drawing and cuts reduced the time to almost the same. Preoperative planning also helps in accurate

Table 1: Observations on various parameters

	Time of union (in weeks)	Dislocation of radial head	Subluxation of radial head	Average duration of surgery (in minutes)	Increase in ROM (in degree)	Increase in MEPI scores	Infection
Group I (22)	8.5	-	-	80	45	33	1 (4.8)
Group II (18)	8.5	-	2 (11)	90	30	27	2 (11.1)
Group III (9)	8.5	1	2 (22)	40	45	32	-
Group IV (14)	9	-	2 (14)	70	20	18	2 (14.3)

Figures in parenthesis are in percentage

placement of the osteotomy and screws at the proper angle leading to a more anatomical, easier, and better reduction of the radial head.

There is no consensus over the addition of reconstruction of annular ligament to the various osteotomies. Some such as Nakamura *et al.*¹ and David-West *et al.*¹⁹ advocate it in all cases while others such as Devanani⁷ and Bhojraj *et al.*²⁰ disregard it completely. Others like Bhaskar *et al.*⁵ go for an intraoperative decision based on the stability of reduction. As we always performed the ulnar osteotomy first, a common finding after the first few modified Hirayama's osteotomy was that the radial head reduced automatically just after fixing the plate without any direct intervention. This led us to falsely believe that anatomical reduction and correction of the deformity takes away the dislocation forces on the radial head, leading to a stable radial head. Therefore, we skipped the annular ligament reconstruction in one group of patients (Group III). This group had one dislocation and two subluxations which was clearly more than any other group. This made us realize that soft-tissue forces also play a major role in the stability of the radial head which can be achieved only by reconstruction of the annular ligament. Thus, we believe that Hirayama's osteotomy is inherently more stable than the simple transverse osteotomy as evident by comparing the subluxation rate of Groups II and IV. The Hirayama's osteotomy alone is not sufficient for all cases (Group III) and should be combined with an annular ligament reconstructive procedure.

Historically there have been numerous methods of reconstruction of the annular ligament using the forearm fascia,²³ triceps fascia^{11,21,22} and most recently the Palmaris longus graft.^{4,21} Direct repair is not possible in these long-standing cases of chronic dislocations. We used both triceps fascia and Palmaris longus graft for this reconstruction. However, the material of the sling is not the only difference in the two procedures. The Bell Tawse's procedure involves using a triceps sling attached on the ulna to go around the radial head and forming a new sling around it by reattaching it with the ulna.^{11,12} But the Palmaris longus is a free graft, where we actually use the remnants of the annular ligament and just bridge the gap or defect with the free graft. Palmaris longus free graft augmentation of the remnant is thus a more physiological procedure leading to better results in not only containing the head, but also providing better range of motion due to no morbidity of the triceps causing an extension lag as observed in most of our Bell Tawse cases. This procedure is more anatomical as it recreates the same shape and size of sling that originally existed for the radial head to remain in place.¹ It also avoids the complication of too tight slings leading to notching and restriction of motion which is so common with the other procedures.

The length of the scar and dissection required for annular ligament reconstruction using triceps fascia (Bell Tawse's procedure) is much more than of that with Palmaris longus. We believe that this also leads to an increase in operative time and along with increased chances of infection as shown in our study (comparing Groups I and II). We also found Palmaris longus reconstruction to be technically easier than the Bell Tawse's procedure especially after the identification of the remnants. Our followup functional results also favor this group of patients. One exception to this operation is the bilateral absence of Palmaris longus which compels the surgeon to use some other method.¹ We did not have any such case in this series.

After comparing all these four groups we found that modified Hirayama's osteotomy with annular ligament reconstruction with Palmaris longus free graft serves as the better option for chronic radial head dislocation in patient's with missed Monteggia fractures.

REFERENCES

1. Nakamura K, Hirachi K, Uchiyama S, Takahara M, Minami A, Imaeda T. Term clinical and radiographic outcomes after open reduction for missed Monteggia fracture-dislocations in children. *J Bone Joint Surg Am* 2009;91:1394-404.
2. Rodgers WB, Waters PM, Hall JE. Chronic Monteggia lesions in children. Complications and results of reconstruction. *J Bone Joint Surg Am* 1996;78:1322-9.
3. Holst-Nielsen F, Jensen V. Tardy posterior interosseous nerve palsy as a result of an unreduced radial head dislocation in Monteggia fractures: A report of two cases. *J Hand Surg Am* 1984;9:572-5.
4. Chen WS. Late neuropathy in chronic dislocation of the radial head. Report of two cases. *Acta Orthop Scand* 1992;63:343-4.
5. Bhaskar A. Missed Monteggia fracture in children: Is annular ligament reconstruction always required? *Indian J Orthop* 2009;43:389-95.
6. Stoll TM, Willis RB, Paterson DC. Treatment of the missed Monteggia fracture in the child. *J Bone Joint Surg Br* 1992;74:436-40.
7. Devnani AS. Missed Monteggia fracture dislocation in children. *Injury* 1997;28:131-3.
8. Kim HT, Conjares JN, Suh JT, Yoo CI. Chronic head dislocation in children, Part 1: Pathologic changes preventing stable reduction and surgical correction. *J Pediatr Orthop* 2002;22:583-90.
9. Kim HT, Park BG, Suh JT, Yoo CI. Chronic radial head dislocation in children, Part 2: Results of open treatment and factors affecting final outcome. *J Pediatr Orthop* 2002;22:591-7.
10. Hirayama T, Takemitsu Y, Yagihara K, Mikita A. Operation for chronic dislocation of the radial head in children. Reduction by osteotomy of the ulna. *J Bone Joint Surg Br* 1987;69:639-42.
11. Bell Tawse AJ. The treatment of malunited anterior Monteggia fractures in children. *J Bone Joint Surg Br*. 1965;47:718-23.
12. Cappellino A, Wolfe SW, Marsh JS. Use of a modified Bell Tawse procedure for chronic acquired dislocation of the radial head. *J Pediatr Orthop* 1998;18:410-4.

13. Nakamura T, Yabe Y, Horiuchi Y. Functional anatomy of the interosseous membrane of the forearm—dynamic changes during rotation. *Hand Surg* 1999;4:67-73.
14. Best TN. Management of old unreduced Monteggia fracture dislocations of the elbow in children. *J Pediatr Orthop* 1994;14:193-9.
15. Fowles JV, Sliman N, Kassab MT. The Monteggia lesion in children. Fracture of the ulna and dislocation of the radial head. *J Bone Joint Surg Am* 1983;65:1276-82.
16. Kalamchi A. Monteggia fracture-dislocation in children. Late treatment in two cases. *J Bone Joint Surg Am* 1986;68:615-9.
17. Futami T, Tsukamoto Y, Fujita T. Rotation osteotomy for dislocation of the radial head. 6 cases followed for 7 (3-10) years. *Acta Orthop Scand* 1992;63:455-6.
18. Freedman L, Luk K, Leong JC. Radial head reduction after a missed Monteggia fracture: Brief report. *J Bone Joint Surg Br* 1988;70:846-7.
19. David-West KS, Wilson NI, Sherlock DA, Bennet GC. Missed Monteggia injuries. *Injury* 2005;36:1206-9.
20. Bhojraj SD. Surgical correction of malunited Monteggia fractures in children. *Indian J Orthop* 1981;21-2:138-44.
21. Lloyd-Roberts GC, Bucknill TM. Anterior dislocation of the radial head in children: Aetiology, natural history and management. *J Bone Joint Surg Br* 1977;59:402-7.
22. Inoue G, Shionoya K. Corrective ulnar osteotomy for malunited anterior Monteggia lesions in children. 12 patients followed for 1-12 years. *Acta Orthop Scand* 1998;69:73-6.
23. Speed JS, Boyd HB. Treatment of fractures of ulna with dislocation of head of radius. *JAMA* 1940;115:1699-705.

How to cite this article: Garg P, Baid P, Sinha S, Ranjan R, Bandyopadhyay U, Mitra SR. Outcome of radial head preserving operations in missed Monteggia fracture in children. *Indian J Orthop* 2011;45:404-9.

Source of Support: Nil, **Conflict of Interest:** None.