

Brain Dopamine Transporter Binding and Glucose Metabolism in Progressive Supranuclear Palsy-Like Creutzfeldt-Jakob Disease

Eero Rissanen^{a, b} Valtteri Kaasinen^{a, b} Pirkko Sonninen^d
Matias Røyttä^c Markku Päivärinta^b

^aTurku PET Centre, ^bDivision of Clinical Neurosciences, and ^cDepartment of Pathology, University of Turku and Turku University Hospital, and ^dNeuroradiology Department, Turku University Hospital, Medical Imaging Centre of Southwest Finland, Turku, Finland

Key Words

Creutzfeldt-Jakob disease · Progressive supranuclear palsy · PET · MRI

Abstract

Here, we present a patient with Creutzfeldt-Jakob disease (CJD) who developed initial symptoms mimicking progressive supranuclear palsy (PSP). Before the development of typical CJD symptoms, functional imaging supported a diagnosis of PSP when [¹²³I]-FP-CIT-SPECT showed a defect in striatal dopamine transporter binding, while [¹⁸F]-fluorodeoxyglucose PET showed cortical hypometabolism suggestive of Lewy body dementia. However, the postmortem neuropathological examination was indicative of CJD only, without tau protein or Lewy body findings. This case demonstrates that CJD should be taken into account in rapidly progressing atypical cases of parkinsonism, even when functional imaging supports a diagnosis of a movement disorder.

© 2014 S. Karger AG, Basel

Introduction

Creutzfeldt-Jakob disease (CJD) is a rare and fatal prion disease that is characterised by rapidly progressive neurodegeneration, with myoclonia, ataxia, advancing dementia, akinetic mutism, and visual disturbances as presenting symptoms [1, 2]. In addition to the typical myoclonic jerks, extrapyramidal symptoms such as parkinsonism, dystonia, and

Eero Rissanen, MD
Turku PET Centre, Turku University Hospital
PO Box 52
FI-20521 Turku (Finland)
E-Mail eerris@utu.fi

chorea are also possible clinical manifestations of CJD, and the frequency of extrapyramidal symptoms increases with the duration of the disease [1, 2].

In this report, we present a patient with neuropathologically confirmed CJD who developed initial symptoms closely mimicking progressive supranuclear palsy (PSP). Before the development of more classical symptoms of CJD, [¹²³I]-FP-CIT-SPECT showed a clear striatal dopaminergic defect, and [¹⁸F]-fluorodeoxyglucose (FDG) PET showed widespread cortical losses in glucose metabolism.

Case Report

A 58-year-old male was referred to a neurologist specialised in movement disorders in June 2009. He had a 6-month history of increasing clumsiness, forgetfulness, and apathy. The patient had a history of atrial fibrillation and concomitant mild dilative cardiomyopathy. He was taking warfarin, bisoprolol, digitalis, and candesartan. A 1.5-T brain MRI did not show clinically significant findings. A neurological examination revealed mildly diminished arm swing bilaterally, slight hypomimia, hypokinesia, cervical axial rigidity, and decreased frequency of blinking. The combination of hypokinesia, axial rigidity, and symmetrical extrapyramidal symptoms, in the absence of tremor, gave rise to suspicion of PSP. Levodopa was initiated with increasing doses up to 400 mg/day. One month later, increased latency in saccadic eye movements in downward gaze was noted, and postural retropulsion was evident. No favorable response to levodopa was noted, and the patient reported visual hallucinations. Consequently, the medication was withdrawn.

The patient was referred to the Neurology Outpatient Clinic of the University Hospital for further diagnostics and clinical follow-up. Dopamine transporter imaging with [¹²³I]-FP-CIT-SPECT was performed 9 months after the onset of symptoms. The scan showed clear reductions in tracer binding in the left caudate nucleus compared to the right side and bilaterally in the posterior putamen (striatal to occipital uptake ratio: 2.42 on the right and 2.02 on the left) (fig. 1a). Neuropsychological testing revealed marked cognitive impairment manifesting as slowed executive functions and impaired working and short-term memory as well as visual recognition and processing. Psychomotor slowing and mild apraxia were also noted. FDG-PET showed widespread reductions in FDG binding bilaterally in cortical and deep grey matter, with a small area of preserved cortical binding in the frontoparietal region (fig. 1b). The FDG-PET findings were clinically interpreted to be suggestive of Lewy body dementia.

During follow-up, rigidity further increased axially and also became present in the lower extremities. The patient's gaze was staring, and saccadic eye movements were slow. No tremor was present, but bradykinesia had increased substantially. At this time, in January 2010, he was still ambulatory, although he needed bilateral walking aids intermittently. In April 2010, the patient was admitted to an emergency unit due to deteriorating condition. He was now bedbound and aphasic, his upper limbs were in constant flexion, and intermittent myoclonic jerks, especially in the left upper limb, were present. CT of the head only revealed increased central atrophy. An EEG showed posterior theta-delta background activity with 3 slowly generalising spike-slow-wave discharges frontally without clinical motor symptoms. After intravenous lorazepam, the abnormal discharge subsided without improvement in the clinical status. The EEG was interpreted to be consistent with nonconvulsive status epilepticus, and the patient was treated with an intravenous loading dose of fosphenytoin and further with sodium valproate. However, his clinical condition remained essentially the same, and the suspicion of prion disease was raised. A control EEG, performed the next day,

showed no epileptiform discharges, whereas semi-rhythmic, slow, mixed activity periods alternating with rhythmic, triphasic PED activity were evident. Per oral clonazepam (via nasogastric tube) alleviated, but did not stop, the myoclonic jerks. A brain MRI showed no structural abnormalities, whereas pathological changes in diffusion tensor imaging concurrent with CJD were seen (fig. 1c, d); however, other infectious or inflammatory etiology could not be excluded.

In cerebrospinal fluid (CSF) analysis, the protein content was elevated to 1,216 mg/l (normal range 150–450 mg/l), but no discoloration or pleocytosis was present, and comprehensive examinations revealed no signs of active autoimmune or infectious diseases. CSF Western blot analysis showed small amounts of 14-3-3 protein. The patient was unable to communicate or react meaningfully to physical stimuli, and at this point, 1.5 years since the first symptoms, he was transferred to a nursing home for palliative care. The patient succumbed 22 months after the onset of initial symptoms.

In order to confirm the diagnosis, a neuropathological examination was performed. Under macroscopic inspection, the cerebral cortex appeared atrophic and slightly spongiform. Atrophy of the caudate nucleus was apparent, and moderate dilatation of brain ventricles was noted. However, the striatum did not show any marked macroscopic changes. There were no major changes in the substantia nigra, pons or medulla, whereas marked atrophy of the cerebellum was observed. The histological samples showed marked spongiform changes in the cerebral cortex (fig. 1d). Abundant spongiform changes and gliosis as well as nerve cell loss were found in the caudate nucleus, putamen, and thalamus (fig. 1e). The substantia nigra did not show any obvious loss of neurons, but slight spongiosis was noted. In the cerebellum, a marked loss of Purkinje cells as well as granular cells was observed with numerous torpedoes in the granular cell layer. Immunohistochemically, a positive finding for prion protein was discovered using the monoclonal antibody 12F10, confirming the diagnosis of CJD.

This case study was conducted according to the World Association's Declaration of Helsinki. Since it was an observational retrospective study of a clinical patient case following the local guidelines of investigation and treatment procedures, no separate permission from the local ethics committee was needed. Written informed consent was obtained from the patient's caregiver.

Discussion

Although a rare presentation in prion disease, PSP-like symptoms have been reported to occur in individual cases [3–10] (table 1). Our patient's case of PSP mimicking sporadic CJD, however, is unique in its functional neuroimaging data followed by the neuropathological examination confirming the diagnosis and showing no postmortem signs of PSP or Lewy body disease pathology. Therefore, although clinical signs and imaging results suggested multiple diagnoses, the histological diagnosis was valid for CJD only.

CIT-SPECT is considered to reflect mainly presynaptic dopamine transporter protein activity as well as the number of vital presynaptic nerve terminals within the striatum. Similar to our findings, in a recent observation by Ragno et al. [11] a patient with unilateral extrapyramidal rigidity as a first symptom of CJD was found to have reduced uptake of [¹²³I]-FP-CIT in dopamine transporter SPECT imaging in the contralateral putamen, thus corresponding to the clinical symptoms. However, the detailed mechanisms of the dopaminergic loss in prion diseases are unknown.

As for the extensive reductions in brain glucose metabolism in our patient, previous PET imaging studies in sporadic CJD demonstrated widespread cortical and deep gray matter hypometabolism with [¹⁸F]-FDG [12, 13]. Interestingly, Zhang et al. [14] have reported a patient with CJD mimicking corticobasal degeneration, in whom SPECT and FDG-PET revealed unilateral hypoperfusion and hypometabolism in the frontoparietal and temporal cortices correlating to the contralateral clinical symptoms. Thus, FDG-PET may be a relevant option for secondary diagnostic examinations in PSP patients who develop atypical features in rapid progression. Importantly, the bilateral cortical hypometabolic regions were observed in our patient when he was still cooperative and ambulatory, 4 months before myoclonic jerks emerged.

Conclusion

Although prion disease is a rare cause of movement disorders [15], this case demonstrates that CJD should be taken into account as a differential diagnostic option when a patient with atypical parkinsonism presents with an unusual progression of cognitive symptoms and when functional neuroimaging findings do not support the initial diagnosis. Our report also emphasises the importance of a properly functioning chain of treatment from the initial clinical contact through to the later stages of palliative care of a patient with suspected CJD, followed by neuropathological confirmation of the disease.

Disclosure Statement

This work was supported by a personal study grant from the Finnish Parkinson Foundation. None of the authors declare any conflicts of interest.

References

- 1 Masters CL, Richardson EP: Subacute spongiform encephalopathy (Creutzfeldt-Jakob disease). The nature and progression of spongiform change. *Brain* 1978;101:333–344.
- 2 Maltete D, Guyant-Marechal L, Mihout B, et al: Movement disorders and Creutzfeldt-Jakob disease: a review. *Parkinsonism Relat Disord* 2006;12:65–71.
- 3 Bertoni JM, Label LS, Sackelleres JC, et al: Supranuclear gaze palsy in familial Creutzfeldt-Jakob disease. *Arch Neurol* 1983;40:618–622.
- 4 Kawasaki K, Wakabayashi K, Kawakami A, et al: Thalamic form of Creutzfeldt-Jakob disease or fatal insomnia? Report of a sporadic case with normal prion protein genotype. *Acta Neuropathol* 1997;93:317–322.
- 5 Zarei M, Nouraei SA, Caine D, et al: Neuropsychological and quantitative oculometric study of a case of sporadic Creutzfeldt-Jakob disease at predementia stage. *J Neurol Neurosurg Psychiatry* 2002;73:56–58.
- 6 Shimamura M, Uyama E, Hirano T, et al: A unique case of sporadic Creutzfeldt-Jacob disease presenting as progressive supranuclear palsy. *Intern Med* 2003;42:195–198.
- 7 Josephs KA, Tsuboi Y, Dickson DW: Creutzfeldt-Jakob disease presenting as progressive supranuclear palsy. *Eur J Neurol* 2004;11:343–346.
- 8 Rowe DB, Lewis V, Needham M, et al: Novel prion protein gene mutation presenting with subacute PSP-like syndrome. *Neurology* 2007;68:868–870.
- 9 Prasad S, Ko MW, Lee EB, et al: Supranuclear vertical gaze abnormalities in sporadic Creutzfeldt-Jakob disease. *J Neurol Sci* 2007;253:69–72.
- 10 Huber FM, Bour F, Sazdovitch V, et al: Creutzfeldt-Jakob disease with slow progression. A mimicry of progressive supranuclear palsy. *Bull Soc Sci Med Grand Duche Luxemb* 2007;2:125–130.
- 11 Ragno M, Scarcella MG, Cacchio G, et al: Striatal [¹²³I] FP-CIT SPECT demonstrates dopaminergic deficit in a sporadic case of Creutzfeldt-Jakob disease. *Acta Neurol Scand* 2009;119:131–134.

- 12 Friedland RP, Prusiner SB, Jagust WJ, et al: Bitemporal hypometabolism in Creutzfeldt-Jakob disease measured by positron emission tomography with [¹⁸F]-2-fluorodeoxyglucose. *J Comput Assisted Tomogr* 1984;8:978–981.
- 13 Henkel K, Zerr I, Hertel A, et al: Positron emission tomography with [(18)F]FDG in the diagnosis of Creutzfeldt-Jakob disease (CJD). *J Neurol* 2002;249:699–705.
- 14 Zhang Y, Minoshima S, Vesselle H, et al: A case of Creutzfeldt-Jakob disease mimicking corticobasal degeneration: FDG PET, SPECT, and MRI findings. *Clin Nucl Med* 2012;37:e173–e175.
- 15 Jendroska K, Hoffmann O, Schelosky L, et al: Absence of disease related prion protein in neurodegenerative disorders presenting with Parkinson's syndrome. *J Neurol Neurosurg Psychiatry* 1994;57:1249–1251.

Table 1. Cases of neuropathologically confirmed CJD with PSP among the presenting symptoms

Author(s), year	Cases, n	Disease type	CSF 14-3-3 protein assay	MRI suggestive of CJD	EEG suggestive of CJD	Functional neuroimaging
Huber et al., 2007	1	sCJD	n.a.	no	no	n.a.
Prasad et al., 2007	2	sCJD	positive/borderline	yes/no	no/n.a.	n.a./n.a.
Rowe et al., 2007	1	sCJD ^a	negative	no	no	n.a.
Josephs et al., 2004	2	sCJD	n.a.	no	no	n.a.
Shimamura et al., 2003	1	sCJD	n.a.	yes	n.a.	[¹²³ I]-IMP-SPECT ^b
Zarei et al., 2002	1	sCJD	positive	no	n.a.	SPECT ^c
Bertoni et al., 1983	2	fCJD	n.a.	n.a.	no	n.a.

n.a. = Data not available/not applicable; sCJD = sporadic CJD; fCJD = familial CJD.

^a Novel gene mutation (A133V).

^b Cortical hypoperfusion in SPECT correlating to restricted diffusion in DWI.

^c Normal findings in SPECT (further information not available).

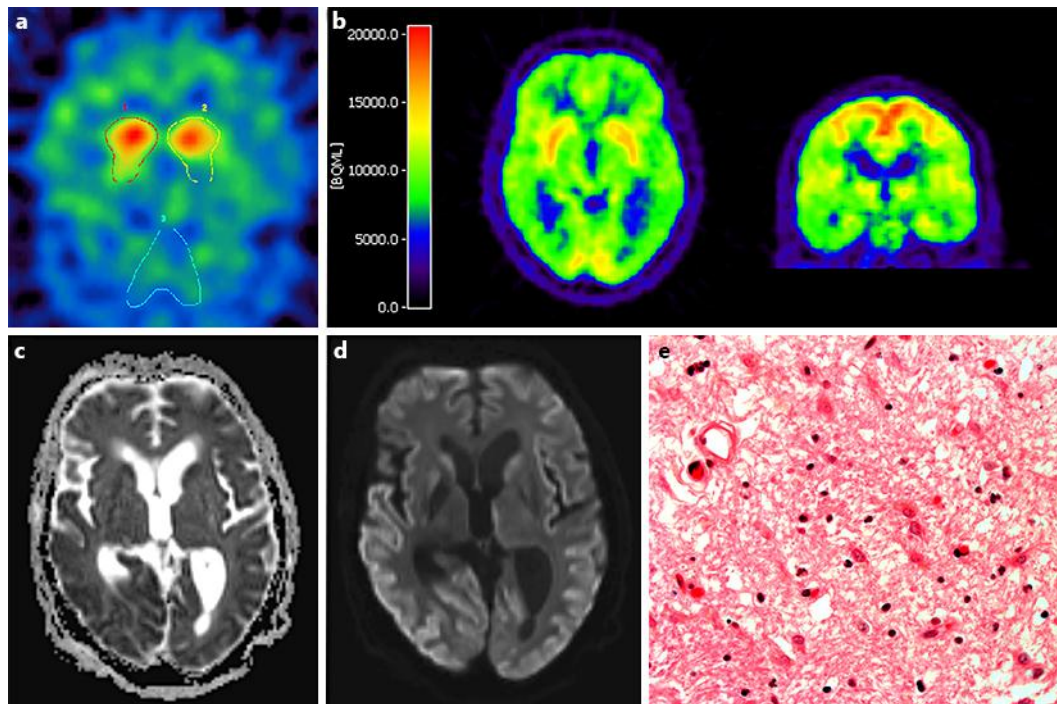


Fig. 1. **a** [^{123}I]-FP-CIT-SPECT. Transaxial view at striatal level with identical regions of interest covering the caudate nucleus and putamen (1 right, 2 left) and occipital reference region (3) showing decreased uptake bilaterally in the posterior putamen and in the left caudate nucleus compared to the right side. The striatal-to-occipital uptake ratio is: 2.24 on the right and 2.02 on the left side. **b** [^{18}F]-FDG-PET. Summed image with transaxial and coronal views on the striatal level revealing widespread cortical hypometabolism in the frontal, temporal, parietal, and occipital lobes bilaterally as well as in striatum and thalami. A small cortical area of preserved uptake in the frontoparietal region can be seen in the coronal view. MR DWI with apparent diffusion coefficient (**c**) and TRACE maps (**d**). Restricted diffusion is noted in the cortical gray matter (especially temporally and occipitally) and in striatum. **e** Histologic sample with HE staining from the right thalamus, showing marked spongiform changes, gliosis, and neuronal loss.