


## CLINICAL ARTICLE

# Application of Laminoplasty Combined with ARCH Plate in the Treatment of Lumbar Intraspinous Tumors

Zhi-Chao Wang, MD, Shu-Zhong Li, PhD, Yuan-Liang Sun, PhD, Chu-Qiang Yin, MD, Yue-Lei Wang, MD, Jie Wang, MD, Chen-Jing Liu, MD, Zhen-Lu Cao, MD, Ting Wang, PhD 

*Department of Spine Surgery, The Affiliated Hospital of Qingdao University, Qingdao, China*

**Objective:** To investigate the bone fusion and clinical effect of laminoplasty combined with ARCH plate fixation in the treatment of lumbar intraspinal tumors.

**Methods:** This was a clinical study. From June 2017 to January 2019, 24 patients (seven males and 17 females, average age  $40 \pm 16$  years) with lumbar intraspinal tumors underwent laminoplasty combined with ARCH plate fixation in our hospital. The bone fusion was evaluated by X-ray and computed tomography (CT) scans that were taken  $15.2 \pm 2.17$  months postoperatively. Each segment showed a bone bridge on one side, which was classified as “segmental partial fusion.” Each segment showed bilateral bone bridges, which were classified as “segmental complete fusion”. When all segments of the patient showed bilateral bone bridging so that the replanted lamina and the host lamina became a unit on the CT scan, it was defined as “complete fusion”. In addition, the operation time and blood loss were recorded. Fisher’s exact test was used to analyze the potential influencing factors of bone healing, including age ( $\leq 40$  years vs  $> 40$  years), gender, number of operated levels (single vs two). Paired *t*-test was used to analyze pre- and postoperative Oswestry Disability Index (ODI) scale and low back and leg pain visual analog scale (VAS).

**Results:** A total of 33 segments of laminoplasty were successfully performed in 24 patients. The average operation time was  $128 \pm 18$  minutes. The average blood loss was  $110 \pm 19$  mL. All patients were followed up at least 12 months after operation (average,  $15.2 \pm 2.17$  months). At the final follow-up, according to the definition of this study, the proportion of “segmental partial fusion” and “segmental complete fusion” were 30.3% (10/33) and 69.7% (23/33), respectively. And the proportion of patients with “complete fusion” was 70.8% (17/24). Age, gender, and number of operated levels were not associated with the fusion ( $P = 1.0, 0.37, \text{ and } 0.06$ , respectively). ODI and VAS were much better at 1 month after operation and the final follow-up than those before the operation ( $P < 0.01$ ). At 6 months after operation, the results of magnetic resonance imaging (MRI) showed that the supraspinous ligament was repaired, and there were no complications, such as spinal epidural scar recompression.

**Conclusions:** Laminoplasty combined with ARCH plate was a better surgical method, and 70.8% of the patients showed complete bone fusion and there was no case of bilateral nonunion.

**Key words:** ARCH plate; Bone fusion; Intradural tumor; Laminoplasty; Lumbar

## Introduction

Intraspinous tumors usually constrict the spinal cord and nerve root, which may lead to severe neurological deficits. For the treatment of intraspinal tumors, the posterior

column structure of the spine is completely removed by classical total laminectomy. Although the compression of the spinal cord by the tumor has been solved, the posterior complex of the spine was seriously damaged. From the

**Address for correspondence:** Ting Wang, PhD, Affiliated Hospital of Qingdao University, Qingdao University, Jiangsu Road, Shinan District, Qingdao, China 266000 Tel: 0-18661809505; Fax: 0532-82911652; Email: wt18661809505@163.com

**Disclosure:** All authors declare that there are no conflicting interests.

Received 2 April 2020; accepted 23 June 2020

biomechanical point of view, lamina, facet joint, supraspinous or interspinous ligament, and ligamentum flavum are important posterior components. The decrease of spinal biomechanical stability often leads to a series of complications such as kyphosis, epidural fibrosis, and iatrogenic spinal canal stenosis<sup>1-3</sup>. The method of total laminectomy and screw-rod system internal fixation makes up for the shortcomings of spinal instability or kyphosis after classical total laminectomy to a certain extent. Zong *et al.*<sup>4</sup> have retrospectively analyzed the surgical results of 122 cases of intraspinal subdural tumors and achieved satisfactory results in reducing spinal instability and deformities in short-term follow-up. However, the range of spinal motion is obviously limited, especially for patients involving multiple segments, which often causes segmental dyskinesia and adjacent segmental degeneration. Meanwhile, there is still a risk of iatrogenic spinal canal stenosis due to the loss of the posterior complex of the spine.

At present, more and more surgeons are aware of the importance of reconstruction of spinal stability and reducing postoperative complications for postoperative recovery and quality of life of patients, and pay great attention to the maintenance of spinal stability during operation. Following the introduction of lamina replantation by Raimondi in 1976<sup>5</sup>, a series of laminoplasty has been developed for intraspinal tumor resection<sup>6-10</sup>. By preserving some or all of the posterior column elements, these techniques restore the stability and integrity of the posterior column structure of spine and significantly reduce the complications of classical total laminectomy. In addition, laminoplasty makes revision surgery much easier and safer than classical total laminectomy, considering that intradural tumors may recur, because laminoplasty retains a relatively normal posterior skeletal structure without epidural scars. Therefore, laminoplasty may be a suitable choice for this kind of patient with intraspinal tumor.

Some scholars have used hemi-laminectomy to treat patients with intraspinal tumors<sup>11-14</sup>. Koch-Wiewrodt *et al.*<sup>15</sup> have performed intraspinal tumor resection with lamina fenestration, by which certain surgical results are achieved. In addition, Csaba *et al.*<sup>16</sup> have reported that para-split laminotomy approach can be used to explore different intramedullary pathologies located in the midline of the spinal canal. Lee *et al.*<sup>8</sup> have reported spinous process-splitting hemi-laminoplasty for intradural and extradural lesions. The common advantages of these procedures include little effect on the extent of laminectomy and the stability of the spine. The original anatomical structure and biomechanical relationship of the spine have been preserved to some extent. As a result, the occurrence of complications, such as kyphosis and cerebrospinal fluid (CSF) leakage, is greatly reduced. However, due to the limitations of exposure range and surgical field of vision, these techniques have great limitations for intramedullary tumors, larger tumors, and tumors closely adhering to the spinal cord and peripheral nerve roots.

Another method of laminoplasty is resection and replantation of spinous process-lamina complex, in which the resected spinous process-lamina complex was replanted at the end of the procedure, allowing a complete reconstruction of the posterior element of the spinal canal. This surgical method makes up for the deficiency of the above operation. It not only provides a broad surgical field of vision for the complete resection of intraspinal tumors, but also restores the structure and function of the spine. The long-term effect of this kind of laminoplasty depends on the stability of replanted spinous process-lamina complex. Stable replanted spinous process-lamina complex facilitates the realization of replanted lamina bony fusion and provides the best insertion point of muscle to withstand the pressure of body movement<sup>17</sup>. At present, there are still some shortcomings in the fixation method of replanted spinous process-lamina complex. The strength of traditional surgical sutures and steel wire is not enough, and it is easy to cause replanted spinous process-lamina complex nonunion, displacement, and collapse. Auxiliary pedicle screw cannot directly fix the replanted spinous process-lamina complex, which leads to the rotation and nonunion of the replanted spinous process-lamina complex. Lamina screw has certain requirements for the diameter of replanted lamina. Because of its strong plasticity, simple installation, and firm fixation, miniature steel plate has been widely used in laminoplasty. In addition, the biomechanical test results showed that the technique of lamina replantation with ARCH plate fixation can improve spinal stability, compressive resistance, anti-bending, anti-shearing, and anti-rotation abilities<sup>18</sup>. This provides favorable conditions for replanting spinous process-lamina complex to achieve bone healing.

Therefore, we have retrospectively reviewed 24 patients with lumbar intraspinal tumors who underwent laminoplasty combined with ARCH plate fixation. The purpose of this study was to investigate: (i) the bone fusion of replanted spinous process-lamina complex; (ii) the potential influencing factors of bone fusion; and (iii) the clinical effect after laminoplasty combined with ARCH plate fixation.

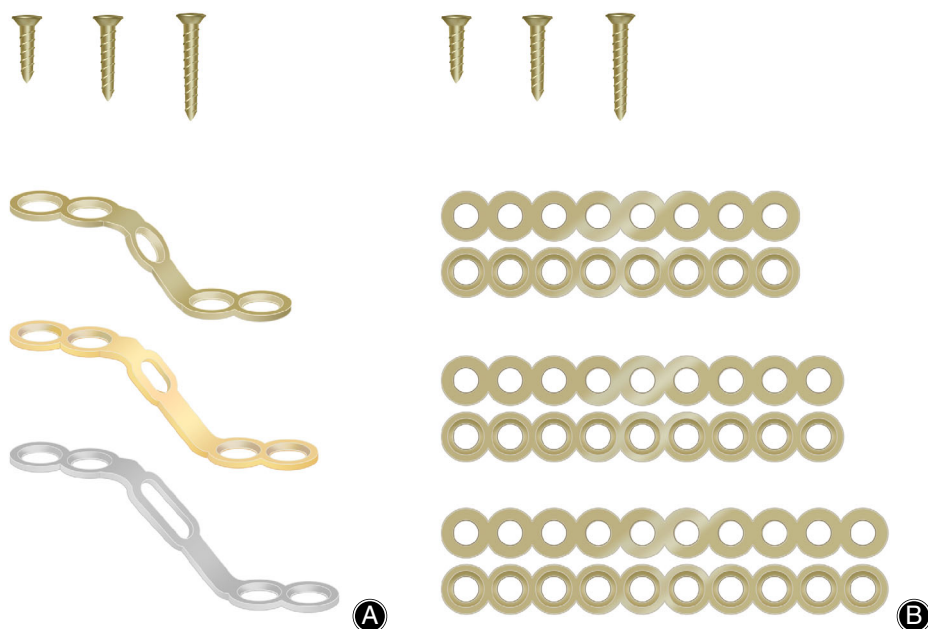
## Materials and Methods

### *Inclusive and Exclusion criteria*

In this study, patients with lumbar intraspinal tumors who underwent laminoplasty combined with ARCH plate internal fixation (Johnson & Johnson Inc. America) (Fig. 1) from June 2017 to January 2019 were collected retrospectively.

Inclusive criteria: (i) all patients with intraspinal tumors underwent operation for the first time; (ii) no spinal structure destruction or spine instability; (iii) clinical and pathological data were complete; and (iv) all patients were followed up for at least 1 year.

Exclusion criteria: (i) facet joint was destroyed; (ii) patient suffered from tumor recurrence; and (iii) lesions lead to spinal destruction and instability.



**Fig. 1** ARCH plates and titanium screws used during operation. A depression on one side of the steel plate hole is beneficial to screw fixation. The smoothness of the other side is beneficial to the close fitting of the replanted lamina.

### Patients Information

Finally, 24 patients (seven males and 17 females) with lumbar intraspinal tumors were included. The mean age of the patients was  $40 \pm 16$  years. All patients were diagnosed by lumbar X-ray plain film, computed tomography (CT), and magnetic resonance imaging (MRI) before operation. After the lesions were found by routine scan, enhanced scanning was performed to clarify the scope and size of the tumor and its relationship with the spinal cord, cauda equina, and nerve root. This study was conducted in accordance with the Declaration of Helsinki, and approved by the Ethics Committee of the Affiliated Hospital of Qingdao University (Qingdao, China). Written informed consent was obtained from all participants.

### Surgical Technique

#### Anesthesia and Position

All patients were administered with general anesthesia through tracheal intubation, and the operation was performed in the prone position.

#### Approach and Exposure

Through a midline posterior approach, the paravertebral muscles were detached from the spinous processes and laminae, preserving the supraspinal and interspinal ligaments (Fig. 2A). Then, minimized laminectomy was performed between the two sides of the spinous process and the inner edge of the facet joint with a grinding drill and 1 mm lamina rongeur. The supraspinal ligament and interspinal ligament of the head and tail segments of the lamina were cut off (Fig. 2B,C). Subsequently, the free spinous process-lamina

complex was removed with tweezers and placed on the worktable outside the operation area (Fig. 2D).

#### Resection of the Tumor

The surgeon made a longitudinal incision at the center of the posterior dura mater under the microscope and pulled it open with silk thread (Fig. 2E,F). Complete separation and resection of the tumor were carried out to decompress the spinal cord. Waterproof suture was used on the dura mater after tumor resection (Fig. 2G).

#### Shaped ARCH Plate

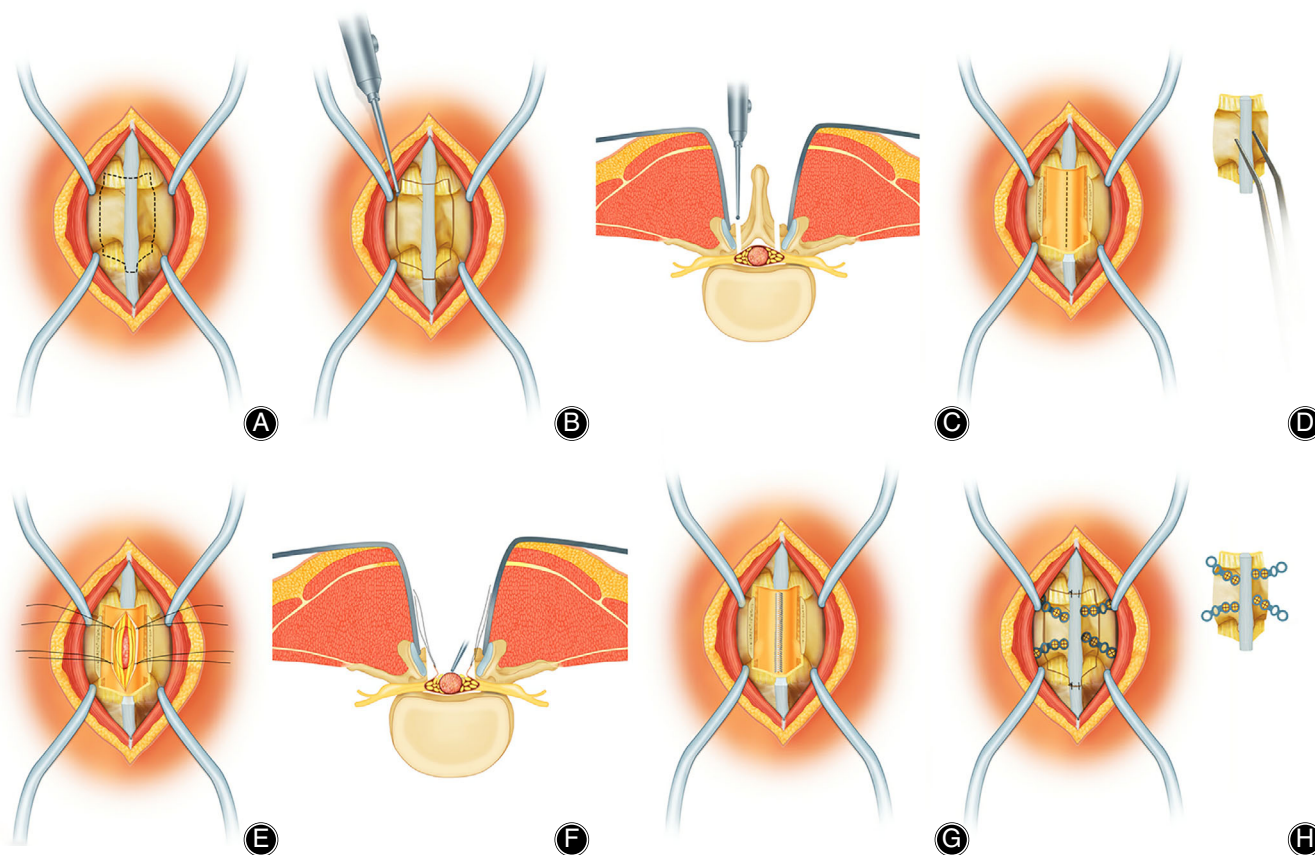
The ARCH plate was molded by an assistant to achieve the best fit with the free spinous process-lamina complex. And the molded ARCH plate was fixed on the spinous process-lamina complex with two screws of 3–5 mm. Four ARCH plates are used in each segment (Fig. 2H).

#### Reconstruction of Posterior Column of Spine

The spinous process-lamina complex with the molded arch plate were anatomically reduced along the cutting line. In a stepwise fashion, the other end of the ARCH plates were secured to the host bone with screws. Finally, the suture line of tendon was used to fix the supraspinal ligament of the head and tail of the lamina to further maintain the replantation of the spinous process-lamina complex *in situ* (Fig. 2H). The tube placement was drained, and the incision was washed and closed at each layer.

#### Postoperative Management

Antibiotics were used prophylactically for 48 hours after operation, and the deterioration of neurological symptoms and drainage were observed. If there was no CSF leakage, the



**Fig. 2** (A) The paraspinous muscles were dissected and separated under the periosteum to expose the spinous process and lamina, while the supra and interspinous ligaments remained intact. (B and C) Minimal laminotomy was performed on the targeted level. (D) The spinous process-lamina complex was removed with tweezers. (E and F) A longitudinal incision was made at the center of the posterior dura mater under a microscope and pulled open with silk thread. Complete separation and resection of the tumor were performed to decompress the spinal cord. (G) Waterproof suture was performed on the dura mater after tumor resection. (H) The spinous process-lamina complex was reduced and fixed with titanium screw and ARCH plate. Moreover, the suture line of tendon was used to fix the supraspinous ligament of the head and tail of the lamina.

patient could pull out the drainage tube at 24 h after the operation. If there was CSF leakage, CSF drainage was controlled within 150–200 mL every day until the drainage was clear. The drainage tube was pulled out, and the wound was pressurized and bandaged. The patient was allowed to get out of bed under the protection of external brace. The external brace was removed at 3 months after the operation.

### Outcome Evaluations

#### Therapeutic Evaluations

All patients were followed up for at least 12 months. Data were recorded, including surgical time, blood loss, type of tumor, and any complications. To determine the level of internal fixation and spinal stability, frontal and lateral X-ray plain films of the spine were performed at 1, 3, 6, 12 months, and annually post-operation. Lumbar CT scans were performed to evaluate the bone growth of the replanted spinous

process-lamina complex at 3, 6, and 12 months postoperatively. At 6 months after the operation, MRI was performed to detect tumor recurrence and scar oppression in the spinal canal, as well as the repair of the ligaments.

#### Oswestry Disability Index (ODI) Scale

The neurological status was evaluated using ODI scale preoperatively and at 1 month post-operation and the final follow-up. The ODI score system includes 10 sections: pain intensity, personal care, lifting, walking, sitting, standing, sleeping, sex life, social life, and traveling. For each section of six statements the total score is 5. If all 10 sections are completed the score is calculated as follows: total scored out of total possible score  $\times 100$ . If one section is missed (or not applicable) the score is calculated: (total score / (5  $\times$  number of questions answered))  $\times 100\%$ . A score of 0%–20% is considered mild dysfunction, 21%–40% is moderate dysfunction,



41%–60% is severe dysfunction, and 61%–80% is considered as disability.

#### *Visual Analog Scale (VAS)*

Low back and leg pain was evaluated using VAS preoperatively, at 1 month post-operation, and at the final follow-up. VAS refers to a ruler about 10 cm long, marked with 10 scales on one side. The two ends of the ruler are “0” and “10,” respectively. A score of “0” indicates no pain, and a score of “10” indicates the most severe pain. Patients were asked to mark the corresponding position on the ruler to represent the degree of their pain as the score. According to the clinical evaluation, “0–2” was classified as “excellent,” “3–5” as “good,” “6–8” as “poor,” and “>8” as “worst.”

#### *Assessment of the Bony Fusion*

The bone fusion was evaluated by postoperative lumbar X-ray plain films and CT. Each segment showed a bone bridge on one side, which was classified as “segmental partial fusion.” Each segment showed bilateral bone bridges, which were classified as “segmental complete fusion.” When all segments of the patient showed bilateral bone bridging so that the replanted lamina and the host lamina became a unit on the CT scan, it was defined as “complete fusion.” The following factors that might affect the bone fusion with regard to the patient were investigated: age ( $\leq 40$  years vs  $> 40$  years), gender, number of operated levels (single vs two).

#### *Statistical Analysis*

The preoperative and postoperative ODI score and VAS were expressed by mean  $\pm$  standard deviation (SD), and the paired *t*-test was used for the analyses. The Fisher exact test was used to analyze factors that might affect the bone fusion. All data was analyzed using the software package SPSS 25.0 (IBM, USA), and  $P < 0.05$  or  $P < 0.01$  were considered statistically significant.

## **Results**

#### *General Results*

In the present study, 24 patients underwent successful operation and demonstrated primary healing. The average operation time was  $128 \pm 18$  minutes. The average blood loss was  $110 \pm 19$  mL. Histological diagnoses were schwannoma in 17 patients, ganglioneuroma in three patients, ependymoma in two patients, meningioma in two patients. All patients were followed up for 12–18 months (average,  $15.2 \pm 2.17$  months). The pain and numbness of all patients were significantly relieved or disappeared after operation. At 6 months after the operation, the results of MRI showed that the supraspinous ligament was repaired, and there was no tumor recurrence or spinal epidural scar recompression. Moreover, at the final follow-up, neither spinal malalignment on the coronal plane nor displacement of bone flap was observed in lumbar X-ray plain films and CT.

#### *Oswestry Disability Index (ODI) Scale*

As shown in Table 1, the mean preoperative ODI score was  $72.5\% \pm 6.1\%$ , while the mean last follow-up ODI score was  $13.2\% \pm 3.4\%$ , with statistically significant differences ( $t = 40.74$ ,  $P < 0.01$ ).

#### *Visual Analog Scale (VAS)*

As shown in Table 1, the mean preoperative VAS was  $6.5 \pm 1.1$ , while the mean last follow-up VAS was  $0.9 \pm 0.7$ , with statistically significant differences ( $t = 22.69$ ,  $P < 0.01$ ).

#### *Result of Bone Fusion*

A total of 33 segments of laminoplasty were successfully performed in 24 patients. There were 15 cases of single segment and nine cases of two segments. At the final follow-up, according to the definition of this study, the proportion of “segmental partial fusion” and “segmental complete fusion” were 30.3% (10 / 33) and 69.7% (23 / 33), respectively. And the proportion of patients with “complete fusion” was 70.8% (17 / 24) including 13 cases of single segment and four cases of two segments. Although it seemed that the proportion of complete fusion of patients was better with single-segment (86.7%, 13/15) than with two-segment (44.4%, 4/9), there was no statistical significance ( $P = 0.06$ ). In addition, age and gender were not associated with the bone fusion ( $P = 1.0$ , 0.37, respectively).

#### *Complications*

Among these participants, no complications were found after the surgery, such as kyphosis, epidural fibrosis, CSF, etc.

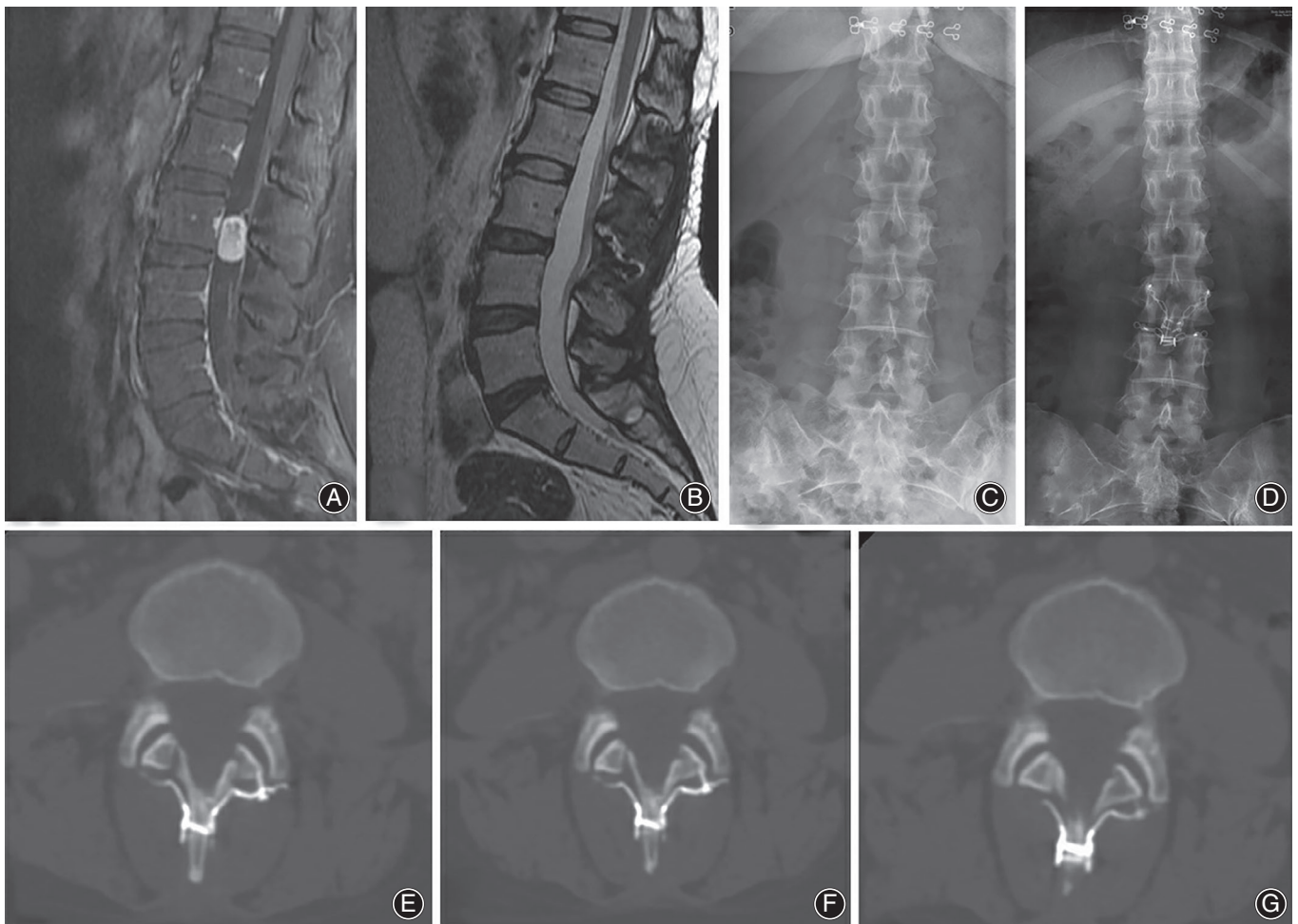
#### *Illustrative Case*

Case 1. A 32-year-old female patient had right lower limb pain and numbness for 1 year, and the above symptoms worsened for half a month. Lumbar MRI showed intraspinal space occupying lesions. Admission for physical examination: The spinous process of lumbar vertebrae had mild tenderness. The sensation of the medial skin of the right leg and foot were decreased. The preoperative VAS score was 6 and ODI was 64%. Laminoplasty combined with ARCH plate internal fixation in the treatment of L<sub>3</sub> level intraspinal tumors. Histological examination of the surgical specimen confirmed the diagnosis of schwannoma. After operation, the right lower limb pain disappeared, the numbness of the right lower limb was obviously relieved. And there were no complications, such as CSF leakage. At 1 month after operation, VAS score was 3 and the ODI was 27%. At 6 months after operation, lumbar MRI showed that the ligaments were repaired and healed, and there was no intraspinal scar adhesions or restenosis. At 12 months after operation, VAS score was 0 and the ODI was 5%. Meanwhile, lower limb function returned to normal, and CT showed that the replanted lamina healed completely (Fig. 3).

TABLE 1 VAS and ODI scores (mean  $\pm$  SD)

Items	Pre-operation	One month after surgery	Final follow-up	Pre-operation vs Final follow-up	
				t	P
VAS	6.5 $\pm$ 1.1	2.2 $\pm$ 0.7	0.9 $\pm$ 0.7*	22.69	<0.001
ODI (%)	72.5 $\pm$ 6.1	26.8 $\pm$ 5.5	13.2 $\pm$ 3.4*	40.74	<0.001

Scores are mean  $\pm$  standard deviation.  
\*P < 0.01 vs. preoperative score.  
VAS, visual analog scale; ODI, Oswestry Disability Index.



**Fig. 3** Clinical imaging from one representative patient (female, 32 years old) more than 12 months after laminoplasty combined with ARCH plate fixation ( $L_3$ ). (A) Preoperative enhanced lumbar MRI showed intraspinal space occupying lesions at  $L_3$  level. (B) Six months after operation, lumbar MRI showed that the ligaments were repaired and healed, and there was no intraspinal scar adhesions or restenosis. (C) Prior to surgery, lumbar X-ray plain film was performed under the upright conditions. (D) One month after operation, the positive X-ray plain film of lumbar showed that the replanted lamina began to heal. (E, F) Three months and 6 months after operation, the lumbar CT cross section showed that the replanted lamina gradually had bony fusion. (G) Twelve months after operation, the replanted lamina was almost completely fused.

## Discussion

### *Significance of Reconstruction of Posterior Column of Spine*

According to the spinal “three-column theory” of Denis<sup>19</sup>, the posterior column is composed of vertebral arch, lamina, spinous process, interspinous ligament, and supraspinous ligament. The posterior column is subjected to 24%-30% pressure and 21%-54% rotational stress. After tumor resection, the replantation of spinous process-lamina complex is beneficial to restore the anatomical structure and function of the spine<sup>18, 20</sup>. This reduced postoperative complications such as kyphosis, epidural fibrosis, and iatrogenic spinal canal stenosis. At the same time, the recovery of ligament-nerve-muscle reflex system of supraspinous ligament and interspinous ligament is helpful to the movement of the lower back<sup>21</sup>. In addition, considering that intradural tumors may recur, the preservation of relatively normal posterior skeletal structure and the absence of epidural scars make revision surgery easier and safer.

### *Comparison of Different Laminoplasty*

The long-term effect of laminoplasty depends on the stability of replanted spinous process-lamina complex. Stable replanted spinous process-lamina complex facilitates the realization of replanted lamina bony fusion and provides the best insertion point of muscle to withstand the pressure of body movement. Among the many factors affecting the stability of replanted spinous process-lamina complex, the fixation instrument has the greatest influence.

For the lack of fixation strength of traditional surgical sutures and steel wire, it is easy to cause “floating spine” phenomenon or iatrogenic spinal canal stenosis due to spinous process-lamina complex displacement and nonunion<sup>22</sup>. In addition, this kind of fixation requires long-term bed rest and postoperative brace protection<sup>23</sup>. The method of pedicle screw is to combine the titanium rod or connecting rod transversely through the spinous process with bilateral pedicle screws. The replanted lamina cannot be fixed directly, which leads to the rotation and instability of replanted spinous process-lamina complex. Especially for patients involving multiple segments, the operation is complex and the fusion rate is not high. Yang *et al.*<sup>17</sup> have reported that the bone fusion rate was 67.5% in 40 patients who underwent laminoplasty with lamina screws. However, facet joint destruction was observed in more than five patients. In addition, there are some limitations for patients whose lamina diameter is smaller than that of lamina screws or when lamina is eroded. Miniature plate and screw fixation of lamina are widely used in laminoplasty. Zhou *et al.*<sup>18</sup> have reported that 13 patients with thoracolumbar tumors are treated with replantation of vertebral lamina ARCH plate internal fixation technique, and the postoperative effect is good. Meanwhile, the biomechanical test results show that this technique can improve spinal stability and compressive abilities<sup>18</sup>. This provides favorable conditions for replanting spinous process-

lamina complex to achieve bone healing. In addition, the technique of ARCH plate fixation in this study allowed for smaller surgical incisions and laminectomy, which can retain part of the lamina that protects the spinal cord. It was beneficial to the recovery of spinal stability. At the same time, we speculated that the smaller laminectomy was also one of the reasons why there are no complications in all patients, such as screw loosening, lamina displacement, or collapse.

### *Assessment of the Bony Fusion*

We analyzed the healing of replanted spinous process-lamina complex in patients who had been followed up for more than 12 months. According to the definition of this study, the proportion of “segmental partial fusion” and “segmental complete fusion” were 30.3% and 69.7%, respectively. And the proportion of patients with “complete fusion” was 70.8%. Although seven patients (two cases of single segment and five cases of two segments) did not achieve “complete fusion,” at least one side of the bone healed. And none of the patients had bilateral nonunion. Unilateral fusion may be caused by a bone defect between the incision lines of the lamina. Complete fusion of each segment is undoubtedly the ideal goal of laminoplasty. It can be expected that more patients will achieve complete bone fusion with such tools as a T-SAW<sup>24</sup>. However, for patients with narrow spinal canal caused by thickening of ligamentum flavum or large tumor volume, there is some difficulty and risk of nerve injury in removing lamina with T-saw<sup>9</sup>. In these cases, it is necessary to use a drill bit to thin the lamina and drill it carefully. In addition, we analyzed the potential influencing factors of bone healing, including age ( $\leq 40$  years *vs*  $> 40$  years), sex, and number of operated levels (single *vs* two). Although there was no statistical significance ( $P = 1.0, 0.37, 0.06$  respectively), we found that the complete fusion of single segment seems to be more likely to occur than that of two segments. We speculated that the good healing of a single segment had something to do with the smaller extent of resection of spinous process-lamina complex and the shorter operation time. This needs to be further proved in more patients.

### *Limitation*

This study had several limitations. First of all, this study was mainly for patients with single or two segments, but there was a lack of research on patients with more than two segments. Second, we did not evaluate patients with continuous CT scans. In order to verify the bone fusion, a series of CT scans should be performed on all patients. Therefore, this study had limitations in determining the bone fusion over time. In order to accurately assess the bone fusion over time, forward-looking design is necessary. After that, this study could not provide a direct comparison of ARCH plate with other fixation methods of laminoplasty, because this was a single cohort study. A comparative study or randomized controlled trial was needed to discuss the advantages or disadvantages of ARCH plates over other procedures. However,

the technique of lamina replantation with ARCH plate fixation can improve spinal stability, compressive resistance, anti-bending, anti-shearing, and anti-rotation abilities. It was beneficial to replanted lamina to achieve bone fusion.

### Conclusion

A total of 70.8% of the patients showed complete bone fusion, and there was no case of bilateral nonunion. There

was no displacement of bone graft lamina in all patients. It was a valuable alternative to laminectomy, especially for patients with single segment.

### Acknowledgments

None.

### Reference

1. Millward CP, Bhagawati D, Chan HW, Bestwick J, Brecknell JE. Retrospective observational comparative study of Hemilaminectomy versus laminectomy for intraspinal tumour resection; shorter stays, lower analgesic usage and less kyphotic deformity. *Br J Neurosurg*, 2015, 29: 390–395.
2. Lee SM, Cho YE, Kwon YM. Neurological outcome after surgical treatment of intramedullary spinal cord tumors. *Korean J Spine*, 2014, 11: 121–126.
3. McGirt MJ, Garces-Ambrossi GL, Parker SL, et al. Short-term progressive spinal deformity following laminoplasty versus laminectomy for resection of intradural spinal tumors: analysis of 238 patients. *Neurosurgery*, 2010, 66: 1005–1012.
4. Zong S, Zeng G, Du L, Fang Y, Gao T, Zhao J. Treatment results in the different surgery of intradural extramedullary tumor of 122 cases. *PLoS One*, 2014, 9: e111495.
5. Raimondi AJ, Gutierrez FA, Di Rocco C. Laminotomy and total reconstruction of the posterior spinal arch for spinal canal surgery in childhood. *J Neurosurg*, 1976, 45: 555–560.
6. Montano N, Trevisi G, Cioni B, et al. The role of laminoplasty in preventing spinal deformity in adult patients submitted to resection of an intradural spinal tumor. Case series and literature review. *Clin Neurol Neurosurg*, 2014, 125: 69–74.
7. Oral S, Tumturk A, Kucuk A, Menku A. Cervical Hemilaminoplasty with Miniplates in long segment Intradural extramedullary Ependymoma: case report and technical note. *Turk Neurosurg*, 2018, 28: 158–163.
8. Lee YS, Kim YB, Park SW. Spinous process-splitting Hemilaminoplasty for Intradural and extradural lesions. *J Korean Neurosurg Soc*, 2015, 58: 494–498.
9. Park YJ, Kim SK, Seo HY. Ligament-saving Laminoplasty for Intraspinous tumor excision: a technical note. *World Neurosurg*, 2019, 128: 438–443.
10. Song ZJ, Zhang Z, Ye YJ, Zheng JZ, Wang FD. Efficacy analysis of two surgical treatments for thoracic and lumbar intraspinal tumours. *BMC Surg*, 2019, 19: 131.
11. Naganawa T, Miyamoto K, Hosoe H, Suzuki N, Shimizu K. Hemilaminectomy for removal of extramedullary or extradural spinal cord tumors: medium to long-term clinical outcomes. *Yonsei Med J*, 2011, 52: 121–129.
12. Mohindra S, Savardekar A. Unilateral hemilaminectomy: the surgical approach of choice for juxta-medullary spinal tumors. *Neurol India*, 2015, 63: 230–236.
13. Mobbs RJ, Maharaj MM, Phan K, Rao PJ. Unilateral Hemilaminectomy for Intradural lesions. *Orthop Surg*, 2015, 7: 244–249.
14. Pompili A, Caroli F, Crispo F, et al. Unilateral laminectomy approach for the removal of spinal Meningiomas and schwannomas: impact on pain, spinal stability, and neurologic results. *World Neurosurg*, 2016, 85: 282–291.
15. Koch-Wiewrodt D, Wagner W, Pernecky A. Unilateral multilevel interlaminar fenestration instead of laminectomy or hemilaminectomy: an alternative surgical approach to intraspinal space-occupying lesions. Technical note. *J Neurosurg Spine*, 2007, 6: 485–492.
16. Padanyi C, Vajda J, Banczerowski P. Para-split laminotomy: a rescue technique for split laminotomy approach in exploring intramedullary midline located pathologies. *J Neurol Surg A Cent Eur Neurosurg*, 2014, 75: 310–316.
17. Yang SH, Kim CH, Chung CK, Park SB, Sohn S, Lee S. Bone fusion rate in the thoracic and lumbar spine after laminoplasty with laminar screws. *Spine (Phila Pa 1976)*, 2014, 39: E1325–E1330.
18. Zhou D, Nong LM, Gao GM, Jiang YQ, Xu NW. Application of lamina replantation with ARCH plate fixation in thoracic and lumbar intraspinal tumors. *Exp Ther Med*, 2013, 6: 596–600.
19. Denis F. The three column spine and its significance in the classification of acute thoracolumbar spinal injuries. *Spine (Phila Pa 1976)*, 1983, 8: 817–831.
20. Samartzis D, Gillis CC, Shih P, O'Toole JE, Fessler RG. Intradural spinal cord tumors: part II-management options and outcomes. *Global Spine J*, 2016, 6: 176–185.
21. Jiang H, Russell G, Raso VJ, Moreau MJ, Hill DL, Bagnall KM. The nature and distribution of the innervation of human supraspinal and interspinal ligaments. *Spine (Phila Pa 1976)*, 1995, 20: 869–876.
22. Liu XY, Zheng YP, Li JM. Laminoplasty for the treatment of extramedullary intradural tumors in the thoracic and lumbar spine: greater than two-year follow-up. *Orthop Surg*, 2009, 1: 275–279.
23. Hara M, Takayasu M, Takagi T, Yoshida J. En bloc laminoplasty performed with threadwire saw. *Neurosurgery*, 2001, 48: 235–239.
24. Miyakoshi N, Hongo M, Kasukawa Y, Shimada Y. En-bloc resection of thoracic calcified meningioma with inner dural layer in recapping T-saw laminoplasty: a case report. *BMC Surg*, 2015, 15: 82.