

This article is licensed under the Creative Commons Attribution-NonCommercial 4.0 International License (CC BY-NC) (<http://www.karger.com/Services/OpenAccessLicense>). Usage and distribution for commercial purposes requires written permission.

Case Report

# Resolution of Refractory Corneal Neovascularization with Subconjunctival Bevacizumab

Anna Krystyna Britton · Basil Bamford Crayford

Eye Surgery Associates, Orange, NSW, Australia

## Keywords

Corneal neovascularization · Bevacizumab · Anti-vascular endothelial growth factor

## Abstract

Corneal neovascularization (CNV) has a variety of causes and threatens corneal clarity, thus optimal visual acuity. Conventional medical management includes topical steroids and matrix metalloproteinase inhibitors like doxycycline. Anti-vascular endothelial growth factor (anti-VEGF) agents have demonstrated promise but remain off-label for this indication. However, these agents hold value in cases refractory to first-line medical management. We report the case of a 63-year-old woman who presented with ocular rosacea and CNV affecting vision, on a background of acne rosacea. She was initially treated with fluorometholone and doxycycline, yet continued to deteriorate. Eventually she received two 1.5-mg subconjunctival injections of bevacizumab 2 months apart. CNV completely resolved and results were maintained at 4-year follow-up. This case demonstrates that refractory CNV can be effectively treated with subconjunctival injection of anti-VEGF bevacizumab. The resolution of CNV was also maintained years after injection with minimal adjunctive therapy during this period, and to our knowledge there are no other studies reporting a follow-up period of 4 years after treatment. This is a pertinent case for other clinicians treating patients in a similar situation.

© 2020 The Author(s)  
Published by S. Karger AG, Basel

## Introduction

Corneal neovascularization (CNV) involves the ingrowth of new blood vessels from the limbus into the avascular cornea [1–3]. These new vessels disrupt corneal clarity, which threatens vision [3]. CNV can be secondary to inflammation or hypoxia and has a wide differential, including ocular rosacea, contact lens overwear, chemical burns, autoimmune conditions (including graft rejection), bacterial (chlamydial, staphylococcal) and viral (herpes simplex and zoster) infections [1, 3, 4].

Medical management includes topical steroids or nonsteroidal anti-inflammatory drugs, anti-vascular endothelial growth factor (anti-VEGF) agents, and matrix metalloproteinase inhibitors (e.g., doxycycline) [1–3]. The anti-VEGF bevacizumab for CNV has consistently demonstrated improvement in both animal and human studies [2, 5–9], but it remains off-label and long-term data are lacking [1]. In the reports available, the effects of bevacizumab for CNV seem to be short-lived [10, 11]. We report a case of CNV which was resistant to other forms of medical management, yet was successfully treated with subconjunctival bevacizumab and also maintained years after injection.

## Case Report

A 63-year-old woman was referred for ophthalmic review of blurred vision and found to have ocular pannus and rosacea. Her medical history was positive for acne rosacea, previously treated with doxycycline and tobramycin. Other past medical history included hyperthyroidism; family history was unknown.

Her visual acuity (VA) was 6/12-2 in the right eye and 6/12 in the left eye. Intraocular pressure was 8 and 9 mm Hg, respectively. There was CNV bilaterally, up to the edge of the pupil on the left and 50% encroaching on the pupil on the right. Conjunctiva, anterior chamber, and iris examination was normal. Examination of the lens revealed a 2+ nuclear sclerosis cataract bilaterally. A diagnosis of CNV secondary to ocular rosacea was made and the patient was commenced on fluorometholone drops twice daily and 100 mg oral doxycycline daily for 3 months.

Over the following year and a half, the patient was reviewed at 3- to 5-monthly intervals. She had poor compliance for fluorometholone as she felt it caused irritation. Corneal examination revealed scarring in an inferotemporal distribution bilaterally, with stromal vessels on the right and ghost vessels on the left. She was also found to have blepharitis and was recommended warm compresses to lids daily. Across this time period dexamethasone drops were trialed in place of fluorometholone. She was continued on oral doxycycline 50 mg daily and lubricant drops. At each follow-up corneal examination was worsening with increased vessels bilaterally (Fig. 1a). VA worsened to 6/18 bilaterally, then to 6/36 for the right eye at one review and the patient was interested in an alternative to the current medications.

Almost 2 years after initial presentation, the patient was given 1.5 mg of subconjunctival bevacizumab to both eyes. At 1-month follow-up, VA was 6/9-3 on the right and 6/12 with pinhole on the left. Review of the conjunctiva revealed decreased injection and a reduction in inferior temporal stromal vessels (Fig. 1b). A month later, the patient received a further 1.5 mg subconjunctival bevacizumab bilaterally. She was prescribed 3 months of further dexamethasone and 6 months of further fluorometholone, ocular lubricant drops, and doxycycline. She did not present for her scheduled follow-up review as planned and was not seen

until referred by her general practitioner for follow-up in 2020, 4 years following the last injection. During this time, the patient admitted ceasing doxycycline tablets, and it is unclear whether she continued on the dexamethasone or fluorometholone drops. Her general practitioner did not prescribe any more of these medications, so at best she had a limited supply of each of these.

At the review 4 years following the last bevacizumab injection, corneal examination revealed a maintained reduction in stromal and ghost vessels bilaterally (Fig. 1c). The patient was no longer continuing any ocular medication besides ocular lubricant drops as needed. VA was 6/12 bilaterally, improving to 6/9 on the right with a pinhole.

## Discussion

CNV is vision-threatening and thus rapid, effective, and long-lasting treatment is required [3]. Here we report the case of a 63-year-old woman with CNV resistant to conventional forms of management, which was affecting both vision and quality of life. She was effectively treated with subconjunctival bevacizumab and resolution of CNV was maintained. Our case not only demonstrates successful resolution of CNV with bevacizumab, but is unique in the time period in which treatment was commenced and the long-term follow-up of the case.

In our case bevacizumab injections were commenced a few years after initial presentation, yet were still effective in reducing CNV. This is in contrast to multiple papers which suggest that commencing anti-VEGF treatment later in the disease course has minimal effect on reduction of neovascularization and that neovascularization can recur [2, 11, 12]. The success of treatment with bevacizumab has been linked with blood vessel maturity stage, suggesting that bevacizumab is much more effective against new, active vessels compared to mature ones [3]. In our case, despite the chronicity, it is likely that there were ongoing proangiogenic factors (namely VEGF) stimulating vessel formation in the cornea, which made it susceptible to bevacizumab when given.

Despite the abundance of literature on the effectiveness of bevacizumab for CNV [2, 5–9], there is a lack of long-term studies in humans. A case series evaluating subconjunctival bevacizumab in 12 eyes with CNV due to various causes had a follow-up period of only 3 months [10]. In this study, researchers found that recession of corneal vessels was not maintained after 1 month [10]. The first randomized controlled trial demonstrating a significant reduction in CNV with subconjunctival bevacizumab compared to controls also had a follow-up period of only 3 months [2].

Contrary to what may have been expected given the literature, reduction of CNV was maintained at a follow-up of 4 years after the last injection in our case. This is perhaps partly related to some ongoing adjunctive treatment of ocular rosacea in this case, but the subconjunctival bevacizumab proved crucial in inducing regression of neovascularization where conventional medical management alone had proved ineffective. During the 4-year period following the last bevacizumab injection, this patient may have continued on steroid drops for up to 9 months at best and admitted to ceasing doxycycline entirely. Given minimal adjunctive ocular medication during the 4-year period, this emphasizes the role of bevacizumab in the successful treatment of refractory CNV in this case.

Since bevacizumab for CNV remains off-label, further studies with adequate power are required to provide clinical guidelines on dosage, number of injections, and timings between them [2]. We used a total of two subconjunctival injections of 1.5 mg bevacizumab for each

eye 2 months apart, but numerous studies used a 2.5-mg dose [2, 10, 11]. In our case the subconjunctival injections were well tolerated with no adverse effects, but there have been reports of corneal epithelial defects and subconjunctival hemorrhages following injection [2]. Given these inconsistencies, more long-term studies of subconjunctival bevacizumab in humans are required, and Petsoglou et al. [2] suggest that a sample size of 40 patients would be required to confirm the effect.

## Conclusion

We present a case of refractory and progressive CNV which was safely and effectively treated by subconjunctival bevacizumab. Contrary to much of the existing literature, these results were maintained years after the last injection, and so this case remains pertinent for clinicians treating patients in a similar situation. However, further prospective trials are clearly required to consolidate guidelines around dosage and regime of anti-VEGF for CNV.

## Acknowledgments

The authors would like to thank the patient for her consent for publication of this report and images.

## Statement of Ethics

No formal ethics approval was sought, however the risks of off-label use of subconjunctival bevacizumab were explained to the patient and she agreed to its use in this setting. Written informed patient consent was obtained for publication of this report and images.

## Conflict of Interest Statement

The authors have no conflicts of interest to declare.

## Funding Sources

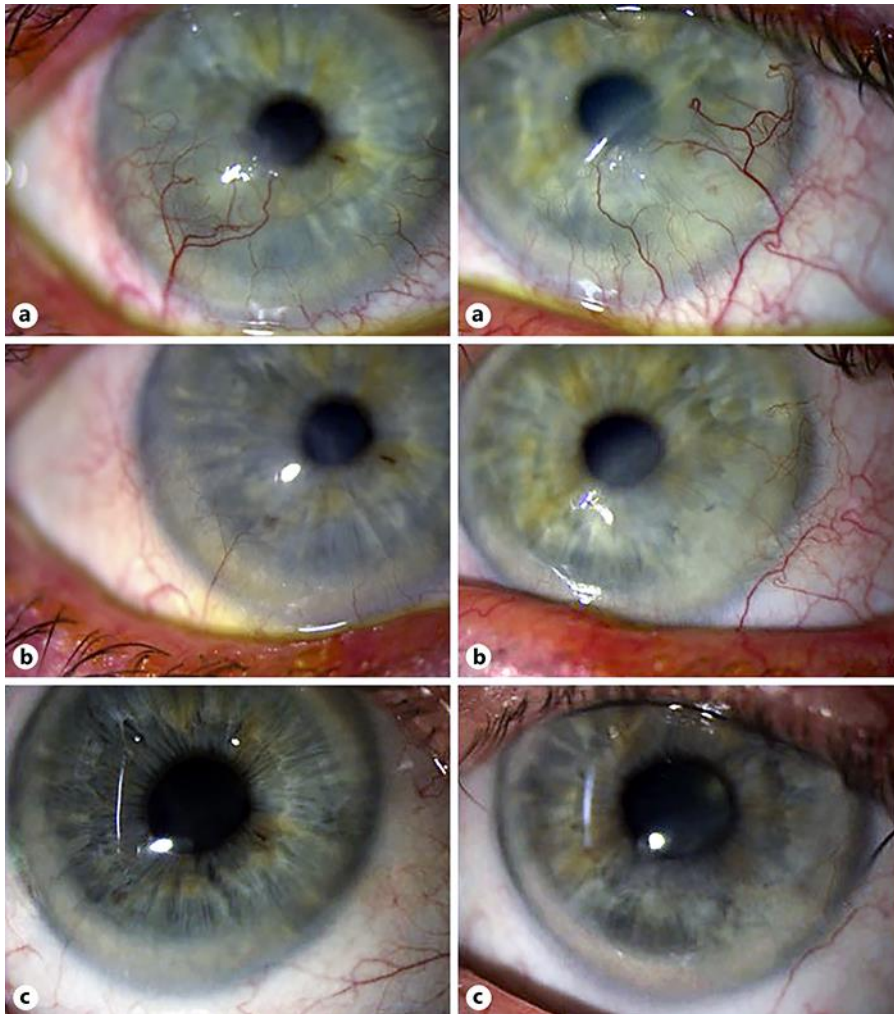
No funding or grant support was received for this paper.

## Author Contributions

A.K. Britton sought patient consent, collected background information, and wrote the manuscript. B.B. Crayford managed the patient, reported the case, provided clinical advice, and edited the manuscript. Both authors read and approved the final manuscript.

## References

- 1 Chiang H, Hemmati HD. Treatment of corneal neovascularization. *EyeNet Magazine*. 2013. [www.aao.org/eyenet/article/treatment-of-corneal-neovascularization](http://www.aao.org/eyenet/article/treatment-of-corneal-neovascularization).
- 2 Petsoglou C, Balaggan KS, Dart JK, Bunce C, Xing W, Ali RR, et al. Subconjunctival bevacizumab induces regression of corneal neovascularisation: a pilot randomised placebo-controlled double-masked trial. *Br J Ophthalmol*. 2013 Jan;97(1):28–32.
- 3 Sharif Z, Sharif W. Corneal neovascularization: updates on pathophysiology, investigations & management. *Rom J Ophthalmol*. 2019 Jan–Mar;63(1):15–22.
- 4 Bagheri N, Wajda BN, editors. *Wills eye manual: office and emergency rood diagnosis and treatment of eye disease*, 7th ed. Kluwer; 2017.
- 5 Papatthanassiou M, Theodoropoulou S, Analitis A, Tzonou A, Theodossiadis PG. Vascular endothelial growth factor inhibitors for treatment of corneal neovascularization: a meta-analysis. *Cornea*. 2013 Apr;32(4):435–44.
- 6 Krizova D, Vokrojova M, Liehneova K, Studeny P. Treatment of Corneal Neovascularization Using Anti-VEGF Bevacizumab. *J Ophthalmol*. 2014;2014:178132.
- 7 Kim WJ, Jeong HO, Chung SK. The effect of bevacizumab on corneal neovascularization in rabbits. *Korean J Ophthalmol*. 2010 Aug;24(4):230–6.
- 8 Kasiri A, Mirdehghan MS, Farrahi F, Ostadian F, Fegghi M, Ghomi MR, et al. Prevention of Corneal Neovascularization; a Preliminary Experimental Study in Rabbits. *Med Hypothesis Discov Innov Ophthalmol*. 2020;9(1):47–55.
- 9 Lopes GJ, Casella AM, Oguido AP, Matsuo T. Effects of topical and subconjunctival use of bevacizumab on corneal neovascularization in rabbits' eyes. *Arq Bras Oftalmol*. 2017 Jul–Aug;80(4):252–6.
- 10 Benayoun Y, Adenis JP, Casse G, Forte R, Robert PY. Effects of subconjunctival bevacizumab on corneal neovascularization: results of a prospective study. *Cornea*. 2012 Aug;31(8):937–44.
- 11 Awadein A. Subconjunctival bevacizumab for vascularized rejected corneal grafts. *J Cataract Refract Surg*. 2007 Nov;33(11):1991–3.
- 12 Lin CT, Hu FR, Kuo KT, Chen YM, Chu HS, Lin YH, et al. The different effects of early and late bevacizumab (Avastin) injection on inhibiting corneal neovascularization and conjunctivalization in rabbit limbal insufficiency. *Invest Ophthalmol Vis Sci*. 2010 Dec;51(12):6277–85.



**Fig. 1.** Corneal photographs of the right and left eye. **a** Taken in July 2015, prior to bevacizumab injections. **b** Taken in May 2016, 1 month following the first bevacizumab injections. **c** Taken in February 2020, almost 4 years after the last bevacizumab injections.