



Contents lists available at ScienceDirect

International Journal of Surgery Case Reports

journal homepage: www.casereports.com

Transplantation of a horseshoe kidney from a living donor: Case report, long term outcome and donor safety



Jaime Manuel Justo-Janeiro^{a,b,*}, Eduardo Prado Orozco^a,
Francisco J. Roberto Enríquez Reyes^a, René de la Rosa Paredes^a,
Luis G. Vázquez de Lara Cisneros^c, Alfonso Lozano Espinosa^c, Jesús Mier Naylor^d

^a Department of Surgery, Angeles Hospital of Puebla, 2143 Kepler Street, Atlixcáyotl, Puebla 72190, Puebla, Mexico

^b Faculty of Medicine, Autonomous University of Puebla, 2902 South 13th Street, Volcanes, Puebla, Puebla, Mexico

^c Department of Anesthesia, Angeles Hospital of Puebla, 2143 Kepler Street, Atlixcáyotl, Puebla 72190, Puebla, Mexico

^d Department of Nephrology, Angeles Hospital of Puebla, 2143 Kepler Street, Atlixcáyotl, Puebla 72190, Puebla, Mexico

ARTICLE INFO

Article history:

Received 25 June 2015

Accepted 5 August 2015

Available online 12 August 2015

Keywords:

Horseshoe kidney
Renal transplantation
Kidney abnormalities
Kidney surgery

ABSTRACT

INTRODUCTION: The use of a horseshoe kidney in renal transplant remains controversial, when it is found in the evaluation of a living donor, anatomical, surgical and ethical issues are involved.

PRESENTATION OF CASE: An uncomplicated horseshoe kidney was detected in a 51-year-old woman who was the only suitable donor for her 30-year-old son. Kidneys were fused in the inferior pole and no vascular or urinary abnormalities were detected during imaging evaluation. The surgical procedure was approved by the hospital transplant committee. A laparotomy was performed by means of a medial upper incision. The isthmus of the kidney was divided using a harmonic scalpel and the left segment was used; it had 2 arteries too distant to create a common one, thus anastomosed separately. The renal vein was side-to-side anastomosed to the right external iliac vein and a Lich-Gregoir ureteral implant was made. There were no intraoperative or postoperative complications in the donor who currently remains asymptomatic. Recipient developed a delayed graft function (DGF), and was discharged on the 12th day after surgery. After 24 months of surgery, renal function has remained stable with a serum creatinine of 128 $\mu\text{mol/L}$ (1.45 mg/dL).

DISCUSSION: There are 7 reports of a horseshoe kidney from living donors in 8 patients without morbidity and a good long term outcome of all recipients.

CONCLUSION: If we anticipate a low operative risk and there is a suitable anatomy, we may consider the use of horseshoe kidneys from living donors a viable alternative.

© 2015 The Authors. Published by Elsevier Ltd. on behalf of Surgical Associates Ltd. This is an open access article under the CC BY-NC-ND license (<http://creativecommons.org/licenses/by-nc-nd/4.0/>).

1. Introduction

Horseshoe kidney is the most common urinary congenital abnormality. When it is found at the time of operation in a deceased donor, it can be divided and transplanted into two different recipients or as a unit in a single receptor; depending on the vascular and urinary anatomy [1,2]. When found during the preoperative work up of a living donor, its use is controversial. There are previous reports in which 8 living donors were used without morbidity or mortality and with good long term results in the recipients (Table 1) [2–8]. This report describes the case of a successful transplantation of a horseshoe kidney from a living donor; and emphasizes the fact that the decision must be made once the absence of abnormalities

that may increase the risk in the surgical donor is established. To our knowledge this is the 9th case reported worldwide.

2. Presentation of case

A 51 year old woman was considered as a kidney donor to her 30 year-old son. Recipient was transplanted 11 years before with his father's right kidney and implanted in the left side of the lower abdomen. After 10 years of adequate renal function, he developed chronic rejection and returned to hemodialysis. A new transplant was proposed and the mother was found to be the only available donor. Mother's preoperative study protocol was uneventful, except for the finding in the renal artery resonance of a horseshoe kidney with fused lower poles and no major vascular or urological abnormalities (Fig. 1). The case was presented to the hospital transplant committee and surgery was authorized.

A medial upper abdominal incision was made in order to approach the left segment of the kidney mobilizing the left colon

* Corresponding author at: Calle Kepler 2143, Office 940, R.T Atlixcáyotl, Puebla, Puebla, CP 72190, Mexico.

E-mail address: jaime_justo@icloud.com (J.M. Justo-Janeiro).

Table 1
Living donor horseshoe kidneys transplants.

Author/Reference	Year	Transplants	Donor/age	Follow up	Surgical approach/ Segment used	Complications
Aikawa [3]	1998	1	Father/55	20 months	Medium T.P./Left	Urine leakage
Inoue [4]	2000	1	Father/55	54 monthss	Medium T. P./Left	Urine leakage
Goyal [5]	2003	2	Sister/47Mother/55	Case 1: 18 months Case 2: 12 months	Rigth flank/Rigth Left flank/Left	No Urine leakage
Hüser [6]	2005	1	Parent/59	16 months	N.R./Rigth	No
Dinckan [7]	2007	1	Sister/42	30 months	Left flank/Left	No
Sezer [2]	2013	1	Sister/43	8 months	Left flank/Left	Ureteral obstruction
Kumar [8]	2015	1	Wife/44	N. R.	Left flank/Left	N. R.
Justo-Janeiro	2015	1	Mother/51	24 months	Medium T. P./Left	No

T.P.: Trans peritoneal
N.R.: Not reported

until the isthmus was exposed (Fig. 2). A left renal artery was found and occluded temporarily in order to reveal the limit with the right segment of the kidney. This was not achieved because another inferior artery was found. No other vascular abnormalities were encountered and the only urological abnormality present was an anterior renal pelvis.

Separation was made through the ischemic line with a harmonic scalpel, left nephrectomy ended with negligible bleeding, transected surface of the remaining kidney was sutured using an oxidized cellulose matrix (Surgice1™, Johnson & Johnson, Pisacatay, New Jersey, USA) and a soft drainage was left in the operating area which was retired at the third post-operative day.

Excised kidney was perfused with a histidine-tryptophan solution (Custodio1™ HTK, Dr. Franz Köhler Chemie GmbH, Bensheim, Deutschland) and was implanted in the right iliac fossa, with an end-to-side anastomosis of the renal vein to the external iliac vein.

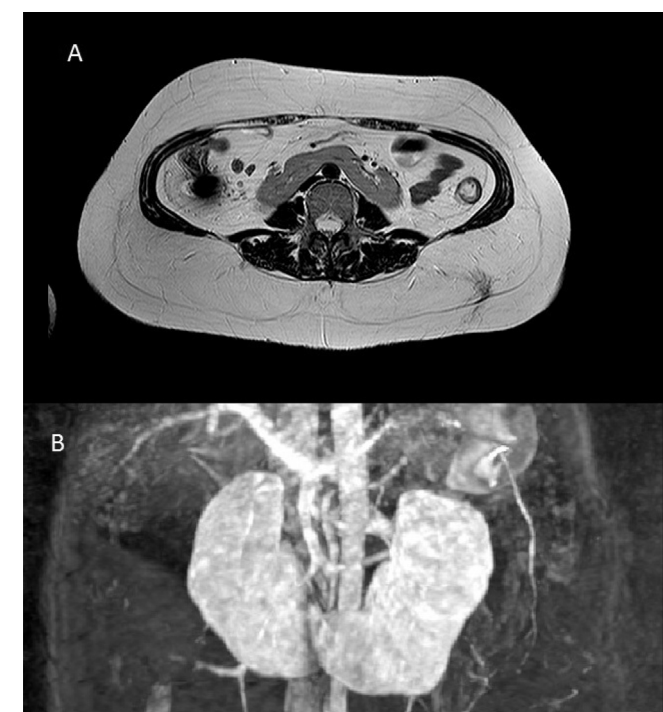


Fig. 1. Magnetic resonance images, axial view (A) and coronal view (B).

The two arteries were too distant to make a common one (Fig. 3), thus the superior artery was anastomosed end-to-end to internal iliac artery and inferior end-to-side to the external iliac artery; transected edge was left with no further treatment or suture (Fig. 4). The ureter was implanted with the Lich-Gregoir technique and a “double J” catheter was left inside, total ischemic time was 125 min.

Immunosuppression was carried in the standard way, induced with 20 mg IV basiliximab on days 0 and 4, oral mycophenolate 1 g twice a day. An intravenous infusion of methylprednisolone was begun for the first 3 post-operative days, followed by oral prednisone at 2 mg/kg/day and tapered it until a target dose of 0.2 mg/kg/day; oral cyclosporine was begun at 3 mg/kg/day when a serum creatinine below 176 μmol/L (1.99 mg/dL) was reached, which was achieved at the 20th P.O. day.

Donor evolution was uneventful and was discharged at the fifth postoperative day; protocol laboratories 24 months after the nephrectomy remain normal.

Recipient developed a DGF and the laboratory tests showed acute tubular necrosis with good arterial perfusion demonstrated in Doppler ultrasonography (Fig. 5) and scintigraphy (Fig. 6) showing isotope’s concentration without elimination. Patient began diuresis at the 8th postoperative day and a progressively achieved normal renal function. After 3 months of surgery renal function stabilized, and at the end of the first year serum creatinine was found to be

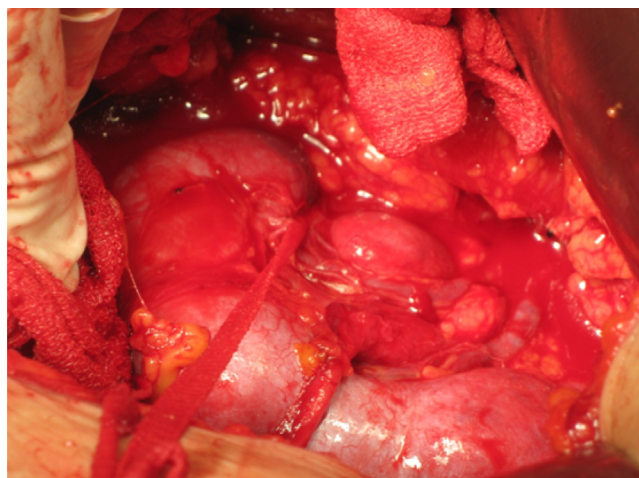


Fig. 2. Isthmus of the horseshoe kidney in situ.

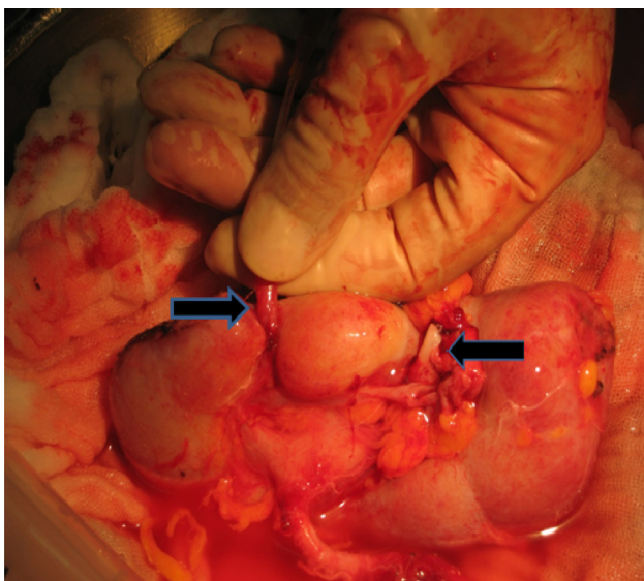


Fig. 3. Black arrows show both renal arteries too far to make a common one.

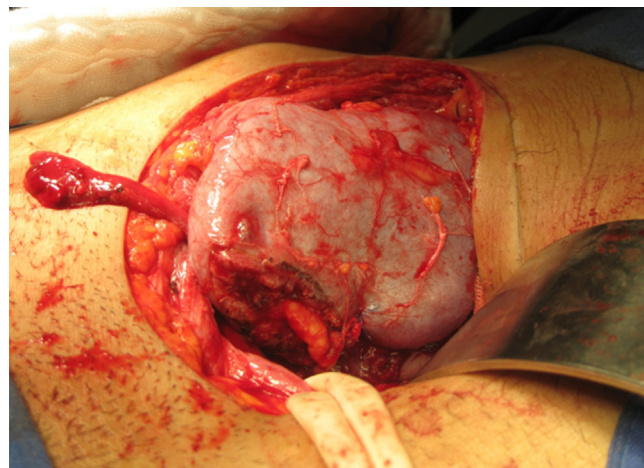


Fig. 4. Transected surface of the isthmus after reperfusion.

128 $\mu\text{mol/L}$ (1.45 mg/dL). Donor and recipient were reevaluated at 24 months and both remain in good health and no complications.

3. Discussion

During preoperative evaluation of a living kidney donor multiple abnormalities can be found. Some of these can be surpassed or treated before the operation. From a surgical point of view, anatomic variations that can affect transplant feasibility, graft viability, and especially long term function must be taken in consideration [9]. When vascular or urinary abnormalities are present and there is no other suitable living donor, the alternative may be to sign in the patient in a cadaveric organ donor program with the disadvantages that this entails: large lists, long waiting time, urgent surgery and poor compatibility [10]. Chronic organ shortage and increased number of patients waiting for a transplant sometimes makes it necessary to use marginal donors or donors with vascular

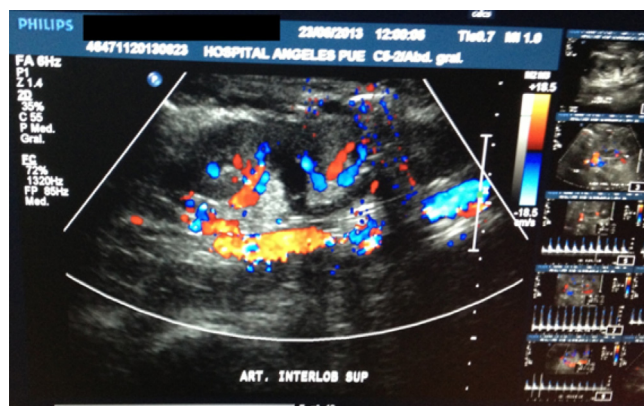


Fig. 5. Doppler ultrasonography showing complete perfusion.

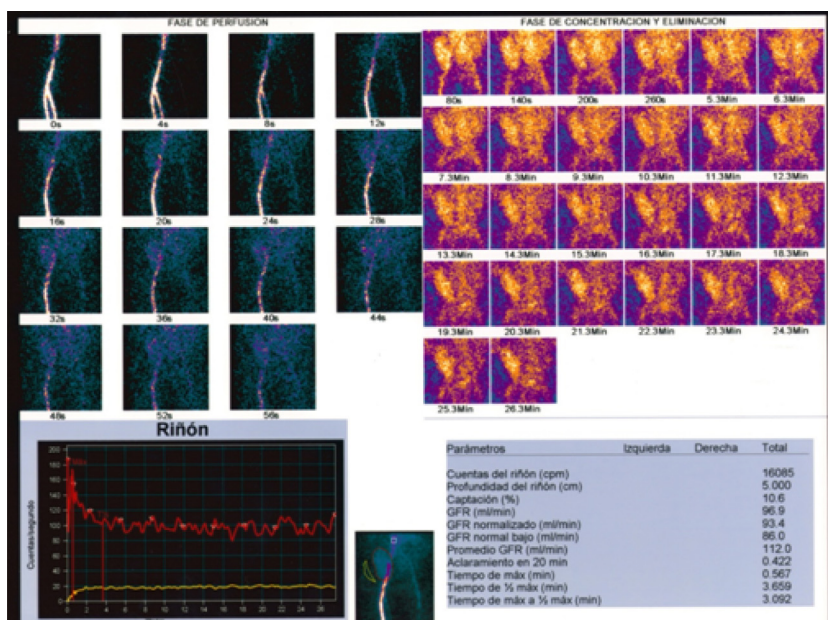


Fig. 6. Scintigraphy showing changes compatible with acute tubular necrosis.

or urinary abnormalities, which are a surgical challenge, while not losing sight of donor and patient safety. Common issues are vascular abnormalities with the need of lengthy back table surgery, or urinary abnormalities such as a double collector system [11].

In our institution we evaluate the living donor with angiogram or angioresonance with tridimensional reconstruction of the vascular and urinary tree, to decide which kidney to use [12,13]. In case of a second transplant, this imaging technique allows us to evaluate the selected kidney for preparation of reconstruction if an abnormality is found.

There are three abnormalities that can be found in a horseshoe kidney: ectopia, malrotation and vascular changes [14]. Graves defined three types of arteries in a horseshoe kidney [15]: in type 1, there are single arteries in each side; in type 2, lower arteries arise from the aorta and in type 3, middle and lower arteries arise from the aorta. Type 3 arteries probably pose an increased surgical risk in the donor because of the technical difficulties during separation and implantation. A shared urinary pelvis is another factor that precludes the excision in a living donor. When this anatomic feature is found in cadaveric kidneys it must be transplanted en bloc, but in living donors this finding precludes the donation [16]. Other factors which influence the decision to split the kidney are the number of veins and the nature of the pole fusion, if it is fibrous or parenchymal tissue [9].

With these anatomical considerations in mind, the experience from horseshoe kidney cadaveric donors encouraged us to consider its use in living donors, and the decision was made mainly on an anatomical basis. Fusion usually occurs in the inferior pole and it can be either fibrous tissue that can be cut without hemorrhagic risk or renal tissue. In both cases separation of the tissue can be made with a suitable hemostatic technique, such as bipolar or harmonic energy, a local hemostatic agent or a linear cutter stapler [1]. A careful exploration of the arterial anatomy is mandatory in order to establish the line of transection. There are usually two or three arteries found in each renal segment and the decision to make a back table surgery to attach two arteries to make a common one is based on the distance between them. In this case, they were too distant to join them together and thus were anastomosed separately, the superior to the right internal iliac artery and the inferior to the right external iliac artery, the vein was anastomosed to the right external iliac vein and a Lich-Gregoir ureteral implant was made.

The most common complication reported is urinary leakage [3–5] most likely due to the anterior situation of the urinary pelvis. In our experience we routinely use a ureteral double-J stent in order to prevent any urinary complication, especially in these cases where the urinary pelvis is left posterior to the kidney. Acute tubular necrosis was the most likely explanation for the DGF seen in this, perhaps due to the clamping of the arteries to limit the place for transection causing warm ischemia, or as a result of the prolonged total ischemia time caused by the need for more arterial anastomoses during back table surgery. We had a total ischemia time of 125 min, using HTK solution for prolonged preservation. In this case, despite good vascular reperfusion, the graft initiated urine production a week later.

There are only 7 horseshoe kidney reports around the world obtained from living donors (Table 1), none has reported a donor complication and despite the recipient complications, there is a good long term function of the graft and the mean follow time is 22.75 months (8–54) including this case. We suggest that the decision must be made once the surgical risk in the donor is thoroughly assessed; however, more evidence is needed to make a more definitive statement on the technical and ethical aspects of this procedure.

4. Conclusion

We consider that the use of a segment obtained from a horseshoe kidney living donors may be a safe alternative in renal transplantation, once a thorough evaluation of vascular and urinary anatomy is made to rule out possible anatomical variations that could increase the surgical risk in the donor.

Conflicts of interest

The authors declare that they have no conflict of interests regarding the publication of this paper.

Sources of funding

There was no source of funding.

Ethical approval

The surgery was approved by the transplant's committee of the hospital, supervised by the ethical committee.

Consent

The informed consent for the surgery was obtained and certified by two witness, as well as the consent to be published.

Author contribution

Jaime Manuel Justo-Janeiro: Main investigator, study concept, data collection, analysis and writing the paper.

Eduardo Prado Orozco: Data collection and analysis.

Roberto Enríquez Reyes: Data collection and analysis.

René de la Rosa Paredes: Study concept, data collection and analysis.

Alfonso Lozano Espinosa: Data collection and analysis.

JesúsMier Naylor: Data collection, analysis and writing the paper.

Luis G. Vázquez de Lara Cisneros: Study concept, data collection, analysis and writing the paper.

References

- [1] H.M. Hau, H.M. Morgul, D. Uhlmann, A. Thelen, P. Fellmer, C. Benckert, et al., Horseshoe kidney for transplantation: technical considerations, *Scand. J. Urol.* 47 (2013) 76–79.
- [2] T.O. Sezer, I. Solak, M. Sozbilen, O. Firat, M. Yilmaz, H. Toz, et al., A horseshoe kidney from a live donor as a renal transplant: case report, *Exp. Clin. Transplant.* 11 (2013) 454–457.
- [3] M. Aikawa, T. Hashiba, Y. Dobashi, S. Inoue, K. Kuzuhara, O. Otsubo, A case report of use of horseshoe kidney as renal transplant from live donor [In Japanese], *Nihon Hinyokika Gakkai Zasshi* 89 (1998) 62–65.
- [4] S. Inoue, K. Imai, K. Kuzuhara, O. Ootubo, A. Yamada, Use of horseshoe kidney as renal transplant from living donor: its surgical feasibility and pitfalls, *Transplant. Proc.* 32 (2000) 1586–1588.
- [5] A. Goyal, K. Gaitonde, S.N. Sagade, B.V. Shah, M.H. Kamat, Transplantation of horseshoe kidney from living-related donors: report of two cases, *Transplant. Proc.* 35 (2003) 32–34.
- [6] N. Huser, K.E. Gerauer, A.R. Novotny, V. Assfalg, M.J. Stangl, Successful living donor transplantation of a kidney with horseshoe malformation: extending the donor pool, *Transplant. Int.* 18 (2005) 761–762.
- [7] A. Dinckan, A. Tekin, S. Turkyilmaz, H. Kocak, A. Gurkan, O. Erdogan, et al., Horseshoe kidney for transplant: report of 3 cases, *Exp. Clin. Transplant.* 5 (2007) 716–719.
- [8] S. Kumar, D.K. Agarwal, S. Guleria, P. Pushkar, Expanding the living renal donor pool by using a horseshoe kidney, *Indian J. Nephrol.* 25 (2015) 124–125.
- [9] J.T. Foster, P.E. Morrissey, Segmental renal ischemia following transplantation of horseshoe kidney as separate allografts, *Case Rep. Transplant.* (2013) 852127.
- [10] T. Pontinen, K. Khanmoradi, A. Kumar, H. Kudsi, S. Cheng Kung, D. Chewaproug, R. Zaki, J. Ortiz, Horseshoe kidneys: an underutilized resource in kidney transplant, *Exp. Clin. Transplant.* 8 (2010) 74–78.

- [11] M.M. Rodriguez, Congenital anomalies of the kidney and the urinary tract (CAKUT), *Fetal Pediatr. Pathol.* 33 (2014) 293–320.
- [12] P.J. Arevalo, T.F. Gragera, T.A. Marin, F.L. Koren, C. Hayoun, N. Daimiel, I. Angio, CT assessment of anatomical variants in renal vasculature: its importance in the living donor, *Insights Imaging* 4 (2013) 199–211.
- [13] J.Q. Zhang, X.P. Hu, W. Wang, X.B. Li, H. Yin, X.D. Zhang, Multidetector row–CT in evaluation of living renal donors, *Chin. Med. J. [Engl.]* 123 (2010) 1145–1148.
- [14] K. Natsis, M. Piagkou, A. Skotsimara, V. Protogerou, I. Tsitouridis, P. Skandalakis, Horseshoe kidney: a review of anatomy and pathology, *Surg. Radiol. Anat.* 36 (2014) 517–526.
- [15] C.S. Zipitis, T. Augustine, A. Tavakoli, R. Surange, A. Agrawal, H.N. Riad, Horseshoe kidney transplantation, *Surgeon* 1 (2003) 160–163.
- [16] O.B. Stroosma, H. Schurink, G. Kootstra, Current opinions in horseshoe kidney transplantation, *Transpl. Int.* 15 (2002) 196–199.

Open Access

This article is published Open Access at scimedirect.com. It is distributed under the [IJSCR Supplemental terms and conditions](#), which permits unrestricted non commercial use, distribution, and reproduction in any medium, provided the original authors and source are credited.